



# PMMA Cranioplasty Making by Using Open-Source CAD Software, PLA Printers, and Silicone Rubber Molds: Technical Note with Two Illustrative Cases

Azad Malikov<sup>1</sup> Ahmet Eren Secen<sup>1</sup> Ozgur Ocal<sup>1</sup> Denizhan Divanlioglu<sup>1</sup>

<sup>1</sup>Department of Neurosurgery, Ankara City Hospital, Ankara, Turkey

Address for correspondence Azad Malikov, MD, Department of Neurosurgery, Ankara City Hospital, Ankara 06800, Turkey (e-mail: azadmelik33@gmail.com).

AJNS 2022;17:317–323.

## Abstract

In this technical report, we discuss the design and production of polymethyl methacrylate (PMMA) implants, which we successfully applied in two patients using silicone molds, and a retrospective review of these patients at 1- and 6-month intervals. By using open-source computer-assisted design software, three-dimensional printers, and the patient's thin-sliced computed tomography data, we designed and produced the implant template and used it to make silicone rubber molds for intraoperative PMMA casting with good results. As a negative of the implant, we created a silicon mold, which can be autoclaved.

## Keywords

- ▶ PMMA cranioplasty
- ▶ PLA printer
- ▶ silicone mold

Two patients underwent PMMA cranioplasty using this method. Both implants were fitted into the defect without manipulation and good aesthetic appearance of all patients was achieved. At follow-up 1 and 6 months after the operation, no complication was noted and the patients tolerated the cranioplasty plate well.

## Introduction

The evolution of cranioplasty parallels the development of technology, the growth of our collective imagination, and our desire to provide maximum benefit with minimum risk and the smallest footprint.<sup>1</sup>

Using autografts from other parts of the body, such as the contralateral skull vault or the ribs, is feasible but incurs the cost of additional donor site morbidity.<sup>2,3</sup>

Many synthetic materials have been used successfully in cranioplasty.<sup>4–6</sup> Today, in the cranioplasty commonly used synthetic materials include polymethyl methacrylate (PMMA), titanium, ceramics, and polyetheretherketone.<sup>6</sup> The main advantage of PMMA over all these materials is that it is cost-effective, available in cement form and can be molded intraoperatively. PMMA is an acrylic polymer created when two sterile components (a powder and a liquid) are mixed, while the polymer sets, it can be molded into a

specific shape.<sup>7</sup> Once hardened and cooled, it is safe for implant into humans.<sup>7,8</sup>

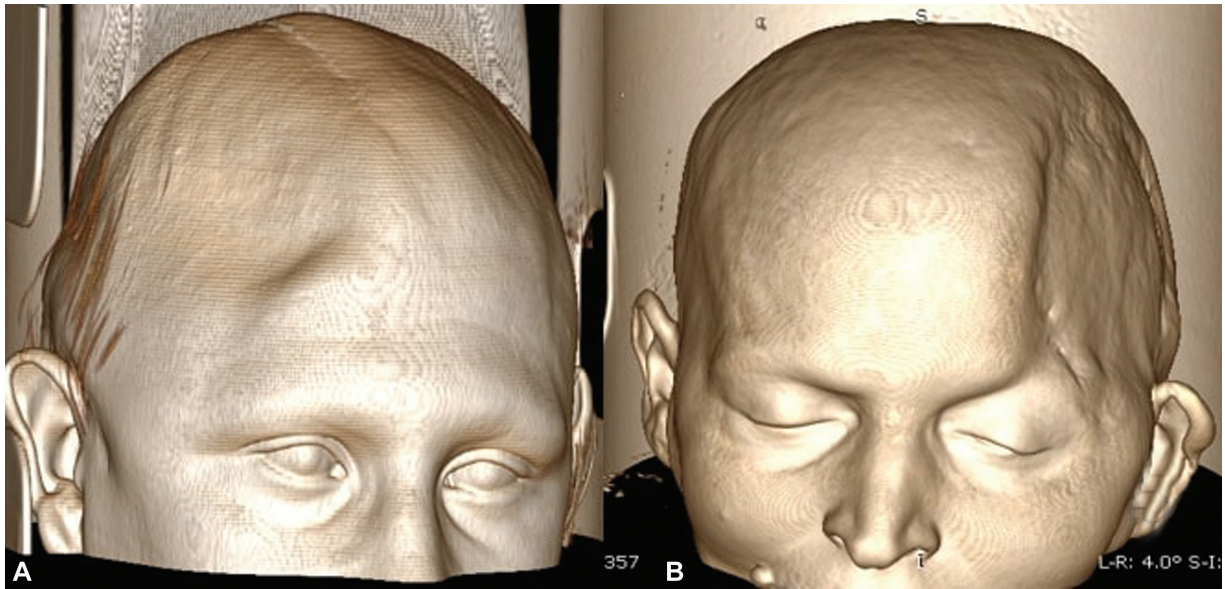Three-dimensional (3D) printing technology also known as additive manufacturing, together with modern computer-assisted design (CAD) and computer-aided manufacturing systems and rapid prototyping, facilitates the evaluation of cranial defects and allows accurate fabrication of custom-designed objects, and has immense potential in the medical field, particularly for surgical planning and implant production.<sup>9</sup> 3D prints of anatomical structures could be produced with submillimeter accuracy (< 0.5 mm) compared with the original specimens.<sup>10,11</sup> In a preclinical study, Tan et al obtained excellent cosmetic results with patient-specific PMMA implants produced with low-cost 3D printed polylactic acid (PLA) molds.<sup>11</sup> Similar to this study, we also demonstrate how to produce patient-specific implant using desktop 3D printers, but unlike Tan et al's technique, we did

DOI <https://doi.org/10.1055/s-0042-1750812>.  
ISSN 2248-9614.

© 2022. Asian Congress of Neurological Surgeons. All rights reserved.

This is an open access article published by Thieme under the terms of the Creative Commons Attribution-NonDerivative-NonCommercial-License, permitting copying and reproduction so long as the original work is given appropriate credit. Contents may not be used for commercial purposes, or adapted, remixed, transformed or built upon. (<https://creativecommons.org/licenses/by-nc-nd/4.0/>)

Thieme Medical and Scientific Publishers Pvt. Ltd., A-12, 2nd Floor, Sector 2, Noida-201301 UP, India



**Fig. 1** Initial images of the patient 1 (A) and 2 (B) created with head computed tomographic rendering using Radiant Dicom Viewer (Medixant, Poznan, Poland), user friendly, open-source software.

not use PLA molds, but silicone molds to get precise implants intraoperatively, which were successfully used in two patients. Using CAD software and the patient's neuroimaging data, we designed and produced the implant template and used it to make silicone rubber molds for intraoperative PMMA casting with good results. We created a silicon mold as a negative of the implant based on a 3D reconstructed image of the defect. The silicone mold can be autoclaved preoperatively, which allows the surgeon to create a sterile implant that matches the defect perfectly.

The purpose of this article is to demonstrate our method of creating patient-specific templated silicone molds, assess its safety and practicality, and compare it to existing techniques.

## Materials and Methods

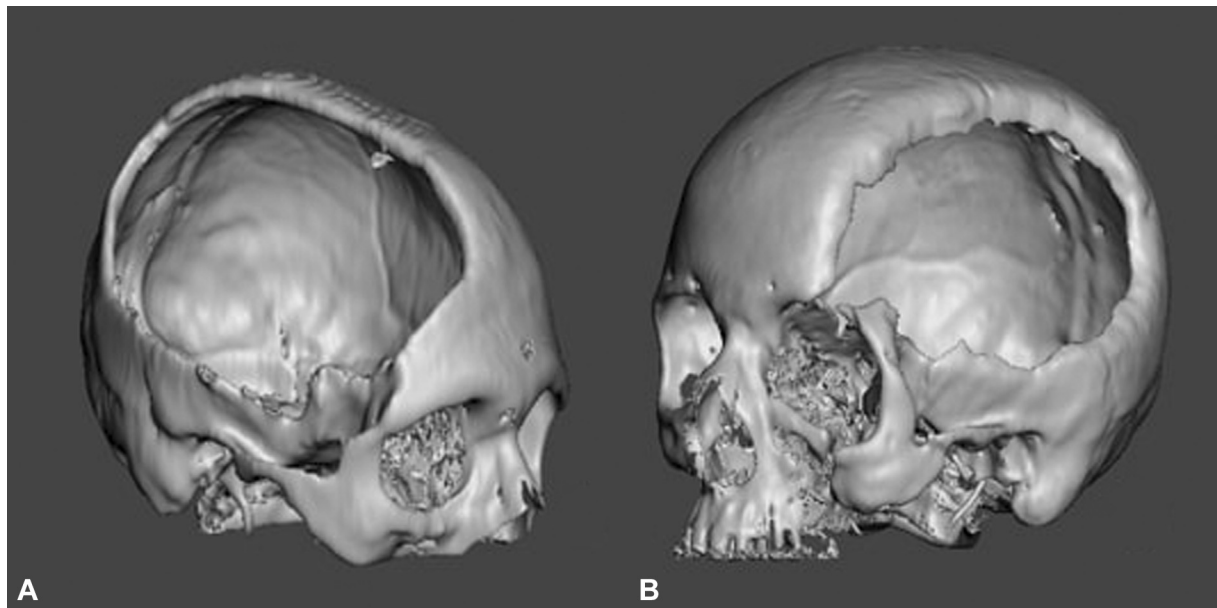
The Helsinki Declaration guidelines had been followed. Both patients had been informed about this new technique and gave written consent for performing cranioplasty using this method. Both patients were considered good candidates for investigated method.

### Patients

Patient 1 was a 21-year-old male who was admitted in hospital 3 years ago with traumatic brain injury and underwent an immediate right-sided decompressive craniotomy. He suffered from Broca-type aphasia and left-sided hemiparesis. The patient underwent preoperatively a cerebral computed tomography (CT) scan with thin slices (1 mm) (►Fig. 1A).

Patient 2 was a 54-year-old female who suffered 4 years previously from a major traumatic brain injury complicated by left-sided subdural hematoma that required immediate left-sided decompressive craniotomy. The defect was repaired two times with acrylic cranioplasty that got infected and implant removed. She was referred to us after

6 months of last cranioplasty. She suffered from frontal lobe syndrome and epilepsy. The patient underwent preoperatively a cerebral CT scan with thin slices (1 mm) (►Fig. 1B). Clinical consideration of the CAD algorithms and their potential application in this study are briefly outlined. Contiguous 1-mm reconstructed slices were produced from the CT data volume. The data, in DICOM format, was transferred to a computer workstation for editing in open-source image-editing software. We use open-source image-editing software and desktop 3D printers, which are briefly described in the following text. With computer software (3D Slicer 4.11.0; Surgical Planning Laboratory, Department of Neurosurgery, Ankara City Hospital, Ankara, Turkey), image segmentation was performed using the threshold method, based on density ranges of the Hounsfield units, the 3D model of the region of interest was obtained, and the data was exported in the Standard Tessellation Language (STL) format later on. Next, using 3D modeling software (MeshMixer 3.5; Autodesk Inc., San Rafael, California, United States), the STL file was then analyzed and reverse engineering was performed to make solid CAD (►Fig. 2A, B) from the STL file so that operations such as editing, modelling, and Boolean operations could be performed. Then using Blender software (Blender 2.8  $\beta$ , Blender Foundation, community) a mirror image of the normal model was created, resized (►Fig. 3A, B), and overlapped onto the mirror model (►Fig. 4A, B). The Boolean operation was performed on the superimposed solids. After performing the subtraction, the contours were not closed and small missing spaces were repaired and small protruding areas were cropped. The resulting mesh was then exported in STL format to get the file. The mirrored part was subtracted from the defect, leaving the missing part. The two designed prototype models are shown in ►Fig. 1A, B. Both the STL files (models of the defective skull and implant) generated were converted into slices in the G-code format to be printed in PLA material using fusion deposition modeling technique.



**Fig. 2** The Standard Tessellation Language files obtained by using three-dimensional Slicer software were converted to solid computer-aided design form in patient 1 (A) and patient 2 (B).

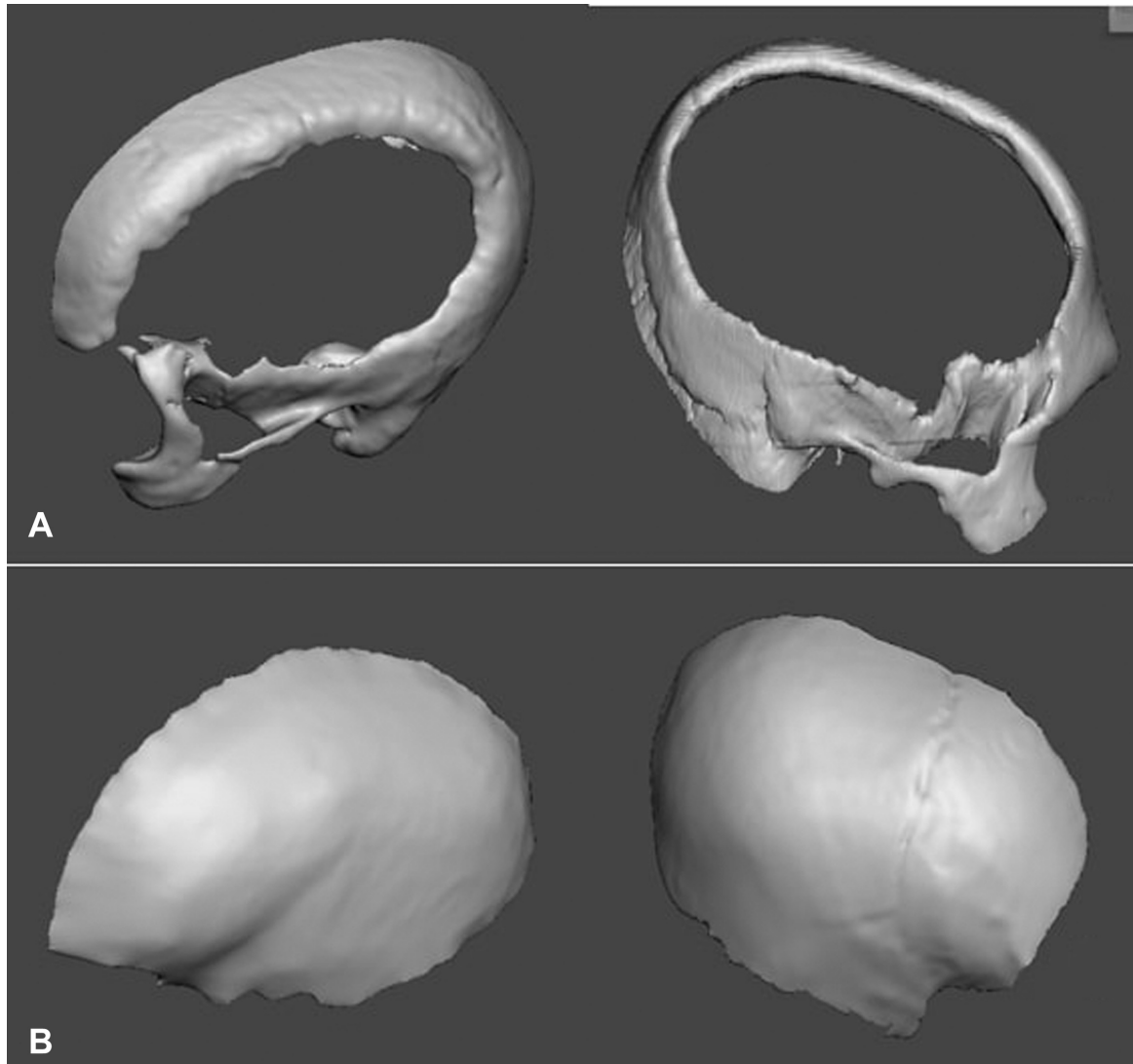
The 3D models of both the defective skull and the implant template were “sliced” with computer software (Cura 15.04.3; Ultimaker Industries) with the following settings: infill, 15%; shells, 0.8; layer height, 0.2 mm; extrusion temperature, 220°C; speed while extruding, 40 mm/second; speed while traveling, 100 mm/second; and the addition of both raft and supports. These files exported in G-code and then sent to the desktop 3D printer (Anet A8; Shenzhen Anet Technology Co., Ltd), which produced two prototypes. The defective skull model took approximately 6 hours to print and the implant model was printed in approximately 4 hours. The printed implant prototype allows us to make molds, that can be used to produce the cranial prosthesis intraoperatively. The two printed models are shown in ▶Fig. 5A–C. The silicon rubber molds were made by using Elite Double 22 Fast duplicate silicon. The silicon mold is sterilized by steam autoclave just prior to the procedure and presented to the surgeon (▶Fig. 6A) once the defect is exposed. We exposed the dural edges until the full thickness of the skull surrounding the defect (▶Fig. 7A). PMMA (Mendec Cranio Radiopaque bone cement; Tecres S.p.A.) is mixed and placed in the mold. The bone cement was allowed to harden and then after removal from the mold (▶Fig. 6B). Five- to six-millimeter holes were drilled in the center of cranioplasty plate to prevent development of an epidural hematoma. The thickness of the implant produced for each case was of 5 mm. The thickness of the prosthesis matched the patient’s cranial vault thickness. A drain was placed and then the plate was secured in place with titanium miniplates and screws (▶Fig. 7B, C). Prophylactic antibiotics were given routinely prior to the incision. The defect is routinely closed in available layers. No complications were observed in either of the cases intraoperatively. ▶Fig. 8A, B shows postoperative CT images with bone reconstruction.

## Results

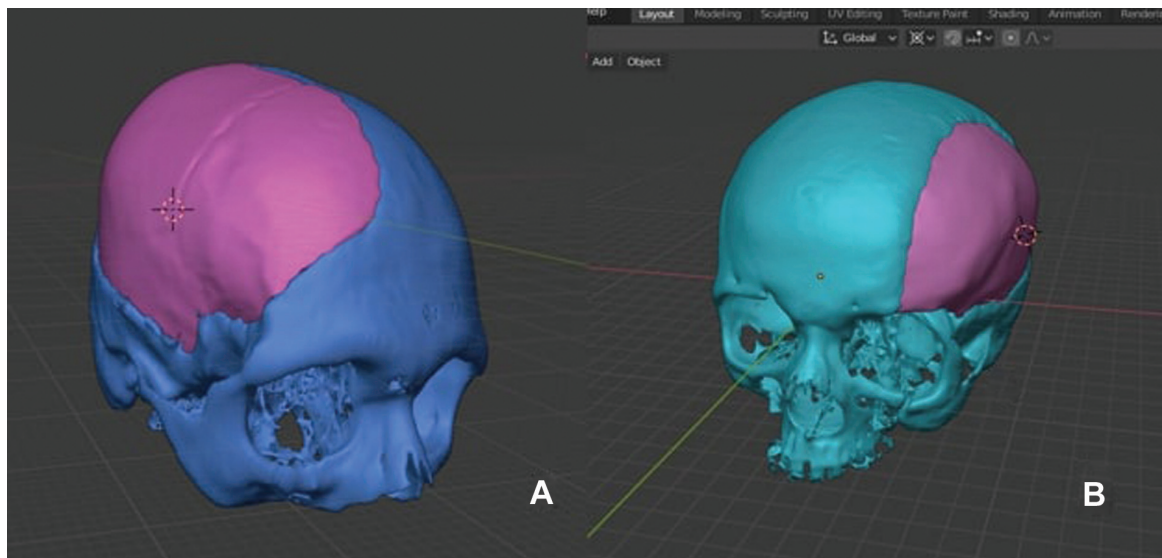
Total of two patients underwent PMMA cranioplasty using a silicone mold. The implant model was designed and manufactured successfully. The generation and design of the digital models were completed in 60 minutes. The implant template was printed in approximately 4 hours. Then using the templated silicone molds, we created the implants intraoperatively. Two units of PMMA were used to form the acrylic cranioplasty implant. Application of the bone cement in its putty form to the silicone mold was simple. Both implants were fitted into the defect without manipulation and the good aesthetic appearance of all patients was achieved. At follow-up 1 and 6 months after the operation, no complication was noted and the patients tolerated the cranioplasty plate well. No septic complications were noted postoperatively. Fitting the implant to the craniotomy defect did not require any further drilling or modification. There were no intraoperative complications; the drain was withdrawn when the flow rate was less than 50 mL in the postoperative 24 hours and the patients were discharged on the second and third days postoperatively. At follow-up 1 and 6 months after the operation, no complication was noted and the patients tolerated the cranioplasty plate well. Thanks to use of this method, both patients had the excellent cranial contour.

## Discussion

Considerably cost saving is achieved by using described method of creating a templated silicone mold, which is the negative of the patient-specific implants. The silicone mold can be autoclaved preoperatively, which allows the surgeon to create a sterile implant that matches the defect perfectly. Sepsis in cranioplasty is a well-known complication; Kwarcinski et al<sup>12</sup> in their meta-analysis of materials,

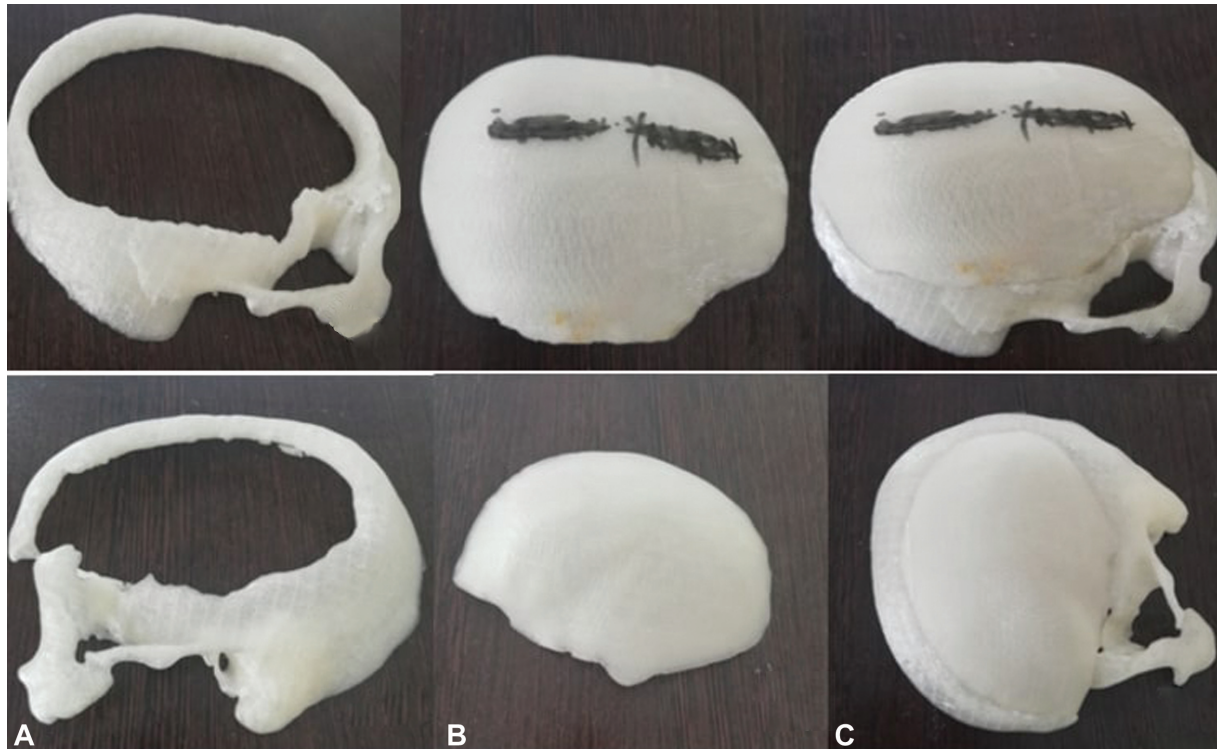


**Fig. 3** Models of the defective skull and implant template of patient 1 (A) and patient 2 (B).

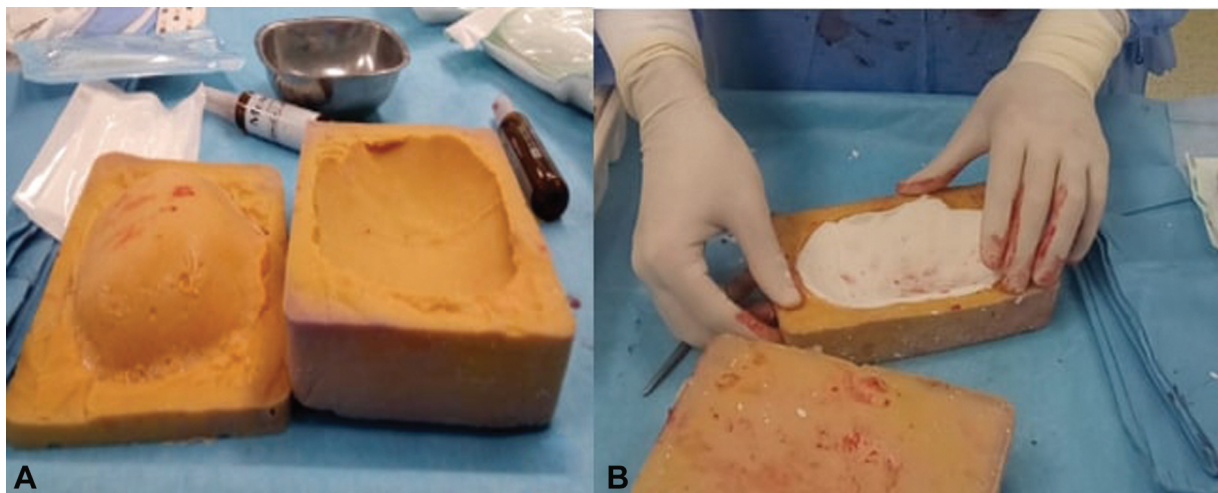


**Fig. 4** The symmetrization of skull by obtaining a mirrored image of the contralateral side via the Boolean subtraction process in patient 1 (A) and patient 2 (B).





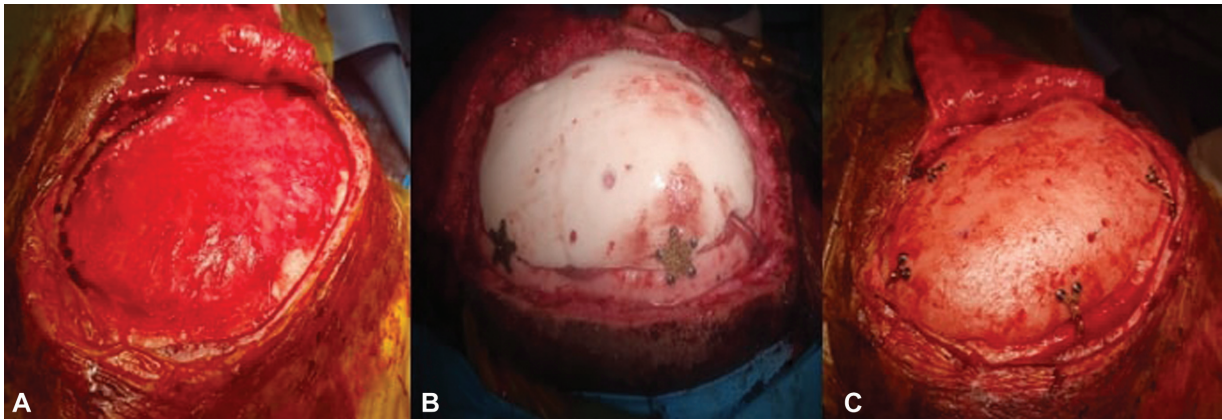
**Fig. 5** Prototypes of the cranial prosthesis of patient 1 (A) and patient 2 (B). (C) Assembled models to test precision. Note the perfect marginal adaptation of prototypes.



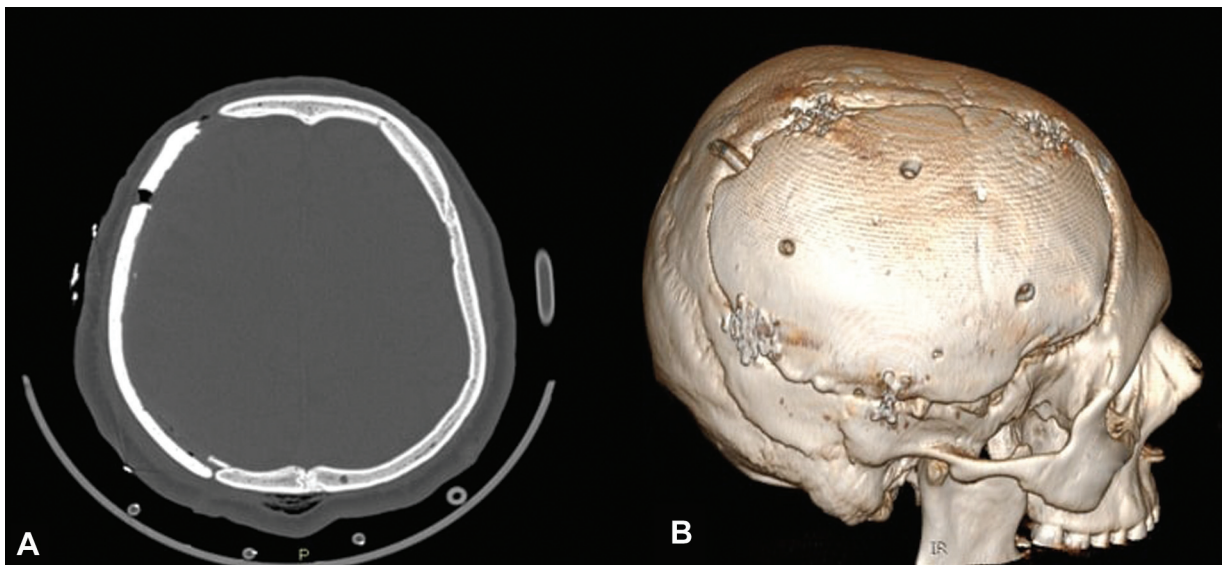
**Fig. 6** (A) The sterilized silicone rubber mold; (B) final prosthesis with the same dimensions of the initial prototype.

manufacturing techniques, and infection risk demonstrated an overall sepsis rate of 6.99% in premanufactured PMMA implants, 10.98% in hand-formed PMMA implants, and 6.86% in templated PMMA implants.<sup>13</sup> This was comparable with titanium mesh and plates that had 7.71 and 8.31% average reported infection rates.<sup>13</sup> In our study, no septic complications were noted. The main advantage of silicone rubber is that it allows preservation of very thin details of the plate (e. g., margins) during unmolding, which provided good stabilization and there was no need for rigid fixation.<sup>14</sup> One of the other advantages of the silicon mold is the ability to reuse it if necessary as the mold is simply resterilized in theater and a

new PMMA implant created.<sup>15</sup> In our study, we demonstrated the safety and practicality of making cranial implants by using open-source CAD software, a PLA 3D printer, PMMA, and autoclavable laboratory silicone. The implant created matched to the craniectomy defect perfectly. We used PLA to create both the defective skull and the implant template. PLA is a biodegradable and biocompatible thermoplastic with widespread applications in both medical and nonmedical fields.<sup>16,17</sup> It has been used for implantation in the human body for functions ranging from soft tissue fillers to fracture fixing screws.<sup>18,19</sup> With a glass transition temperature of 55° C, it is unsuitable for the autoclave.<sup>10</sup> Since the PLA is not



**Fig. 7** (A) Defect exposed after the elevation of the scalp in patient 2; (B and C) fixation of the prosthesis into the defect in patient 1 (A) and patient 2 (B). Note an implanted prosthesis having exact shape and size as of skull defect.



**Fig. 8** (A) Postoperative computed tomography (CT) image in patient 1 and (B) postoperative CT image with bone reconstruction of the same patient.

autoclave-resistant, we did not use PLA molds for intraoperative molding.

## Conclusion

In this study, we showed that patient-specific silicone rubber molds using PMMA to create cranial implants intraoperatively are safe, have excellent cosmetic results, and are a very cost-effective option to treat large and complex cranial defects.

### Conflict of Interest

None declared.

## References

- 1 Feroze AH, Walmsley GG, Choudhri O, Lorenz HP, Grant GA, Edwards MS. Evolution of cranioplasty techniques in neurosurgery: historical review, pediatric considerations, and current trends. *J Neurosurg* 2015;123(04):1098–1107
- 2 Munro IR, Guyuron B. Split-rib cranioplasty. *Ann Plast Surg* 1981; 7(05):341–346
- 3 Viterbo F, Palhares A, Modenese E. Cranioplasty: the autograft option. *J Craniofac Surg* 1995;6(01):80–83
- 4 Harris DA, Fong AJ, Buchanan EP, Monson L, Khechoyan D, Lam S. History of synthetic materials in alloplastic cranioplasty. *Neurosurg Focus* 2014;36(04):E20
- 5 Sanan A, Haines SJ. Repairing holes in the head: a history of cranioplasty. *Neurosurgery* 1997;40(03):588–603
- 6 Shah AM, Jung H, Skirboll S. Materials used in cranioplasty: a history and analysis. *Neurosurg Focus* 2014;36(04): E19
- 7 Marbacher S, Anderegg L, Erhardt S, et al. Intraoperative template-molded bone flap reconstruction for patient-specific cranioplasty. *Neurosurg Rev* 2012;35(04):527–535, discussion 535
- 8 Walker I, Vlok AJ, Kamat A. A double-edged sword: the effect of technological advancements in the management of neurotrauma patients. *Br J Neurosurg* 2017;31(01):89–93
- 9 Rengier F, Mehndiratta A, von Tengg-Kobligh H, et al. 3D printing based on imaging data: review of medical applications. *Int J CARS* 2010;5(04):335–341

- 10 Tan ET, Ling JM, Dinesh SK. The feasibility of producing patient-specific acrylic cranioplasty implants with a low-cost 3D printer. *J Neurosurg* 2016;124(05):1531–1537
- 11 Baskaran V, Štrkalj G, Štrkalj M, Di Ieva A. Current applications and future perspectives of the use of 3D printing in anatomical training and neurosurgery. *Front Neuroanat* 2016;10:69
- 12 Kwarcinski J, et al. Cranioplasty and craniofacial reconstructions: a review of implant material, manufacturing method, and infection risk. *Applied Sciences* 2017;7(03):276
- 13 Vaishya R, Chauhan M, Vaish A. Bone cement. *J Clin Orthop Trauma* 2013;4(04):157–163
- 14 Rotaru H, Baciut M, Stan H, et al. . Silicone rubber mould cast polyethylmethacrylate-hydroxyapatite plate used for repairing skull defect. *J Craniomaxillofac Surg* 2006;34(04):242–246
- 15 Vlok AJ, Naidoo S, Kamat AS, Lamprecht D. Evaluation of locally manufactured patient-specific custom made implants for cranial defects using a silicone mould. *S Afr J Surg* 2018;56(03):38–42
- 16 Jamshidian M, Tehrany EA, Imran M, Jacquot M, Desobry S. Polylactic acid: production, applications, nanocomposites, and release studies. *Compr Rev Food Sci Food Saf* 2010;9(05):552–571
- 17 Lasprilla AJ, Martinez GA, Lunelli BH, Jardini AL, Filho RM. Polylactic acid synthesis for application in biomedical devices - a review. *Biotechnol Adv* 2012;30(01):321–328
- 18 Bartus C, William Hanke C, Daro-Kaftan E. A decade of experience with injectable poly-L-lactic acid: a focus on safety. *Dermatol Surg* 2013;39(05):698–705
- 19 Vleggaar D, Fitzgerald R, Lorenc ZP. Composition and mechanism of action of poly-L-lactic acid in soft tissue augmentation. *J Drugs Dermatol* 2014;13(4, Suppl):s29–s31