



# Rare Case of Solitary Nasal Fibrous Tumor Eroding Skull-Base

Aditendraditya Singh Bhati<sup>1</sup> Nishant Rana<sup>2</sup> Girish Raheja<sup>2</sup> Sudheer K. Tyagi<sup>1</sup>

<sup>1</sup> Department of Neurosurgery, Indraprastha Apollo Hospitals, New Delhi, India

<sup>2</sup> ENT Department, Indraprastha Apollo Hospitals, New Delhi, India

Address for correspondence Nishant Rana, MBBS, MS, Q 203, Homes 121, Sector 121, Gautam Budha Nagar, Noida, Uttar Pradesh, 201301 (e-mail: nishant52rana@gmail.com).

AJNS 2022;17:375–378.

## Abstract Keywords

- ▶ solitary fibrous tumor
- ▶ nasal
- ▶ anterior skull base
- ▶ endoscopic excision
- ▶ CD34

Solitary fibrous tumor (SFT) is a spindle cell lesion, classified under mesothelial tumors. Involvement of the nasal cavity, paranasal sinuses, and nasopharynx is rare. We present an extremely rare case of SFT of nasal origin eroding the anterior skull base. Complete local excision is the treatment of choice in the head and neck SFT, and we successfully excised the tumor by endoscopic approach only. The patient followed an uneventful course without any evidence of recurrence on 8-months follow-up.

## Introduction

Solitary fibrous tumor (SFT) is an uncommon spindle cell lesion, which is of mesenchymal origin.<sup>1</sup> It is subclassified under mesothelial tumors.<sup>2</sup> They may occur in any anatomical sites but pleural SFT is the most common.<sup>3</sup> Within the head and neck, it is seen in the oral cavity (most common), orbit, salivary glands, upper respiratory tract, larynx, hypopharynx, thyroid, nasal cavity, nasopharynx, nasal septum, and temporal region.<sup>4–7</sup> In the central nervous system (CNS), it is reported to occur in the cerebellopontine angle, spinal dura, parasagittal region, meninges, and interventricular region.<sup>8</sup> The involvement of the nasal cavity, paranasal sinuses (PNSs) and nasopharynx is rarely seen and a tumor breaching or eroding skull base is extremely rare. In the sinonasal tract, they present with compressive symptoms while the tumor is still small.

SFTs in the nasal cavity and paranasal sinuses are being treated by endoscopic sinus surgery (ESS).<sup>9</sup> Sufficient excision of the tumor with disease-free tumor margin is curative in most of cases. Here in, we are reporting an extremely rare case of SFT of nasal origin, eroding the anterior skull base.

## Case Report

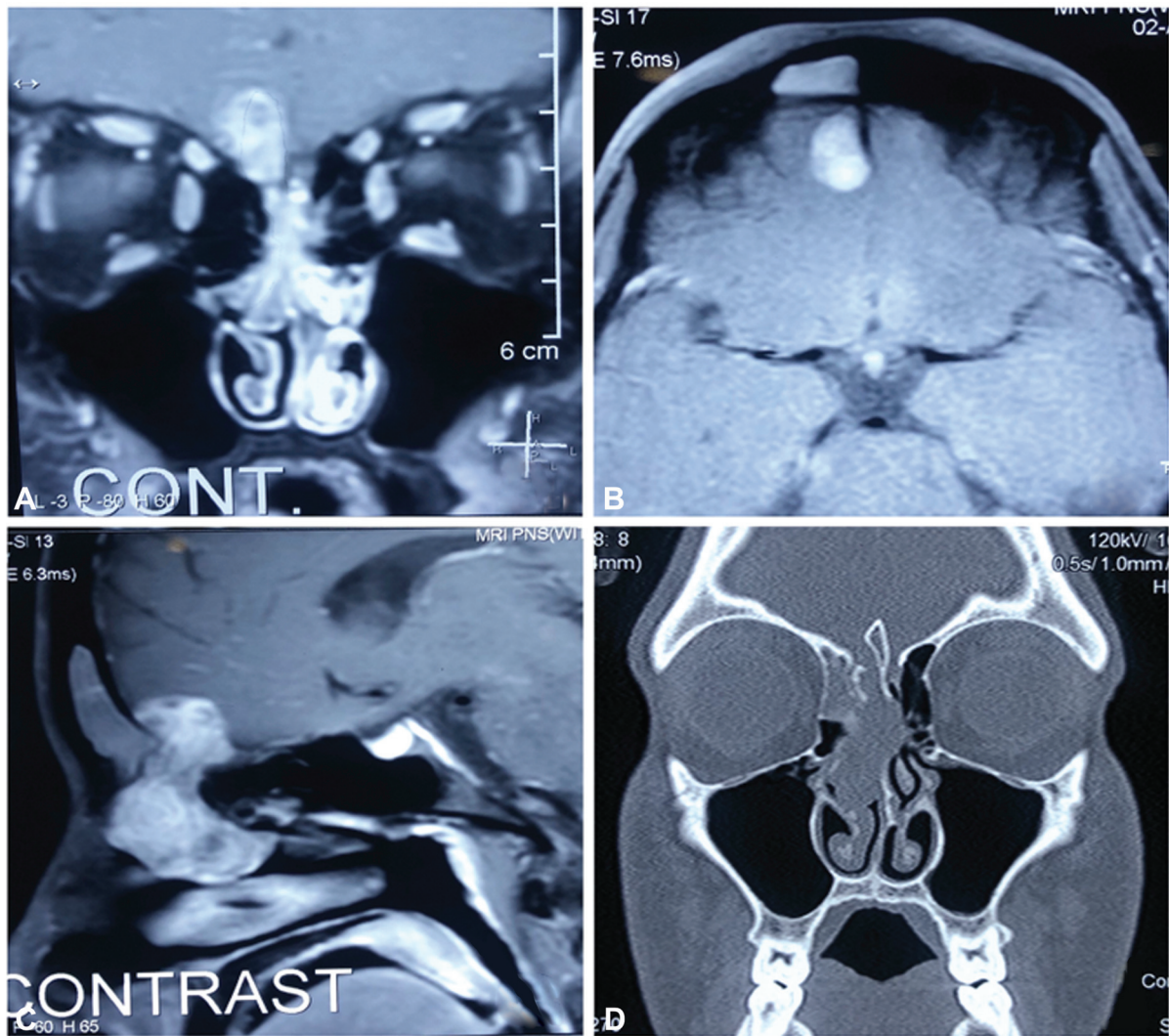
This 30-year-old male patient presented with complaints of nasal obstruction and bifrontal headache for the last 3 months. These complaints were insidious in onset and were progressive in nature. Ophthalmologic examination was normal. There was no history of nasal bleeding. There were no other known co-morbidities. On diagnostic nasal endoscopy a polypoidal mass was noted filling the right nasal cavity. A computed tomography of the nose and paranasal sinuses was planned, which was suggestive of a mass lesion involving ethmoidal air cells and extending into the anterior cranial fossa and destroying the cribriform plate. Later on, a gadolinium-enhanced magnetic resonance imaging (MRI) of the brain and paranasal sinuses was advised, which showed a dumbbell-shaped heterogeneous soft tissue lesion causing expansion and destruction of anterior and middle ethmoid air cells, middle turbinate with intracranial extension through right cribriform plate, showing heterogeneous post contrast enhancement. On the basis of radiological findings, the author's first impression was esthesioneuroblastoma and then an endoscopic decompression of the tumor was planned under general anesthesia (–Fig. 1).

DOI <https://doi.org/10.1055/s-0042-1750808>.  
ISSN 2248-9614.

© 2022. Asian Congress of Neurological Surgeons. All rights reserved.

This is an open access article published by Thieme under the terms of the Creative Commons Attribution-NonDerivative-NonCommercial-License, permitting copying and reproduction so long as the original work is given appropriate credit. Contents may not be used for commercial purposes, or adapted, remixed, transformed or built upon. (<https://creativecommons.org/licenses/by-nc-nd/4.0/>)

Thieme Medical and Scientific Publishers Pvt. Ltd., A-12, 2nd Floor, Sector 2, Noida-201301 UP, India



**Fig. 1** (A–C) Contrast MRI of the brain and PNS shows a dumbbell-shaped heterogeneously enhancing soft tissue lesion causing the expansion and destruction of anterior and middle ethmoid air cells, middle turbinate with intracranial extension through the right cribriform plate, into the right basi-frontal region. (D) Destruction of the right cribriform plate.

## Surgical Technique

The patient was prepared under general anesthesia. A diagnostic nasal endoscopy was done using a zero-degree endoscope. A moderately vascular tumor was seen involving the right nasal cavity. The tumor was delineated. Frontal recess was opened and thick mucus was drained followed by anterior and posterior ethmoidectomy. The tumor was seen extending into the anterior cranial fossa with erosion of the skull base and dura. The tumor excised entirely and the bony defect ( $\sim 1.5 \times 1$  cm) was repaired with fat, fascia, cartilage, and surgical glue. The arachnoid was intact and no cerebrospinal fluid (CSF) leak was seen. The nasal cavity was packed with merocel (**Fig. 2**).

The excised specimen was sent for histopathological examination. The nasal packing was removed after 72 hours.

After HPE and immunohistochemistry of the tumor, the final diagnosis of the SFT was confirmed. The tumor cells revealed diffuse positivity for vimentin, BCL-2, CD-34,

patchy faint positivity for SMA, and showed no expression for cyclin D1 and nuclear  $\beta$  catenin.

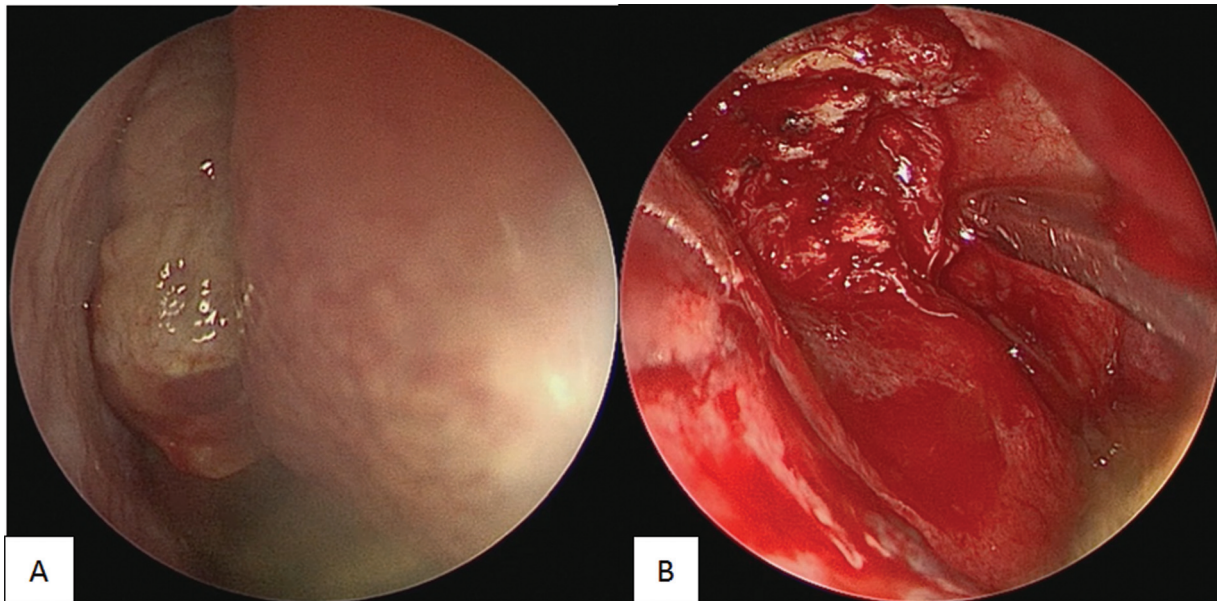
The patient had an excellent recovery post procedure and upon follow-up of 8 months, no recurrence was noted (**Fig. 3**).

## Discussion

Solitary fibrous tumors (SFTs) may manifest at any age and a slight male preponderance has been described.<sup>7</sup> SFTs arising in the head and neck are relatively rare ( $\sim 6\%$  of all SFTs) and sinonasal SFTs are further rare.<sup>10,11</sup> However, the number of reported cases involving the nose and paranasal sinuses (PNS) are increasing.

SFTs involving the nose and PNS are slow-growing, painless masses that typically present with unilateral mass, progressive nasal obstruction, rhinorrhea, anosmia, headache, epistaxis, and facial pain.<sup>12</sup> A few patients can develop exophthalmos, epiphora, and visual field changes in the case





**Fig. 2** (A) Endoscopic view of the tumor protruding into the nasal cavity. (B) Moderately vascular tumor being decompressed.

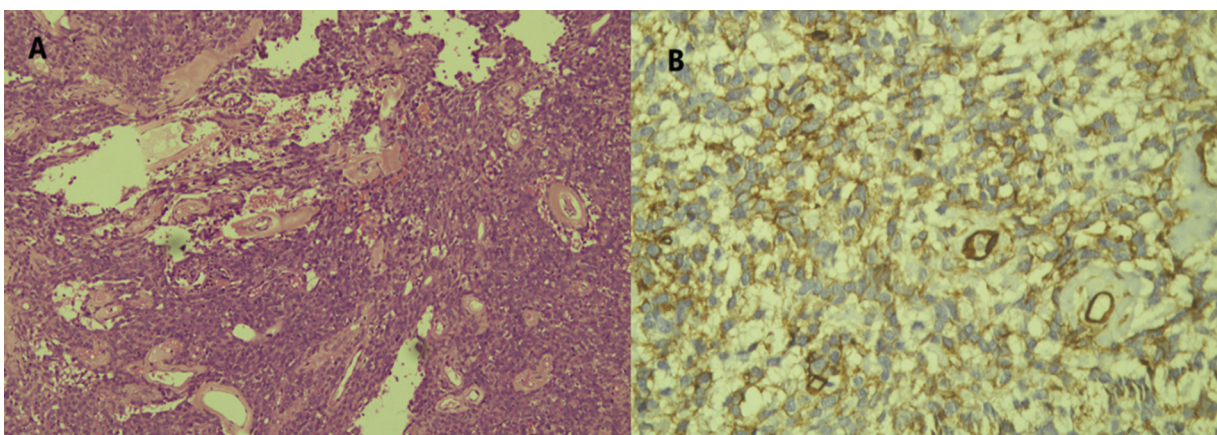
of orbital involvement by the tumor [sf-10]. If the central nervous system (CNS) is involved, symptoms such as headache, dizziness, gait disturbance, hemiparesis or hemiplegia, and alteration in mental status may present depending upon the involvement.<sup>13</sup>

On endoscopic examination of the nose, nasal SFT can be one of the two types. Either it will be grayish to pinkish, solid, smooth, and glistening mass or it will be a rough reddish mass that can easily bleed on touch or manipulation.<sup>14</sup> In the present case, the tumor was solid, pinkish, and did not bleed on touch.

On computed tomography scan (CT), SFTs of the nose and PNS appear as masses with irregular central bone density due to remodeling and may cause bony destruction, whereas on MRI (T2-weighted), it appears iso-to-hypointense.<sup>15</sup> Overall, the role of imaging in making diagnosis is challenging; however, MRI can narrow down the differential diagnosis.

While operating for SFTs of the nose and PNS, many differential diagnosis should be kept in mind including fibrosarcoma, inverted papilloma, hemangiopericytoma, nasopharyngeal carcinoma, esthesioneuroblastoma, and nasopharyngeal angiofibroma.<sup>4,6</sup> In extra pleural sites, the histopathological diagnosis of SFTs is difficult to make, because of its overlapping microscopic features to other spindle cell tumor and expression of many similar features to the other soft tissue tumors such as hemangiopericytomas, schwannomas, fibrous histiocytosis, and fibrosarcomas.<sup>6,16</sup>

The examination of pathological features with IHC is the key for diagnosis of SFTs. Grossly, the tumors are mostly soft to firm, encapsulated, red, and fibrous. Histologically, it is composed of spindle cells arranged in a nonspecific pattern with varying vascularity (present case had rich vascularity).<sup>17</sup> It usually stains positive for CD-34, CD-99, bcl-2 protein, and vimentin and negative for S-100.<sup>8,18</sup>



**Fig. 3** (A) 10 × , hematoxylin and eosin (H&E) stained cellular tumor composed of shells of plump ovoid to spindle cells, punctuated with many thick-walled hyalinized blood vessels. (B) 40 × , the tumor cells show diffuse positivity for CD34.

Local surgical excision is the treatment of choice and may involve endoscopic resection (current case), transcranial approach, maxillectomy, sphenoidotomy, external ethmoidectomy and midfacial degloving approach.<sup>5,19</sup> SFTs limited to the nasal cavity and PNS can be treated successfully by ESS only. The tumor involving the anterior skull base or breaching the cribriform plate may sometimes require additional approaches such as transcranial or open transfacial approach. Complete local excision is the treatment of choice in the head and neck SFT.<sup>16</sup> If completely excised, the chances of recurrence is minimal. In cases, where complete excision is difficult, adjunctive radiation therapy may prevent recurrence. In the present case, we successfully treated the tumor extending to the anterior skull base by endoscopic decompression only.

The prognosis of SFTs of the nose and PNS depends on its resectability. Other potential prognostic factors include the presence of malignant component, positive surgical margins, deep tumor location, and size of the tumor (difficult to achieve complete surgical resection if more than 10 cm).<sup>20,21</sup> SFTs of the head and neck region pose an anatomical challenge for surgeon in view of obtaining negative margins, compared with the tumor present elsewhere. Hence, a close follow-up becomes essential in such type of cases.

Darren et al reviewed 142 cases of SFT of the head and neck.<sup>16</sup> Alobid et al described 21 cases of SFTs originating from the nose and PNS.<sup>12</sup> Involvement and erosion of the anterior skull base have also been published in the literature.<sup>4</sup> Although head and neck SFTs behave in a benign manner and malignant variants have been recognized in sites other than the head and neck, malignant lesion with capability of involving the skull base have been detected very rarely.<sup>5,22</sup> Malignant lesions show a high cellularity, more than 4 mitoses per 10 high power field with hemorrhage and necrosis.<sup>9</sup>

## Conclusion

Solitary fibrous tumor (SFT) of the nasal cavity extending to the anterior skull base is a rare mesenchymal origin neoplasm and is a surgical challenge. Imaging and immunohistochemistry are critical for final diagnosis. Complete surgical excision is the treatment of choice and can be resected completely using endoscopic approach. Recurrence has been reported and thus long-term follow-up is mandatory.

### Funding

None.

### Conflict of Interest

None declared.

### Acknowledgments

We would like to thank the Department of Neurosurgery and ENT, Head and Neck Surgery, Indraprastha Apollo Hospitals, New Delhi, India.

## References

- Mentzel T, Bainbridge TC, Katenkamp D. Solitary fibrous tumour: clinicopathological, immunohistochemical, and ultrastructural analysis of 12 cases arising in soft tissues, nasal cavity and nasopharynx, urinary bladder and prostate. *Virchows Arch* 1997;430(06):445–453
- Mathew GA, Ashish G, Tyagi AK, Chandrashekhara R, Paul RR. Solitary fibrous tumor of nasal cavity: a case report. *Iran J Otorhinolaryngol* 2015;27(81):307–312
- Chan JK. Solitary fibrous tumour—everywhere, and a diagnosis in vogue. *Histopathology* 1997;31(06):568–576
- Hicks DL, Moe KS. Nasal solitary fibrous tumor arising from the anterior cranial fossa. *Skull Base* 2004;14(04):203–207
- Zeitler DM, Kanowitz SJ, Har-El G. Malignant solitary fibrous tumor of the nasal cavity. *Skull Base* 2007;17(04):239–246
- Witkin GB, Rosai J. Solitary fibrous tumor of the upper respiratory tract. A report of six cases. *Am J Surg Pathol* 1991;15(09):842–848
- Künzel J, Hainz M, Ziebart T, et al. Head and neck solitary fibrous tumors: a rare and challenging entity. *Eur Arch Otorhinolaryngol* 2016;273(06):1589–1598
- Kim JH, Yang KH, Yoon PH, Kie JH. Solitary fibrous tumor of central nervous system: a case report. *Brain Tumor Res Treat* 2015;3(02):127–131
- Takasaki K, Watanabe T, Hayashi T, Kinoshita N, Kumagami H, Takahashi H. Solitary fibrous tumor arising from the sphenoid sinus. *Case Rep Med* 2009;2009:316042
- Thompson LDR, Lau SK. Sinonasal tract solitary fibrous tumor: a clinicopathologic study of six cases with a comprehensive review of the literature. *Head Neck Pathol* 2018;12(04):471–480
- Smith SC, Gooding WE, Elkins M, et al. Solitary fibrous tumors of the head and neck: a multi-institutional clinicopathologic study. *Am J Surg Pathol* 2017;41(12):1642–1656
- Alobid I, Alós L, Blanch JL, Benítez P, Bernal-Sprekelsen M, Mollo J. Solitary fibrous tumour of the nasal cavity and paranasal sinuses. *Acta Otolaryngol* 2003;123(01):71–74
- Wang XQ, Zhou Q, Li ST, Liao CL, Zhang H, Zhang BY. Solitary fibrous tumors of the central nervous system: clinical features and imaging findings in 22 patients. *J Comput Assist Tomogr* 2013;37(05):658–665
- Fujikura T, Ishida M, Sekine K, Aoki H, Okubo K. Solitary fibrous tumor arising from the superior nasal turbinate: a case report. *J Nippon Med Sch* 2012;79(05):373–376
- Kim TA, Brunberg JA, Pearson JP, Ross DA. Solitary fibrous tumor of the paranasal sinuses: CT and MR appearance. *Am J Neuroradiol* 1996;17(09):1767–1772
- Cox DP, Daniels T, Jordan RC. Solitary fibrous tumor of the head and neck. *Oral Surg Oral Med Oral Pathol Oral Radiol Endod* 2010;110(01):79–84
- Brunnemann RB, Ro JY, Ordóñez NG, Mooney J, El-Naggar AK, Ayala AG. Extraleural solitary fibrous tumor: a clinicopathologic study of 24 cases. *Mod Pathol* 1999;12(11):1034–1042
- Hasegawa T, Matsuno Y, Shimoda T, Hasegawa F, Sano T, Hirohashi S. Extrathoracic solitary fibrous tumors: their histological variability and potentially aggressive behavior. *Hum Pathol* 1999;30(12):1464–1473
- Kessler A, Lapinsky J, Berenholz L, Sarfaty S, Segal S. Solitary fibrous tumor of the nasal cavity. *Otolaryngol Head Neck Surg* 1999;121(06):826–828
- Gold JS, Antonescu CR, Hajdu C, et al. Clinicopathologic correlates of solitary fibrous tumors. *Cancer* 2002;94(04):1057–1068
- Bowe SN, Wakely PE Jr, Ozer E. Head and neck solitary fibrous tumors: diagnostic and therapeutic challenges. *Laryngoscope* 2012;122(08):1748–1755
- Ito H, Fukuda M, Imamura Y, Fuse H. A malignant solitary fibrous tumor in the retroperitoneum. *Int J Clin Oncol* 2008;13(02):173–175