



Acute Liver Injury due to Glecaprevir/Pibrentasvir in a Patient with Chronic Hepatitis C Virus Infection without Cirrhosis

Ayushi Jain¹  Khalid Mumtaz²

¹Department of Internal Medicine, The Ohio State University Wexner Medical Center, Columbus, Ohio, United States

²Division of Gastroenterology, Hepatology and Nutrition, Department of Internal Medicine, The Ohio State University Wexner Medical Center, Columbus, Ohio, United States

Address for correspondence Khalid Mumtaz, MBBS, MSc,

Department of Clinical Medicine, Gastroenterology, Hepatology & Nutrition, Ohio State University Wexner Medical Center, Columbus, Ohio 43210, United States (e-mail: khalid.mumtaz@osumc.edu).

Avicenna J Med 2022;12:154–156.

Abstract

Keywords

- ▶ acute liver injury
- ▶ drug induced liver injury
- ▶ hepatitis C
- ▶ glecaprevir/pibrentasvir

We reported a rare case of acute liver injury in a patient with chronic hepatitis C virus infection without cirrhosis 4 weeks after initiation of glecaprevir/pibrentasvir. After prompt cessation of antiviral therapy, liver enzymes rapidly improved toward baseline. This case reflects the need to remain vigilant for the development of acute liver injury after initiation of glecaprevir/pibrentasvir even without a diagnosis of cirrhosis.

Introduction

Glecaprevir/pibrentasvir is a direct-acting antiviral oral agent used for treatment of pangenotypic hepatitis C virus (HCV) infections and has shown to achieve sustained virologic response rates of greater than 90% after 12 weeks of treatment.¹ The combination of glecaprevir, a NS3/4A protease inhibitor, and pibrentasvir, a NS5A inhibitor, in a ribavirin-free regimen has demonstrated safety and effectiveness in patients without liver function test (LFT) impairment or with mild LFT impairment but is not indicated for use in patients with moderate-to-severe liver impairment.

There are few reports of hepatic decompensation with the use of glecaprevir/pibrentasvir in patients with existing decompensated cirrhosis and reactivation of hepatitis B virus (HBV) coinfection.² Yoon et al reported a case of severe jaundice in a patient with compensated cirrhosis 12 weeks after initia-

tion of glecaprevir/pibrentasvir that resolved 3 months after drug cessation.³ However, acute liver injury is rare in a non-cirrhotic patient without HBV coinfection with the use of glecaprevir/pibrentasvir. We report a unique case of acute liver injury in a patient with chronic HCV infection without cirrhosis 4 weeks after initiation of glecaprevir/pibrentasvir.

Case Report

A 43-year-old female patient with a past medical history of intravenous drug use was known to have contracted chronic HCV infection genotype 2B approximately 10 years ago. She had no clinical, biochemical, or imaging features of cirrhosis and was initiated on glecaprevir/pibrentasvir for treatment of chronic HCV. Four weeks after initiation of glecaprevir/pibrentasvir, she was admitted with worsening right upper quadrant (RUQ) abdominal pain with nausea. Physical exam revealed jaundice

published online
July 3, 2022

DOI <https://doi.org/10.1055/s-0042-1750716>.
ISSN 2231-0770.

© 2022. Syrian American Medical Society. All rights reserved.

This is an open access article published by Thieme under the terms of the Creative Commons Attribution-NonDerivative-NonCommercial-License, permitting copying and reproduction so long as the original work is given appropriate credit. Contents may not be used for commercial purposes, or adapted, remixed, transformed or built upon. (<https://creativecommons.org/licenses/by-nc-nd/4.0/>)

Thieme Medical and Scientific Publishers Pvt. Ltd., A-12, 2nd Floor, Sector 2, Noida-201301 UP, India

and mild tenderness in the RUQ without Murphy's sign. No stigmata of cirrhosis including ascites or hepatosplenomegaly were identified on exam. LFTs on admission revealed elevated total bilirubin of 6.8 mg/dL with a direct bilirubin of 4.3 mg/dL, and aspartate transaminase and alanine aminotransferase were 273 and 198 U/L, respectively. The remainder of the LFTs, international normalized ratio, and complete blood count were within normal range. Work up for autoimmune (antinuclear, antismooth muscle, antimitochondrial, and anti-liver-kidney microsome antibodies), viral (hepatitis A, B, and E), and metabolic (ceruloplasmin, iron studies) causes of liver disease were all negative. Liver ultrasound and magnetic resonance cholangiopancreatography revealed hepatic steatosis and diffuse gallbladder wall thickening and edema without biliary dilation or cholelithiasis. A list of the patient's current medications was reviewed and no hepatotoxic drugs were identified. Surgical consultation was sought and acute acalculous cholecystitis was also ruled out.

Based on the temporal association of initiation of antiviral therapy for chronic HCV, a diagnosis of acute liver injury secondary to glecaprevir/pibrentasvir was concluded. Glecaprevir/pibrentasvir was discontinued and LFTs peaked 2 days later with rapid subsequent improvement. The pattern of improvement in LFTs is demonstrated in **Fig. 1**. On follow-up, 1 week after holding glecaprevir/pibrentasvir, LFTs had completely improved. HCV polymerase chain reaction (PCR) was shown to have improved from 139,268 copies/mL (reference range < 25) prior to initiation of glecaprevir/pibrentasvir to 425 copies/mL. We plan to monitor HCV PCR and consider alternate antiviral therapy including sofosbuvir/velpatasvir.

Discussion

We presented a rare case of acute liver injury secondary to glecaprevir/pibrentasvir in a patient with HCV infection without cirrhosis. Acute liver injury due to the use of glecaprevir/pibrentasvir was concluded by the temporal association of drug initiation and subsequent rise in LFTs. It is further supported by improvement in LFTs shortly after discontinuation of glecaprevir/pibrentasvir. The Naranjo Probability Scale for Adverse Drug Events was used to estimate the probability that a drug was the cause of the acute liver injury.⁴ A score of 7 was calculated, consistent with a probable adverse drug reaction. This indicates that the reaction followed a reasonable recognized response to the suspected drug, was confirmed by withdrawal but not by exposure to the drug and could not be reasonably explained by the known characteristics of the patient's clinical state.

The introduction of protease inhibitors such as glecaprevir/pibrentasvir brought a more favorable safety profile with primary biliary-fecal excretion.⁵ This combination carries a risk of HBV reactivation without concomitant HBV antiviral therapy and is contraindicated in patients with Child-Turcotte-Pugh B or C decompensated cirrhosis, prior history of hepatic decompensation, or use of atazanavir or rifampin.⁶ Previous literature describes a case of liver injury due to glecaprevir/pibrentasvir by Hammami et al in a patient with the absence of cirrhosis who developed acute liver injury that completely resolved after withdrawal of glecaprevir/pibrentasvir.⁷ Hara et al describe a second case

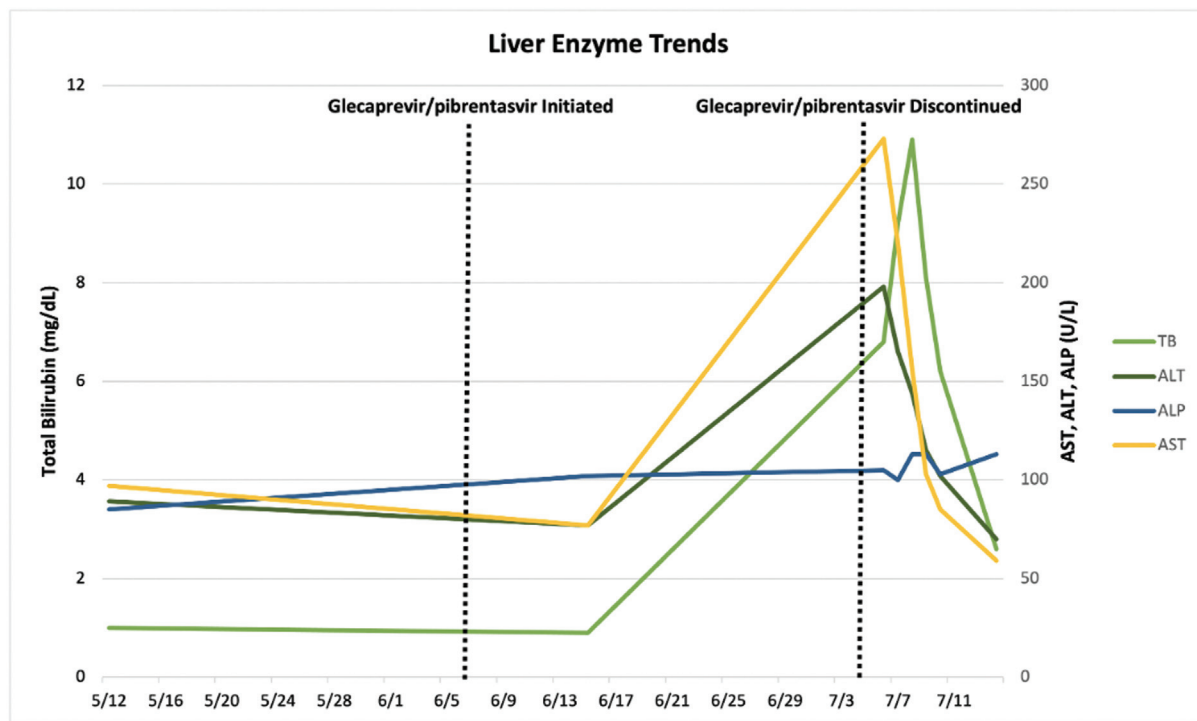


Fig. 1 Temporal correlation of initiation and discontinuation of glecaprevir/pibrentasvir on liver function tests (LFTs) in a patient with chronic hepatitis C infection.

of acute liver injury with development of hepatic encephalopathy in a patient with concomitant inactive HBV coinfection 6 weeks after glecaprevir/pibrentasvir initiation that later resolved with discontinuation of therapy.⁸ The mechanism of liver injury in the absence of cirrhosis with glecaprevir/pibrentasvir is unknown. As glecaprevir is largely metabolized by the liver, there may be an increased risk of potential drug–drug interactions and subsequent liver injury. The production of toxic or immunogenic metabolites is one proposed source of injury.⁹

This case report highlights a probable adverse drug reaction causing acute liver injury in a patient with chronic HCV due to glecaprevir/pibrentasvir. Our findings endorse the need to remain vigilant for the risk of liver injury after initiation of glecaprevir/pibrentasvir even without a diagnosis of cirrhosis. When glecaprevir/pibrentasvir-associated liver injury is identified, cessation of therapy has shown to lead to subsequent improvement in LFTs within weeks,^{3,7} as in our case. We emphasize monitoring patient symptoms and LFTs while on glecaprevir/pibrentasvir for chronic HCV infection, regardless of the status of preexisting liver cirrhosis.

Note

Informed consent was obtained for this case report.

Authors' Contributions

A.J. and K.M. wrote the manuscript. K.M. is the article guarantor.

Funding

None.

Conflict of Interest

None declared.

References

- Müllhaupt B, Semela D, Ruckstuhl L, et al. Real-world effectiveness and safety of glecaprevir/pibrentasvir therapy in patients with chronic hepatitis C virus infection in Switzerland. *Swiss Med Wkly* 2021;151:w20399
- FDA warns about rare occurrence of serious liver injury with use of hepatitis C medicines Mavyret, Zepatier, and Vosevi in some patients with advanced liver disease. U.S. Food and Drug Administration; 2019
- Yoon JH, Kim SM, Kang G, Kim HJ, Jun CH, Choi SK. A case report of glecaprevir/pibrentasvir-induced severe hyperbilirubinemia in a patient with compensated liver cirrhosis. *Medicine (Baltimore)* 2019;98(39):e17343
- Naranjo CA, Busto U, Sellers EM, et al. A method for estimating the probability of adverse drug reactions. *Clin Pharmacol Ther* 1981; 30(02):239–245
- Highlights of Prescribing Information. FDA 2017. Available at: https://www.accessdata.fda.gov/drugsatfda_docs/label/2017/208434s003lbl.pdf
- European Association for the Study of the Liver. Electronic address: easloffice@easloffice.eu Clinical Practice Guidelines Panel: Chair EASL Governing Board representative Panel members. EASL recommendations on treatment of hepatitis C: final update of the series*. *J Hepatol* 2020;73(05):1170–1218
- Hammami MB, Aboushaar R, Alsabbagh E. Glecaprevir/pibrentasvir-associated acute liver injury in non-cirrhotic, chronic HCV infection without HBV co-infection. *BMJ Case Rep* 2019;12(05):e226622
- Hara T, Ohara T, Taniguchi M, et al. Severe liver injury associated with glecaprevir plus pibrentasvir therapy in a patient with treatment-naïve hepatitis C virus infection. *Intern Med* 2021;60(15):2437–2443
- Mavyret, in *LiverTox: Clinical and Research Information on Drug-Induced Liver Injury*. Bethesda, MD: National Institute of Diabetes and Digestive and Kidney Diseases; 2012