



Isolated Rectal Metastases from Locally Advanced Carcinoma Prostate Detected by ^{18}F -PSMA-1007 PET/CT

Shashank Shekhar Singh¹ Rani Kunti Randhir Singh¹ Narvesh Kumar¹ Harshvardhan Atrey²

¹Department of Nuclear Medicine, Apollomedics Hospital, Lucknow, Uttar Pradesh, India

²Department of Medical Oncology, Apollomedics Hospital, Lucknow, Uttar Pradesh, India

Address for correspondence Shashank Shekhar Singh, DNB, Department of Nuclear Medicine, Apollomedics Hospital, Lucknow, 226012, Uttar Pradesh, India (e-mail: rahul.sin880@gmail.com).

World J Nuclear Med 2022;21:248–250.

Abstract

Keywords

- carcinoma prostate
- rectal metastases
- ^{18}F -PSMA-1007 PET/CT

Rectal involvement by prostate carcinoma is rare and isolated rectal metastases are even rarer with only a few cases having been reported in the literature. In our knowledge, no case of isolated rectal metastases diagnosed on prostate specific membrane antigen positron emission tomography/computed tomography has been reported to date. We present a case of a 66-year-old patient who presented with rectal bleeding and passage of urine from anal region and was diagnosed with carcinoma prostate infiltrating the rectum along with solitary rectal metastases.

Introduction

Rectal metastases in prostate cancer are rare. Most patients with rectal involvement show rectal involvement by direct extension of the primary cancer. Isolated metastases to rectum that is noncontiguous with the primary tumor are rare. Isolated rectal metastases have diagnostic as well as prognostic implications. Isolated rectal metastases should be differentiated from primary rectal carcinoma. Also, whether isolated rectal metastases confer poor prognosis is debatable.

Case History

A 66-year-old male presented with complaints of bleeding per rectum, dysuria, retention of urine, and passage of urine from anal region. Cystoscopy and biopsy revealed adenocarcinoma prostate (Gleason score 4 + 4) following which patient underwent transurethral resection of prostate and suprapubic cystostomy. Fluorine-18 prostate specific mem-

brane antigen (^{18}F -PSMA-1007) positron emission tomography/computed tomography (PET/CT) was done for staging. The whole body ^{18}F -PSMA-1007 PET/CT (►Fig. 1A) shows multiple foci of abnormal tracer uptake in the pelvis and abdomen. The cross-sectional fused PET/CT and contrast-enhanced computed tomography (CECT) images showed increased uptake of radiotracer in primary tumor in residual prostate gland infiltrating the neck of urinary bladder, rectum, levator ani, and obturator muscles along with pelvic lymphadenopathy (►Fig. 1B, C). An isolated PSMA avid enhancing nodule was also noted in the mucosal aspect of anterolateral wall of rectum away from the primary lesion (►Fig. 1D–G).

Patient received six cycles of docetaxel-based chemotherapy along with androgen deprivation treatment. The maximum intensity projection image of whole body ^{18}F -PSMA-1007 PET/CT post six cycles of chemotherapy (►Fig. 2A) shows persistent radiotracer uptake in the primary and pre-existing metastatic sites in pelvis along with new foci of PSMA uptake.

DOI <https://doi.org/10.1055/s-0042-1750440>.
ISSN 1450-1147.

© 2022. World Association of Radiopharmaceutical and Molecular Therapy (WARMTH). All rights reserved.

This is an open access article published by Thieme under the terms of the Creative Commons Attribution-NonDerivative-NonCommercial-License, permitting copying and reproduction so long as the original work is given appropriate credit. Contents may not be used for commercial purposes, or adapted, remixed, transformed or built upon. (<https://creativecommons.org/licenses/by-nc-nd/4.0/>)

Thieme Medical and Scientific Publishers Pvt. Ltd., A-12, 2nd Floor, Sector 2, Noida-201301 UP, India

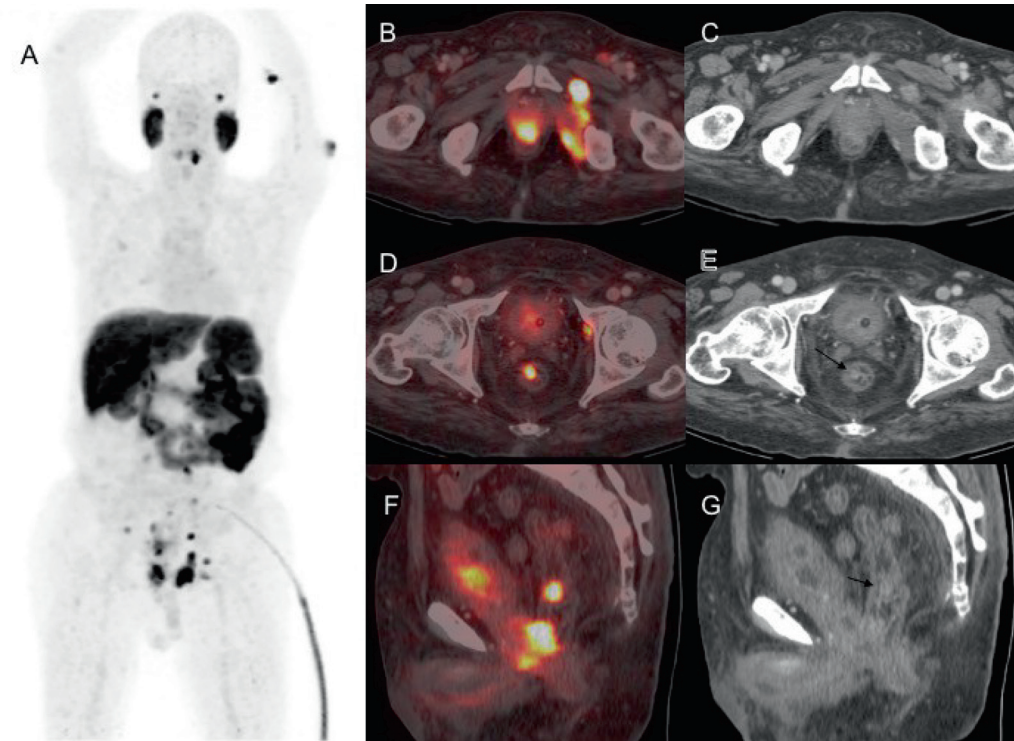


Fig. 1 The maximum intensity projection image of whole-body Fluorine-18 prostate specific membrane antigen positron emission tomography/computed tomography (¹⁸F-PSMA-1007 PET/CT) (A) shows multiple foci of abnormal tracer uptake in the pelvis and abdomen. The transaxial fused PET/CT and contrast-enhanced computed tomography images showed increased uptake of radiotracer in primary tumor in prostate infiltrating the neck of urinary bladder, rectum, levator ani, and obturator muscles along with pelvic lymphadenopathy (B, C). An isolated PSMA avid enhancing nodule was also noted in the mucosal aspect of anterolateral wall of rectum away from the primary lesion in transaxial (D, E; black arrows) and sagittal (F, G; black arrows) sections.

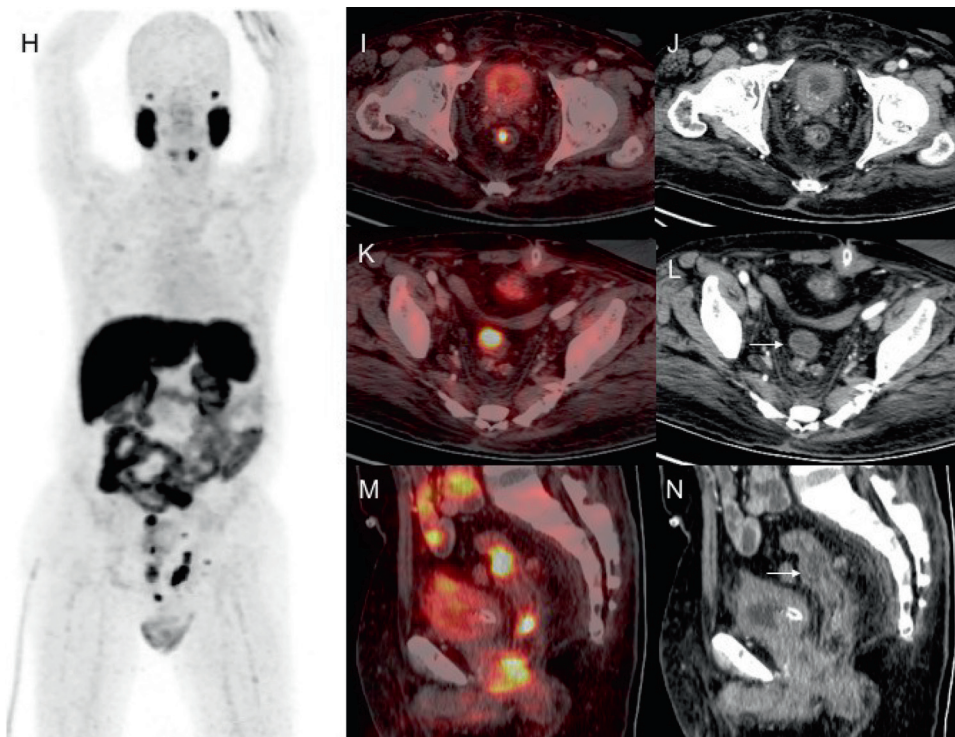


Fig. 2 The maximum intensity projection image of whole-body fluorine-18 prostate specific membrane antigen positron emission tomography/computed tomography (¹⁸F-PSMA-1007 PET/CT) post six cycles of chemotherapy (A) shows persistent radiotracer uptake in the primary and pre-existing metastatic sites in pelvis along with new foci of PSMA uptake. The transaxial fused PET/CT and contrast-enhanced computed tomography images showed persistent uptake of radiotracer in the previously documented nodular deposit in rectum (B, C). A new PSMA avid hypodense lesion was visualized in the anterior wall of rectum on transaxial (D, E; white arrows) and sagittal (F, G; white arrows) sections.

The transaxial fused PET/CT and CECT images showed persistent uptake of radiotracer in the previously documented nodular deposit in rectum (→Fig. 2B, C). A new PSMA avid hypodense lesion was visualized in the anterior wall of rectum (→Fig. 2D–G).

Discussion

Rectum is one of the least commonly involved site by prostate cancer by direct invasion or metastasis despite its close proximity to the prostate gland with few cases reported in the literature.^{1–3} This has been attributed to rectoprostatic (Denonvilliers') fascia between the prostate and anterior rectal wall, which works as a critical barrier to local extension of tumor.⁴ The possible reasons for rectal involvement may be related to tumor de-differentiation, positive surgical margins, or collision tumor in the very rare situation. Solitary metastasis to rectum by carcinoma prostate is even rare and it may be due to shared common lymphatic drainage by prostate and rectum or by tumor seeding while performing a needle biopsy of the prostate.⁵ Patients can present with abdominal pain, rectal bleeding, and fecal or urinary discharge from abnormal routes in cases of fistulous tract formation. Differentiating primary rectal cancer from rectal involvement by prostate cancer is essential since the treatment and prognosis of these two entities vary significantly.^{6,7} Although majority of prostate cancers with rectal involvement present with metastatic disease, rectal involvement by prostate cancer does not necessarily predict a worse outcome in hormone treatment naïve patients.⁸ However, prior hormone therapy and rectal bleed-

ing could be independent poor prognostic factors in prostate cancer patients with rectal involvement.

Funding

None.

Conflict of Interest

None declared.

References

- 1 Venara A, Thibaudeau E, Lebdaï S, et al. Rectal metastasis of prostate cancer: about a case. *J Clin Med Res* 2010;2(03):137–139
- 2 Morita T, Meguro N, Tomooka Y, et al. [Rectal metastasis of prostatic cancer causing annular stricture: a case report]. *Hinyokika Kyo* 1991;37(03):295–298
- 3 Nwankwo N, Mirrakhimov AE, Zdunek T, Bucher N. Prostate adenocarcinoma with a rectal metastasis. *BMJ Case Rep* 2013; 2013:bcr2013009503
- 4 Villers A, McNeal JE, Freiha FS, Boccon-Gibod L, Stamey TA. Invasion of Denonvilliers' fascia in radical prostatectomy specimens. *J Urol* 1993;149(04):793–798
- 5 Vaghefi H, Magi-Galluzzi C, Klein EA. Local recurrence of prostate cancer in rectal submucosa after transrectal needle biopsy and radical prostatectomy. *Urology* 2005;66(04):881–e7
- 6 Yoon G, Han MH, Seo AN. Rectal invasion by prostatic adenocarcinoma that was initially diagnosed in a rectal polyp on colonoscopy. *J Pathol Transl Med* 2019;53(04):266–269
- 7 Dulskas A, Cereska V, Zurauskas E, Stratilatovas E, Jankevicius F. Prostate cancer solitary metastasis to anal canal: case report and review of literature. *BMC Cancer* 2019;19(01):374
- 8 Wang H, Yao Y, Li B. Factors associated with the survival of prostate cancer patients with rectal involvement. *Diagn Pathol* 2014;9(01):35