



# Inguinal Lymphadenopathy: A Rare Initial Site of Metastatic Lung Carcinoma

Abhishek Mahato<sup>1</sup> Gaurav P.S. Gahlot<sup>2</sup> Deepak Kumar Jha<sup>3</sup> Rajhans<sup>4</sup>

<sup>1</sup>Department of Nuclear Medicine and PET/CT, Command Hospital Lucknow, Lucknow Cantonment, Uttar Pradesh, India

<sup>2</sup>Department of Oncopathology, Command Hospital Chandimandir, Panchkula, Haryana, India

<sup>3</sup>Department of Nuclear Medicine and PET/CT, Army Hospital R&R, New Delhi, Delhi, India

<sup>4</sup>Department of Radiation Oncology, Army Hospital R&R, New Delhi, Delhi, India

Address for correspondence Abhishek Mahato, DNB, Department of Nuclear Medicine and PET/CT, Command Hospital Lucknow, Lucknow Cantonment, 226002, Uttar Pradesh, India (e-mail: dr.abhi22ndleo@gmail.com).

World J Nuclear Med 2022;21:334–337.

## Abstract

Solid-organ tumors involving inguinal lymph nodes commonly originate from genitourinary tract, skin, ano-rectum, or the urinary bladder. Thus, solitary metastatic involvement of inguinal lymph nodes from extra-abdominal primary malignancies is extremely rare. However, involvement of nonregional lymph nodes upstages the disease to M1b with poor prognosis. Identification of the site of metastases is extremely crucial for deciding the management of patients.

This is the first ever case reported of de-novo or synchronous oligometastatic disease of carcinoma lung with inguinal lymph node involvement. In addition, it highlights the importance of <sup>18</sup>F-FDG PET-CT to diagnose the involvement of inguinal lymph node that was further proved on fine needle aspiration cytology. Only two such cases of lung cancer have been reported, but both of them had inguinal lymph node during the follow-up and none was present at initial presentation.

## Keywords

- ▶ inguinal metastases
- ▶ carcinoma lung
- ▶ oligometastasis
- ▶ FDG PET-CT

## Case Presentation

A 59-year-old male presented with weight loss and chronic productive cough in the last 6 months. The patient was a chronic smoker for 40 years, using 50 bidis (tobacco wrapped in tendu or temburni leaf and hand-rolled) per month. Radiograph of the chest revealed an opacity in the right upper zone extending till the mediastinum. Clinical differentials of lung carcinoma and pulmonary tuberculosis were considered. On further evaluation, the patient had microcytic hypochromic anemia with a hemoglobin of 9.1 g/dL, while liver function and kidney function tests were preserved for

his age. Negative results of Mantoux test and *Mycobacterium tuberculosis* polymerase chain reaction excluded pulmonary tuberculosis.

The computed tomography (CT) of the chest revealed a large, soft tissue density mass lesion involving the anterior segment of right upper lobe. The lesion was abutting the costal pleura along the right third–sixth rib posteriorly with mediastinal infiltration on the medial side; however, no obvious pleural/chest wall infiltration was appreciable. CT scan findings were suggestive of a neoplastic etiology likely carcinoma lung stage—T4N2M0. CT-guided biopsy was performed and based on histopathological and

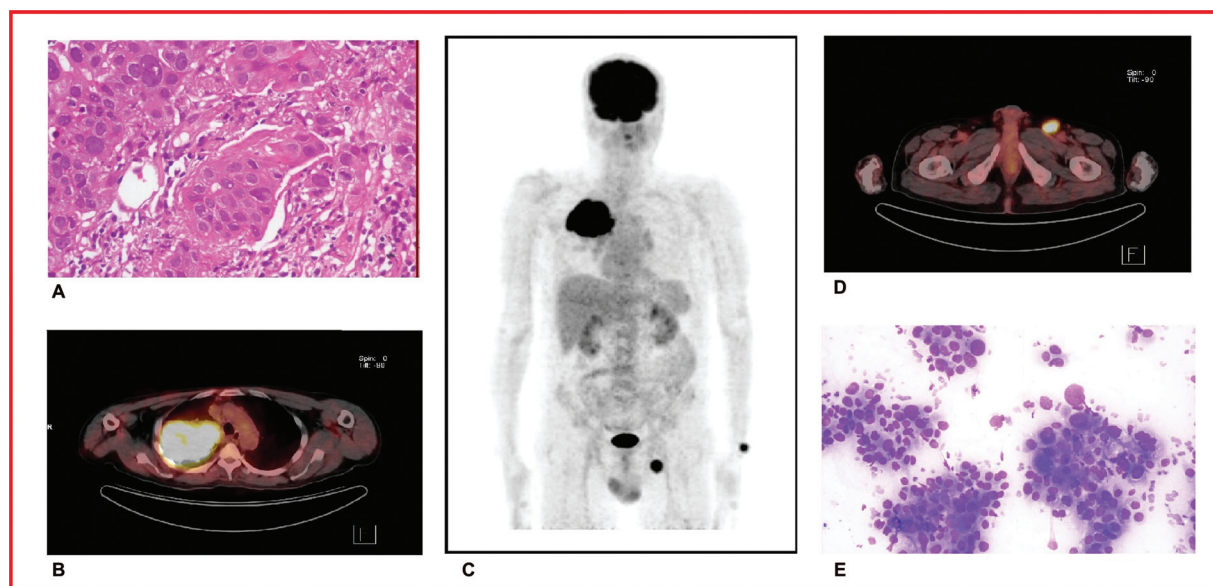
published online  
September 8, 2022

DOI <https://doi.org/10.1055/s-0042-1750397>.  
ISSN 1450-1147.

© 2022. World Association of Radiopharmaceutical and Molecular Therapy (WARMTH). All rights reserved.

This is an open access article published by Thieme under the terms of the Creative Commons Attribution-NonDerivative-NonCommercial-License, permitting copying and reproduction so long as the original work is given appropriate credit. Contents may not be used for commercial purposes, or adapted, remixed, transformed or built upon. (<https://creativecommons.org/licenses/by-nc-nd/4.0/>)

Thieme Medical and Scientific Publishers Pvt. Ltd., A-12, 2nd Floor, Sector 2, Noida-201301 UP, India



**Fig. 1** (A) 400× H&E-stained sections showed tumor cells arranged in nests, islands, and singly scattered patterns. The individual tumor cells show well-defined cell borders with moderate eosinophilic cytoplasm squamoid morphology with polygonal shape, round to oval hyperchromatic nuclei, mild to moderate nuclear polymorphism, and prominent nucleoli. (B) Axial section of FDG PET-CT at the level of mid-thorax showing FDG-avid mass in right lung invading the mediastinum. (C) Maximum intensity projection (MIP) images of FDG PET-CT showing FDG-avid right lung mass and left inguinal lymphadenopathy. (D) Axial section of FDG PET-CT at the level of upper thigh depicting intense FDG avid left inguinal lymph node. (E) 200× FNAC of left inguinal lymph node was performed with LG (Leishman–Giemsa) stain. FNAC smears showed tumor cells arranged in small sheets, clusters, and singly scattered pattern. The individual tumor cells have round to oval nuclei and moderate to marked nuclear polymorphism. FNAC, fine needle aspiration cytology.

immunohistochemical findings a final diagnosis of squamous cell carcinoma lung was made (→ Fig. 1A).

As a part of routine protocol, whole body  $^{18}\text{F}$ -FDG PET-CT (fluoro deoxy glucose positron emission tomography-computed tomography) scan from base of skull to mid-thigh was performed with Siemens Symbia T6 after 45 minutes after intravenous injection of 370MBq of  $^{18}\text{F}$ -FDG. CT images were acquired by a whole-body full-ring dedicated lutetium oxyorthosilicate PET/CT scanner using 130 KV and 90 mAs<sup>-1</sup> without administration of intravenous or oral contrast. Images were reconstructed using standard iterative algorithm—Ordered Subset Expectation Maximization (OSEM)—and reformatted into transaxial, coronal, and sagittal views. The FDG-avid findings of PET-CT scan were in consistency with the findings of CT chest (→ Fig. 1B, C); however, PET-CT also showed an intense FDG-avid focus in an enlarged left inguinal lymph node (→ Fig. 1C, D). No other abnormal FDG-avid focus was noted in the contralateral lung, liver, adrenals, or axial and appendicular skeleton, and in the abdominopelvic region. Therefore, in the absence of abnormal FDG avidity elsewhere in the scanned region of the body ruling out a second primary, a diagnosis of carcinoma lung with left inguinal lymph nodal metastases was concluded.

Based on PET-CT findings, fine needle aspiration cytology of the lymph node was performed, revealing metastatic deposits of poorly differentiated carcinoma (→ Fig. 1E). Since solitary involvement of inguinal lymph nodes from carcinoma lung is an extremely uncommon finding, search for a second primary was considered. Relevant physical examination of ano-rectum, penis, and lower limb was performed; contrast-enhanced CT of the abdomen and pelvis did not

reveal any abnormality. This case was discussed in the tumor board of the hospital as a case of carcinoma lung with oligometastatic involvement of left inguinal lymph nodes—stage T4N2M1b. The tumor board was of divided opinion on the line of management shuffling between curative intent and palliative care. Although the final decision shifted toward a palliative care, a significant majority were for curative intent based on the newer concept of oligometastatic disease. The patient was started on palliative chemo-radiotherapy; however, despite limited tumor burden the patient succumbed to his illness within a year of initiation of treatment.

## Discussion

Lung cancer is the most commonly diagnosed cancer in males and the leading cause of cancer death.<sup>1</sup> Lung carcinoma is broadly divided into two main categories, that is, non-small cell lung carcinoma (NSCLC; 80–85%) and small cell lung carcinoma (SCLC; 15%). In total, 30 to 40% of NSCLC patients have metastatic disease to contralateral lungs, brain, liver, and adrenal glands at the time of diagnosis.<sup>2,3</sup> Tamura et al noted that among the consecutive 1,542 NSCLC patients, 47.3% of all cases presented with distant metastasis to bone (34.3%), lung (32.1%), brain (28.4%), adrenal gland (16.7%), liver (13.4%), and extrathoracic lymph node (9.5%) sites, respectively.<sup>4</sup>

Metastasis of NSCLC to inguinal lymph nodes is extremely rare and solid-organ tumors involving inguinal lymph nodes commonly originate from genitourinary tract, skin, ano-rectum, or urinary bladder.<sup>5</sup> While surgery is preferred for NSCLC in initial stages, metastatic cases of NSCLC are

**Table 1** A comparative feature of the three cases of NSCLC with inguinal lymph node metastases cited in the English literature

Parameters	Kocak et al <sup>10</sup>	Grandić et al <sup>11</sup>	Present case
Age (y)	58	67	59
Gender	Male	Male	Male
Lung affected	Right perihilar	Right perihilar	Right upper lobe mass with hilar involvement
NSCLC type	Squamous cell carcinoma	Squamous cell carcinoma	Squamous cell carcinoma
CT chest staging	T4N2M0	T3N2M0	T4N2M0
<sup>18</sup> F-FDG PET-CT	Not performed	Not performed	T4N2M1b
Inguinal lymph node affected	Right	Bilateral inguinal lymph node	Left
Time line in which inguinal lymph node was found	5 months after diagnosis and treatment	After few months of treatment	Initial staging
Other site of metastases reported	Nil	Liver and lumbosacral spine after few months of treatment	Nil
Overall survival	1 y (approx.)	1 y (approx.)	9 mo

managed with palliative chemo-radiotherapy.<sup>6,7</sup> Such patients have a 5-year survival chance of less than 5% despite chemo and radiation therapy.<sup>8,9</sup>

Our extensive literature search could find only five cases of solid-organ tumor involving inguinal lymph nodes that have been reported ante-mortem in the English literature with primary being lung cancer, malignant mesothelioma, and salivary duct and breast carcinoma.<sup>10</sup> Only two articles cited involvement of inguinal lymph nodes from primary lung cancer. One by Grandić et al who reported inguinal lymph node metastases as the first sign of disease relapse following remission of primary lung cancer.<sup>11</sup> Second case report is by Kocak et al who observed inguinal lymph node as the only evidence of progressive lung cancer.<sup>10</sup> ▶ **Table 1** compares the three reported cases of inguinal lymph nodal metastases in lung cancer.

The inclusion of the term “oligometastatic disease” by the International Association for the Study of Lung Cancer in its eighth edition signifies the paradigm shift happening in the management of lung cancer. The classification divides patients into three distinct categories based on the prognosis: stage M1a: involvement of the lung alone; M1b: single extrathoracic metastasis; and M1c: multiple extrathoracic metastases in one or more organs.<sup>12</sup>

First described by Hellman and Weichselbaum in 1995, oligometastasis refers to a clinical stage in which patients present a limited number of metastases to a few sites (a single organ or a few organs).<sup>13,14</sup> These patients have a better prognosis than patients presenting with multiple metastases. The oligometastatic group represents 20 to 50% of patients with NSCLC depending upon the specific definition and time of presentation.<sup>15</sup>

We hereby report the first ever case of synchronous oligometastatic carcinoma lung with solitary involvement of left inguinal lymph node. The case highlights the advantage FDG PET-CT has over traditional imaging modalities in

delineating the oligometastatic subgroup of patients. Although the patient was managed with palliative treatment, a substantial majority in the hospital tumor board were of the opinion to enroll and treat the patient as oligometastatic disease with a curative intent. However, the final decision taken was of palliative management due to lack of experience in managing oligometastatic disease and also of definite guidelines which are still in phase II trials. The rapid progression of the disease with no response to the palliative line of care suggests adaptation of the new paradigm shift with informed patient consent and enrolment into clinical trials.

## Conclusion

The index case showcases one of the rare presentations of carcinoma lung. Based on our extensive literature search, we claim this to be the first ever case reported of a de-novo or synchronous oligometastatic disease of carcinoma lung with inguinal lymph node involvement.

The case emphasizes the critical role played by <sup>18</sup>F-FDG PET-CT as an essential work-up tool for metastatic work-up of malignancies. FDG PET-CT was the decisive imaging modality in this case. The article also points out that special emphasis should be given to any suspicious abnormal FDG-avid focus on a PET-CT scan. In absence of the FDG PET-CT, the metastatic disease would have been missed. In fact, since the other two case reports had the disadvantage of not having FDG PET, therefore the possibility of inguinal metastases at the initial presentation cannot be excluded in them.

As per latest American Joint Committee on Cancer guidelines, involvement of nonregional lymph nodes upstages the disease to stage M1b. Such patients have a 5-year survival chance of less than 5% despite chemo and radiation therapy.<sup>8,9</sup> With the concept of oligometastatic disease, such patient population should be admitted into a trial of curative management rather than subjecting them to palliative care.

**Conflict of Interest**

None.

**References**

- 1 World Health Organization. Accessed at: <https://www.who.int/news-room/fact-sheets/detail/cancer>
- 2 Matsuda A, Matsuda T, Shibata A, Katanoda K, Sobue T, Nishimoto H. Japan Cancer Surveillance Research Group. Cancer incidence and incidence rates in Japan in 2008: a study of 25 population-based cancer registries for the Monitoring of Cancer Incidence in Japan (MCIJ) project. *Jpn J Clin Oncol* 2014;44(04):388–396
- 3 Little AG, Gay EG, Gaspar LE, Stewart AK. National survey of non-small cell lung cancer in the United States: epidemiology, pathology and patterns of care. *Lung Cancer* 2007;57(03):253–260
- 4 Tamura T, Kurishima K, Nakazawa K, et al. Specific organ metastases and survival in metastatic non-small-cell lung cancer. *Mol Clin Oncol* 2015;3(01):217–221
- 5 Kaya C, Tanrikulu H, Yilmaz G, Aker F, Karaman MI. Spermatic cord metastasis as an initial manifestation of non-small cell carcinoma of the lung. *Int J Urol* 2006;13(06):846–848
- 6 Kalemkerian GP, Pass HI. Lung cancer: present concepts in the molecular biology of lung cancer. In: Shields TW, Locicero J, Ponn RB, eds. *General Thoracic Surgery*, 5th ed. Philadelphia, PA: Lippincott Williams & Wilkins; 2000:1235–1268
- 7 Nesbitt JC, Putnam JB Jr, Walsh GL, Roth JA, Mountain CF. Survival in early-stage non-small cell lung cancer. *Ann Thorac Surg* 1995;60(02):466–472
- 8 Ota T, Shinohara M, Tanaka M, et al. Spermatic cord metastases from gastric cancer with elevation of serum hCG-beta: a case report. *Jpn J Clin Oncol* 2000;30(05):239–240
- 9 U.S. National Institute Of Health, National Cancer Institute. *Seer cancer statistics review, 1975–2015*.
- 10 Kocak Z, Saynak M, Oz-Puyan F, et al. Inguinal lymph node as the only evidence of progressive lung cancer. *Rev Port Pneumol* 2008;14(05):709–713
- 11 Grandić L, Pogorelić Z, Banović J, Forempoher G, Ilić N, Perko Z. Atypical non-small cell lung cancer presentation: inguinal lymph node metastases as the first sign of disease relapse. *Acta Clin Croat* 2010;49(04):441–444
- 12 Eberhardt WE, Mitchell A, Crowley J, et al; Rami-Porta R International Association for Study of Lung Cancer Staging and Prognostic Factors Committee, Advisory Board Members, and Participating Institutions. The IASLC Lung Cancer Staging Project: proposals for the revision of the M descriptors in the forthcoming eighth edition of the TNM classification of lung cancer. *J Thorac Oncol* 2015;10(11):1515–1522
- 13 Hellman S, Weichselbaum RR. Oligometastases. *J Clin Oncol* 1995;13(01):8–10
- 14 Bergsma DP, Salama JK, Singh DP, Chmura SJ, Milano MT. Radiotherapy for oligometastatic lung cancer. *Front Oncol* 2017;7:210
- 15 Couñago F, Luna J, Guerrero LL, et al. Management of oligometastatic non-small cell lung cancer patients: current controversies and future directions. *World J Clin Oncol* 2019;10(10):318–339