



# An Innovative Method of Securing the Endotracheal Tube in Patients with Facial Hair Undergoing Neurosurgical Procedures

Ravindra Singh<sup>1</sup> Manbir Kaur<sup>1</sup> Kamlesh Kumari<sup>1</sup> Swati Chhabra<sup>1</sup> Darshana Rathod<sup>1</sup>  
Jaskaran Singh Gosal<sup>1</sup>

<sup>1</sup>Department of Anesthesia and Critical Care and Neurosurgery, All India Institute of Medical Sciences (AIIMS), Jodhpur, Rajasthan, India

AJNS 2022;17:392–393.

Address for correspondence Kamlesh Kumari, MD, DNB, Department of Anesthesia and Critical Care, All India Institute of Medical Sciences (AIIMS), Jodhpur, 342005, Rajasthan, India (e-mail: kamlesh.gmch@gmail.com).

Securing the endotracheal tube (ETT) is one of the most crucial steps in airway management. Accidental extubation can lead to catastrophic events, especially in head and neck surgeries, when airway access is difficult intraoperatively.<sup>1</sup> Providing anesthesia to the patients with facial hair or beard is always a challenge because, in addition to difficult mask ventilation, tube fixation is also tricky. Some people keep a beard because of religious beliefs, while others keep it as a symbol of fashion or respect, so they do not consent to shave. It becomes incredibly challenging for securing ETTs in bearded patients, posted for neurosurgical procedures, as the application of tapes or bandages around the neck to secure the ETT is generally avoided in these cases due to the risk of jugular venous compression (which may affect venous drainage from the head), causing raised intracranial pressure.<sup>2</sup> Moreover, a bandage around the neck is not suitable in patients undergoing posterior fossa or cervical spine surgery due to its interference with the operative field. Many different techniques have been mentioned in the literature to secure ETT in patients with a beard.<sup>2–5</sup> However, we describe a novel and simple approach to fix ETT in bearded patients.

A 53-year-old male patient diagnosed with the left temporoparietal space-occupying lesion was planned for left temporoparietal craniotomy and excision of the tumor in the lateral position under general anesthesia. The patient had a beard and was shifted to the operating room without shave because of personal reasons. After intubation and confirming bilateral equal air entry, the Tegaderm was first

applied over the patient's beard (→**Fig. 1A**). (Tegaderm which we are using in our patient is 3M Tegaderm HP surgical dressing. It consists of a thin film backing with a latex-free adhesive that gently, yet securely, adheres to the skin. These dressings are breathable, sterile, transparent, and waterproof, and provide a barrier to external contaminants. It has a special adhesive for greater holding power in the presence of moisture. Tegaderm consists of a thin polyurethane membrane coated with a layer of an acrylic adhesive. Its size is 10 cm × 12 cm.) After establishing its adhesiveness, two Dynaplast strips were rolled around the ETT, which were then fixed over the already well-placed Tegaderm (→**Fig. 1B**). The ETT remained in position throughout the surgery. At the end of the surgery, the Tegaderm was quickly removed by putting over a small amount of alcohol-based hand rub solution, which dissolves the adhesive bonds of the Tegaderm.

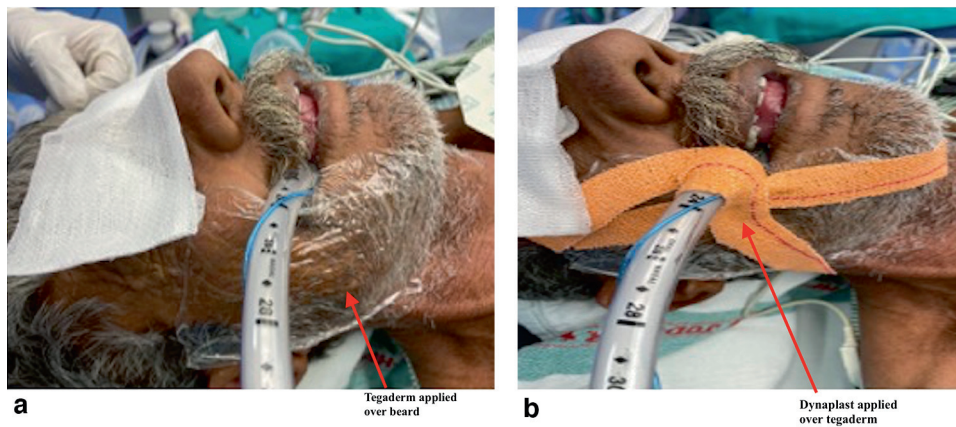
In patients with facial hair, various methods for ETT fixation have been described in the literature, such as adhesive tape, bandage, surgical suture, ETT holder, and a plastic hook, but each method has its limitations and cannot be used for all types of surgery and position.<sup>2–5</sup> Our technique is simple and an easy option for patients who refuse to cut their beards before the surgical procedures. The Tegaderm provides a good and firm ground for the fixation of the Dynaplast and holds the tube efficiently throughout the surgery, and its ease of removal further adds to its beneficial role in such patients. This technique

DOI <https://doi.org/10.1055/s-0042-1750383>.  
ISSN 2248-9614.

© 2022. Asian Congress of Neurological Surgeons. All rights reserved.

This is an open access article published by Thieme under the terms of the Creative Commons Attribution-NonDerivative-NonCommercial-License, permitting copying and reproduction so long as the original work is given appropriate credit. Contents may not be used for commercial purposes, or adapted, remixed, transformed or built upon. (<https://creativecommons.org/licenses/by-nc-nd/4.0/>)

Thieme Medical and Scientific Publishers Pvt. Ltd., A-12, 2nd Floor, Sector 2, Noida-201301 UP, India



**Fig. 1** (A) Application of Tegaderm over patient's facial hair. (B) Rolling of dynaplast strips around ETT followed by fixing over Tegaderm.

also has no risk of engorgement of neck veins. Though we have successfully used this ETT fixation method in few patients with facial hair undergoing neurosurgery in supine position, its use may be limited to the patients undergoing surgeries in prone position as well as for facial surgeries. We used this method of tube fixation in few cases in supine position and many more cases would be needed to confirm its safety for use both in supine and prone position.

We believe that this is a simple, readily available, and reliable technique to secure ETT in patients with a beard, without problems of taping around the neck and entrenching the surgical fields.

**Funding**  
None.

**Conflict of Interest**  
None declared.

#### Patient Consent

The patient has given permission and written consent to use images or other clinical information relating to his case to be reported in a medical publication.

#### References

- 1 Farbod F, Tuli P, Robertson BF, Jackson IT. Endotracheal tube fixation methods for optimal stability: a comparison of adhesive tape, suture, and tape-suture fixation. *J Craniofac Surg* 2010;21(04):1250–1251
- 2 Brahma R, Singla R, Pandia MP, Dube SK. Securing endotracheal tube in a bearded patient undergoing surgery for cerebellopontine angle tumor in lateral position—a different approach. *J Neurosurg Anesthesiol* 2020;32(03):280–281
- 3 Agarwal A, Singh DK, Dinesh C, Pradhan C. Nonconventional way of securing endotracheal tube in bearded individuals. *J Anaesthesiol Clin Pharmacol* 2011;27(03):425–426
- 4 Khorasani A, Bird DJ. Facial hair and securing the endotracheal tube: a new method. *Anesth Analg* 1996;83(04):886
- 5 Thakur S, Thakur JR. Endotracheal tube holder: an innovation. *J Anaesthesiol Clin Pharmacol* 2005;2(03):307–308