



Nonvenomous Snakebite in Pediatric Age Group—Wolf under a Sheep's Coat

Ranjit Kumar Sahu¹ Sourabh Shankar Chakraborty² Suresh K.³ Sourabh Gupta⁴

¹Department of Plastic Surgery, AIIMS, Bhubaneswar, Odisha, India

²Department of Plastic Surgery, South Eastern Railway Central Hospital, Kolkata, West Bengal, India

³Department of Plastic Surgery, GSL Medical College, Rajahmundry, Andhra Pradesh, India

⁴Department of Nephrology and Paediatric Nephrology, Max Hospital, Vaishali, Uttar Pradesh, India

Address for correspondence Sourabh Shankar Chakraborty, DNB, MCh, Department of Burns & Plastic Surgery, South Eastern Railway Central Hospital, Ground Floor, OPD Block, Kolkata 700043, West Bengal, India (e-mail: sourabh.chakraborty86@gmail.com).

Indian J Plast Surg 2022;55:299–301.

Abstract

Nonvenomous snakebite, far outnumbering venomous bites, is a neglected occupational hazard in the Indian subcontinent. We encountered four cases of traditionally nonvenomous snakebite in pediatric age group with symptoms of limb swelling proximal to the bite site. All cases were found to have extensive fibrinous exudate and fibrinoid necrosis of the deeper layer of fat, deep to the intact skin and superficial layer of fat, extending far from the wound toward the proximal limb in continuity. This obscured presentation of infection and extensive necrosis of only the deeper layer of fat warrants exploratory incisions proximally for thorough debridement, underlying the normal appearing skin.

Keywords

- ▶ snakebite
- ▶ nonpoisonous snake
- ▶ incision and drainage
- ▶ reconstruction
- ▶ fibrinoid necrosis

Introduction

Snakes belong to suborder of the order Squamata. India had the highest number of envenomations (81,000 per year) and the highest number of deaths due to snakebite (11,000 per year) in the world.¹ Epidemiological studies suggested that snakebite in the tropics is an occupational hazard for farmers, plantation workers, herders, and hunters.²

Although more common, nonvenomous snakebite has been given little relevance in literature. We encountered four cases of traditionally nonvenomous snakebite in pediatric age group with masked presentation.

Cases

All the four children were of age group 2 to 4 years. They presented to us 30 to 40 days after snakebite. Two were bitten by royal snake, the other two by beaded snake and common

sand boa, respectively (as per the parents' description). Three of them were bitten over foot and underwent local wound debridement initially for tissue necrosis, while the fourth child bitten on hand was conservatively managed outside. The latter also received polyvalent antsnake venom empirically. All the parents reported that after brief asymptomatic period, they developed mild swelling over the entire limb proximal to the bite site, with tenderness. After admission, it was observed that in two children white blood cell count was increased, while in other two it was within normal limits. Ultrasonography suggested no well-formed collection in leg and thigh, but fluid in interfascial/intermuscular planes was present. Local wound debridement along with incision and drainage of swellings of leg and thigh (for bite over foot) and hand and forearm (for finger bite) was done. Skin proximal to the bite was normal in color, turgidity, and texture. However, intraoperatively it was found that the deeper layer of fat was necrotic and in continuity (nonpatchy), extending from

published online
July 5, 2022

DOI <https://doi.org/10.1055/s-0042-1750376>.
ISSN 0970-0358.

© 2022. Association of Plastic Surgeons of India. All rights reserved. This is an open access article published by Thieme under the terms of the Creative Commons Attribution-NonDerivative-NonCommercial-License, permitting copying and reproduction so long as the original work is given appropriate credit. Contents may not be used for commercial purposes, or adapted, remixed, transformed or built upon. (<https://creativecommons.org/licenses/by-nc-nd/4.0/>)
Thieme Medical and Scientific Publishers Pvt. Ltd., A-12, 2nd Floor, Sector 2, Noida-201301 UP, India

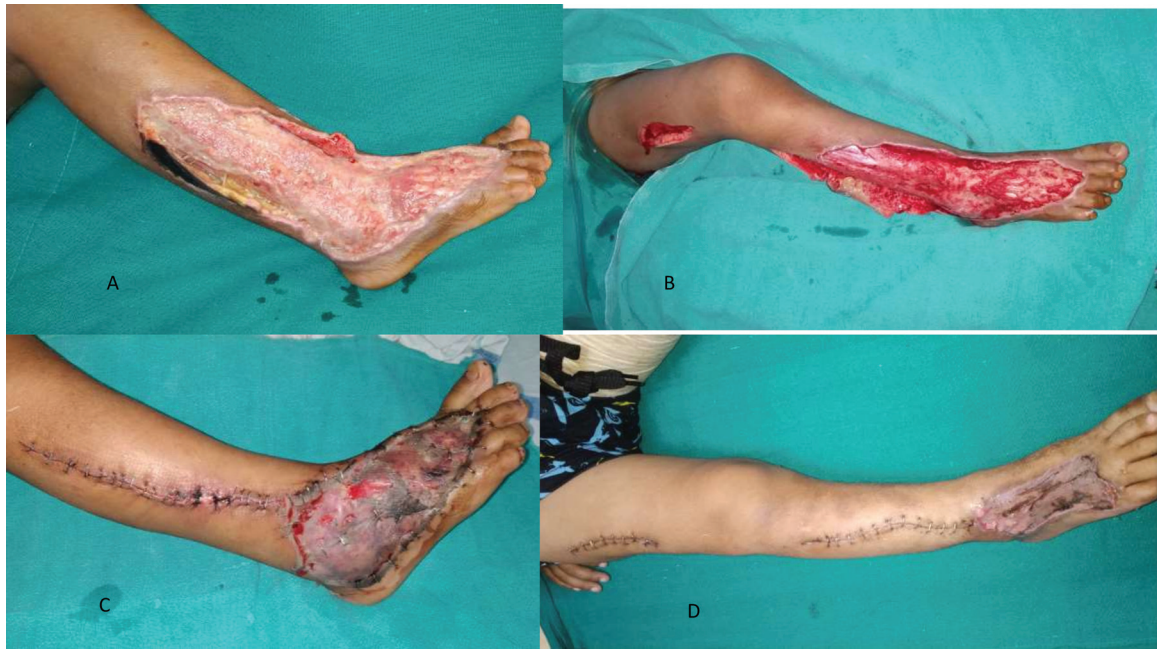

Fig. 1 (A) Leg wound at presentation. (B) Wound debridement and exploration of proximal necrosed deeper layer of fat of leg with overlying intact skin and superficial layer of fat. (C) Immediate postoperative, with primary closure of exploratory incision and skin grafting over wound. (D) 10 days postoperative after primary closure and satisfactory skin graft uptake.

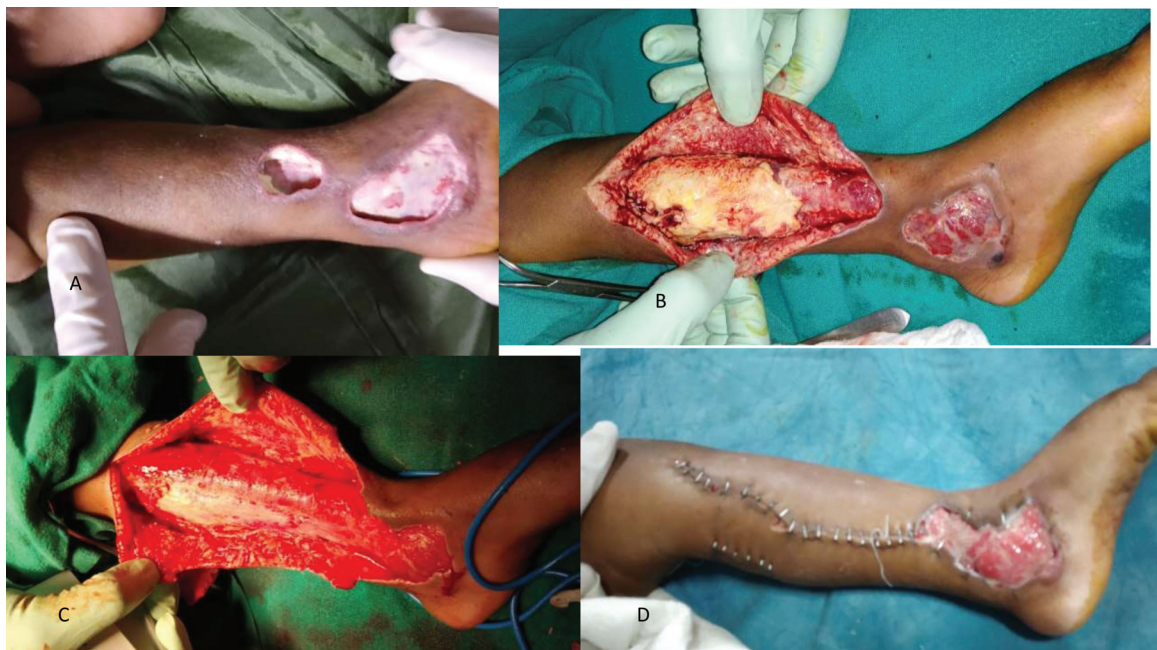


Fig. 2 (A) Preoperative wound over ankle. (B) Exploratory incision to expose necrosed deeper layer of fat. (C) Intact deep fascia post-debridement. (D) 10 days follow-up, with partial loss of skin graft.

ankle to proximal thigh (in foot bite cases), and hand to distal forearm (in finger bite case). Interestingly, the superficial layer of fat and skin was intact and normal, as also the deep fascia in all these four cases (—Figs. 1 and 2). Histopathology revealed dense fibrinoid necrosis of deeper adipose layer. This fibrofatty tissue had neutrophils, lymphocytes, and macrophages infiltrating into adipose tissue. Karyorrhexis with fibrinous exudate and fibrinoid necrosis was present. In one case culture was sterile, while in other three Enter-

obacter species were positive. One case was also positive for *Serratia marcescens*. Surgical incisions were closed immediately. Debrided wound was grafted with split-thickness graft. All the children responded well dramatically.

Discussion

More than 80% of snakebites are not evenenomated, namely when the bite is of a nonvenomous snake or when a

venomous snake fails to inject venom (dry bite).³ In India, percentage of nonvenomous snakebite ranges from 32 to 46%,⁴ in children it is 45%.⁵ Children, due to their low body surface area relative to the venom dose, are susceptible to more frequent complications in comparison to adults.

In children, pain (93.75%) and anxiety (87.5%) were the most common symptoms, among tingling sensation, swelling, bleeding, vomiting, and bleeding.⁶ Koirala et al found the most common clinical features were local swelling (77%) and local pain (74%).⁷ Local envenoming of snakebites leads to pain, edema, ecchymosis, blisters, and cellulitis. The proteolytic properties of snake venom result in extensive tissue necrosis. Suchithra et al found edema in 93%, skin necrosis in 40%, and blisters in 6% of their cases.⁸

The major complication with respect to nonvenomous snakebite is infection. Oral flora of the biting snake is directly reflected by the types of bacteria recovered from infected snakebite wounds. The most common organism isolated from wound infections secondary to snakebite was *Staphylococcus aureus*.⁹ Although serious systemic illnesses occur infrequently as a result of these infections, if neglected they may lead to sepsis, shock, and death. Abscess is the most common manifestation of infection in snakebite cases, and in a few instances has been suspected as one of the causes of death.

Surgical incision and drainage of abscesses are probably the most important procedures and may be effective even in the absence of other therapeutic measures. Fasciotomy should be discouraged unless compartment syndrome is suspected (intracompartmental pressure must be measured). Antibiotics are not indicated prophylactically in patients with nonvenomous snakebite, if there is no necrosis. In this case series, we observed that following nonpoisonous snakebite in pediatric age group, child developed very selective chronic inflammatory response with fibrinoid necrosis of deeper adipose layer only, which was even distant from the local bite site, although in continuity. So, the area of damage was more extensive than it was clinically evident. Cultures of fibrofatty tissue in one case were sterile, as against the other three cases, in which typical organisms of snake oral flora were detected. All of them responded very well after surgical drainage and immediate closure of the wound.

However, there were certain limitations. Snake species were not identified by herpetologists. None of the patients presented to us immediately following snakebite, so the

exact course of the local wound and surrounding tissues could not be ascertained. The exact cause of this peculiar delayed presentation could not be evaluated and hence warrants further investigations. The possibility of underlying immunodeficiency (B cell immunodeficiency) was not investigated as the children did not have any neutropenia. They were also not evaluated for phagocytic function defect and hypogammaglobinemia.

Conclusion

In cases of nonpoisonous snakebite in pediatric age group, we need to have high index of suspicion to inspect the sites distant from local bite site, for better prognosis and avoidance of long-term complications. An exploratory incision proximally to the bite site can be performed to reveal any masked infective or necrotic tissue, underlying the normal appearing skin.

Conflict of Interest

The authors declare that there is no conflict of interest.

References

- 1 Kasturiratne A, Wickremasinghe AR, de Silva N, et al. The global burden of snakebite: a literature analysis and modelling based on regional estimates of envenoming and deaths. *PLoS Med* 2008;5(11):e218
- 2 Reid HA. Snakebite in the tropics. *BMJ* 1968;3(5614):359–362
- 3 Russell FE. Snake Venom Poisoning. Philadelphia: JB Lippincott; 1980
- 4 Dalal I, Mandal P, Mahata R, Ghosh S, Ghosh B, Das R. Clinical and epidemiological profile of snake bite cases in a tertiary care medical college and hospital in Eastern India. *Saudi J Med Pharm Sci* 2017;3(05):408–413
- 5 Varahala AM, Dundigalla C, Subrahmanyam GVS, Amrutha PR. Clinical profile of envenomation in children with reference to snake bite. *IOSR J Dent Med Sci* 2015;14(11):12–18
- 6 Phirke DS, Nazparveen LA. Study of treatment strategies and outcome of snake bite in children at a tertiary care hospital. *Wjpmr*. 2017;3(11):128–130
- 7 Koirala DP, Gauchan E, Banset S, Adhikari S. Clinical features, management and outcome of snake bite in children in Manipal teaching hospital. *Nepal Journal of Medical Sciences* 2013;2(02): 119–124
- 8 Suchithra N, Pappachan JM, Sujathan P. Snakebite envenoming in Kerala, South India: clinical profile and factors involved in adverse outcomes. *Emerg Med J* 2008;25(04):200–204
- 9 Garg A, Sujatha S, Garg J, Acharya NS, Chandra Parija S. Wound infections secondary to snakebite. *J Infect Dev Ctries* 2009;3(03): 221–223