



Cleft Hand—Our Experience of Five Cases

Kuldeep Singh¹ Krittika Aggarwal¹ Meenu Beniwal¹

¹Department of Burns and Plastic Surgery, Pt. Bhagwat Dayal Sharma PGIMS, Rohtak, Haryana, India

Address for correspondence Krittika Aggarwal, MS, Mch, Dept of Burns and Plastic Surgery, Pt. Bhagwat Dayal Sharma PGIMS, Rohtak.124001, Haryana, India (e-mail: krittika.agga@gmail.com).

Indian J Plast Surg 2022;55:302–306.

Abstract

Introduction Hand helps us perform our work and express ourselves. Cleft hand is an aesthetic deformity rather than functional. We document our experience in five such cases from the ages of 3 to 5 years who underwent reconstruction under general anesthesia.

Materials and Methods Three patients underwent Snow–Littler procedure, one underwent osteotomy for angled metacarpal and transverse metacarpal ligament reconstruction, and one underwent removal of transverse bone and transverse metacarpal ligament reconstruction. Splintage was done for 6 to 8 weeks and physiotherapy started. Function was assessed at 6 months.

Results The operating time ranged from 2 to 3 hours. No major postoperative complications were noted. The parents' satisfaction was excellent at 6 months. None of the patients needed revision surgery for recurrence or first web space widening.

Conclusion Cleft hand needs to be analyzed for the adequacy of first web space. The reconstruction is aimed at functional first web space and cleft closure for providing better aesthetic results.

Keywords

- ▶ congenital
- ▶ reconstruction
- ▶ cleft hand
- ▶ limb anomalies

Introduction

Cleft hand or ectrodactyly is a congenital disorder that severely affects the aesthetics of the hand. It may be unilateral or bilateral. It may be associated with involvement of feet. Cleft hand can further be classified according to Manske and Halikis classification, based on first web space, as in **Table 1**.¹

Cleft hand has been called “functional triumph but a social disaster” by Flatt due to good function despite the presence of cleft.² Even so, surgical treatment improves the aesthetics without significantly compromising the function.³ Various authors have studied the pathology, development, classification and presented surgical techniques for correction of the deformity. We present our experience with reconstruction of cleft hand in five cases.

Materials and Methods

This is a retrospective review of cleft patients who presented to us from 2016 to 2020. Informed consent was obtained from all parents. All patients were in the age group of 3 to 5 years. After assessing the preoperative function, adequacy of first web space and thumb function, radiographs of the involved hand were taken. First web space angle was measured clinically using goniometer. First web space angle of sixty degrees or more was considered adequate.³ Preoperative photographs were taken. Associated involvement of other limbs and presence of vertebral defects, anal atresia, cardiac defects, tracheoesophageal fistula, renal and limb anomalies (VACTERL) syndrome was ruled out. The procedure was performed under general anesthesia with tourniquet control.

published online
June 29, 2022

DOI <https://doi.org/10.1055/s-0042-1750373>.
ISSN 0970-0358.

© 2022. Association of Plastic Surgeons of India. All rights reserved. This is an open access article published by Thieme under the terms of the Creative Commons Attribution-NonDerivative-NonCommercial-License, permitting copying and reproduction so long as the original work is given appropriate credit. Contents may not be used for commercial purposes, or adapted, remixed, transformed or built upon. (<https://creativecommons.org/licenses/by-nc-nd/4.0/>)
Thieme Medical and Scientific Publishers Pvt. Ltd., A-12, 2nd Floor, Sector 2, Noida-201301 UP, India

Table 1 Manske and Halikis classification for cleft hand

Type	Description	Characteristics
I	Normal web	Thumb space not narrowed
IIA	Mildly narrowed web	Thumb space mildly narrowed
IIB	Severely narrowed web	Thumb space severely narrowed
III	Syndactylized web	Thumb and index rays syndactylized, web space obliterated
IV	Merged web	Index ray suppressed; thumb web space merged with cleft
V	Absent web	Thumb elements suppressed, ulnar rays remain, thumb web space no longer present

Postoperatively, splintage was done for 6 to 8 weeks. Sutures were removed on day 14. Physiotherapy was started after 8 weeks and functional outcome was noted at 6 months. Satisfaction of parents in terms of function and cosmesis was noted on a scale of 1 to 4, one being poor, 2—fair, 3—good, and 4—excellent. It was subjective assessment. All patients were followed up for at least 6 months.

Surgical Technique

In three of the patients, Snow–Littler procedure was done as shown in ►Fig. 1A–D.⁴ All three patients had absent middle finger with its metacarpal present. The incisions were planned as shown. Preoperative photograph for case 1 is

shown in ►Fig. 2A. Intraoperative photographs and immediate postoperative photographs are shown in ►Fig. 2B–E. The skin flaps were raised on dorsal and volar sides as shown in ►Fig. 2C for case 1. After raising flaps and dissection, the second metacarpal osteotomy was done at the metacarpal base. Shortening of third metacarpal was done as required. The muscle attachments and neurovascular structures are carefully preserved. We did not need to divide the digital artery or nerve to shift the second metacarpal. The second metacarpal and the index finger were then

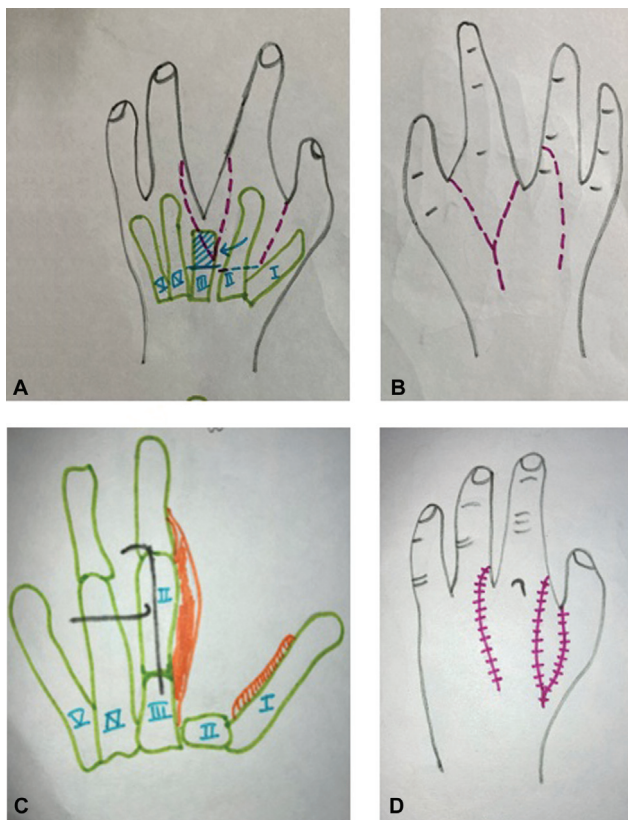


Fig. 1 Schematic diagram for the Snow–Littler procedure: (A and B) incisions over the skin. The bony incisions in A show the site of osteotomy over second and third metacarpal. C and D show the final bone and skin arrangement at the end of procedure.

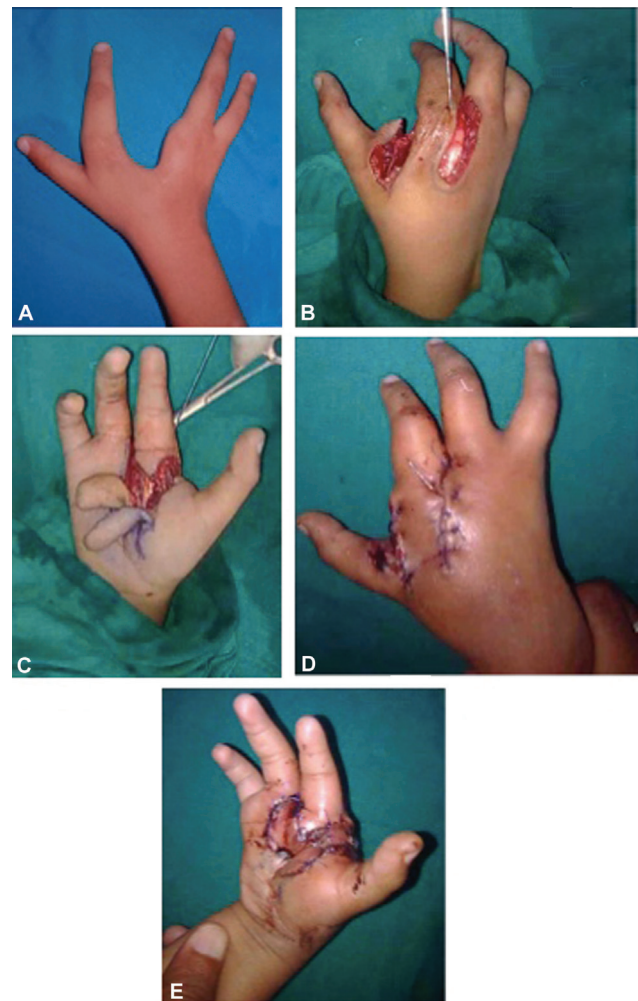


Fig. 2 (A) Preoperative and (B and C) intraoperative photographs for Snow–Littler procedure. (D and E) Immediate postoperative photographs are shown for case 1.

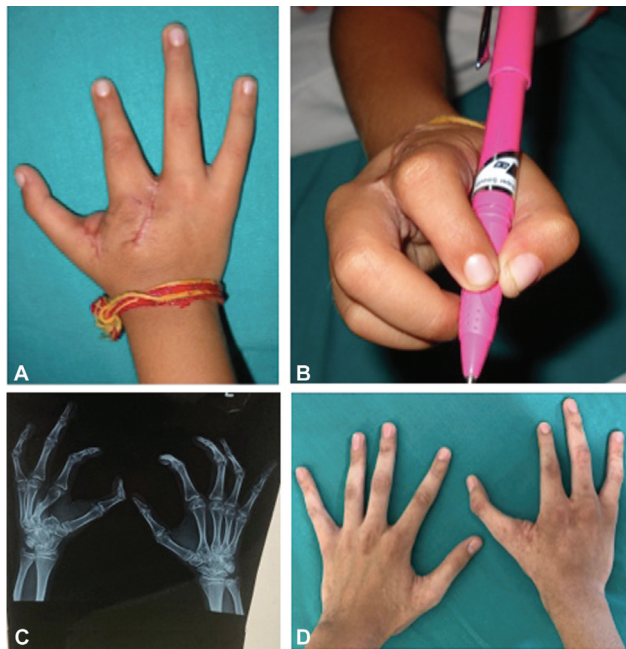


Fig. 3 (A and B) Postoperative photographs at 6 months for cases 1. (C) Postoperative radiograph at 2 years. (D) Postoperative result at 2 years with no widening of web space at previous cleft site.

shifted to third metacarpal base and fixed with two crossed Kirschner wires (K-wires), creating adequate first web space. Carpometacarpal joint was not included in the fixation. The skin flaps were used to resurface the first web space and wound closure is done. Splintage was done for 6 to 8 weeks. Sutures were removed on day 14. K-wires were removed after 6 weeks. Final result for case 1 was as shown in **Fig. 3A and B** with good functional outcome and minimal scars at 6 months. **Fig. 3C and D** shows postoperative radiograph and clinical photograph for case 1 after 2 years of surgical reconstruction. Minimal scars and good functional outcome with bony union can be appreciated. **Fig. 4A–D** shows preoperative and postoperative photographs for case 2.

In one patient, first web space was adequate with presence of all the digits. On radiological evaluation, it was noted that third metacarpal had angulation in its distal third. Preoperative photographs and radiograph have been shown in **Fig. 5A–C**. Reconstruction of the cleft with bone correction of the third metacarpal was done. Transverse metacarpal ligament reconstruction with Prolene 2-0 was done. The suture was passed around second and fourth metacarpal heads and tied in position. The web space was reconstructed using local flaps. The angulation was corrected and checked under fluoroscopy. Bone stabilization with two K-wires was done. Splintage was done for 4 weeks and suture removal was done after 14 days. **Fig. 5D and E** shows immediate postoperative photograph and postoperative result after 2 weeks.

In case 5, type I defect with central polydactyly was noted. The patient also had bilateral cleft hand with polydactyly and polydactyly in feet. Craniofacial structures were normal. On radiography, it was noted that transverse bone was present. The parents wanted correction of only right hand. The

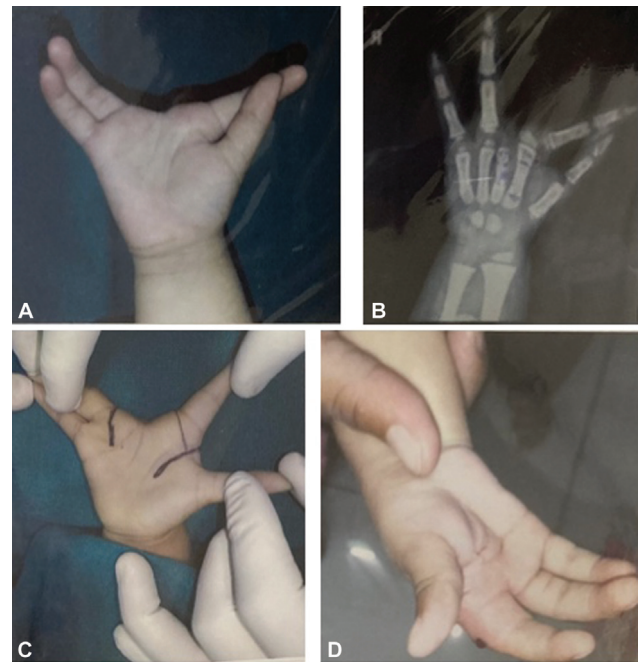


Fig. 4 (A) Preoperative photograph and (B) preoperative radiograph for case 2. (C) Intraoperative photograph with incisions marked and (D) final postoperative photograph at 6 months.

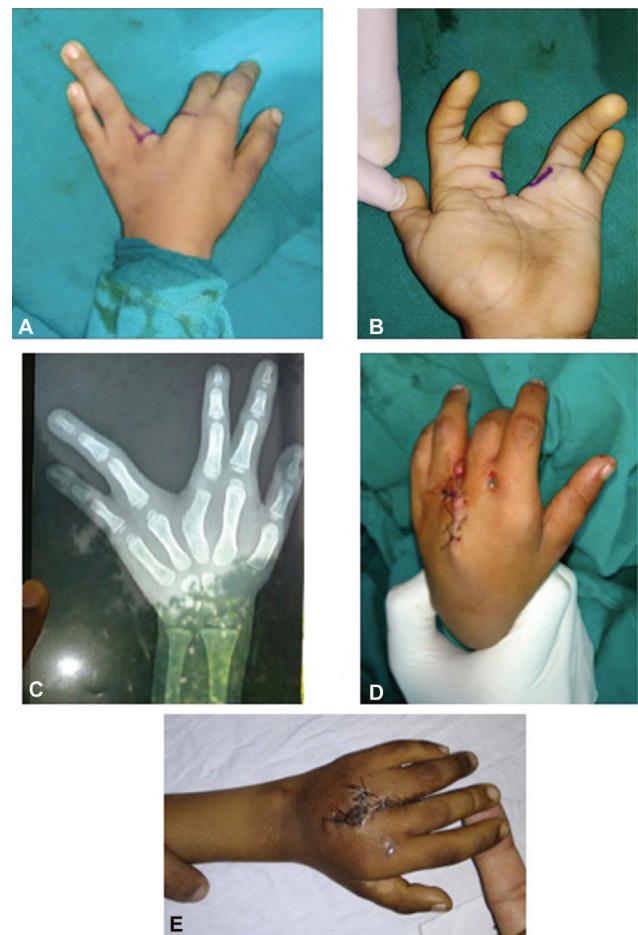

Fig. 5 (A and B) Preoperative photographs for case 4. (C) Preoperative radiograph. (D) Immediate postoperative photograph and (E) shows good result at 2 weeks.

Table 2 Details of all the patients with cleft hand who underwent correction

Case	Age (years)	Angle of first web space (clinical)	Type (Manske and Halikis classification)	Involvement	Procedure	Transverse metacarpal ligament reconstruction	Postoperative complications	Satisfaction
1	3	45	IIB	Right hand	Snow-Littler		–	Excellent
2	4	60	IIA	Left hand	Snow-Littler		–	Excellent
3	2.5	50	IIB	Right hand	Snow-Littler		–	Excellent
4	5	70	I	Right hand	Wedge osteotomy of III metacarpal and cleft closure	Yes	–	Excellent
5	3	70	1	Bilateral hands and feet	Right hand-transverse bone removal and cleft closure	Yes	Dorsal skin flap necrosis	Good

transverse bone was removed partially and transverse metacarpal ligament was reconstructed. Splintage was done for 4 weeks and suture removal was done after 14 days.

The relevant details of all the patients who underwent surgical reconstruction are shown in ► **Table 2**.

Results

The operating time ranged from 2 to 3 hours. One patient had skin flap necrosis that was managed conservatively. No major postoperative complications were noted. Four of the five patients had unilateral involvement. The parent satisfaction was excellent at 6 months in four patients and good in one. None of the patient needed revision surgery for recurrence or first web space widening. No finger angulation or instability of metacarpophalangeal joint was noted at follow-up. ► **Figs. 2 and 3** show preoperative, intraoperative, and postoperative photographs for case 1 who underwent Snow-Littler procedure. Photographs at 6 months and 2 years from surgery demonstrates good function with satisfactory scar over hand.

Discussion

Cleft hand or central ray deficiency is classified as a longitudinal deficiency. The hallmark for cleft hand is V-shaped cleft in the hand. The cause has been hypothesized as degeneration of apical ectodermal ridge of central segment.^{5,6} Thus, it affects the central digits sparing the radial and ulnar ones. In a typical cleft hand along with V-shaped cleft, syndactyly of the bordering digits especially first web can also be seen.

Main indications for surgery are follows:

1. Progressive deformity caused by deforming syndactyly or transverse bones
2. Deficient first web space
3. Deformity of the cleft
4. The absent thumb

Various surgical techniques have been documented for correction of cleft hand. Miura and Komada⁷ and more recently Upton⁸ have described transposition of the index finger into the central position. The palmar and dorsal skin are used to create first web space. Beck et al⁹ reported their results of Miura reconstruction with 20-year follow-up. They reported better results in terms of early flap necrosis and late web space contracture as compared with Snow-Littler procedure.

Snow-Littler procedure involves raising the cleft skin as palmar flap and using it for first web space after relocating index finger to third metacarpal.¹⁰ The idea was to remove third digit and relocate index finger over third metacarpal that increased first web space. Rider et al reported their experience with this technique.⁴ They noted satisfactory first web space and no significant flap necrosis. However, they reported that four patients had to undergo revision surgery for first web space. Inclusion of digital artery and limiting the size of the flaps have been recommended to decrease flap necrosis.⁴ Upton and Taghinia¹¹ modified the incisions described by Snow and Littler to decrease the chances of flap necrosis. Oberlin et al also modified the Snow-Littler technique.¹² They used a dorsal flap only to decrease scars on palm that may lead to contractures later on. In our experience, all three patients who underwent standard Snow-Littler procedure did not have any flap necrosis. They did not need revision surgery as well for first web space. However, due to rarity of the condition, the sample size is too small to make generalizations from this.

Ogino stated that in cleft hand syndactyly release and first web space correction are needed for functional improvement and cleft closure for aesthetics.¹³ He suggested that transverse metacarpal ligament reconstruction should be done using flexor tendon sheath of index and ring finger to decrease chances of late recurrence of cleft. He suggested use of cleft skin flaps for first web space widening.¹³ In our study, we used the method used by Barsky,¹⁴ that is, a nonabsorbable suture was passed around the metacarpal

heads and tied in position. No recurrence of cleft was seen in the patient. The postoperative follow-up needs subjective and objective assessment to document the improvement in hand function as described by Goldfarb et al.¹⁵ In our study, only subjective assessment was done.

Conclusion

The assessment of first web space is of foremost importance in deciding upon the surgical technique. Snow–Littler procedure, if needed, is useful for cleft closure and reconstructs narrowed first web space. The assessment of cause of cleft and its correction helps achieve good functional outcome.

Conflict of Interest

None.

References

- Manske PR, Halikis MN. Surgical classification of central deficiency according to the thumb web. *J Hand Surg Am* 1995;20(04):687–697
- Flatt AE. Cleft hand and central defects. In: *The Care of Congenital Hand Anomalies*. St. Louis: CV Mosby; 1977:265–285
- Youngleson JH. The management of the contracted first web space. *S Afr Med J* 1965;39(32):716–719
- Rider MA, Grindel SI, Tonkin MA, Wood VE. An experience of the Snow–Littler procedure. *J Hand Surg [Br]* 2000;25(04):376–381
- Buss PW. Cleft hand/foot: clinical and developmental aspects. *J Med Genet* 1994;31(09):726–730
- Falcochio DF, Da Costa AC, Durigan CPI, Nascimento VDG, Santili C, Chakkour I. Epidemiological and clinical aspects of cleft hand: case series from a tertiary public hospital in São Paulo, Brazil. *Hand (N Y)* 2019;14(06):814–818
- Miura T, Komada T. Simple method for reconstruction of the cleft hand with an adducted thumb. *Plast Reconstr Surg* 1979;64(01):65–67
- Upton J. Simplicity and treatment of the typical cleft hand. *Handchir Mikrochir Plast Chir* 2004;36(2-3):152–160
- Beck JD, Chang B, Jones NF. Over 20-year follow-up of Miura reconstruction of cleft hand. *Hand (N Y)* 2015;10(02):319–322
- Snow JW, Littler JW. Surgical treatment of cleft hand. In: *Transactions of the Fourth International Congress of Plastic Surgery (Rome)*. Amsterdam, The Netherlands: Excerpta Medica; 1967:888–893
- Upton J, Taghinia AH. Correction of the typical cleft hand. *J Hand Surg Am* 2010;35(03):480–485
- Oberlin C, Korchi A, Belkheyar Z, Touam C, Macquillan A. Digitalization of the second finger in type 2 central longitudinal deficiencies (clefing) of the hand. *Tech Hand Up Extrem Surg* 2009;13(02):110–112
- Ogino T. Cleft hand. *Hand Clin* 1990;6(04):661–671
- Barsky AJ. Cleft hand: classification, incidence, and treatment. Review of the literature and report of nineteen cases. *J Bone Joint Surg Am* 1964;46:1707–1720
- Goldfarb CA, Chia B, Manske PR. Central ray deficiency: subjective and objective outcome of cleft reconstruction. *J Hand Surg Am* 2008;33(09):1579–1588