



The Value of Radionuclide Cisternography in a Case of Spontaneous Cerebrospinal Leak

Carlyle Marques Barral¹ Thaís Ribeiro Lemos² Shirleide Santos Nunes³
Sandra Monetti Dumont Sanches⁴

¹Densitometry and Nuclear Medicine Physician at Hospital das Clínicas – Federal University of Minas Gerais (HC-UFMG), Belo Horizonte, Minas Gerais, Brazil

²The Nuclear Medicine Service of Hospital das Clínicas - Federal University of Minas Gerais Clinics (HC-UFMG), Belo Horizonte, Minas Gerais, Brazil

³Radiopharmacist at the Nuclear Medicine Service of Hospital das Clínicas - Federal University of Minas Gerais Clinics (HC-UFMG), Belo Horizonte, Minas Gerais, Brazil

⁴Head of the Nuclear Medicine Service of Hospital das Clínicas - Federal University of Minas Gerais Clinics (HC-UFMG), Assistant Professor at the Department of Anatomy and Image, Faculty of Medicine, UFMG. Belo Horizonte, Minas Gerais, Brazil

Address for correspondence Carlyle Marques Barral, MMed, Rua Prof. Morais, 476/901, Savassi, Belo Horizonte – MG Brazil CEP 30150-370, Brazil (e-mail: cbarral@terra.com.br).

World J Nuclear Med 2022;21:152–155.

Abstract

Keywords

- ▶ spontaneous intracranial hypotension
- ▶ spontaneous cerebrospinal fluid leak
- ▶ orthostatic headache
- ▶ Tc 99m-DTPA

Spontaneous intracranial hypotension (SIH) is an infrequent cause of daily persistent orthostatic headache with an incidence of 5 to 100,000 persons/year. In very rare cases, no cause can be found and these conditions may be called spontaneous cerebrospinal fluid leak (CSFL). Radionuclide cisternography (RNC) has played useful role in detecting CSFL. Although RNC has been used in many cases, few have been reported in which CSFL out of the subarachnoid space was detected. A case of CSFL confirmed by RNC direct findings is reported. SIH is difficult to diagnose and 95% of patients may initially receive an incorrect diagnosis. RNC has been shown to be fairly characteristic in SIH patients.

Introduction

Spontaneous intracranial hypotension (SIH) is an infrequent cause of daily persistent orthostatic headache with an incidence of 5 to 100,000 persons/year.¹ Other SIH common

symptoms arise from brainstem compression and nearby nerves traction. Cerebrospinal fluid leaks (CSFL) occur under several conditions: lumbar puncture performed for contrast myelography, spinal surgery, spinal stab wounds, spine fracture, inadvertent spinal puncture during epidural anesthesia, traumatic lumbar meningocele, and bronchopleural subarachnoid fistula due to bronchogenic carcinoma. Non-traumatic leaks result from cranial base focal areas pathologic destruction such as hydrocephalus, meningocele, global

Institution: Hospital das Clínicas – Federal University of Minas Gerais (HC-UFMG)

DOI <https://doi.org/10.1055/s-0042-1750338>.
ISSN 1450-1147.

© 2022. World Association of Radiopharmaceutical and Molecular Therapy (WARMTH). All rights reserved.

This is an open access article published by Thieme under the terms of the Creative Commons Attribution-NonDerivative-NonCommercial-License, permitting copying and reproduction so long as the original work is given appropriate credit. Contents may not be used for commercial purposes, or adapted, remixed, transformed or built upon. (<https://creativecommons.org/licenses/by-nc-nd/4.0/>)

Thieme Medical and Scientific Publishers Pvt. Ltd., A-12, 2nd Floor, Sector 2, Noida-201301 UP, India

atrophy, congenital deformities, osteomyelitis or tumors, leading to dura mater penetration. In very rare cases, no cause can be found and these conditions may be called spontaneous cerebrospinal leak.²

Radionuclide cisternography (RNC) can readily demonstrate and has played useful role in detecting CSFL. Although RNC has been used in many cases, few have been reported in which CSFL out of the subarachnoid space was detected.³

Case Report

CFS, a 26-year-old female, presented with one vomiting episode in the last week and throbbing severe parieto-occipital bilateral orthostatic headache for the last 3 months, and analgesic daily use. Photo/phonophobia, fever, visual symptoms, vertigo or focal deficit were absent. No history of comorbidities, trauma, sinusitis, lumbar puncture, or previous surgeries was found. Patient was normotensive, afebrile, eupneic, without focal deficits or meningeal irritation signs, Glasgow coma scale was 15, pupils were isochoric, and Romberg test was negative.

Computed tomography showed bilateral frontoparietal laminar subdural collection. Brain magnetic resonance imaging (MRI) showed laminar subdural effusion in frontoparietal lobes with discrete extension to the left temporal region, narrowing cortical sulcus, inferior brainstem displacement, inferior projection of the cerebellar tonsils toward the foramen magnum, and signs of venous congestion. Brain MRI showed bilateral frontoparietal laminar subdural effusion with slight extension to the left temporal region, erased cortical grooves, inferior brainstem displacement, midbrain located at the dorsum of the saddle level, and

inferior projection of the cerebellar tonsils toward the foramen magnum without collapse. Spine MRI showed dural sac meningeal thickening with contrast hypercaptation and epidural venous plexus distension along the spine compatible with pachymeningeal thickening, without leak localization. Lumbar puncture showed 10 cm H₂O opening CSF pressure.

After receiving 20 mCi of technetium-99m-diethylene-triamine-pentaacetate (^{99m}Tc-DTPA) intrathecally via lumbar puncture, posterior views of the brain and spine were performed at 0, 1, 2, and 4 hours post-injection. RNC showed bilateral CSFL at the lower lumbar spine level throughout the study (→Fig. 1) and isotope accumulation was also noted in the kidneys at the 1-hour image (→Fig. 2). Patient's symptoms subsided after conservative treatment (bed resting and hydration) and she was discharged asymptomatic.

Discussion

SIH diagnosis is based on clinical history, neurologic examination, neuroimaging studies, and CSF pressure measurement. SIH is difficult to diagnose and 95% of patients may initially receive an incorrect diagnosis.⁴ It is important to understand risk factors and symptoms to obtain appropriate imaging and avoid care delays. Otherwise, chronic pain and disability ensue with the potential for more serious neurological sequelae.⁵

RNC is used to study the CSF kinetics and for differential diagnosis of hydrocephalus and surgical shunts patency. The radiopharmaceutical used must follow the CSF flow without affecting its dynamics and then be reabsorbed quickly into




Fig. 1 Technetium-99m-diethylene-triamine-pentaacetate (^{99m}Tc-DTPA) radionuclide cisternography showing bilateral cerebrospinal fluid leak at the lower lumbar spine level throughout the study.

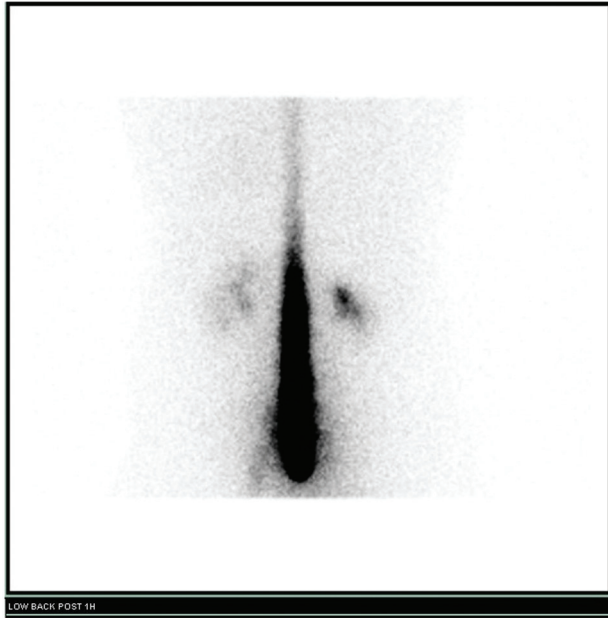


Fig. 2 Posterior view of technetium-99m-diethylene-triamine-pentaacetate radionuclide cisternography with isotope accumulation in the kidneys at the 1-hour image.

the arachnoid villi. The chelating agent, DTPA, is ideal for these purposes. DTPA shows no metabolism or absorption along the ependyma before reaching the arachnoid villi and has low lipid solubility. RNC is performed by means of injecting $^{111}\text{In-DTP}$ or $^{99\text{m}}\text{Tc-DTPA}$ subarachnoidally. Planar images are acquired immediately and at 1, 2, 4, and 24 hours. Occasionally, 48-hour delayed images are also obtained. Besides offering a whole spine encompassing view, this prolonged monitoring capability may aid in the detection of slow or intermittent leaks.

Typically, thoracolumbar spine posterior image taken at 15 to 30 minutes should show radioactivity cephalad expansion within spinal subarachnoid space. By 1 to 2 hours, activity should reach basilar cisterns, frontal poles by 2 to 5 hours, sylvian and interhemispheric fissures by 3 to 5 hours, and over cerebral convexities by 10 to 12 hours. By 24 hours, much of the activity is localized along arachnoid villi in superior sagittal sinus and less in basilar cisterns. Approximately two-thirds of the administered radioisotope are cleared via kidneys by 24 hours. Bladder activity is noted by 9 hours.⁶

If there is normal activity over the cerebral convexities at 24 hours, active CSF leak possibility will be quite slim. Negative findings can save the patient additional invasive studies and unnecessary radiation exposures. Activity paucity over cerebral convexities at 24 hours—in the absence of meningitis, subdural hematoma, head injury, brain surgery history—should point to a strong CSF leak probability.

RNC has been shown to be fairly characteristic in SIH patients, with findings including parathecal activity, less than 4 hours' renal uptake, and early urinary bladder radionuclide accumulation, slow ascent along spinal axis, activity delaying, and paucity over cerebral convexities. If leak is present, isotope concentration at the leak site increases progressively and isotope passage from basal cisterns to the sylvian fissure and interhemispheric cistern is reduced, consistent with low CSF pressure state. Direct evidence of spinal leak was reported in approximately 40% of patients in one series of 67 patients referred for clinically suspected SIH.⁷ If SIH is caused by reduced CSF production, then cisternography would probably show slow isotope egress and high concentration remaining for prolonged period at injection site.⁸ Indirect signs are sufficient to establish CSF leakage diagnosis. If RNC does not show any leak but is suggestive of rapid tracer uptake, presence of generalized CSF hyperabsorption is not necessarily indicated, but rather, leak presence is below the study resolution limit. Tracer activity semiquantitative graphical analysis over multiple craniospinal segments may aid in reduced intracranial activity indirect signs detection and rapid spinal activity loss and may improve this technique sensitivity and specificity.⁹

Several SIH cisternographic findings reports have been published, but lesions that clearly show the leaking site are rare. The reported case revealed small CSF leak in the early phase and clearly defined kidney images, which were helpful in lesion location. RNC is not only the diagnostic investigation key, but is also useful for better management planning, to help select the patients who need early intervention, to guide the level of epidural blood patch injection and to evaluate therapeutic effects.

Conflict of Interest

None declared.

References

- 1 Akbar RA, Khan AA, Fernandes GM, Ahmed Mohamed AZ, Elsouhouy A, Ali YOM. Spontaneous intracranial hypotension and its management with a cervical epidural blood patch: a case report. *Am J Case Rep* 2020;21:e925986
- 2 Kraft O, Safarčík K, Bartos V. Detection of spontaneous cerebrospinal fluid rhinorrhea. *Hell J Nucl Med* 2004;7(01):56–57
- 3 Spelle L, Boulin A, Tainturier C, Visot A, Graveleau P, Pierot L. Neuroimaging features of spontaneous intracranial hypotension. *Neuroradiology* 2001;43(08):622–627
- 4 Frank LR, Paxson A, Brake J. Spontaneous intracranial hypotension—a case report. *J Emerg Med* 2005;28(04):427–430
- 5 Falatko SR, Kelkar P, Setty P, Tong D, Soo TM. C1–C2 cryptic cerebrospinal fluid leak directly identified by pressurized radionuclide cisternography: case report and review of the literature. *Surg Neurol Int* 2015;6:126
- 6 Mokri B. Radioisotope cisternography in spontaneous CSF leaks: interpretations and misinterpretations. *Headache* 2014;54(08):1358–1368

- 7 Morioka T, Aoki T, Tomoda Y, et al. Cerebrospinal fluid leakage in intracranial hypotension syndrome: usefulness of indirect findings in radionuclide cisternography for detection and treatment monitoring. *Clin Nucl Med* 2008;33(03):181-185
- 8 Ozaki Y, Sumi Y, Kyogoku S, Shindoh N, Katayama H. Spontaneous intracranial hypotension: characteristic findings of radionuclide cisternography using In-111 DTPA. *Clin Nucl Med* 1999;24(10):823-825
- 9 Ali SA, Cesani F, Zuckermann JA, Nusynowitz ML, Chaljub G. Spinal-cerebrospinal fluid leak demonstrated by radiopharmaceutical cisternography. *Clin Nucl Med* 1998;23(03):152-155