



Hydrocephalus in Neurofibromatosis Type 1 Caused by a Cyst Formation Similar to Late-Onset Aqueductal Membranous Occlusion: A Case Report and Review of Literature

Kiyonori Kuwahara¹ Shigeo Ohba¹ Tsukasa Ganaha¹ Kazuhiro Murayama² Masato Abe³
Mitsuhiro Hasegawa¹ Yuichi Hirose¹

¹Department of Neurosurgery, School of Medicine, Fujita Health University, Toyoake, Japan

²Department of Radiology, School of Medicine, Fujita Health University, Toyoake, Japan

³Department of Pathology, School of Health Science, Fujita Health University, Toyoake, Japan

Address for correspondence Kiyonori Kuwahara, MD, PhD, Department of Neurosurgery, School of Medicine, Fujita Health University, 1-98 Dengakugakubo, Kutsukakecho, Toyoake, 470-1192, Japan (e-mail: kiyonorikuwahara@gmail.com).

AJNS 2022;17:357–361.

Abstract

Cyst formation in the third ventricle and the histopathological findings were rarely reported. We report a similar case of late-onset aqueductal membranous occlusion (LAMO) caused by a thin gliotic cyst and a review of related literature. A 28-year-old woman with enlarged lateral ventricles was referred to our hospital with complaints of headache and dizziness. In our hospital, the obvious cause of the hydrocephalus was unknown on any examination and we decided performing endoscopic third ventriculostomy for hydrocephalus. A thin cyst covering the entrance of the aqueduct was identified and we perforated it. Histopathological finding of the cyst wall was gliosis and our case was similar to LAMO, although not typical. The postoperative symptoms and ventricle size improved for 4 years. When suspecting cases similar to definition of LAMO, neuroendoscopic surgery would be the first-choice treatment and might detect causes undetectable on preoperative imaging such as our thin membrane.

Keywords

- ▶ hydrocephalus
- ▶ late-onset aqueductal membranous occlusion
- ▶ time-SLIP

Introduction

Neurofibromatosis type 1 (NF1) is one of the most common autosomal dominant genetic disorders in humans.¹ Hydrocephalus has been reported in 2 to 23% of NF1 patients, and NF1 patients rarely present with hydrocephalus caused by late-onset aqueductal membranous occlusion (LAMO).^{2,3}

Here, we report a similar case to LAMO. Although the membranous structure directly covered the aqueduct in the LAMO, a thin expanded cyst wall covered the entrance of the aqueduct in our case. The cause of the hydrocephalus was diagnosed on the basis of the neuroendoscopic rather than the preoperative examination findings. We reviewed the literatures about LAMO and compared our case with previously reported LAMO cases.

DOI <https://doi.org/10.1055/s-0042-1750308>.
ISSN 2248-9614.

© 2022. Asian Congress of Neurological Surgeons. All rights reserved.

This is an open access article published by Thieme under the terms of the Creative Commons Attribution-NonDerivative-NonCommercial-License, permitting copying and reproduction so long as the original work is given appropriate credit. Contents may not be used for commercial purposes, or adapted, remixed, transformed or built upon. (<https://creativecommons.org/licenses/by-nc-nd/4.0/>)

Thieme Medical and Scientific Publishers Pvt. Ltd., A-12, 2nd Floor, Sector 2, Noida-201301 UP, India

Case Report

A 28-year-old woman visited a nearby hospital with complaints of headache and dizziness. Computed tomography revealed enlarged lateral ventricles. She was referred to our hospital for further examinations. Café au lait spots and neurofibroma were observed on her face and back. Blood and cerebrospinal fluid (CSF) examinations yielded normal results. The patient's past medical history included systemic lupus erythematosus and NF1. She received prednisolone, tacrolimus, and mizoribine. Magnetic resonance imaging (MRI) revealed hydrocephalus, but no obvious intracranial lesions. MRI with the time-spatial labeling inversion pulse (SLIP) showed no CSF flow in the aqueduct, and obstructive hydrocephalus due to aqueductal lesion was suspected (►Figs. 1A, 2). When endoscopic third ventriculostomy (ETV) was performed, a thin membrane covering the entrance of the aqueduct was detected (►Fig. 1B). In addition to ETV, we perforated the thin membrane to maintain the normal CSF flow (►Fig. 1C). The membranous structure was part of the cyst wall, and the cyst was deflated by breaking a part of the membranous structure, thereby restoring the CSF flow to the aqueduct. Histopathologically, the cyst wall consisted of gliosis (►Fig. 1D, E). After the operation, the symptoms and enlargement of the ventricles were

improved (►Fig. 1F). CSF flow was observed not through the floor of the third ventricle but through the aqueduct on MRI with the time-SLIP (►Fig. 3). No recurrence of hydrocephalus was observed for 4 years after the surgery.

Discussion

Matsuda et al first described LAMO in 2011.² Terada et al defined LAMO as follows³: first, the aqueduct of Sylvius showed a membranous structure but no CSF flow; second, no other occlusive lesion and no recent subarachnoid hemorrhage, intraventricular hemorrhage, or meningitis was found that could cause the hydrocephalus; third, the lateral and third ventricles were enlarged, but the fourth ventricle was not; and fourth, the patient was not diagnosed in childhood. No membranous structure was found in the aqueduct of Sylvius in our case, but it was a similar case to LAMO. In our case, the membranous structure covered the entrance of the aqueduct by expanding like a cyst. Gliosis, forking, simple stenosis, or membranous occlusion was considered to be the cause of the aqueductal stenosis or occlusion in the past report.^{4,5} Our histopathological findings from the cyst wall were also consistent with gliosis. The surgical treatment of LAMO is mainly endoscopic aqueductoplasty (EA) and/or ETV, which have an advantage of improving hydrocephalus without shunt system

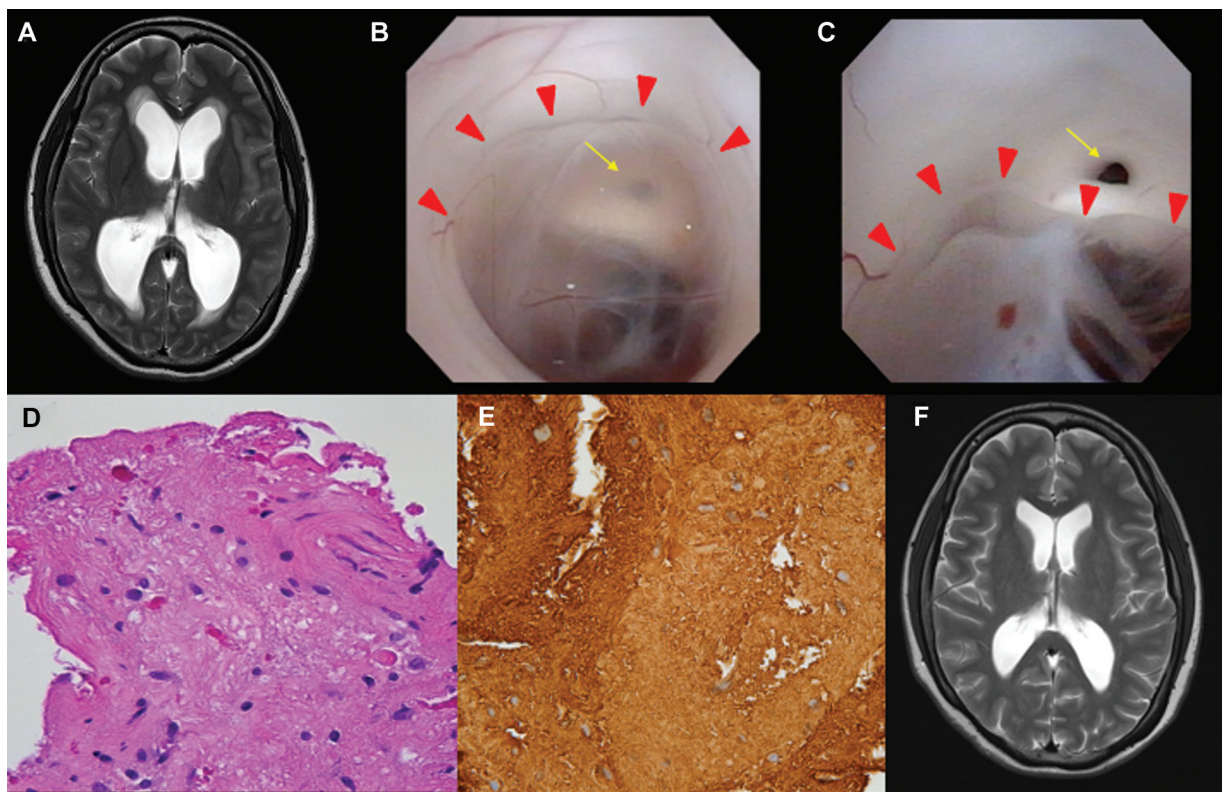


Fig. 1 (A) Preoperative T2-weighted magnetic resonance image showing the enlarged ventricles and no intracranial lesions. (B) Intraoperative view showing the thin cyst (red arrowhead, the edge of the cyst wall) covering the entrance of the aqueduct (yellow arrow). (C) The membrane covering the aqueduct is perforated, and the cerebrospinal fluid flow is improved. The red and yellow arrowheads indicate the edge of shrank cyst wall; the entrance of the aqueduct, respectively. (D) The pathological findings from the hematoxylin and eosin staining (original magnification $\times 40$) showing astrocytes with irregular nuclei. Neither mitosis nor necrosis was detected. (E) Staining positive for glial fibrillary acidic protein (original magnification $\times 40$). (F) Postoperative T2-weighted magnetic resonance image showing the improvement of the ventricles size.

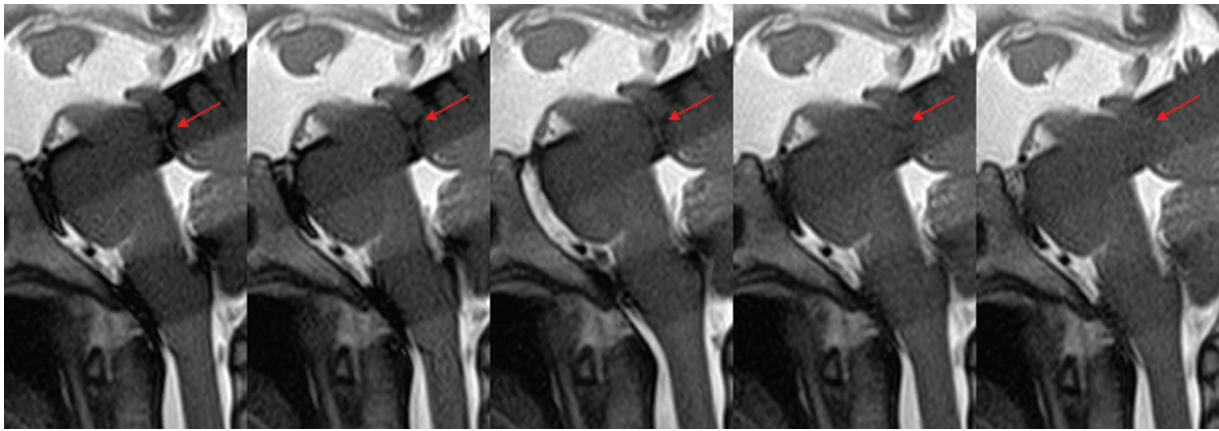


Fig. 2 Preoperative magnetic resonance image with time-spatial labeling inversion pulse showing no cerebrospinal fluid flow from the third ventricle to the aqueduct (*red arrow*).

insertion.^{2,3,6,7} We performed EA and ETV because the patient took immunosuppressive drugs, and we were concerned of a possible shunt infection.

We summarize 12 cases consistent with LAMO in **Table 1**.^{2,3,6,7} The main symptom was headache, and the oldest patient was 66 years old. Only EA was performed in eight cases, and EA + ETV was performed in four cases. The chief complaints were improved in eight cases (66.6%). Of the EA + ETV cases, two (50%) had complications, but only the EA

cases had no complications. The postoperative CSF flow was studied in Terada's case and in our case using MRI with a three-dimensionally driven equilibrium pulse and time-SLIP, respectively.³ CSF flow was detected in the third ventricular floor and aqueduct in a former case and only in the aqueduct in our case. According to the postoperative CSF flow analysis of two cases, performing aqueductoplasty to restore the physiological CSF flow would be more important than performing ETV alone in cases like LAMO. Our case did not show




Fig. 3 Postoperative magnetic resonance image with time-spatial labeling inversion pulse showing cerebrospinal fluid flow signal not through the floor of the third ventricle (*yellow arrow*) but through the aqueduct (*red arrow*).

Table 1 Review of clinical results of late-onset aqueductal membranous occlusion treated by endoscopic ventriculostomy and/or aqueductoplasty

Author (y)	Age/sex	Symptoms	Operation (complication)	Outcome (follow-up [mo])	Postoperative ventricular size	Postoperative CSF flow
Schroeder and Gaab (1999) ⁶	31/F	Headache, nausea, vomiting, blurred vision, seizure	EA	Occasional headache (18)	Smaller	N/A
	46/F	Headache, mental deterioration	EA	Unchanged (7)	Smaller	N/A
	66/M	Mental deterioration, gait disturbances, urinary incontinence, alcohol abuse	EA	Unchanged (1)	Unchanged	N/A
	66/F	Headache, mental deterioration, gait disturbances, urinary incontinence, dementia	EA + ETV (Fornix contusion)	Died after stroke (1)	Unchanged	N/A
Matsuda et al (2011) ²	57/M	Gait disturbances, dementia	EA + ETV	Improved (7)	Unchanged	N/A
Chen et al (2013) ⁷	20/M	Headache, vomiting	EA	Improved (16 ≤)	N/A	N/A
	24/F	Headache, vomiting	EA	Improved (16 ≤)	N/A	N/A
	26/M	Headache, vomiting	EA	Improved (16 ≤)	N/A	N/A
	28/F	Headache, vomiting	EA	Improved (16 ≤)	N/A	N/A
	33/F	Headache, vomiting	EA	Improved (16 ≤)	N/A	N/A
Terada et al (2020) ³	36/M	Headache, loss of consciousness	EA + ETV (diplopia)	Improved (N/A)	Smaller	CSF flow in the third ventricular floor and aqueduct
Our case	28/F	Headache, dizziness	EA + ETV	Improved (54)	Smaller	CSF flow in the aqueduct

Abbreviations: CSF, cerebrospinal fluid; EA, endoscopic aqueductoplasty; ETV, endoscopic ventriculostomy; F, female; M, male; N/A, not available.

a reocclusion for 54 months despite that no postoperative CSF flow was observed in the third ventricle floor.

The histopathological findings from the cyst wall in our case were consistent with gliosis and suggested a relationship between the cyst formation and the membranous structure of the aqueduct in the previous report.^{4,5}

In the other reports, the membranous structure in the aqueduct was detected on the preoperative MRI, but our case did not show obvious causes in the radiological images.^{2,3,6,7} It was considered that the cyst wall of the gliosis was so thin that it could not be identified on the preoperative MRI. If LAMO was suspected, endoscopic treatment might be available to find and treat unknown causes in the imaging examinations and obtain a good clinical result for a long time without shunt insertion.

Conclusion

When suspecting cases similar to LAMO, neuroendoscopic surgery might have an advantage in the diagnosis of unknown causes by preoperative MRI, and the hydrocephalus could be treated without shunt insertion for a long time.

Declaration of Patient Consent

The authors certify that they have obtained all appropriate patient consent forms. In the form, the patient has given her consent for her images and other clinical information to be reported in the journal. The patient understand that her name and initials will not be published, and due efforts will be made to conceal her identity, but anonymity cannot be guaranteed.

Ethical Approval

Informed consent was obtained, and this research was performed in accordance with the rules of the ethics committee of Fujita Health University.

Funding

None.

Conflict of Interest

None declared.

References

- Wallace MR, Marchuk DA, Andersen LB, et al. Type 1 neurofibromatosis gene: identification of a large transcript disrupted in three NF1 patients. *Science* 1990;249(4965):181–186
- Matsuda M, Shibuya S, Oikawa T, Murakami K, Mochizuki H. [A case of late-onset aqueductal membranous occlusion and a successful treatment with neuro-endoscopic surgery]. *Rinsho Shinkeigaku* 2011;51(08):590–594
- Terada Y, Yamamoto M, Motoie R, et al. Hydrocephalus resulting from late-onset aqueductal membranous occlusion: a case report and review of the literature. *World Neurosurg* 2020;137:345–349
- Drachman DA, Richardson EP. Aqueductal narrowing, congenital and acquired a critical review of the histologic criteria. *Arch Neurol* 1961;5:552–559
- Russell DS. Observation on the pathology of hydrocephalus. In: *Medical Research Council Special Report, Series No. 265*. London: His Majesty's Stationery Office; 1949:41–50
- Schroeder HW, Gaab MR. Endoscopic aqueductoplasty: technique and results. *Neurosurgery* 1999;45(03):508–515, discussion 515–518
- Chen G, Zheng J, Xiao Q, Liu Y. Application of phase-contrast cine magnetic resonance imaging in endoscopic aqueductoplasty. *Exp Ther Med* 2013;5(06):1643–1648