




Combined Use of Negative Oral Contrast and Ranitidine for Magnetic Resonance Cholangiopancreatography: A Randomized Controlled Trial

Aravintho Natarajan¹  Dilip S. Phansalkar¹ George Kurian² Mithun Raj R.¹ Preeth Pany T.¹ Jayaranjeetham Jayabalan¹

¹ Department of Radiology, Pondicherry Institute of Medical Sciences, Puducherry, India

² Department of Gastroenterology (Retired), Pondicherry Institute of Medical Sciences, Puducherry, India

Address for correspondence Mithun Raj R., MBBS, MD, Department of Radiology, Pondicherry Institute of Medical Sciences, Kalapet, Puducherry 605 014, India (e-mail: dr.muthu1211@gmail.com).

J Gastrointestinal Abdominal Radiol ISGAR 2023;6:8–14.

Abstract

Objective Magnetic resonance cholangiopancreatography (MRCP) is a noninvasive imaging modality to study pancreaticobiliary tree. The primary aim of this study was to compare the image quality of MRCP obtained with the use of ferric ammonium chloride (negative oral contrast) with that of combined use of ferric ammonium chloride and ranitidine (administered orally). Secondary aim was to determine the interobserver agreement between the assessing radiologists.

Materials and Methods The study was a single-center randomized-controlled trial. The patients were randomized into two groups. One group received ranitidine orally and ferric ammonium chloride (Dexorange) and the other group received only the ferric ammonium chloride. The images were qualitatively analyzed independently by the two blinded radiologists. Two scoring systems were used for grading the diagnostic quality of the images: the gastrointestinal tract signal intensity score (range: 1–4) and the structure visibility score (range: 0–3). The mean score of contrast effect and image effect of the two groups were compared by using Mann–Whitney U test. A *p*-value < 0.05 was considered statistically significant. Interobserver agreement was studied using Cohen kappa coefficient.

Results A total of 93 patients were eligible for the study. Forty-one patients were randomly assigned to the group that received only negative oral contrast and 52 group that received both ranitidine and negative oral contrast. The mean score of the images obtained with using both ranitidine and negative oral contrast was significantly higher when compared with the other group (3.02 vs. 2.7) (*p*-value = 0.018). However, there was no significant difference in mean structure visualization score of various parts of

Keywords

- ▶ image quality
- ▶ MRCP
- ▶ negative oral contrast
- ▶ ranitidine

article published online
July 11, 2022

DOI <https://doi.org/10.1055/s-0042-1750138>.
ISSN 2581-9933.

© 2022. Indian Society of Gastrointestinal and Abdominal Radiology. All rights reserved.

This is an open access article published by Thieme under the terms of the Creative Commons Attribution-NonDerivative-NonCommercial-License, permitting copying and reproduction so long as the original work is given appropriate credit. Contents may not be used for commercial purposes, or adapted, remixed, transformed or built upon. (<https://creativecommons.org/licenses/by-nc-nd/4.0/>)

Thieme Medical and Scientific Publishers Pvt. Ltd., A-12, 2nd Floor, Sector 2, Noida-201301 UP, India

the pancreaticobiliary system. The interobserver agreement between the two readers in our study was acceptable.

Conclusion Combined use of hematinic syrup and ranitidine increases the image quality by improving the suppression of gastrointestinal fluid signal as compared with the use of only hematinic syrup as negative oral contrast.

Introduction

Magnetic resonance cholangiopancreatography (MRCP) is a noninvasive imaging modality that depicts the anatomy and pathology of the pancreaticobiliary tree. Heavily T2-weighted (T2W) two-dimensional and three-dimensional sequences are used in MRCP to visualize the pancreaticobiliary system. The pancreaticobiliary tree is visualized as hyperintense structure due to fluid signal from bile and pancreatic enzymes. However, fluid signals of the gastrointestinal tract (GIT) pose a challenge by interfering in the visualization of pancreaticobiliary tree especially the distal parts.

Orally administered (negative) contrast agents that contain superparamagnetic and paramagnetic particles, with a strong T2 shortening effect, can suppress the high-intensity fluid signal from the GIT. Approved contrast agents that contain superparamagnetic particles are generally costly, not widely available, and are not palatable. In our hospital, the standard protocol is to use ferric ammonium citrate (Dexorange) as negative oral syrup to suppress the fluid signals from GIT. A alternative approach is to suppress the gastric secretion by use of drugs like ranitidine.^{1,2}

The primary aim of this study was to compare the image quality of MRCP obtained with the use of iron syrup (Dexorange administered orally) with that of combined use of iron syrup and ranitidine (administered orally). Secondary aim was to determine the interobserver agreement between the assessing radiologists.

Materials and Methods

The study was a single-center, randomized controlled trial conducted between April 2019 and December 2020. The study was approved by the ethics committee of the institute in which the trial was performed and was registered in clinical trial registry of India (registration number: CTRI/2019/04/018466). Written informed consent was obtained from all participants prior to MRCP. All patients above 18 years of age who were referred for MRCP were eligible for this study. Following patients were excluded: 1. Patients with MRI incompatible implant or aneurysm/surgical clips or metallic sutures; 2. Patients with history of foreign body; 3. Patients with history of prior hepatobiliary surgery or endoscopic retrograde cholangiopancreatography; 4. Patients with ascites; 5. Scans of patient with poor quality due to other technical factors like motion artifacts; 6. Patients who were allergic to hematinic syrup and/or ranitidine.

Eligible patients were enrolled for trial after obtaining written consent. The enrolled patients were randomized (by computer aided simple randomization technique) into two

groups. One group received 300 mg of ranitidine orally 2 hours prior to scan and 30 mL of ferric ammonium chloride 1.06% (weight/volume) (Dexorange) as negative oral contrast 15 minutes prior to scan; and the other group received only the negative oral contrast (Dexorange) 15 minutes prior to scan.

MRI Protocol

The patients were instructed to fast 4 to 6 hours, prior to the examination. All MRCP examinations were performed using 1.5-T MRI unit (Achieva, Philips Healthcare, Best, Netherlands) with phased-array body coil. Conventional upper abdominal MRI examination using axial T1W, T2W, and T2 spectral adiabatic inversion recovery (SPAIR) and coronal T2W and T2 SPAIR sequences were performed before MRCP protocols. Two MRCP sequences were applied for each patient. The first one was thick slab sequence (SSh MRCP rad; repetition time (TR): 8,000 ms; time to echo (TE): 800 ms; flip angle: 90 degrees; field of view (FOV): 300 mm; 40mm thick oblique coronal slices) at single breath hold. Sections were taken through the porta hepatis and rotating around a point anterior to the portal vein. The other sequence was thin slab sequence (3D MRCP HR; TR: 1,204 ms; TE: 650 ms; flip angle: 90 degrees; FOV: 260; 1 mm thick straight 3D coronal sections at 0.8-mm interval). Two maximum-intensity projection (MIP) reconstruction sets of MRCP sequence were obtained in two different rotation plans: sagittal-coronal and axial-coronal.

Image Analysis

The images of MRCP were viewed on display system using extended MR workspace software (version 2.6.3.4, Philips Healthcare) by two experienced radiologists. The images were analyzed independently by the two radiologists who were blinded to information regarding the negative oral contrast and ranitidine ingestion. Two scoring systems were used for grading the diagnostic quality of the images: the GIT signal intensity score and the structure visibility score.

The GIT signal intensity scoring was done qualitatively by grading the images as one of following four scores: 4—entirely no signal in stomach, duodenum, and in rest of the small bowel; 3—part of the stomach/duodenum/rest of the small bowel showing high signal but not affecting the reading of scan; 2—high signal intensity in stomach/duodenum/rest of the small bowel affecting the reading of scan; 1—high signal intensity in stomach /duodenum /rest of the small bowel making reading the scan difficult.

The structure visibility scoring was done qualitatively by grading the various segments of the biliary tree and pancreatic duct as one of following four scores: 3—complete

Table 1 General demographics of study population in each group

| Group | Number of patients | Age (years) Median (range) | Male | Female |
|-------------------------------------|--------------------|-------------------------------|------|--------|
| Ranitidine + negative oral contrast | 52 | 46 (19–74) | 23 | 29 |
| Only negative oral contrast | 41 | 55 (21–76) | 23 | 18 |

visualization; 2—moderate visualization; 1—poor visualization; 0—no visualization. The various segments assessed were the gallbladder, ampulla, common bile duct, common hepatic ducts, intrahepatic ducts, and pancreatic duct.

Statistical Analysis

Estimated sample size was calculated using data from previous study that used similar scoring system to compare the quality of MRCP scan. The mean score of one group was assumed to as 2.6 ± 0.8 and the other as 3.4 ± 0.5 . An α error of 5% and power of 80% yielded 50 patients per each group.

The mean score of contrast effect and image effect of the two groups was compared by using Mann–Whitney U test. A p -value < 0.05 was considered statistically significant. Inter-observer agreement was studied using Cohen kappa coefficient.

Results

A total of 115 patients were assessed for eligibility. Among them 22 patients were excluded due to prior hepatobiliary surgery ($n = 11$), ascites ($n = 10$), and declination to participate ($n = 2$). Ninety-three patients were eligible and were enrolled in the study after obtaining informed consent. Forty-one patients were randomly assigned to the group that received only negative oral contrast and 52 to the group that received both ranitidine and negative oral contrast. The patient characteristics are shown in **Table 1** (**Figs. 1 and 2**).

The mean score of the images obtained with using both ranitidine and negative oral contrast (3.02) was significantly higher when compared with those obtained with using only negative oral contrast (2.7) (p -value = 0.018) (**Table 2**). There was substantial agreement between the two readers

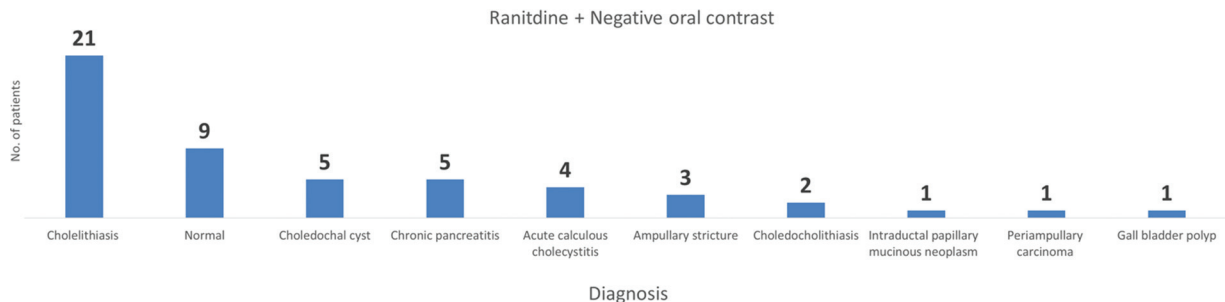


Fig. 1 Frequency histogram depicting the number of patients with their respective diagnosis who received ranitidine and negative oral contrast.

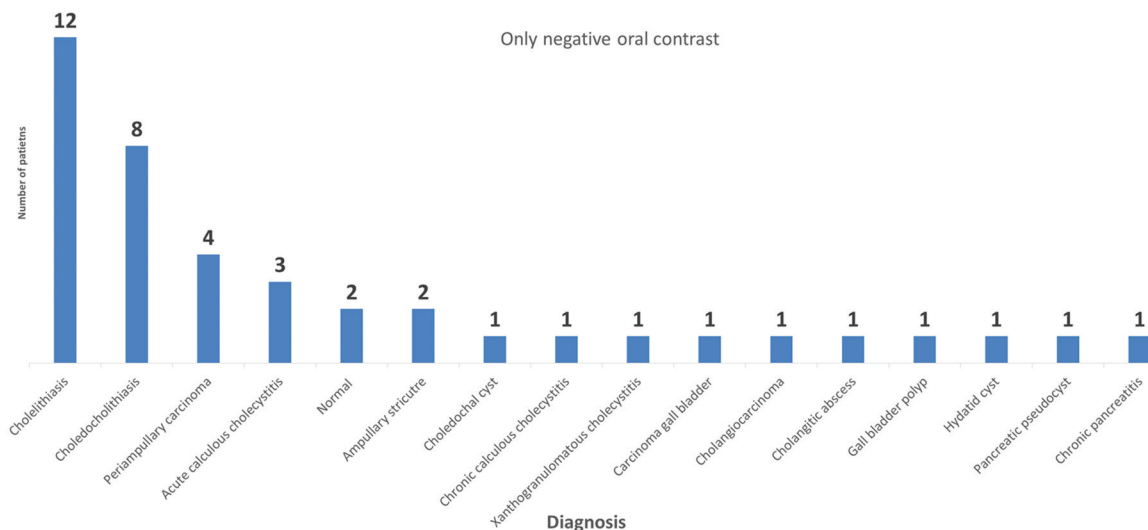


Fig. 2 Frequency histogram depicting the number of patients with their respective diagnosis who received only negative oral contrast.

Table 2 Comparison of the mean gastrointestinal tract signal intensity score of both groups

| Group | Number of patients | Mean score | SD |
|-------------------------------------|--------------------|------------|-------|
| Ranitidine + negative oral contrast | 52 | 3.0288 | 0.606 |
| Only negative oral contrast | 41 | 2.7073 | 0.602 |

with Cohen kappa value being 0.61. However, there was no significant difference in mean structure visualization score of various parts of the pancreaticobiliary system between the two groups (► **Table 3**). Duodenum was the frequent site with high signal intensity in both groups (► **Fig. 3**).

Discussion

MRCP is a noninvasive imaging modality to evaluate the pancreaticobiliary system. It has continued to evolve and is established as a noninvasive alternative to endoscopic retrograde pancreatography. Images are obtained without requiring ionizing radiation, sedation, or intravenous contrast material administration.

MRCP uses heavily T2W sequences to depict the biliary tract, pancreatic duct, and gall bladder as high signal intense structures owing to the fluid within them serving as an intrinsic contrast medium. The entire pancreaticobiliary ductal system can be imaged in MRCP using fast imaging

sequences, single-breath-hold techniques, and/or respiratory gating. Current techniques allow for the depiction of obstructed or dilated bile and pancreatic ducts as well as normal caliber biliary systems, although the latter may be more difficult to visualize. The image quality of MRCP may deteriorate due to superimposition of high signal intensity from intestinal fluid. This superimposition may obscure the underlying ducts or mimic pathology and is more pronounced in sequences with thick slice images. Fasting before the MRCP is not sufficient to eliminate signals from the GIT. This pitfall can be avoided to an extent by understanding the normal coronal anatomy of the abdomen and acquiring images in multiple planes or thin continuous slice images. One simple technique to suppress the high signal in the GIT is by using a negative oral contrast agent, which shortens the T2 relaxation time and thus reduces the signal of the intestinal fluid.

A review of literature by Frisch et al has reported that 16 different orally administered contrast agents were used in MRCP to suppress intestinal fluid signal. These included certified and/or pharmaceutically approved substances and various fruit juices/beverages rich in iron/manganese.³ An ideal contrast agent should decrease T2 relaxation time, cause homogeneous signal suppression safe, and should be safe, good patient tolerance, and readily available. Commercially available preparations of oral contrast agents contain magnetic particles that are responsible for T2 shortening effect. They are generally expensive, not widely available, and unpalatable.^{4,5} Various fruit juices/beverages (pineapple, blueberry juice) have been used in few studies as

Table 3 Comparison of mean structure visibility score of various segments of the pancreaticobiliary tree

| Segments of pancreaticobiliary tree | Mean score of ranitidine and negative oral contrast group | Mean score of only negative oral contrast group | p-Value |
|-------------------------------------|---|---|---------|
| Gallbladder | 2.5 | 2.4 | 0.3 |
| Ampulla | 1.5 | 1.2 | 0.19 |
| Common bile duct | 2.8 | 2.8 | 0.6 |
| Common hepatic ducts | 2.8 | 2.8 | 0.6 |
| Intrahepatic ducts | 2.5 | 2.7 | 0.08 |
| Pancreatic duct | 2 | 2.2 | 0.2 |

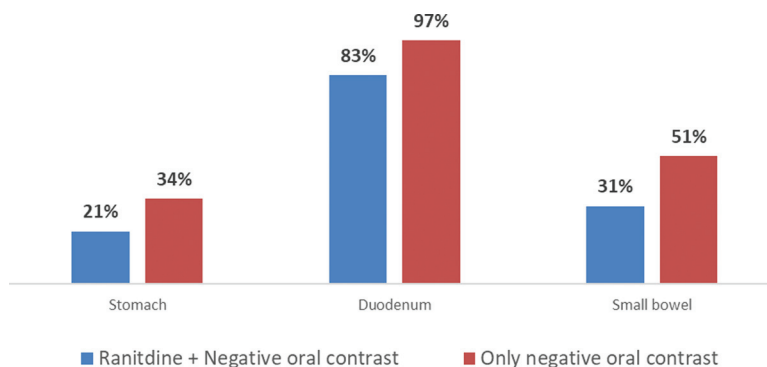


Fig. 3 Frequency histogram depicting the percentage of patients with signal intensity in various parts of gastrointestinal tract in both groups.

negative contrast agent. These beverages are rich in iron/manganese that reduce the T2 relaxation time, thus decreasing the signal intensity in the GIT.

A recent study by Mohabir et al used 250 mL of commercially available packaged pineapple juice. The authors believed that the concentration of the manganese in the pineapple juice in general could vary from 9.3 to 12.7 mg/L; however, they did not mention the exact concentration of that particular brand of pineapple juice that they used for the study.⁶ In our region, commercially prepared pure pineapple or blue berry juices are not readily or widely available and the manufacturers do not provide the manganese concentration.

Govindarajan et al studied the in vitro and in vivo effects of date syrup on the quality of MRCP images and observed significant improvement in GIT signal suppression with increase in visibility of the common bile duct, cystic duct, and pancreatic duct. In vivo analysis revealed iron (in ferric form) in date syrup was responsible for T2 shortening effect.⁷ Most commercial preparations of date syrup that are available in local market do not mention the iron concentration in their package and hence it is difficult to compare its efficacy.

Hematinic syrup used for treating anemia is rich in iron and thus it has low T2 relaxation time and low T2 signal. So, in our hospital the standard protocol is to use ferric ammonium citrate 1.06% (weight/volume) (Dexorange) as negative oral syrup to suppress the fluid signals from GIT. The ideal amount of hematinic syrup required to suppress the signal is not unknown; however, we used 30 mL since it is well tolerated by most patients. However, complete suppression of the GIT signal could not be achieved with only the use of hematinic syrup as negative oral contrast.

Another way to suppress the fluid signal from stomach and duodenum is to use drugs that could reduce gastric secretion. Clarke et al conducted a meta-analysis on effect of ranitidine versus proton pump inhibitors on gastric secretions. They concluded that premedication with ranitidine was more effective than proton pump inhibitors in reducing the volume of gastric secretions.⁸ Ranitidine is a specific rapidly acting histamine H₂-antagonist. It inhibits basal and stimulated secretion of gastric acid, reducing both the volume and the acid and pepsin content of the secretion. Absorption of ranitidine after oral administration is rapid and peak plasma concentrations are usually achieved within 2 to 3 hours of administration. The bioavailability of ranitidine is consistently ~50% and it is not extensively metabolized. The absorption and subsequent bioavailability of ranitidine are quicker than omeprazole.^{9,10} Bowes et al demonstrated the effectiveness of single oral dose of 300 mg of ranitidine to suppress the GIT signal in MRCP. However, Torres et al in their trial concluded that the image quality obtained with ranitidine was similar to those obtained with only fasting and that negative oral contrast (gadolinium solution) was superior in comparison to ranitidine.^{2,11}

Our study demonstrated that use of ranitidine increases the image quality by improving the suppression of GIT fluid as compared with use of only hematinic syrup as negative

oral contrast (►Figs. 4–7). The group that received both negative oral contrast and ranitidine had better mean GIT signal intensity score than that of the group that received only negative oral contrast (3 vs. 2.7) (p -value = 0.018). Duodenum was the frequent site to show bright signal in the GIT among both groups. Mohabir et al reported that use of 250 mL of commercially available pineapple juice as negative oral contrast decreased the duodenal signal intensity. However, pineapple juice did not decrease the signal intensity in the stomach.⁶ In our study, we observed that the group that received both ranitidine and hematinic syrup had decreased signal intensities in both duodenum and stomach. Govindarajan et al used date syrup as negative oral contrast and compared the image quality of pre- and post-oral contrast images of the same patients. The mean score of

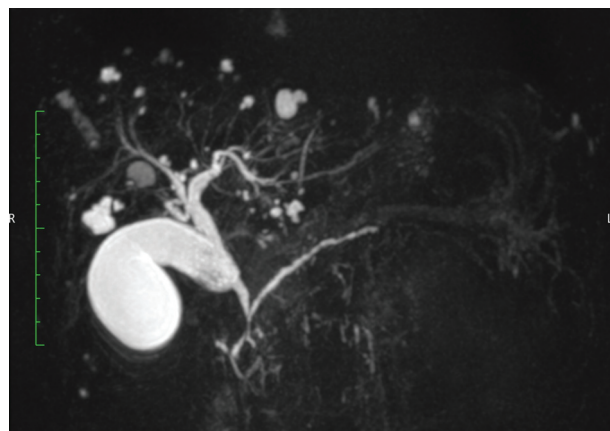


Fig. 4 Maximum-intensity projection image of three-dimensional magnetic resonance cholangiopancreatography sequence of a 48-year-old patient with cholelithiasis and multiple hepatic cysts who received both oral contrast and ranitidine. There was no significant signal intensity from the gastrointestinal tract and both the reviewers scored the gastrointestinal tract signal intensity score as 4.

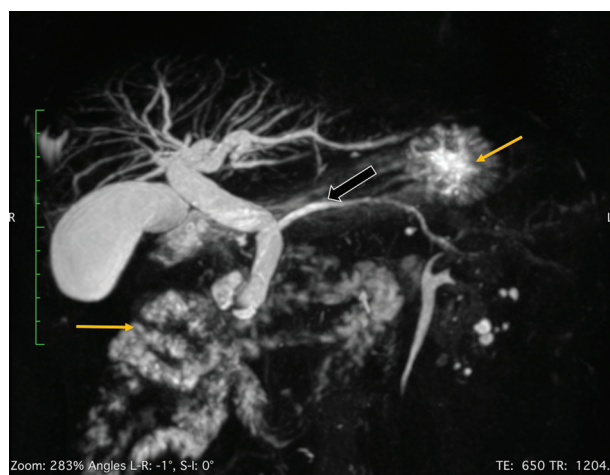

Fig. 5 Maximum-intensity projection image of three-dimensional magnetic resonance cholangiopancreatography sequence of a 70-year-old patient with periampullary neoplasm who received only negative oral contrast. The biliary radicles, common bile duct, and pancreatic duct (block arrow) are dilated. There is high signal intensity in the stomach and small bowel (thin arrow) that was scored as 2 by both the reviewers.

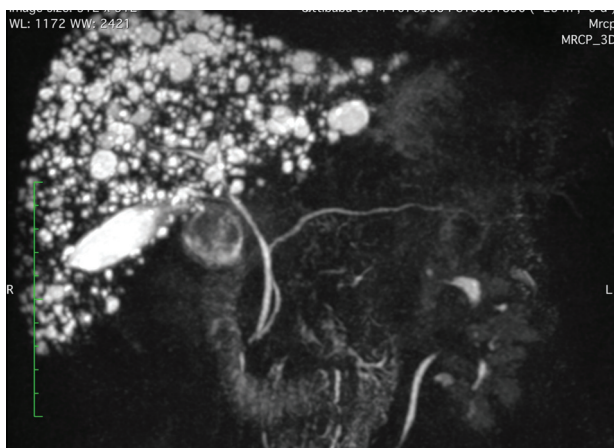


Fig. 6 Maximum-intensity projection image of three-dimensional magnetic resonance cholangiopancreatography sequence of a 37-year-old patient with Caroli's disease who received both oral contrast and ranitidine. One reviewer scored the gastrointestinal tract signal intensity score as 4, while the other reviewer gave a score of 3.

the post contrast images was significantly higher than that of the precontrast images (1.5 vs. 2.6; score range: 1–3). In our study, the mean score of the group that received only negative oral contrast (hematinic syrup) had lower mean gastrointestinal signal intensity score (2.7; score range: 1–4).

Bowes et al studied the effect of single oral dose of 300 mg of ranitidine on the effect of MRCP image quality in 35 healthy volunteers. All participants underwent MRCP after intake of placebo in 1 day and ranitidine (administered 2–3 hours prior to MRCP) in another day with 5 days of interval between the two scans. The grading of image quality was performed using visual analogue scales on a 100 mm scale (score range: 0–100). They compared the mean score of the images obtained using placebo with that of the images obtained after ranitidine ingestion and found significant improvement in the contrast effect in the ranitidine images. We were not able to compare only ranitidine ingestion versus only negative oral contrast (hematinic syrup) for patient preparation in our study, since it would require crossover trial design, which has many practical problems. If we carry out a randomized control trial comparing only ranitidine ingestion versus only negative oral contrast (hematinic syrup), then the patients who received only ranitidine will be denied the standard of care (i.e., negative oral contrast); since prior to this study our standard protocol for MRCP preparation was administration of oral contrast for all patients.

Mohabir et al, Govindarajan et al, and Bowes et al reported improvement in structure visualization score. In our study, we did not observe any significant difference in mean structure visualization score of various parts of the pancreaticobiliary system. First and important reason could be because our study population was not homogenous in that it included patients who were apparently normal and patients who had obstructed pancreaticobiliary system. It is understandable that certain diseases affect the visualization of certain parts of pancreaticobiliary system; for example, in a case of periampullary carcinoma the ampulla may not

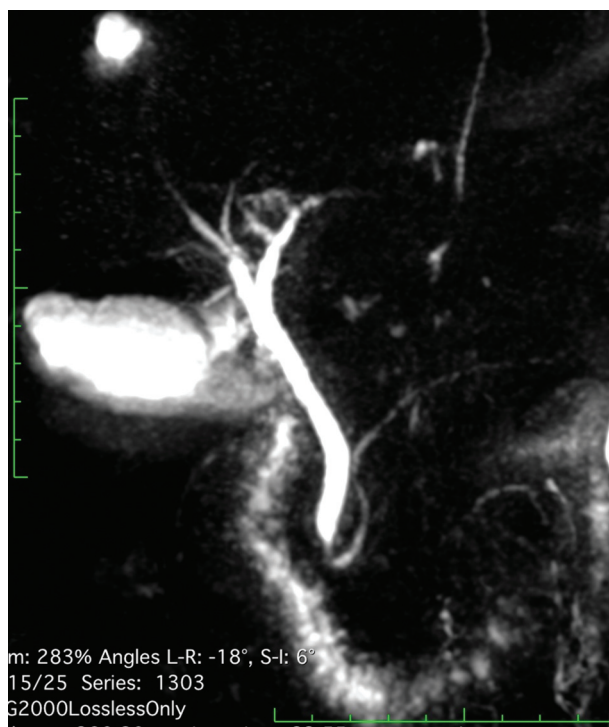

Fig. 7 Maximum-intensity projection image of three-dimensional magnetic resonance cholangiopancreatography sequence of a 65-year-old patient with carcinoma of gallbladder who received only oral contrast. The signal intensity in the small bowel was scored as 3 by both the reviewers.

be visualized clearly; however, the pancreatic duct and biliary system proximal to ampulla are dilated and thus visualized prominently. So, in diseased individuals, ideally a crossover study is required to compare structure visualization score. Another reason could be that we relied more on 3D sequence to score the structure visualization score, as it is superior in depicting the individual parts of pancreaticobiliary ductal system, while two-dimensional sequences and MIP images were used for scoring the image quality in majority of the studies reported in literature.^{2,5–7,12–16}

One of the main limitations of our study was that the assessment of image quality was subjective and no quantitative method was used; however, the interobserver agreement between the readers was acceptable. Another drawback was that our study population included patients with different pathologies in various age group as healthy volunteers in similar age group or patients with same pathology would be preferable in ideal situation.

Conclusions

- Combined use of hematinic syrup and ranitidine increases the image quality by improving the suppression of gastrointestinal fluid signal as compared with the use of only hematinic syrup as negative oral contrast.
- The interobserver agreement between the readers for qualitatively assessing the image quality was acceptable.

Conflict of Interest

None declared.

References

- 1 Bittman ME, Callahan MJ. The effective use of acai juice, blueberry juice and pineapple juice as negative contrast agents for magnetic resonance cholangiopancreatography in children. *Pediatr Radiol* 2014;44(07):883–887
- 2 Bowes MT, Martin DF, Melling A, et al. Single dose oral ranitidine improves MRCP image quality: a double-blind study. *Clin Radiol* 2007;62(01):53–57
- 3 Frisch A, Walter TC, Hamm B, Denecke T. Efficacy of oral contrast agents for upper gastrointestinal signal suppression in MRCP: a systematic review of the literature. *Acta Radiol Open* 2017;6(09):2058460117727315
- 4 Renzulli M, Biselli M, Fabbri E, et al. What is the best fruit juice to use as a negative oral contrast agent in magnetic resonance cholangiopancreatography? *Clin Radiol* 2019;74(03):220–227
- 5 Arrivé L, Coudray C, Azizi L, et al. [Pineapple juice as a negative oral contrast agent in magnetic resonance cholangiopancreatography]. *J Radiol* 2007;88(11 Pt 1):1689–1694
- 6 Mohabir S, Pitcher RD, Perumal R, Goodier MDM. The efficacy of pineapple juice as a negative oral contrast agent in magnetic resonance cholangiopancreatography. *SA J Radiol* 2020;24(01):1875 <https://www.ncbi.nlm.nih.gov/pmc/articles/PMC7433279/> cited 2020Nov28 [Internet]
- 7 Govindarajan A, Lakshmanan PM, Sarawagi R, Prabhakaran V. Evaluation of date syrup as an oral negative contrast agent for MRCP. *AJR Am J Roentgenol* 2014;203(05):1001–1005
- 8 Clark K, Lam LT, Gibson S, Currow D. The effect of ranitidine versus proton pump inhibitors on gastric secretions: a meta-analysis of randomised control trials. *Anaesthesia* 2009;64(06):652–657
- 9 Aboofazeli A, Shafaati A. Comparative bioavailability of ranitidine tablets in healthy volunteers. *Iran J Pharm Res* 2010;0(01):1–6
- 10 Hendolin H, Suojäranta-Ylinen R, Alhava E. Effect of single-dose omeprazole and ranitidine on gastric juice acidity and volume in patients undergoing laparotomy. *Acta Anaesthesiol Scand* 1993;37(05):484–487
- 11 Torres LR, Bretas EAS, Sauaia Filho GA, Soares AF de F, D'Ippolito G. The role of ranitidine in the enhancement of imaging quality in magnetic resonance cholangiopancreatography. *Radiol Bras* 2013;46(02):75–82
- 12 Morita S, Ueno E, Masukawa A, et al. Prospective comparative study of negative oral contrast agents for magnetic resonance cholangiopancreatography. *Jpn J Radiol* 2010;28(02):117–122
- 13 Rinck PA, Myhr G, Smevik O, Borseth A. Oral magnetic particles as MR contrast agents for the gastrointestinal tract. *RoFo Fortschr Geb Röntgenstr Nuklearmed* 1992;157(06):533–538
- 14 Lorenzen M, Wedegartner U, Fiehler J, Adam G. Quality rating of cholangiopancreatography with oral application of iron oxide particles. *RoFo Fortschr Geb Röntgenstr Nuklearmed* 2003;175(07):936–941
- 15 Ghanaati H, Rokni-Yazdi H, Jalali AH, Abahashemi F, Shakiba M, Firouznia K. Improvement of MR cholangiopancreatography (MRCP) images after black tea consumption. *Eur Radiol* 2011;21(12):2551–2557
- 16 Riordan RD, Khonsari M, Jeffries J, Maskell GF, Cook PG. Pineapple juice as a negative oral contrast agent in magnetic resonance cholangiopancreatography: a preliminary evaluation. *Br J Radiol* 2004;77(924):991–999