



# Vulnerable Carotid Artery Plaques in Asymptomatic Patients—A Narrative Review

Zia Ur Rehman<sup>1</sup>

<sup>1</sup> Division of Vascular Surgery, Aga Khan University Hospital, Karachi, Pakistan

Address for correspondence Zia Ur Rehman, FCPS, ChM, Division of Vascular Surgery, Aga Khan University Hospital, Stadium Road, P.O. Box 3500, Karachi 74800, Pakistan (e-mail: ziaur.rehman@aku.edu).

Arab J Intervent Radiol 2022;6:21–24.

## Abstract

Over the last two decades, medical management of carotid artery patients has improved significantly. Most patients remain stable on best medical therapy (BMT), making interventions unnecessary in all patients. “Selective” intervention is advocated for only those few patients who are having vulnerable or unstable carotid artery plaques. Literature search was done to explore current concept and role of available investigations to identify vulnerable carotid plaques. Vulnerable plaque is defined as those plaques having active inflammation, high large necrotic lipid content, neovascularity, thin capsule, surface irregularity, or intraplaque hemorrhage. Ultrasound (US) is the simple, noninvasive, cost-effective investigation to differentiate soft (echolucent) from fibrocalcified (echogenic) plaques. It can also comment on other high-risk plaque features such as plaque volume and area. Contrast-enhanced US can visualize neovascularization and plaque surface irregularities better than conventional US. Computed tomography is limited in identifying most high-risk plaque features and is not useful. High-resolution magnetic resonance imaging is the most accurate and externally validated investigation to characterize most high-risk plaque components. Positron emission tomography has emerged as the most promising dynamic investigation to identify and quantify inflammatory plaques and will be clinically very useful in decision making.

## Keywords

- ▶ carotid
- ▶ asymptomatic
- ▶ stenosis
- ▶ vulnerable plaque
- ▶ stroke

## Introduction

Stroke is one of the leading reasons of death in world<sup>1</sup> and about one-third of strokes are ischemic. About 80% of ischemic strokes are due to carotid bifurcation occlusive disease.<sup>2</sup> Traditionally, degree of carotid stenosis is considered as the most important risk factor for stroke, the higher the degree, the higher is the risk. One to three percent of the adults have moderate-to-severe carotid artery stenosis and incidence of such stenosis increases with advancing age. This is a common

observation that most patients with moderate-to-high-grade carotid artery stenosis remain stable, whereas others become symptomatic leading to stroke and transient ischemic attacks. Medical management of carotid artery disease patients has significantly improved over the last two decades. There are newer antiplatelet and statins medications available that are routinely prescribed to almost all patients. It has also been observed over these decades that most patients remain stable on the modern best medical therapy making intervention in “all” patients unnecessary. This

published online  
June 15, 2022

DOI <https://doi.org/10.1055/s-0042-1750108>.  
ISSN 2542-7075.

© 2022. The Pan Arab Interventional Radiology Society. All rights reserved.

This is an open access article published by Thieme under the terms of the Creative Commons Attribution-NonDerivative-NonCommercial-License, permitting copying and reproduction so long as the original work is given appropriate credit. Contents may not be used for commercial purposes, or adapted, remixed, transformed or built upon. (<https://creativecommons.org/licenses/by-nc-nd/4.0/>)

Thieme Medical and Scientific Publishers Pvt. Ltd., A-12, 2nd Floor, Sector 2, Noida-201301 UP, India

“selective” approach is contrary to the lessons learned from randomized controlled trials conducted in 1990s that have shown performing carotid endarterectomy in asymptomatic patients with high-grade (60–99%) carotid artery stenosis was more beneficial over best medical therapy in reducing future stroke risk.<sup>3</sup> Carotid atherosclerosis is a spectrum of disease ranging from benign, stable plaques to vulnerable or unstable plaques. Patients with unstable plaques are at high risk of having stroke and these patients need to be identified to offer interventions to minimize stroke risk that can be either carotid endarterectomy or carotid stenting. This “selective” approach can avoid many unnecessary interventions. In this article, we will discuss pathophysiology of vulnerable plaque, role, and limitations of currently available investigations to identify them.

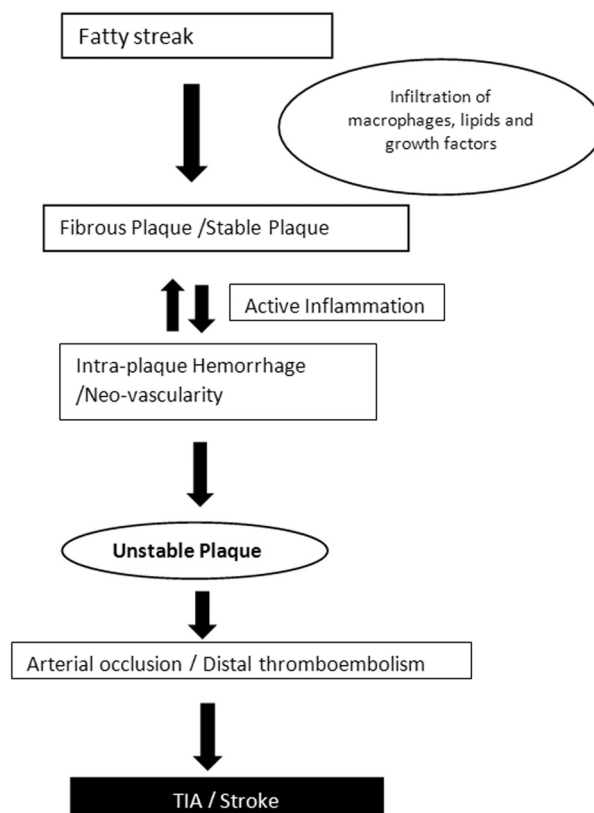
### What is “Vulnerable Carotid Plaque”?

“Vulnerable atherosclerotic plaque” concept was coined first when it was observed that many patients with noncritical coronary artery stenosis were experiencing adverse myocardial ischemic events.<sup>4</sup> It was recognized that plaque characteristics other than stenosis were important. Those characteristics were composition of the plaque, its capsule, and surface irregularities. The same concept has been applied to carotid artery disease patients in the decision making for revascularization. Inflammation is the hallmark of vulnerable plaques. Atherosclerotic plaques become unstable due to ongoing inflammation.<sup>5</sup> This statement is supported by histopathology reviews of the dissected plaque specimens of the patients undergoing carotid endarterectomy for symptomatic disease.<sup>6</sup> Carotid atherosclerosis starts as fatty streaks. Over time, there is infiltration of lipids and macrophages into it. There is amplification of multiple growth factors over time and increase in plaque size.<sup>7</sup> Due to active inflammation, there is hypervascularity in and around the plaque and new vessel formation. This can lead to intra-plaque hemorrhage with rapid increase in plaque size. This increase in size can either lead acute arterial occlusion or sudden plaque rupture with distal thromboembolism (→ Fig. 1).<sup>8</sup> Intraplaque hemorrhage is considered as the most important feature of an unstable plaque.<sup>9,10</sup> Other features are shown in → Fig. 2.

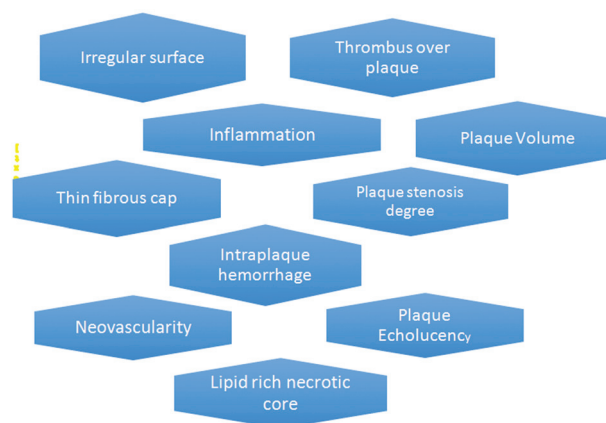
### Current Investigations to Identify Vulnerable Plaque

#### Ultrasound Assessment of Carotid Plaque

On US, carotid plaques appear either as echogenic (white) or echolucent (black). Echogenic plaques have more of fibrous tissue and calcification, while echolucent plaques have higher ratio of lipid content or intraplaque hemorrhage. Patients with echogenic plaques had been reported with less ipsilateral cerebral ischemic symptoms pointing to their stable nature compared with patients having echolucent plaques.<sup>11–13</sup> Based on plaque echotexture, carotid plaques have been classified into four types<sup>14</sup> (→ Table 1). Although US is widely available, cost-effective, portable, and free of radiation, it is operator dependent. Visual assessment of plaque echo texture can be confounded by US machine



**Fig. 1** Flow diagram showing pathogenesis of an unstable carotid plaque. TIA, transient ischemic attack.



**Fig. 2** Various features of high-risk plaque, along with degree of stenosis plaque composition, which is important in decision making.

setting and operator’s experience. Objective assessment of plaque echogenicity using median gray scale is more accurate. el-Barghouty et al noted that dense calcified plaques with gray scale median more than 32 were statistically significantly less associated with computed tomography detected brain infarcts compared with echolucent plaque with gray scale less than or equal to 32.<sup>15,16</sup> Plaques become unstable due to ongoing inflammation and neovascularity. Conventional US is limited in imaging new vessels in and

**Table 1** Gray Weale visual classification of carotid plaques

|                     |   |
|---------------------|---|
| Type 1 <sup>a</sup> | Pure hypoechoic                         |
| Type 2 <sup>a</sup> | Hypoechoic with small hyperechoic areas |
| Type 3              | Hyperechoic with small hypoechoic areas |
| Type 4              | Pure hyperechoic                        |

<sup>a</sup>More associated with neurological symptoms.

around the plaque, while contrast-enhanced US overcome this limitation and have been shown superior in identifying this feature.<sup>17</sup> Intima-media thickness is considered an important marker of atherosclerosis. Contrast-enhanced US is also very useful in determining it. Conventional US is not good in identifying plaque surface and its irregularity, but its accuracy is improved by contrast-enhanced US using micro-bubbles.<sup>18</sup> Another high-risk plaque feature is plaque volume. Assessment of plaque area and volume is considered a useful method of identifying high-risk plaque. Carotid plaques progress more rapidly in longitudinal direction than in its thickness. This can be accurately detectable by three-dimensional US compared with conventional US.<sup>19</sup> Main limitation of US is its inability to differentiate intraplaque hemorrhage from central necrotic lipid component.

### High-Resolution MRI

High-resolution magnetic resonance imaging (MRI) has emerged as most valuable investigation in evaluating high-risk carotid plaque features. It can visualize both vessel lumen and vessel wall and have good soft tissue contrast discrimination. MRI is a noninvasive investigation that is free of ionizing radiation and has been well externally validated. This can clearly differentiate between soft from fibrocalcified plaques and image many high-risk plaque features such as intraplaque hemorrhage, lipid-rich necrotic core, neovascularization, and its capsule.<sup>20,21</sup> A high correlation between histological features of various components of dissected carotid endarterectomy specimens for symptomatic patients and MRI finding has been reported. MRI is currently considered best in imaging modality for intraplaque hemorrhage.<sup>22</sup> Gupta et al in a meta-analysis showed MRI can predict future risk of stroke in patients with unstable carotid artery plaque.

They analyzed three characteristics of vulnerable plaque (intraplaque hemorrhage, thin/ruptured plaque capsule, and intraplaque necrotic lipid core) images by MRI by different studies. They found these characteristics were highly suggestive of future ipsilateral cerebral neurological ischemic symptoms.<sup>23</sup> It has good reproducibility. Carotid plaque progression can also be readily followed with MRI

### Computed Tomography Scan

Computed tomography (CT) is a noninvasive investigation that uses ionizing radiations and contrast media that may be damaging for patient with borderline kidney functions. This is best imaging modality for detecting calcification and can differentiate soft from fibrocalcified plaques. CT scan cannot identify acute phase plaque features such as intraplaque hemorrhage, active inflammation, neovascularization, and capsule thickness (► **Table 2**). It also does not provide information about biological status of the plaque.

### Positron Emission Tomography

Inflammation is the hallmark of high-risk plaque. Over the last few years, positron emission tomography-computed tomography (PET-CT) scan has emerged as potentially useful investigation in identifying high-risk inflammatory plaques.<sup>24</sup> This can also quantify plaque inflammation. Up to now, imaging of inflammatory plaques was not done routinely in clinical practice, it was used for research purpose, but this is now coming as a good clinical tool. PET uses radiolabeled ligands and tracers that bind to specific targeted molecules. These radiolabeled ligands gather in a specific area providing fair idea about metabolic activity of that tissue bed.<sup>25</sup> PET provides dynamic images of intraplaque activity compared with other imaging modalities that focus only on anatomical features of vulnerable plaque. Radiolabeled fluorodeoxyglucose (FDG) is the most used radiotracer used in PET/CT scan. This is readily taken up by cells with active inflammation. The relationship between uptake of FDG and composition of carotid plaque has been evaluated by several studies<sup>26</sup>; and a linear correlation was observed. This is most precise and consistent investigation for identifying a vulnerable inflammatory plaque.

**Table 2** Strengths and limitations of various investigations in evaluating various components of vulnerable carotid artery plaque

| Characteristics      | LRNC | Intraplaque hemorrhage | Plaque volume | Thin fibrous cap | Neovascularization | Inflammation | Plaque echolucency | Surface irregularity |
|----------------------|------|------------------------|---------------|------------------|--------------------|--------------|--------------------|----------------------|
| US                   | –    | –                      | ++            | +                | –                  | –            | ++                 | –                    |
| Contrast US          | +    | –                      | +             | ++               | +++                | +            | +                  | ++                   |
| Three-dimensional US | –    | –                      | +++           | –                | –                  | –            | +                  | –                    |
| CT scan              | +/-  | +/-                    | +             | –                | –                  | –            | +                  | –                    |
| MRI                  | +++  | +++                    | ++            | ++               | ++                 | +            | –                  | ++                   |
| PET-CT scan          | –    | –                      | –             | –                | +                  | +++          | –                  | –                    |

Abbreviations: CT, computed tomography; LRNC, large necrotic lipid core; MRI, magnetic resonance imaging; PET-CT, positron emission tomography-computed tomography; US, ultrasound.

## Conclusion

Vulnerable plaques are having either active inflammation, intraplaque hemorrhage, thin capsule, large necrotic lipid core, neovascularity, or a large plaque area. US with contrast is useful investigation to identify these plaques but cannot differentiate between intraplaque hemorrhage and large necrotic lipid core. MRI is the investigation of choice in identifying most features of high-risk plaques including intraplaque hemorrhage, large necrotic lipid core, and surface irregularity. All features of vulnerable plaques are due to active inflammation and PET scan has emerged a promising dynamic investigation to image and quantify those inflammatory plaques.

### Author's Contribution

Z.U.R. was involved in study concept, investigation, and writing.

### Conflict of Interest

None declared.

## References

- Murray CJ, Lopez AD. Mortality by cause for eight regions of the world: global burden of disease study. *Lancet* 1997;349(9061):1269–1276
- Fontenelle LJ, Simper SC, Hanson TL. Carotid duplex scan versus angiography in evaluation of carotid artery disease. *Am Surg* 1994;60(11):864–868
- Endarterectomy for asymptomatic carotid artery stenosis. Executive Committee for the Asymptomatic Carotid Atherosclerosis Study. *JAMA* 1995;273(18):1421–1428
- Muller JE, Tofler GH, Stone PH. Circadian variation and triggers of onset of acute cardiovascular disease. *Circulation* 1989;79(04):733–743
- Naghavi M, Libby P, Falk E, et al. From vulnerable plaque to vulnerable patient: a call for new definitions and risk assessment strategies: Part I. *Circulation* 2003;108(14):1664–1672
- Redgrave JN, Lovett JK, Gallagher PJ, Rothwell PM. Histological assessment of 526 symptomatic carotid plaques in relation to the nature and timing of ischemic symptoms: the Oxford plaque study. *Circulation* 2006;113(19):2320–2328
- Ross R. The pathogenesis of atherosclerosis—an update. *N Engl J Med* 1986;314(08):488–500
- Ross R. Atherosclerosis—an inflammatory disease. *N Engl J Med* 1999;340(02):115–126
- Langsfeld M, Gray-Weale AC, Lusby RJ. The role of plaque morphology and diameter reduction in the development of new symptoms in asymptomatic carotid arteries. *J Vasc Surg* 1989;9(04):548–557
- Leahy AL, McCollum PT, Feeley TM, et al. Duplex ultrasonography and selection of patients for carotid endarterectomy: plaque morphology or luminal narrowing? *J Vasc Surg* 1988;8(05):558–562
- O'Holleran LW, Kennelly MM, McClurken M, Johnson JM. Natural history of asymptomatic carotid plaque. Five year follow-up study. *Am J Surg* 1987;154(06):659–662
- Polak JF, Shemanski L, O'Leary DH, et al. Hypochoic plaque at US of the carotid artery: an independent risk factor for incident stroke in adults aged 65 years or older. *Cardiovascular Health Study. Radiology* 1998;208(03):649–654
- Doonan RJ, Gorgui J, Veinot JP, et al. Plaque echodensity and textural features are associated with histologic carotid plaque instability. *J Vasc Surg* 2016;64(03):671–677.e8
- Gray-Weale AC, Graham JC, Burnett JR, Byrne K, Lusby RJ. Carotid artery atheroma: comparison of preoperative B-mode ultrasound appearance with carotid endarterectomy specimen pathology. *J Cardiovasc Surg (Torino)* 1988;29(06):676–681
- el-Barghouty N, Geroulakos G, Nicolaidis A, Androulakis A, Bahal V. Computer-assisted carotid plaque characterisation. *Eur J Vasc Endovasc Surg* 1995;9(04):389–393
- Spence JD, Eliasziw M, DiCicco M, Hackam DG, Galil R, Lohmann T. Carotid plaque area: a tool for targeting and evaluating vascular preventive therapy. *Stroke* 2002;33(12):2916–2922
- Coli S, Magnoni M, Sangiorgi G, et al. Contrast-enhanced ultrasound imaging of intraplaque neovascularization in carotid arteries: correlation with histology and plaque echogenicity. *J Am Coll Cardiol* 2008;52(03):223–230
- Saba L, Saam T, Jäger HR, et al. Imaging biomarkers of vulnerable carotid plaques for stroke risk prediction and their potential clinical implications. *Lancet Neurol* 2019;18(06):559–572
- Ainsworth CD, Blake CC, Tamayo A, Beletsky V, Fenster A, Spence JD. 3D ultrasound measurement of change in carotid plaque volume: a tool for rapid evaluation of new therapies. *Stroke* 2005;36(09):1904–1909
- Saam T, Cai JM, Cai YQ, et al. Carotid plaque composition differs between ethno-racial groups: an MRI pilot study comparing mainland Chinese and American Caucasian patients. *Arterioscler Thromb Vasc Biol* 2005;25(03):611–616
- Schindler A, Schinner R, Altaf N, et al. Prediction of stroke risk by detection of hemorrhage in carotid plaques: meta-analysis of individual patient data. *JACC Cardiovasc Imaging* 2020;13(2 Pt 1):395–406
- den Hartog AG, Bovens SM, Koning W, et al. Current status of clinical magnetic resonance imaging for plaque characterisation in patients with carotid artery stenosis. *Eur J Vasc Endovasc Surg* 2013;45(01):7–21
- Gupta A, Baradaran H, Schweitzer AD, et al. Carotid plaque MRI and stroke risk: a systematic review and meta-analysis. *Stroke* 2013;44(11):3071–3077
- Cocker MS, Mc Ardle B, Spence JD, et al. Imaging atherosclerosis with hybrid [18F]fluorodeoxyglucose positron emission tomography/computed tomography imaging: what Leonardo da Vinci could not see. *J Nucl Cardiol* 2012;19(06):1211–1225
- Small GR, Kazmi M, Dekemp RA, Chow BJ. Established and emerging dose reduction methods in cardiac computed tomography. *J Nucl Cardiol* 2011;18(04):570–579
- Choi YS, Youn HJ, Chung WB, et al. Uptake of F-18 FDG and ultrasound analysis of carotid plaque. *J Nucl Cardiol* 2011;18(02):267–272