




# Basilar Invagination in a Cat with Incomplete Ossification of the Atlas Treated by C1-C2 Arthrodesis

Jose Luis Fontalba-Navas<sup>1</sup>  Victoria Rodríguez-Gómez<sup>1</sup> Ignacio Calvo<sup>1</sup> Isidro Mateo-Pampliega<sup>1</sup>

<sup>1</sup>Neurology and Neurosurgery Department, Hospital Veterinario VETSIA, Leganés, Madrid, España

Address for correspondence Jose Luis Fontalba-Navas, DVM, PhD, ECVS Resident, Neurology and Neurosurgery Department, Hospital Veterinario VETSIA, C/Galileo n°3, 28914, Leganés, Madrid, España (e-mail: joseluisfontalba@gmail.com; jlfontalba@vetsia.es).

VCOT Open 2022;5:e78–e82.

## Abstract

Basilar invagination is a poorly described condition in veterinary medicine where the tip of the odontoid process projects into a normal foramen magnum. This report describes the clinical, radiological, and surgical treatment of a basilar invagination associated with instability of the atlantoaxial joint due to an incomplete ossification of the atlas in a cat. At presentation, the clinical signs included obtundation and non-ambulatory tetraparesis with postural reaction deficits in hindlimbs and left forelimb. Radiographic examination revealed cranial displacement of the axis with the dens impinging the basioccipital bone, and computed tomography confirmed the impaction of the axis on the atlas due to an incomplete ossification of the left half of the neural arch with the intercentrum. Magnetic resonance imaging confirmed severe spinal cord compression and myelopathy at this level. The cat underwent surgery for atlantoaxial arthrodesis using a ventral approach to C1-C2. Recovery after surgery was uneventful. Follow-up a year after surgery finds the cat free of neurological signs. An incomplete ossification of the atlas can lead to atlantoaxial instability and basilar invagination in the cat. Diagnosis can be made based on its radiological characteristics, the cranial displacement of the odontoid process in contact with the basioccipital bone being its main feature. This case was successfully treated by atlantoaxial arthrodesis.

## Keywords

- ▶ cat
- ▶ ossification defects
- ▶ feline occipitoatlantoaxial malformations
- ▶ atlantoaxial arthrodesis

## Introduction

Occipitoatlantoaxial malformations (OAAM) are congenital defects affecting the occipital bone, the atlas and the axis that have been occasionally described in the cat.<sup>1–3</sup> Congenital hypoplasia, incomplete ossification or agenesis of the arch of the atlas have been documented in some species including humans,<sup>4</sup> and dogs,<sup>5–7</sup> but not in cats. They are considered a developmental failure of chondrogenesis which may range from partial clefts to total agenesis of the arch, and they are frequently associated with atlantoaxial (AA) instability or OAAM due to an abnormal development of the bones and ligaments of this joint.<sup>4–7</sup> The ossification of the atlas–axis

complex has been studied in the dog but not the cat.<sup>8</sup> However, given that gestation time and prenatal development are very similar in cats, it seems reasonable to assume that ossification of the atlas is comparable in both species. In humans, congenital aplasia or hypoplasia of the atlas is described as cause of cranial displacement of the C2 vertebral body, with the odontoid process extending into the normally formed foramen magnum, causing compression of the medulla and the first spinal cord segments. This defect has been named basilar invagination (BI) which can also be caused by other malformations affecting the osseous structures of the craniovertebral junction, such as atlanto-occipital assimilation, hypoplasia of the atlas, basioccipital hypoplasia and occipital condylar

received

July 5, 2021

accepted after revision

December 19, 2021

DOI <https://doi.org/>

10.1055/s-0042-1750058.

ISSN 2625-2325.

© 2022. The Author(s).

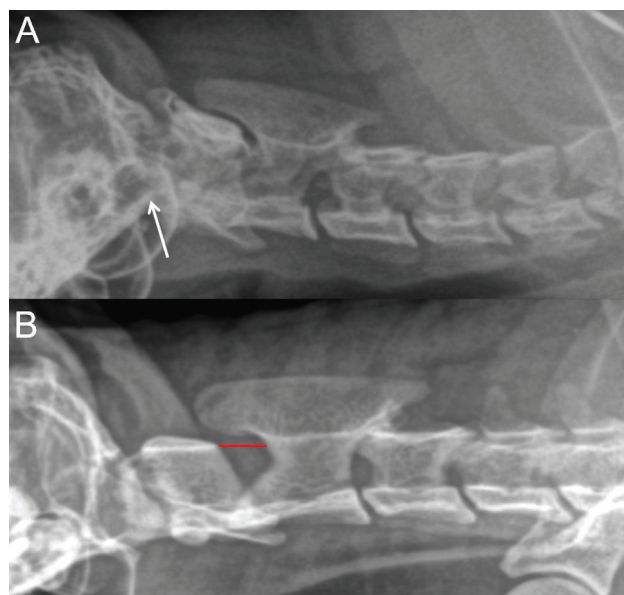
This is an open access article published by Thieme under the terms of the Creative Commons Attribution License, permitting unrestricted use, distribution, and reproduction so long as the original work is properly cited. (<https://creativecommons.org/licenses/by/4.0/>)

Georg Thieme Verlag KG, Rüdigerstraße 14, 70469 Stuttgart, Germany

hypoplasia.<sup>9,10</sup> Although recognized as a consequence of numerous craniocervical junction abnormalities, BI has only been described once, affecting a dog.<sup>6</sup> Diagnostic imaging, using computed tomography (CT) and magnetic resonance imaging (MRI), helpful in the diagnosis and surgical planning in cases of OAAM, incomplete ossification of the atlas and BI.<sup>6,9,10</sup> A combination of six radiological parameters (C1-C2 angle, C1-C2 overlap, AA distance, dens-to-axis length ratio, ventral compression index and clivus canal angle) can also be of diagnostic help if AA instability is suspected.<sup>11</sup> The definitive treatment for BI is surgical decompression and stabilization, particularly if neurologic deficits are the consequence of the compression of the cervicomedullary junction.<sup>9,10</sup> In humans, BI is frequently reducible with traction and posterior cervical approaches are used for decompression, stabilization and fusion. If the BI remains not reducible an anterior decompressive approach removing the anterior ring of the atlas and the odontoid process may be necessary prior to posterior occipito-cervical stabilization.<sup>9</sup> Applying similar considerations in dogs and cats, several surgical approaches for AA joint stabilization and decompression have been used, whereby the ventral approach seems preferable, providing better access to the area of the odontoid process and allowing rigid fixation of the atlanto-occipital joint.<sup>12</sup> This report describes clinical and radiological features and surgical treatment of a BI, associated with instability of the AA joint due to incomplete ossification of the atlas in a cat.

## Case Description

A 5-month-old 2-kg male indoor domestic short-hair cat presented for neurological evaluation. Acute onset and progressive tetraparesis and obtundation over the last month were reported. The cat was treated with meloxicam (Metacam, Boehringer Ingelheim, Ingelheim/Rhein, Germany) by the referring veterinarian with partial improvement but presented with acute relapse 4 weeks later, becoming suddenly non-ambulatory and tetraparetic. Deterioration as a consequence of minor or unobserved trauma could be not ruled out. Complete bloodwork and electrocardiogram revealed no abnormalities. Neurological examination resulted in depressed mental status, non-ambulatory tetraparesis with postural reaction deficits in both pelvic and the left thoracic limb and normal segmental spinal reflexes. No cranial nerve deficits were observed, and severe pain was elicited with manipulation of the cervical spine. Neuroanatomical lesion localization was considered focal or diffuse in the brainstem. Differential diagnoses included congenital malformations (i.e. OAAM or AA instability), inflammatory diseases (i.e. feline infectious peritonitis, feline leukemia virus or bacterial encephalomyelitis) or less probably neoplasia. Radiographic study of the cervical spine revealed a complex OAAM with rostral displacement of the axis over the atlas, with the odontoid process in contact with the basioccipital bone. The space between the lamina of the atlas and spinous process of the axis was severely reduced (►Fig. 1). These findings were compatible with congenital malformation of the occipitoatlantoaxial joint. Computed tomography (Toshiba Astelion CBT-024A, Toshiba Medical Systems Corporation,

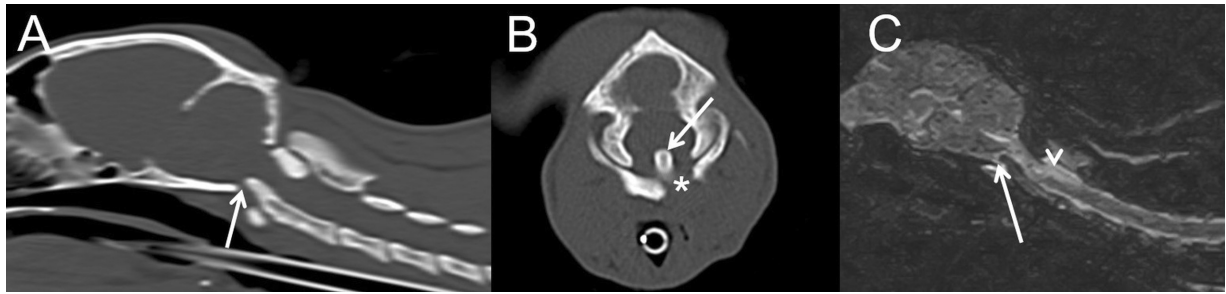


**Fig. 1** Lateral radiography in neutral position of the affected cat (A) and normal age-control cat (B). Note the narrowed distance between lamina of C1 and spinous process of C2 in A compared with the normal cat (red line in B). Also note cranial impingement of the odontoid process with the basioccipital bone (arrow in A) and the close contact between the atlas and occipital bone.

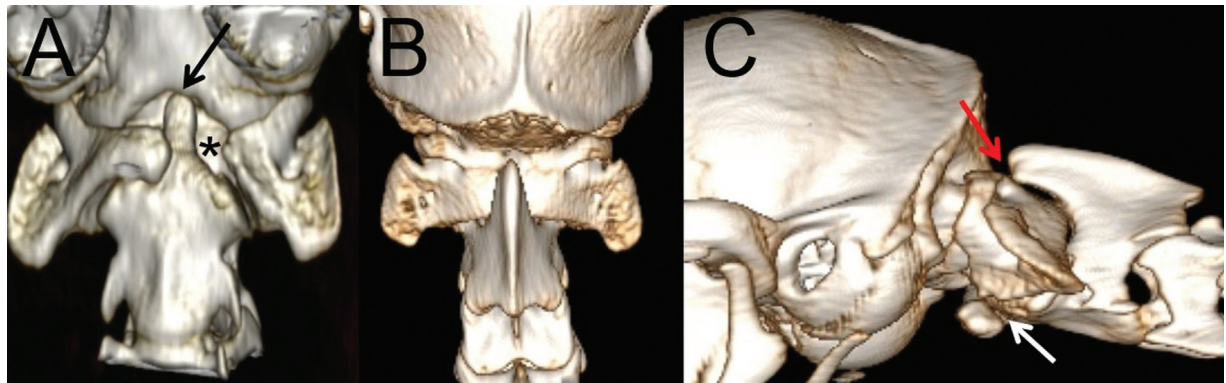
Shimoishigami, Otawara City, Tochigi Prefecture, Japan) confirmed the abnormal position of the AA joint and the cranial displacement of C2 causing the radiographic overlapping of the axis in the atlas causing severe stenosis of the vertebral canal (►Fig. 2A). Basilar invagination was evident as the odontoid process was rostrally displaced over the atlas in contact with the basioccipital bone (►Fig. 2A). This displacement, caused by a congenital osseous defect between the left wing and the body of the atlas, was suspected to be due to an incomplete fusion of the left half of the neural arch with the interarcum (►Figs. 2B and 3). Immediately after CT, MRI (Hitachi Airis MR-WS-12, Hitachi Medical Systems [FUJIFILM Healthcare España S.L.], Av. de Manoteras, Madrid, Spain) of the cervical spine and brain was performed confirming severe compression of the medulla and first cervical spinal cord segments at the craniovertebral junction due to the cranio-dorsal displacement of the dens of the axis. The compressed spinal cord segments exhibited a diffuse hyperintense signal in T2-weighted images and a non-enhancing isointense signal in T1-weighted images, extending caudally to the C3 level (►Fig. 2C). These imaging findings were consistent with the diagnosis of BI and AA instability due to a defect in the left ossification centre of the body of the atlas. Because of clinical progression and the instability of the AA joint, surgical decompression and stabilization were elected. The cat received preoperative analgesia with methadone (Dechra Veterinary Products SLU, Barcelona, Spain) and meloxicam (Metacam, Boehringer Ingelheim, Germany).

## Surgical Technique

A routine ventral surgical approach to the AA joint was performed, exposing the C2 vertebral body and the abnormal



**Fig. 2** Sagittal reconstruction (A), transverse image at the level of the odontoid process (B), computed tomographic images and sagittal T2-weighted magnetic resonance image (C). Note the rostradorsal impingement of the odontoid process near to the basioccipital bone (arrows) and the close contact between the lamina of C1 and spinous process of C2. Also note the defect in the ossification of the left aspect of the vertebral body of the atlas (asterisk). Severe myelopathy is observed as a diffuse hyperintense lesion affecting C1 and C2 spinal cord segments (arrowhead).



**Fig. 3** Ventral (A), dorsal (B), and left lateral (C) three-dimensional computed tomography reconstruction images of the occipitoatlantoaxial joint showing the defect in the ossification of the left aspect of the vertebral body (asterisk in A and white arrow in C), the rostral impingement of the odontoid process (black arrow) and the close contact between the lamina of C1 and spinous process of C2 (red arrow).

ventral arch of the C1, with incomplete ossification on the left side of the vertebral body. In this area, the spinal cord was covered by a thin fibrous membrane which was easily depressible. The C1/C2 joint capsule was incised with a number 11 surgical blade to allow the curettage of the joint surfaces with the aid of a Volkmann curette to promote arthrodesis. The AA overlapping was reduced applying gentle traction and a trans-articular positive profile pin (1.2 mm) was placed in the right vertebral bodies of the atlas and axis, as previously described,<sup>1,2,12</sup> avoiding penetration into the spinal canal. Implant placement was achieved using the described optimal safe implantation corridors.<sup>13</sup> Two 1.5 mm self-tapping screws were then placed in the atlas, the first on the ventral tubercle (which depth was 4.5 mm) and the second on the right lateral aspect of the intact vertebral body (which measured 3.5 mm thickness). Another two self-tapping 1.5 mm screws were placed in the vertebral body of the axis (with ~ 4.5 mm bone thickness at the midline). All implants were transfixed with polymethylmethacrylate cement (CMW3—Gentamicine—DePuy). Postoperative orthogonal radiographs and CT scans were used to verify correct joint alignment and correct placement of the implants (—Fig. 4).

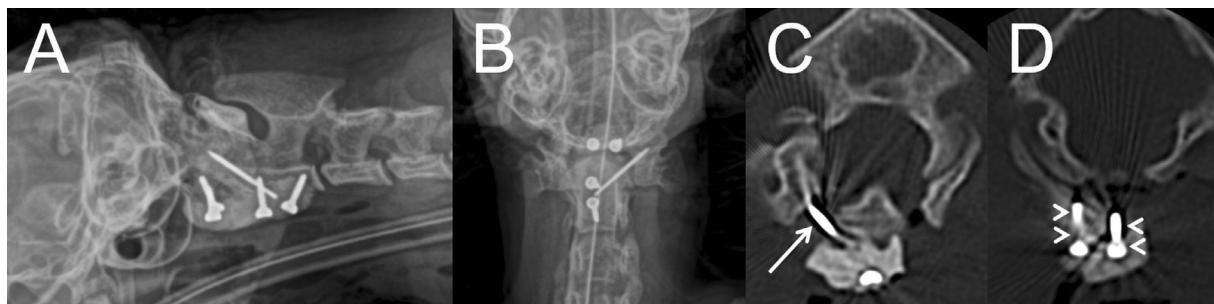
### Follow-Up

The cat was hospitalized for 3 days after surgery receiving methadone for the first 2 days and meloxicam for a week.

Forty-eight hours following surgery the patient showed remarkable neurological improvement, recovering normal mentation and the ability to maintain sternal recumbency with voluntary movement in all four extremities after discontinuation of methadone. The cat was discharged on the 3rd day, with non-ambulatory tetraparesis which gradually improved to ambulatory tetraparesis by week 1. Two months following surgery the cat had completely recovered with a normal neurological status. One-year post-surgery, the patient is fully functional with absence of any neurological signs.

### Discussion

There are multiple congenital malformations that can affect the craniocervical junction, including Chiari-like malformations, atlanto-occipital overlapping, AA instability, OAMM, dorsal AA compressive bands or dorsal AA ligament hypertrophy and dens abnormalities.<sup>14</sup> Few cases are reported of cats with AA instability and OAMM hypoplasia of the dens. Trauma that resulted in a bone fracture or damage of supporting structures has been considered their main cause.<sup>2,3,15,16</sup> In humans, BI is often a result of a disorder where the bone tissue remains abnormal such as atlas hypoplasia or an incomplete ring of C1 with spreading of the lateral masses and atlanto-occipital assimilation.<sup>9</sup> In humans, two different groups of BI are identified. In group



**Fig. 4** Lateral (A) and ventral (B) postoperative radiographies and transverse computed tomographic images at the level of the atlantoaxial joint (C) and body of the atlas (D). Note correct alignment of the atlantoaxial joint with reduced impaction and basilar invagination. Also note correct implant placement with one positive profile pin at the right atlantoaxial junction (arrow) and two screws in the body of the atlas (arrowheads).

A, BI is characterized by AA instability manifested by an abnormal increase in the atlantodental or clidodental interval along with rostral displacement of the odontoid process into the foramen magnum.<sup>17</sup> In group B, patients exhibit no evidence of craniovertebral junction instability when evaluated by the conventional parameter of an abnormal increase in the atlantodental interval.<sup>18</sup> Basilar invagination has not been previously described in cats; however, the case presented here would fall into group A due to the increase of the atlantodental interval (the horizontal distance between the ventral arch of the atlas and the dens of the axis) in similarity to the previously reported case in a dog.<sup>6</sup> In dogs and cats, radiographical signs of AA instability and subluxation included dorsal displacement of the body of the axis over the atlas and a reduced distance of the spinous process of the axis from the lamina of the atlas.<sup>11,12</sup> Such displacement is usually caused by the absence of the ligaments that join the dental axis to the occiput thus inducing the abnormal angle of the joint.<sup>11</sup> However, as exemplified in the cat described here, AA instability and secondary BI may also develop based on a different pathological mechanism. The defect in the ossification of the body of the atlas resulting in loss of support of the joint with its subsequent collapse, causing the rostral displacement of the odontoid process into the foramen magnum (namely BI or telescoping of the axis into the atlas and occiput) but without dorsal movement of the axis in respect to the atlas; this, because the odontoid process and its ligaments were apparently normal. There are several reports describing ossification defects in the atlas of dogs, causing AA instability.<sup>5-7</sup> As in humans, most affect the dorsal arch of the atlas, but abnormalities affecting the sutures of the intercentrum have also been described.<sup>7</sup> In dogs, the atlas is composed of three ossification centres, the right and left neural arches which form the dorsal arch of the atlas and the intercentrum, which in the adult form the body of the atlas. There is a dorsal midline suture between the neural arches that should have fused at 3.5 months of age and two lateral sutures between the intercentrum and each neural arch that should be fused at 4 months.<sup>8</sup> Although the precise mechanism of ossification of the atlas-axis complex has not been described in cats, a similar development to what occurs in dogs may be assumed given that gestation time and prenatal development are very similar.

This assumption would mean that any disturbance (mechanical, vascular or genetic) to the suture between the intercentrum and the left neural arch could be responsible for the defect in the ossification of this cat. However, further anatomical studies may be warranted to further determine the number of, and the time of initial ossification, for each of the bony elements which form the atlas-axis complex of the cat. The clinical signs of the cat described here were typically associated with compression of the medulla associated with the BI. An abnormal mental status, tetraparesis and neck pain have been previously recorded as clinical signs in a cat with OAAM and AA instability that was successfully treated by means of ventral arthrodesis.<sup>2</sup> As in our case, the abnormal mental status was considered a result of the concussion of the medulla and its reticular formation or compression of the ventral spinal artery and vertebral arteries. Different surgical approaches for AA instability have been described, of which the ventral approach appears to offer greater success rates in the long term.<sup>12</sup> The ventral approach allows arthrodesis of the joint and implant positioning in atlas and axis vertebral bodies. The usual surgical technique using transarticular pins and cortical screws<sup>12,19</sup> was modified by using two screws instead of three to achieve fixation and anchor the vertebral bodies of the atlas and axis. Also, only one transarticular pin could be used instead of two, due to the malformation of the atlas which prevented implant placement on its left side. The use of customized three-dimensional printed locking plates could be an option in the treatment of these malformations.<sup>20</sup> However, complete stabilization was achieved by the method described, as evidenced by the satisfactory permanent clinical improvement, despite asymmetric implant placement.

#### Funding

None.

#### Conflict of Interest

The authors have no conflicts of interest to declare related to this report.

#### Authors' Contributions

JL.F.N. wrote the manuscript with support from V.R.G. I.C. and Mateo I.M.P. supervised the project. All authors

discussed the case report and contributed to the final manuscript. All authors provided critical feedback and helped shape the research, analysis and manuscript.

## References

- Bailey CS, Morgan JP. Congenital spinal malformations. *Vet Clin North Am Small Anim Pract* 1992;22(04):985–1015
- Jaggy A, Hutto VL, Roberts RE, et al. Occipitoatlantoaxial malformation with atlantoaxial subluxation in a cat. *J Small Anim Pract* 1991;32:366–372
- Watson AG, Hall MA, de Lahunta A. Congenital occipitoatlantoaxial malformation in a cat. *Compend Contin Educ Pract Vet* 1985;7:245–253
- Sabuncuoglu H, Ozdogan S, Karadag D, Kaynak ET. Congenital hypoplasia of the posterior arch of the atlas: case report and extensive review of the literature. *Turk Neurosurg* 2011;21(01):97–103
- Watson AG, de Lahunta A, Evans HE. Morphology and embryological interpretation of a congenital occipito-atlanto-axial malformation in a dog. *Teratology* 1988;38(05):451–459
- Elvira T, Mateo I. Inestabilidad atlantoaxial con agenesia parcial del atlas en un perro. *Clin Vet peq Anim* 2020;40:93–98
- Warren-Smith CM, Kneissl S, Benigni L, Kenny PJ, Lamb CR. Incomplete ossification of the atlas in dogs with cervical signs. *Vet Radiol Ultrasound* 2009;50(06):635–638
- Watson AG, Evans HE, de Lahunta A. Ossification of the atlas-axis complex in the dog. *Anat Histol Embryol* 1986;15(02):122–138
- Smith JS, Shaffrey CI, Abel MF, Menezes AH. Basilar invagination. *Neurosurgery* 2010;66(3, Suppl):39–47
- Pinter NK, McVige J, Mechtler L. Basilar invagination, basilar impression, and Platybasia: clinical and imaging aspects. *Curr Pain Headache Rep* 2016;20(08):49
- Cummings KR, Vilaplana Grosso F, Moore GE, Rochat M, Thomovsky SA, Bentley RT. Radiographic indices for the diagnosis of atlantoaxial instability in toy breed dogs [corrected]. *Vet Radiol Ultrasound* 2018;59(06):667–676
- Slanina MC. Atlantoaxial instability. *Vet Clin North Am Small Anim Pract* 2016;46(02):265–275
- Leblond G, Gaitero L, Moens NMM, et al. Computed tomographic analysis of ventral atlantoaxial optimal safe implantation corridors in 27 dogs. *Vet Comp Orthop Traumatol* 2017;30(06):413–423
- Loughin CA, Marino DJ. Atlantooccipital overlap and other craniocervical junction abnormalities in dogs. *Vet Clin North Am Small Anim Pract* 2016;46(02):243–251
- Bali MS. Diagnosis and surgical management of a fractured atlas in a cat. *J Feline Med Surg* 2011;13(04):280–282
- Wessmann A, McLaughlin A, Hammond G. Traumatic spinal cord injury caused by suspected hyperflexion of the atlantoaxial joint in a 10-year-old cat. *JFMS Open Rep* 2015;1(01):2055116915589839
- Goel A, Jain S, Shah A. Radiological evaluation of 510 cases of basilar invagination with evidence of atlantoaxial instability (group A basilar invagination). *World Neurosurg* 2018;110:533–543
- Goel A, Nadkarni T, Shah A, Sathe P, Patil M. Radiologic evaluation of basilar invagination without obvious atlantoaxial instability (Group B basilar invagination): analysis based on a study of 75 patients. *World Neurosurg* 2016;95:375–382
- Thomson MJ, Read RA. Surgical stabilization of the atlantoaxial joint in a cat. *Vet Comp Orthop Traumatol* 1996;9:36–39
- Rotter C, Rusbridge C, Fitzpatrick N. Occipitoatlantoaxial malformation in a dog treated with a custom-made implant. *VCOT Open* 2020;03(02):e170–e176