

Iatrogenic Iliopsoas Tendon Injury May Occur during Femoral Head and Neck Osteotomy—An Ex-Vivo Study in Dogs

Charlotte E. Gillis¹ Michael H. Jaffe¹ Alison M. Lee¹ Marc A. Seitz¹

¹ Department of Clinical Sciences, Mississippi State University, MS State, Mississippi, United States

Address for correspondence Charlotte E. Gillis, DVM, 173 Nantasket Road Hull, MA 02045, United States (e-mail: charlotte.gillis@gmail.com).

VCOT Open 2022;5:e36–e40.

Abstract

Objective The aim of this study was to determine if inadvertent iatrogenic damage to the iliopsoas tendon can occur during routine femoral head and neck osteotomy (FHO), using a cadaveric dog model.

Study Design Four cadaveric specimens (eight hindlimbs total) of dogs that were humanely euthanized for reasons unrelated to this study. Pre-experimental radiography confirmed absence of pelvic or femoral comorbidities. Each limb of each paired sample was randomly assigned as either dissection-only control or FHO. The simulated FHO procedures were performed by an American College of Veterinary Surgeons diplomate, and post-procedure radiography confirmed appropriate osteotomy. The FHO limbs underwent pre- and postoperative ultrasonographic investigation by an American College of Veterinary Radiology diplomate. Finally, the FHO limbs were grossly dissected, and abnormalities were documented.

Results Gross visual damage was seen on all postoperative FHO limbs. The damage was most apparent in extreme external rotation of the limb at dissection. Yet, ultrasound investigation did not reveal changes associated with these gross lesions.

Conclusion Iatrogenic inadvertent damage to the iliopsoas tendon may occur during routine FHO, as demonstrated in this ex vivo model; however, this result is not evidence for clinical relevance. A prospective clinical study is needed to assess if iliopsoas injury secondary to FHO has any clinical impact on recovery and limb function.

Keywords

- ▶ orthopaedic surgery
- ▶ osteoarthritis
- ▶ tendon injuries
- ▶ ultrasonography
- ▶ degenerative joint disease

Introduction

Iliopsoas muscle (m.) strain is a well-recognized source of lameness in dogs; the damaging lesions are most commonly situated at the musculotendinous junction near its insertion on the lesser trochanter of the femur.¹ The iliopsoas tendon is an aponeurosis of the psoas major m. and the iliacus m., which functions to flex the hip by drawing the femur cranially. The psoas major m. courses ventral to the spine from its origin on the transverse processes of the second and

third lumbar vertebrae. The iliacus m. originates from the smooth ventral surface of the ilium and merges with the psoas major m. prior to insertion on the lesser trochanter.

Damage to the iliopsoas m. manifests clinically as hindlimb lameness with reluctance to perform high intensity activities.² It is theorized that eccentric contraction of the muscle while lengthening is the source of pain. On orthopaedic examination, abnormalities associated with iliopsoas m. injury include pain with extension and internal rotation of the hip, and with ilium rim or lesser trochanter

received

July 3, 2021

accepted after revision

March 29, 2022

DOI <https://doi.org/>

10.1055/s-0042-1750034.

ISSN 2625-2325.

© 2022. The Author(s).

This is an open access article published by Thieme under the terms of the Creative Commons Attribution License, permitting unrestricted use, distribution, and reproduction so long as the original work is properly cited. (<https://creativecommons.org/licenses/by/4.0/>)

Georg Thieme Verlag KG, Rüdigerstraße 14, 70469 Stuttgart, Germany

palpation.² This condition is typically managed medically.^{3,4} In severe cases, surgical intervention may be warranted.

Femoral head and neck ostectomy (FHO) is a common salvage procedure in dogs. Indications for FHO include coxofemoral luxations, traumatic femoral head/neck fractures, acetabular fractures, aseptic necrosis of the femoral head and end-stage coxofemoral osteoarthritis. Perioperative FHO complications include iatrogenic femoral fracture and sciatic nerve damage⁵; however, whether the FHO procedure can also cause iatrogenic damage to the iliopsoas tendon has not yet been investigated. The craniodorsal surgical approach to the hip joint for FHO utilizes the proximal aspect of the lesser trochanter as a landmark for the distal aspect of the osteotomy. To mitigate the risk of damage to the iliopsoas insertion, handheld Hohmann retractors are commonly used to protect the tendon. However, during the osteotomy procedure, especially when using an oscillating saw, the protecting instruments may shift, exposing the iliopsoas tendon to possible damage (► Fig. 1).

The purpose of this study on cadaver specimens was to investigate if direct damage to the iliopsoas tendon can inadvertently occur despite applying standard surgical techniques executed by an experienced orthopaedic surgeon. Our hypothesis was that such iatrogenic damage can occur.

Materials and Methods

Paired pelvic limb specimens ($n=8$) were evaluated from one female and three male dogs, which were euthanatized for reasons unrelated to this study, which, thus, did not require institutional ethical committee approval. All specimens were from adult mixed breed dogs with an average weight of 26 kg (range: 23–30 kg). The specimens were stored at -25°C and were thawed over a 48-hour period. Dissection and data collection were accomplished within 60 hours of complete thawing to minimize any variables associated with decomposition.

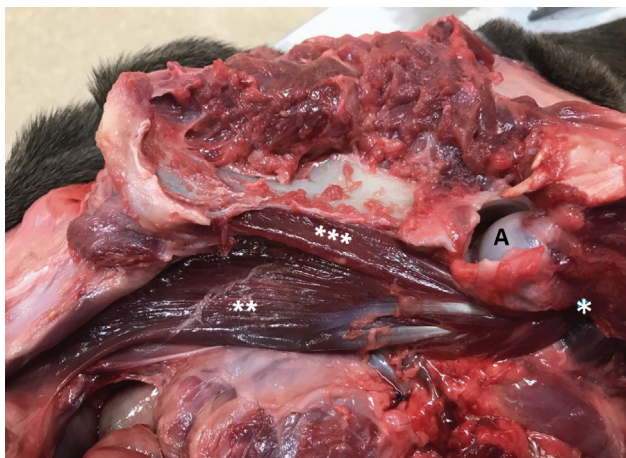

Fig. 1 The letter A marks the head of the femur. The single white asterisk indicates the lesser trochanter. The three white asterisks annotate the iliopsoas m. coursing toward its origin. The two white asterisks highlight the psoas major m. tracking toward its origin.

Orthogonal view digital radiography was performed in the first 24 hours following thaw to confirm absence of skeletal abnormalities. Two specimens were randomly assigned to have a FHO performed on the right pelvic limb and on the remaining two specimens a FHO was done on the left side. Preoperative ultrasonography of the iliopsoas m. on the side undergoing the FHO was done by a board-certified radiologist with the following settings: frequency 8 MHz, depth 3 to 5 cm, dynamic range 81 and power 90% (Ultrasound equipment: LOGIQ S8, General Electric Healthcare, Chicago, Illinois, United States; Transducer: C3-10 D broad-spectrum microconvex transducer (2–11 MHz), General Electric Healthcare, Chicago, Illinois, United States). The areas of interest included the tendons' insertion at the lesser trochanter, the musculotendinous junction of the iliopsoas m., the tendons' thickness prior to the procedure and the iliopsoas m. bellies.

The contralateral pelvic limb of each specimen served as an internal control and was dissected prior to the FHO procedures to evaluate femur, iliopsoas tendon insertion and iliopsoas muscle. The limbs solely undergoing gross anatomical examination were dissected as described in anatomy texts.⁶ A standard craniodorsal FHO approach, as described in standard surgical textbooks, was used by one board-certified surgeon who performed all FHO procedures.⁷ Appropriate osteotomies were grossly appreciated in all specimens and were corroborated by postoperative radiography. Because dissection of the FHO limbs was the ultimate goal, no closure of the deep or superficial structures was performed.

Postoperative ultrasonography of the iliopsoas m. tendon was performed immediately following completion of the FHO procedures. This evaluation focused on the tendon's insertion on the lesser trochanter and the musculotendinous junction.

Following imaging, dissection allowed the iliopsoas m. insertion to be isolated and grossly examined for iatrogenic damage. Once the dissection was completed, the femurs and the iliopsoas m. were excised and removed. Digital photography was used to document any postoperative iliopsoas tendon and muscle abnormalities.

Results

Pre-dissection radiographs revealed no obvious pelvic or femoral co-morbidities that would exclude a specimen from the study. On the radiographs, the femoral neck lengths were evaluated by a single observer. One of the four specimens' radiographic positioning prevented accurate measurements, as soft tissue stiffness limited extension of the limbs. The largest difference between the left and the right femoral neck lengths was 4 mm and the smallest was 1 mm.

Gross evaluation of the supporting structures of the proximal femur and coxofemoral joints revealed no apparent secondary changes consistent with pelvic or femoral disease. Normal iliopsoas musculature was identified in all four specimens. The iliopsoas tendon insertion thickness prior to FHO procedures was on average 3.3 mm (range: 3.1–3.5 mm). The

tendon fibre echogenicity was homogenous in three of the four samples. One specimen had mildly heterogenous iliopsoas fibres at the level of the lesser trochanter. In addition, this specimen had hyperechoic foci noted within the iliopsoas insertion fibres. These changes were likely due to the overlying gas, but a mild chronic inflammatory condition could not be excluded.

Complete removal of the femoral heads and necks in all specimens was confirmed by gross assessment and by completely resected, sharply margined osteotomies, as seen on postoperative radiographs. Postoperative ultrasound evaluations of the iliopsoas tendons revealed one sample displayed an ovoid, homogeneous, hyperechoic region, immediately adjacent to the lesser trochanter (► **Fig. 2**). All samples had moderate subcutaneous air accumulation at the level of the FHO approach and the surrounding soft tissue structures.

Prior to dissection, the osteotomy sites and iliopsoas tendon insertions showed no grossly visible damage. External rotation to the degree which would be possible during a surgical procedure revealed some damage to the insertion

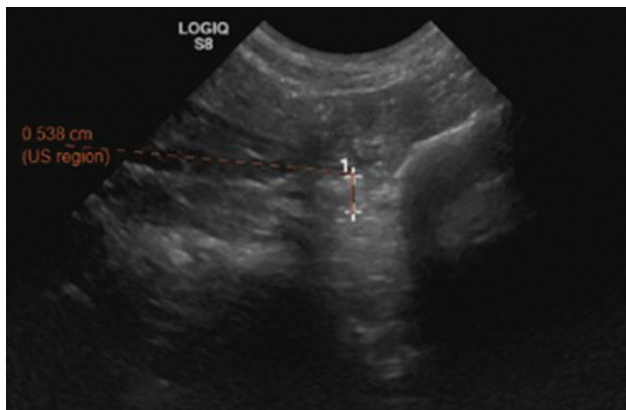


Fig. 2 This is an ultrasound image of the focal lesion in the iliopsoas tendon adjacent to the lesser trochanter of the femur (eUnity v6. Client Outlook, Inc. Waterloo, Ontario, Canada).

site of the iliopsoas tendon. When the superficial muscles of the pelvic limb were detached, further external rotation allowed examination of the musculotendinous junction. Specimen one necessitated complete disarticulation of the femur from the pelvis to assess the full extent of iatrogenic damage to the iliopsoas. There was moderate fibre disruption to the insertion of the iliopsoas tendon on the lesser trochanter noted. Specimen two had very minimal damage to the iliopsoas tendon. It was isolated to the area in direct contact with the arc of the saw. In specimen three, there were three distinct damage patterns: a focal iliopsoas tendon tear at the insertion on the lesser trochanter measuring 1 mm, a linear destructive lesion running parallel to the iliopsoas tendon fibres spanning from the insertion on the lesser trochanter to the musculotendinous junction measuring 4mm and an irregular lesion on the caudo-medial aspect of the iliopsoas tendon, measuring 3mm (► **Fig. 3**). The iliopsoas m. was then incised and removed with the femur to better assess the iliopsoas tendon. The caudo-medial damage was documentable only under this condition. The osteotomy line in specimen three was not directly abutting the lesser trochanter of the femur, and was 1.5 mm proximal to it. In this sample, the tip of the Hohmann retractor was slightly displaced by the saw during the osteotomy. Specimen four had marked disruption of the tendon at the level of the insertion site. The damage was not isolated to the fibres directly adjacent to the osteotomy; it involved the entire tendon insertion.

Discussion

The results of this ex vivo study support our hypothesis that FHO carries a risk of iatrogenic damage to the iliopsoas tendon or muscle. The FHO is a common procedure performed in dogs, which results in a neo-arthritis, or formation of a fibrous false joint.^{7,8} Chronic gait abnormalities that can result from an FHO include shortening of the operated limb limiting the range of motion, patellar luxation because

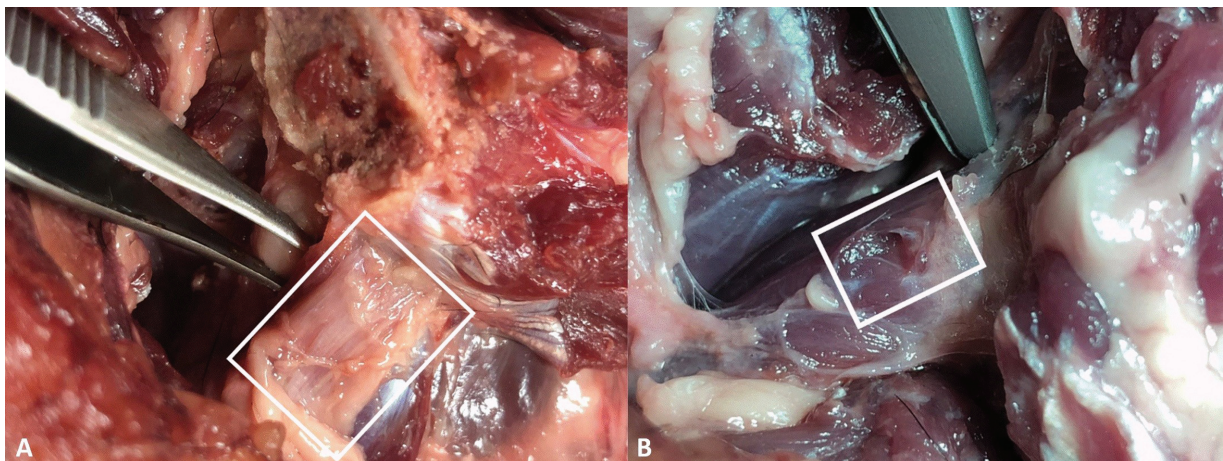


Fig. 3 The injuries noted in both images were discovered after performing the femoral head and neck osteotomy (FHO). The image is a left pelvic limb, and the femur is externally rotated. The left image (A) white boxes outline evidence of gross iliopsoas tendon disruption at the insertion on the lesser trochanter and linear frayed tendon fibres extending to the musculotendinous junction. The right image (B) shows a punctate iliopsoas musculotendinous junction fibre disruption discovered after simulating the FHO.

of proximal femur instability, muscle atrophy, sciatic nerve damage or fracture of the proximal femur.^{5,8,9} To our knowledge, combining gross dissection of cadaveric specimens with ultrasonography to assess the inadvertent iatrogenic damage to the iliopsoas m. has not been previously described. Damage to the iliopsoas m. is not among the reported complications but is suspected to occur in some cases remaining potentially undetected.

All specimens showed grossly appreciable damage to the iliopsoas tendon during postoperative dissection and evaluation. Some of the damage was appreciated in physiologic external rotation; however, dissection of the superficial muscles allowed greater visualization of the full extent of the damage to the iliopsoas tendon and its musculotendinous junction. Without complete dissection, there would have been underestimation of the iatrogenic damage. This limitation of external rotation in the clinical setting may account for overlooking the iliopsoas tendon's role in postoperative delay in return to normal function in dogs who undergo an FHO.

Due to the cadaveric study design, direct examination of the tissues was used to isolate damage sustained to the iliopsoas throughout every step of the investigation. We acknowledge a limitation of the study was that there were only four dogs; however, despite these small numbers we were able to demonstrate that damage to the iliopsoas tendon may occur. Our specimens were frozen and thawed to room temperature prior to investigation. According to Brooks, freezing a carcass slows the rate of decomposition and desiccation of tissues.¹⁰ The role of autolysis and gas accumulation cannot be completely disregarded in this study because the specimens were stored at room temperature for the duration of the investigation.

The portion of the canine iliopsoas anatomy most vulnerable to injury during a FHO is at the insertion on the lesser trochanter. The insertion may be damaged because the iliopsoas tendon is a physiologically rigid structure that functions to transmit contractile force of its muscle with varied elasticity and compliance.¹⁰ The tendon insertion is further compromised by an FHO due to its proximity to the osteotomy site in a small surgical field. In this study, there were variations in injury manifestation: focal iliopsoas tendon insertion fibre disruption immediately adjacent to osteotomy, diffuse tendon fibre disruption on the lesser trochanter, linear destruction of tendon running parallel to the fibres up to the level of the musculotendinous junction and a punctate irregularity to the tendon fibres. This study does not definitively establish which part of the FHO procedure is the cause of iatrogenic damage. The most likely sources are the cutting arc of the saw or placement and retraction by the Hohmann retractors, because of their proximity to the lesser trochanter of the femur during the procedure. Another factor to consider is Hohmann retractors are handheld instruments, and it is not uncommon that they can slip during the sawing process. Some surgeons opt for alternative retraction tools other than the Hohmann. This could be a factor in iatrogenic iliopsoas damage. Another consideration is that this study exclusively examined the standard craniodorsal approach. Cadaveric comparison of

the craniodorsal versus the ventral approach to a FHO determined no significant difference when completed by novice veterinarians. The Kirschner-wire guided ventral FHO method has subjectively shown to decrease regional soft tissue retraction and increase visualization of the femoral neck.^{11,12} Future studies investigating the presence of iliopsoas damage with the ventral FHO approach should be considered. There is lesser concern for the surgical approach or soft tissue dissection causing iatrogenic damage when the procedure is performed by an experienced surgeon; however, it cannot be proven that experience or specialty training level plays a role in the possibility of iatrogenic damage to this structure.

Ultrasound investigation of the iliopsoas m., myotendinous junction and tendon insertion have been described in canine cadaveric specimens. The normal muscle belly is hypoechoic with hyperechoic linear fibres running parallel to the muscle's long axis. The myotendinous junction is fan shaped with obliquely oriented hyperechoic fibres that converge into a short tendon. The hyperechoic, linear iliopsoas tendon inserts onto a hypoechoic notch (lesser trochanter).¹ These cadaveric ultrasound findings positively correlate to in vivo evaluations of the iliopsoas.^{1,13-15}

In three of the four specimens, postoperative ultrasound evaluations of the iliopsoas tendons demonstrated no change in iliopsoas tendon echogenicity following the FHO procedure despite gross evaluation evidence to the contrary. Only one specimen displayed an appreciable postoperative abnormality on the ultrasound exam. One would expect to see acute changes associated with damage from the FHO. In a clinical setting, ultrasound can detect acute iliopsoas fibre injury by illustrating the changes in wave resonance secondary to oedema, haemorrhage and other secondary inflammatory responses.¹⁴ The cadaveric study precludes observation of an in vivo pathophysiologic response to injury. One would expect that the gross observation of tendon fibre disruption to be visible with ultrasound. There have been documented limitations of ultrasonography of the canine shoulder joint for identifying pathology related to instability; however, it was sensitive and reliable for non-instability related pathology.¹⁶ Gas accumulation posed further challenges to the study. Because the soft tissue layers were not closed following the FHO procedures, the dissection site gas accumulation may have limited the utility of ultrasound as a means of evaluating tendon damage in ex vivo tissue.

The results of this cadaver study support the hypothesis that in a clinical setting FHO may carry a risk of iatrogenic damage to the iliopsoas m. tendon at its insertion site at the lesser trochanter.

Conflicts of Interest

The authors declare no financial or other conflicts of interest.

References

- 1 Cannon MS, Puchalski SM. Ultrasonographic evaluation of normal canine iliopsoas muscle. *Vet Radiol Ultrasound* 2008;49(04): 378-382

- 2 Palmar R. Is it the Hip or the Stifle? - Tricks to Distinguish Them. World Small Animal Veterinary Association World Congress Proceedings. VIN; 2015. Accessed April 22, 2022 at <https://www.vin.com/apputil/content/defaultadv1.aspx?id=7259229&pid=14365&>
- 3 Nielsen C, Pluhar GE. Diagnosis and treatment of hind limb muscle strain injuries in 22 dogs. *Vet Comp Orthop Traumatol* 2005;18(04):247–253
- 4 Zink C, Van Dyke JB. *Canine Sports Medicine and Rehabilitation*. 2nd edition. Hoboken, NJ: Wiley Blackwell; 2018:14–15: 353–403
- 5 Off W, Matis U. Excision arthroplasty of the hip joint in dogs and cats. Clinical, radiographic, and gait analysis findings from the Department of Surgery, Veterinary Faculty of the Ludwig-Maximilians-University of Munich, Germany. 1997. *Vet Comp Orthop Traumatol* 2010;23(05):297–305
- 6 Evans H, De Lahunta A. *Guide to the Dissection of the Dog*. 8th edition. Philadelphia: Saunders WB; 2016; 2:62–63
- 7 Brinker W, Piermattei D, Flo G. *Handbook of Small Animal Orthopedics and Fracture Treatment*. 5th edition. St. Louis: Elsevier; 2015; 24:488–500
- 8 Sabiza S, Ronagh A, Khajeh A. Effective Medical Management and Physiotherapy Program of Femoral Head and Neck Osteotomy (FHO) in 24 dogs and cats. *Clinical Report. Iran J Vet Surg* 2019; 14(01):78–84
- 9 Duff R, Campbell JR. Long term results of excision arthroplasty of the canine hip. *Vet Rec* 1977;101(10):181–184
- 10 Brooks JW. Postmortem changes in animal carcasses and estimation of the postmortem interval. *Vet Pathol* 2016;53(05): 929–940
- 11 Winders CLB, Vaughn WL, Birdwhistell KE, Holsworth IG, Franklin SP. Accuracy of femoral head and neck excision via a craniolateral approach or a ventral approach. *Vet Comp Orthop Traumatol* 2018;31(02):102–107
- 12 Saporita JA, Palmer RH, Goh CSS. Ventral femoral head and neck ostectomy: Standard versus novel K-wire guided technique using a premeasured ostectomy angle in canine cadavers. *Vet Surg* 2021;50(06):1201–1208
- 13 Breur GJ, Blevins WE. Traumatic injury of the iliopsoas muscle in three dogs. *J Am Vet Med Assoc* 1997;210(11):1631–1634
- 14 Cullen R, Canapp DA, Carr BJ, et al. Evaluation of iliopsoas strain with findings from diagnostic musculoskeletal ultrasound in agility performance canines-73 cases. *Veterinary Evidence Online* 2017;2:2
- 15 Wilmitzer F, Gumpenberger M, Sommerfeld-Stur I, et al. Radiographically breed specific morphology and calcifying tendinopathy in the iliopsoas muscle at the lesser trochanter in rottweilers, German shepherd dogs and Bavarian mountain hounds. *J Vet Sci* 2016;7:2
- 16 Cogar SM, Cook CR, Curry SL, Grandis A, Cook JL. Prospective evaluation of techniques for differentiating shoulder pathology as a source of forelimb lameness in medium and large breed dogs. *Vet Surg* 2008;37(02):132–141