



Multi-Level Cervical Disc Degeneration and Vertigo

Degeneração do disco cervical em múltiplos níveis e vertigem

Serdar Ercan¹ Murat Baloglu²

¹Department of Neurosurgery, School of Medicine, Atılım University, Ankara, Turkey

²Department of Neurosurgery, Eskisehir City Hospital, Eskisehir, Turkey

Address for correspondence Serdar Ercan, associate professor, Department of Neurosurgery, School of Medicine, Atılım University, Ankara, Turkey, Kizilcasar Mah, 1184. Cad, No:13, Incek, Golbasi, Ankara, Turkey (e-mail: sdrercn@gmail.com).

Arq Bras Neurocir 2022;41(4):e311–e315.

Abstract

Objective While complaints of pain, loss of strength, and numbness radiating to the neck and arm are common in patients due to cervical disc degeneration, vertigo is a rare symptom. The articles previously published on the subject focus on single-level disk degeneration and its correlation with vertigo. However, in the case of multilevel cervical discopathy, its effect on the severity of vertigo and its response to surgical treatment has not been clarified. Therefore, the objective of the present study is to shed light on the topic.

Methods Patients with vertigo complaints in whom all known etiological causes of vertigo had been excluded, but with cervical disc degeneration, were included in the study. The scores on the Visual Analog Scale (VAS) and Cervical Vertigo Evaluation Scale (CVES) were analyzed in terms of numbers of discopathy, spine levels, and differences regarding the preoperative and postoperative status.

Results A total of 24 patients (14 with single-level and 10 with multi-level disc degeneration) underwent anterior cervical discectomy. The preoperative CVES score was significantly decreased after surgery. Multi-level disc degeneration causes fewer vertigo symptoms than the single-level kind. No significant correlation between the severity of pain and vertigo was observed.

Conclusion Multi-level disc degeneration causes fewer vertigo symptoms. These symptoms decreased after anterior cervical discectomy in cases of single-level disk herniation at upper segments. The surgical intervention could be a favorable choice of treatment. However, the mechanism and treatment approach to cervical vertigo is still a controversial issue.

Keywords

- ▶ vertigo
- ▶ dizziness
- ▶ cervical
- ▶ disc degeneration

received
March 21, 2022
accepted
April 25, 2022

DOI <https://doi.org/10.1055/s-0042-1749369>.
ISSN 0103-5355.

© 2022. Sociedade Brasileira de Neurocirurgia. All rights reserved. This is an open access article published by Thieme under the terms of the Creative Commons Attribution-NonDerivative-NonCommercial-License, permitting copying and reproduction so long as the original work is given appropriate credit. Contents may not be used for commercial purposes, or adapted, remixed, transformed or built upon. (<https://creativecommons.org/licenses/by-nc-nd/4.0/>)
Thieme Revinter Publicações Ltda., Rua do Matoso 170, Rio de Janeiro, RJ, CEP 20270-135, Brazil

Resumo

Objetivo Embora as queixas de dor, perda de força e dormência com irradiação para o pescoço e braço sejam comuns em pacientes devido à degeneração do disco cervical, a vertigem é um sintoma raro. Os artigos publicados anteriormente se concentram na degeneração do disco de nível único e na sua correlação com a vertigem. No entanto, no caso da discopatia cervical em múltiplos níveis, seu efeito sobre a gravidade da vertigem e sua resposta ao tratamento cirúrgico não foi esclarecido. Portanto, o objetivo do presente estudo foi lançar luz sobre essa questão.

Métodos Foram incluídos no estudo pacientes com queixa de vertigem nos quais foram excluídas todas as causas etiológicas conhecidas de vertigem, mas que apresentavam degeneração discal cervical. As pontuações na Escala Visual Analógica (EVA) e na Escala de Avaliação da Vertigem Cervical (Cervical Vertigo Evaluation Scale, CVES, em inglês) foram analisadas em termos dos números de discopatia, dos níveis da coluna, e das diferenças entre o estado pré e pós-operatório.

Resultados A todo, 24 pacientes (14 com degeneração discal de nível único e 10 com degeneração em múltiplos níveis) foram submetidos a discectomia cervical anterior. A pontuação pré-operatória no CVES sofreu redução significativa após a cirurgia. A degeneração do disco em múltiplos níveis provoca menos sintomas de vertigem do que a de nível único. Não se observou correlação significativa entre a gravidade da dor e a vertigem.

Conclusão A degeneração discal em múltiplos níveis provoca menos sintomas de vertigem. Os sintomas de vertigem diminuíram após a discectomia cervical anterior em hérnia de disco de nível único nos segmentos superiores. A intervenção cirúrgica pode ser uma escolha favorável no tratamento. No entanto, o mecanismo e a abordagem do tratamento da vertigem cervical ainda é uma questão controversa.

Palavras-chave

- ▶ vertigem
- ▶ tontura
- ▶ cervical
- ▶ degeneração discal

Introduction

Dizziness is the illusion of spinning, with the sensation of rotational movement of the surrounding objects. It is among the most common complaints in medicine, and it affects approximately 20% to 30% of the general population.¹⁻³ The etiology of vertigo varies; insufficient activity of the semi-circular canals of the ear, unequal neural activity of left and right vestibular nuclei at the central nervous system, and blood pressure irregularity due to cardiac disorders are the most common factors that cause dizziness and vertigo. Many treatment protocols have been developed considering the etiology, and the patients are treated by specialist physicians. However, there are reports of^{1,3,4} a group of patients who were have cervical disc degeneration with complaints of dizziness despite the absence of the aforementioned vertigo etiologies. With this new finding, the highly-controversial concept of cervicogenic vertigo was introduced in the literature.

In a study by Colledge et al.⁴ on the causes of vertigo in the elderly, the authors attributed vertigo to cervical spondylosis in 65% of the cases. While complaints of pain, loss of strength, and numbness radiating to the neck and arm are common in patients due to cervical disc degeneration, vertigo is a rare symptom.^{2,5,6}

There are authors⁴ who oppose as well as supporters of cervical vertigo. The lack of an established diagnostic test

for the syndrome is the most important cause of controversy. In studies⁷⁻¹⁰ on this subject, single-level disc pathologies and treatment methods are generally discussed; however, the severity of vertigo in patients with multi-level disc degeneration and the treatment protocols to be applied in these cases are not mentioned. In the present study, we aimed to investigate how it will affect vertigo both between cervical spine levels and in the presence of additional adjacent disc degeneration. In addition, among the treatment options, the effect of the surgical treatment on vertigo was investigated.

Materials and Methods

All patients underwent vestibular and hearing tests. Then, regular consultations were held to exclude any ear, neurologic and cardiologic disorders. Cervical magnetic resonance imaging (MRI) scans, radiographs, and computed tomography (CT) scans were assessed. Patients who have vertigo but no etiological disorders except cervical spondylosis were included. The vertigo symptoms were evaluated based on the Cervical Vertigo Evaluation Scale (CVES), which was first described by Wang and Zhou in 1998.⁷ The duration of the cervical disc degeneration was examined retrospectively from the hospital archive. The data obtained were used to understand whether there is a link between the severity of

Table 1 Demographics of patients with cervical disk degeneration and vertigo

Mean age (years)		62 ± 4
Number of patients	Male	10
	Female	14
Duration of disk degeneration (years)	< 1	7
	1-5	9
	> 5	8
Average score on the Visual Analog Scale	Preoperative	7
	Postoperative	3
Mean score on the Cervical Vertigo Evaluation Scale	Preoperative	11 ± 2
	Postoperative	24 ± 2
Cases of single-level disc degeneration		14
Cases of multi-level disc degeneration		10
Cases of degeneration in the upper cervical segments		11
Cases of degeneration in the lower cervical segments		13

vertigo and the duration of the degeneration. Preoperative and postoperative changes in CVES and Visual Analog Scale (VAS) scores were examined to assess whether there was a difference between vertebral segments.

Operative procedure: anterior cervical discectomy (ACD) was performed using the standard approach.⁸ Under general anesthesia, the disc was completely removed, and the cervical cage was inserted.

Postoperative management: non-steroidal anti-inflammatory drugs (NSAIDs) were used for the next five days.

Follow up: the preoperative and postoperative CVES scores were used to evaluate the clinical outcomes.⁹ Preoperative spine level in which disc degeneration occurred, and number of spine level and surgery performed for the disc degeneration were recorded.

Statistical analysis: for the statistical analysis, we used the Statistical Package for the Social Sciences (IBM SPSS Statistics for Windows, IBM Corp., Armonk, New York, US) software, version 22.0. We compared significant preoperative and postoperative CVES values through the Mann-Whitney U test.

Results

A total of 24 patients (14 female and 10 male subjects) were included. All patients had neck and arm pain along with vertigo. The ages of the patients were between 56 and 72 (mean: 62 ± 4) years. The mean duration of the symptoms was 2 years; 15 patients had symptoms for less than 1 year, and the others, for about 3 years (► **Table 1**).

All patients underwent ACD, and a polyetheretherketone (PEEK) cage was installed at the level of deformity. In total, 14 patients had single-level disk degeneration (3 on C3-C4, 4 on C4-C5, 3 on C5-C6, and 4 on C6-C7), and 10 patients had multi-level disk degeneration (5 on C4-C5-C6 and 5 on C5-C6-C7).

The preoperative VAS scores were evaluated, and no significant differences between the patients with single- and multi-level disk degeneration were observed. However, the results regarding the CVES scores were different: the patients with multi-level disk degeneration had significantly fewer vertigo symptoms ($p = 0.03$). The upper cervical levels (C3-C4-C5) cause greater vertigo symptoms than the lower levels (C5-C6-C7), regardless of the number of degenerated discs (► **Figure 1**).

The preoperative and postoperative VAS scores were compared; the postoperative score was significantly lower than the preoperative scores both in cases of upper and lower cervical disc degeneration ($p = 0.01$ and 0.02 respectively) (► **Figure 1**). Moreover, significant recovery from pain was achieved in cases of single and multi-level disc degeneration ($p = 0.03$ and 0.01 respectively). Similar results were observed regarding the CVES scores ($p = 0.02$). No correlation was observed between the decline ratio of the VAS and CVES scores ($p = 0.1$). However, the efficacy of the surgical treatment for upper cervical levels

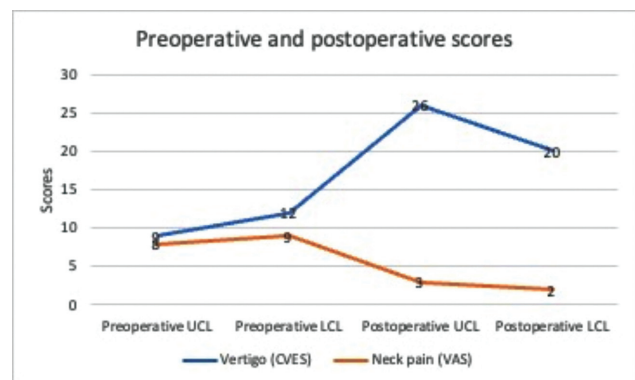


Fig. 1 Preoperative and postoperative CVES and VAS scores for the upper and lower cervical levels. Abbreviations: UCL, upper cervical level; LCL, lower cervical level.

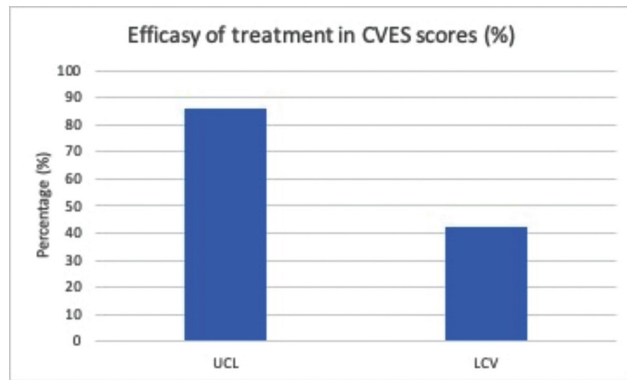


Fig. 2 After the surgical treatment, the improvement in the vertigo symptoms of patients with upper cervical level disc degeneration was significantly greater than that of those with lower cervical disc degeneration. Abbreviations: UCL, upper cervical level; LCL, lower cervical level.

was significantly greater than the efficacy for lower cervical levels ($p = 0.03$) (► **Figure 2**).

In the multi-level disc degeneration group, patients with degeneration longer than five years had fewer vertigo symptoms. However, no significant differences were observed in the single-level group regarding the duration of the disc degeneration (► **Figure 3**).

Discussion

The exact cause of vertigo in cervical disc disorders is a controversial issue, and its mechanism has not yet been elucidated. Among the hypotheses is rotational malposition of the vertebral artery. Cervical balance changes due to cervical degenerative disc disorder, subsequent stenosis, or osteophytes may result in a decrease in the velocity of the flow of the vertebral artery. The resulting vertigo can be explained by the decrease in blood flow. However, Yin et al.¹⁰ stated that changes in the diameter of the vertebral artery were not related to vertigo. They¹⁰ claimed that there was no change in the vertebral artery after the treatment by percutaneous nucleoplasty (PCN), but vertigo decreased with the treatment.

Another hypothesis for the causes of cervicogenic vertigo is proprioceptive sensory dysfunction. The effect of Ruffini bodies in the etiology of cervicogenic vertigo was revealed for the first time, as studies^{8,11} have found that patients with cervicogenic vertigo have more Ruffini bodies at degenerated levels than at healthy levels.⁸ Zheng et al.¹² claimed that asymmetrical protrusion in cervical disc hernias causes asymmetric sensory input, which in turn causes cervical vertigo. But their study¹² only involved patients with single-level disc herniation. In the present study, we evaluated patients with single and multi-level disc herniation, and we observed that vertigo was severe especially in single-level discopathy, which occurred at the C3-4 and C5-6 levels ($p < 0.002$). However, we also observed that the vertigo in patients with multi-level cervical discopathy was less severe than in those with pathologies in two consecutive vertebral segments and those with healthy disc levels in between.

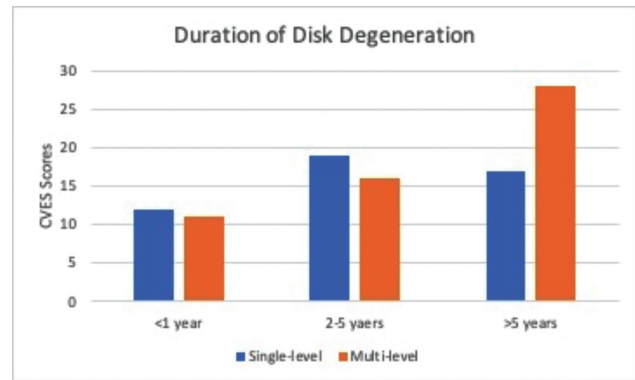


Fig. 3 In the multi-level disc degeneration group, patients with disc degeneration with a duration longer than 5 years had fewer vertigo symptoms. However, there was no significant difference in the single-level group regarding the duration of disc degeneration.

Considering the duration of the degeneration in patients with two or more consecutive disc herniations, those with chronic degeneration (lasting longer than 5 years) had the least severe cases of vertigo, which was significant.

No significant correlation was found between the severity of pain and the severity of vertigo ($p = 0.2$). This inconsistency between pain and vertigo has been the most important claim by researchers who reject the diagnosis of cervical vertigo.^{5,13}

Percutaneous nucleoplasty has been attempted primarily as a treatment option.² Hahn et al.¹⁴ declare that short or medium term effectiveness of PCN is greater than long-term. In contrast, Li et al.⁸ mention that long term effectiveness is better than short or medium term. Yin et al.¹⁰ demonstrated that although there was no significant change in the diameter of the vertebral artery, the severity of the vertigo decreased in patients who underwent PCN. We observed that the severity of the vertigo decreased significantly in our patients who underwent discectomy ($p < 0.03$). However, in the comparison regarding the vertebral levels, we observed a significantly greater decrease in the severity of the vertigo in patients submitted to surgical intervention on the upper cervical vertebra than in the lower vertebral segments. With surgical discectomy, the disc protrusion that compresses the spinal cord is removed. This may explain the “asymmetric sensory input” hypothesis put forward earlier. In addition, complete disc removal means the disappearance of Ruffini bodies, which explains another vertigo hypothesis. However, the fact that the vertigo is less severe in multi-level disc hernia compared to single-level hernia and that it responds less to treatment, shows that all hypotheses should still be viewed with suspicion.

In the literature, there are very few studies approaching the degenerative disc with surgical intervention for the treatment of cervical vertigo, except for percutaneous procedures. Li et al.¹⁵ submitted their patients diagnosed with cervical spondylosis to anterior fusion, and reported that nearly 80% of the vertigo symptoms improved. In similar study, Hong and Kawaguchi¹⁶ obtained results close to those found by Li et al.¹⁵ However, both studies only involved cases

of single-level disc degeneration or spondylosis. In the study, we evaluated vertigo in cases of single- and multi-level disc degeneration.

Conclusion

Cervicogenic vertigo should be considered in patients who do not have any vertigo etiology other than cervical disc degeneration. We observed that vertigo symptoms decreased after ACD, especially in single-level upper segments. However, the mechanism and treatment approach to cervical vertigo is still a controversial issue. The fact that the physiopathology revealed in single-level discopathy is not compatible with that of multi-level discopathy increases the discussion.

Limitations of the Study

Since the tests used for vertigo in general are mostly subjective, it is very difficult to diagnose cervicogenic vertigo. There is no definitive diagnostic method that we can use for this syndrome. The diagnosis can only be established after all causes of vertigo have been ruled out by investigating other etiologies. However, an incorrectly-evaluated cause may lead to misdiagnosis.

Ethical Publication Statement

We confirm that we have read the Journal's position on issues involving ethical publication, and declare that the present report is consistent with those guidelines.

Authors' Contributions

Serdar Ercan and Murat Baloglu: collection and analysis of data, and writing of the manuscript.

Funding Statement

The authors declare that they have received no funding regarding the performance of the present research.

Conflict of Interests

The authors have no conflict of interests to declare.

References

- Hannaford PC, Simpson JA, Bisset AF, Davis A, McKerrow W, Mills R. The prevalence of ear, nose and throat problems in the community: results from a national cross-sectional postal survey in Scotland. *Fam Pract* 2005;22(03):227-233
- Li Y, Peng B. Pathogenesis, Diagnosis, and Treatment of Cervical Vertigo. *Pain Physician* 2015;18(04):E583-E595
- Yardley L, Owen N, Nazareth I, Luxon L. Prevalence and presentation of dizziness in a general practice community sample of working age people. *Br J Gen Pract* 1998;48(429):1131-1135
- Colledge NR, Barr-Hamilton RM, Lewis SJ, Sellar RJ, Wilson JA. Evaluation of investigations to diagnose the cause of dizziness in elderly people: a community based controlled study. *BMJ* 1996; 313(7060):788-792
- Brandt T. Cervical vertigo—reality or fiction? *Audiol Neurotol* 1996;1(04):187-196
- Yacovino D. Cervical vertigo: myths, facts, and scientific evidence. *Neurologia (Barcelona, Spain)* 2012
- Wang C, Zhuo D. A preliminary evaluation of symptoms and functions of patients with cervical vertigo. *Chin J Rehabil Med* 1998;13:245-247
- Li C, Qi Y, Liu G, et al. Long-Term Clinical Outcomes of Percutaneous Cervical Nucleoplasty for Cervical Degenerative Diseases with Neck Pain and Cervical Vertigo. *World Neurosurg* 2020;133: e205-e210
- Clements DH, O'Leary PF. Anterior cervical discectomy and fusion. *Spine* 1990;15(10):1023-1025
- Yin HD, Zhang XM, Huang MG, et al. Curative effect and mechanism of radiofrequency ablation nucleoplasty in the treatment of cervical vertigo. *Br J Radiol* 2017;90(1072):20150772
- Li Y, Peng B. Pathogenesis, Diagnosis, and Treatment of Cervical Vertigo. *Pain Physician* 2015;18(04):E583-E595
- Zheng S, Muheremu A, Sun Y, Tian W, Wu CA. Preoperative imaging differences of patients with cervical spondylosis with cervical vertigo indicate the prognosis after cervical total disc replacement. *J Int Med Res* 2020;48(02):300060519877033
- Brandt T, Bronstein AM. Cervical vertigo. *J Neurol Neurosurg Psychiatry* 2001;71(01):8-12
- Hahn T, Halatsch ME, Wirtz C, Klessinger S. Response to cervical medial branch blocks in patients with cervicogenic vertigo. *Pain Physician* 2018;21(03):285-294
- Li J, Jiang DJ, Wang XW, Yuan W, Liang L, Wang ZC. Mid-term outcomes of anterior cervical fusion for cervical spondylosis with sympathetic symptoms. *Clin Spine Surg* 2016;29(06):255-260
- Hong L, Kawaguchi Y. Anterior cervical discectomy and fusion to treat cervical spondylosis with sympathetic symptoms. *J Spinal Disord Tech* 2011;24(01):11-14