



Establishing a New Neurointerventional Facility in a Remote Area of a Low–Middle Income Country (LMIC): Initial Experience

Nishtha Yadav¹ Ambuj Kumar² Ketan Hedao² Anivesh Jain³ Kamalraj Singh³ Aditya Vikram²

¹Department of Neuroradiology, School of Excellence in Neurosurgery Super Speciality Hospital, Netaji Subhash Chandra Bose Medical College, Jabalpur, Madhya Pradesh, India

²Department of Neurosurgery, Super Speciality Hospital, Netaji Subhash Chandra Bose Medical College, Jabalpur, Madhya Pradesh, India

³Department of Anaesthesia, Super Speciality Hospital, Netaji Subhash Chandra Bose Medical College, Jabalpur, Madhya Pradesh, India

Address for correspondence Nishtha Yadav, MBBS, MD, DM, Super Speciality Hospital, Netaji Subhash Chandra Bose Medical College, Jabalpur, Madhya Pradesh, India (e-mail: nishthayadavthesis@gmail.com).

AJNS 2022;17:50–57.

Abstract

Background Timely performed Neurointervention procedures in patients with neurovascular disorders save them from mortality and lifelong morbidity, in addition to relieving the immense economic and social burden associated with these diseases.

Materials and Methods We retrospectively reviewed data of neurointerventions performed in our hospital from November 2019 till March 2021. Patient age, sex, diagnosis, preoperative, and postoperative imaging findings were collected and analyzed. Types of procedures, success/failure, procedure-related and procedure-unrelated complications were noted and described.

Results Total 161 procedures were done (diagnostic $n=89$, therapeutic $n=72$). Among the 72 cases of therapeutic procedures, angiographic success was noted in 60 cases, partial success was noted in 5 cases (RR grade 3 occlusion) and failure was noted in 7 cases [mechanical thrombectomy ($n=2$), coiling ($n=1$), flow diverter ($n=1$), Caroticocavernous fistula ($n=1$), cerebral Arteriovenous malformation ($n=2$)]. Among therapeutic cases ($n=72$), patient outcome was categorized as improved (with mRS 0-2 at discharge) in 64 cases (60 neurointerventions, 4 converted to surgery), morbidity in form of weakness was noted in 2 cases, mortality was noted in 8 cases. There were no hemorrhagic complications due to rupture or dissection. Ischemic complications were noted in form of thromboembolic complications in three cases and vessel occlusion (delayed MCA occlusion) in one case.

Conclusion With recent efforts by medical associations and governments to provide access to these lifesaving, disability averting neuro-interventions, it's important to recognize and define challenges in implementation of neuro-intervention services. In this article, we share our early experience in establishing a neurointervention facility in a backward region of a low–middle income country.

Keywords

- ▶ neurointervention
- ▶ LMIC
- ▶ endovascular

published online
July 1, 2022

DOI <https://doi.org/10.1055/s-0042-1749150>
ISSN 2248-9614.

© 2022. Asian Congress of Neurological Surgeons. All rights reserved.

This is an open access article published by Thieme under the terms of the Creative Commons Attribution-NonDerivative-NonCommercial-License, permitting copying and reproduction so long as the original work is given appropriate credit. Contents may not be used for commercial purposes, or adapted, remixed, transformed or built upon. (<https://creativecommons.org/licenses/by-nc-nd/4.0/>)

Thieme Medical and Scientific Publishers Pvt. Ltd., A-12, 2nd Floor, Sector 2, Noida-201301 UP, India

Introduction

Neurointervention is a specialized branch which deals with minimally invasive treatment of cerebrovascular disorders causing ischemic/hemorrhagic strokes. It is anticipated that by 2050, 80% of stroke patients will be from the developing regions of the world.¹ Timely performed neurointervention procedures in these patients save them from mortality and lifelong morbidity, in addition to relieving the immense economic and social burden associated with these diseases. As there is increasing effort by medical associations and governments to provide access to these life-saving, disability-averting neurointerventions, it is important to recognize and define challenges in implementation of neurointervention services in low–middle income countries (LMICs).

In India, majority of government hospitals do not have neurointervention facilities predominantly due to lack of trained individuals and extremely high cost of consumables.^{2,3} Only a handful of state government hospitals have these facilities and most of neurointerventions are done in private setups in India which can be afforded only by a limited number of patients.

In Madhya Pradesh, the first public-funded neurointervention facility was started at our institute in November 2019. We discuss the feasibility of establishing a neurointervention setup in a state-owned public-funded hospital setup in a backward region of central India.

Materials and Methods

We retrospectively reviewed data of all diagnostic and therapeutic neurointerventions performed in our hospital from November 2019 till March 2021. Data including patient demographics including age, sex, underlying diagnosis, and preoperative and postoperative imaging findings were collected and analyzed. Types of neurointervention procedures, success/failure of procedure, and procedure-related and procedure-unrelated complications were noted and described.

Procedures were performed on a biplane neuroangiography suite (Artis Zee, Siemens, Erlangen, Germany). Appropriate preprocedure imaging (computed tomography/magnetic resonance imaging [CT/MRI]) was performed. Therapeutic endovascular neurointervention procedures were performed under general anesthesia. The right femoral artery was punctured with an 18G needle and 5F sheath was inserted. Note that 5,000 IU of heparin were given intravenously as a bolus after which 1,000 IU was repeated hourly till the end of the procedure. Postprocedure DynaCT was done on table before extubation. Postprocedure CT was performed for all patients before discharge.

Cases were categorized in the following manner: (1) diagnostic procedures: cerebral and spinal angiograms, (2) neurointervention procedures: mechanical thrombectomy, aneurysms simple coiling, aneurysm device-assisted coiling, flow diverter, cerebral arteriovenous malformation (AVM) embolization, cranial dural arteriovenous fistula (AVF) embolization, direct carotico-cavernous fistula (CCF) embo-

lization, pial fistula embolization, preoperative tumor embolization, and pediatrics: vein of Galen malformation embolization, and (3) others: percutaneous sclerotherapy and balloon occlusion test. No cases of extracranial stenting or intracranial angioplasty were performed.

Results

A total of 161 procedures were done. Types of procedures and their outcomes are highlighted in ►Table 1.

Diagnostic Procedures: Cerebral and Spinal Angiograms

Total 86 cerebral and 3 spinal angiograms were done. Age group ranged from 16 to 73 years, mean age was 46.8 years. Three-dimensional (3D) rotational angiography images were obtained for clear anatomic details. One patient had transient hemiparesis after angiography (patient with bilateral severe chronic middle cerebral artery [MCA] occlusion) which improved after hydration within 20 minutes. There was no procedure-related morbidity/mortality.

Neurointervention Procedures

Mechanical Thrombectomy

A total of 8 cases (age ranging from 26 to 67 years, mean age 45.3 years) were taken up for mechanical thrombectomy. Thrombolysis in cerebral infarction 2b/3 recanalization was achieved in six of these cases, while there was failure to recanalize two cases (one case of intracranial atherosclerosis and one case of cervical internal carotid artery [ICA] dissection). Both the failed cases underwent decompressive hemi-craniectomy but did not survive.

Aneurysm Endovascular Management: simple coiling/device-assisted coiling/flow diverter/braided stent monotherapy

A total of 41 procedures were performed in 41 patients, age ranging from 34 to 71 years, with mean age of 50.9 years. Thirty-eight of these were ruptured aneurysms, while two were unruptured large cavernous and paraclinoid aneurysms. The location of aneurysms is described in ►Table 2.

There were two cases of failure. One case was abandoned due to inability to cannulate the aneurysm and was subsequently clipped. Another case was unruptured large paraclinoid aneurysm which was planned for flow diverter placement. However, due to failure of crossing microcatheter across the neck of aneurysm, procedure was abandoned and patient was referred to higher center.

Simple coiling was done in 20 cases, balloon-assisted coiling was done in 13 cases, and stent-assisted coiling was done in 2 cases. Flow diverter was deployed in two cases (one ruptured supraclinoid aneurysm and one unruptured large cavernous-paraclinoid aneurysm). Braided stent monotherapy was done in two cases (V4 segment dissecting aneurysm and A1 segment aneurysm). Out of cases treated by coiling ($n = 35$), aneurysm occlusion of Raymond–Roy (RR) grade 1/2 was obtained in 30 cases, and RR grade 3 occlusion was noted in 5 cases. Out of these 5 patients, 3 patients expired (as mentioned below—two

Table 1 Procedures done and their outcomes

Name of procedure	Number of patients	Complications			Outcome			mRS 0-2 at discharge after intervention/surgery
		Failure	Intraprocedural	Perioperative	Morbidity	Mortality		
Diagnostic cerebral angiography	86	0	0	1 Transient hemiparesis	0	0	86	
Diagnostic spinal angiography	3	0	0	0	0	0	3	
Simple coiling of aneurysm	21	1 Underwent successful clipping	1 Coil prolapse causing occlusion of contralateral ACA during ACom aneurysm coiling	1 Hemiparesis due to thromboembolism detected on post procedure CT	2 Weakness of right lower limb in case of coil prolapse and hemiparesis due to thromboembolism	3 *Fischer grade 4 SAH at admission with severe spasm in two patients *Myocardial infarction	18	
Balloon-assisted coiling	13	0	0	1 Delayed MCA occlusion with MCA territory infarct	0	2 *Ventilator-associated pneumonia *Delayed MCA occlusion with MCA territory infarct	11	
Stent-assisted coiling	2	0	0	0	0	0	2	
Flow diverter	3	1 Failed due to inability to cross the aneurysm, referred to higher center	0	0	0	0	3	
Braided stent monotherapy	2	0	0	0	0	0	2	
AVM	5	2 (underwent successful surgery)	0	0	0	0	5	
Cranial dAVF	1	0	0	0	0	0	1	
Pial fistula with giant varices	1	0	0	0	0	0	1	
Direct carotico-cavernous fistula	4	0	0	1 Myocardial infarction	0	0	3	

Table 1 (Continued)

Name of procedure	Number of patients	Complications			Outcome		
		Failure	Intraprocedural	Perioperative	Morbidity	Mortality	mRS 0–2 at discharge after intervention/surgery
Vein of Galen malformation	1	0	0	0	0	0	1
Stroke mechanical thrombectomy	8	2 Intracranial atherosclerosis $n = 1$, long segment ICA dissection $n = 1$	0	0	0	2 *Failure to recanalize	6
Balloon occlusion test	8	0	0	0	0	0	8
Preoperative tumor embolization	1	0	0	0	0	0	1
Sclerotherapy	2	0	0	0	0	0	2
Total neurointerventions + 4 surgeries)	161	7	1	4	2	8	153 (149)

Abbreviations: ACA, anterior cerebral artery; ACom, anterior communicating artery; AVF, arteriovenous fistula; CT, computed tomography; dAVF, dural arteriovenous fistula; ICA, internal carotid artery; MCA, middle cerebral artery; mRS, modified Rankin Scale; SAH, subarachnoid hemorrhage.

Table 2 Location of aneurysms

Location of aneurysm	Number
Anterior circulation	35
Anterior communicating artery	15
Middle cerebral artery	1
Distal anterior cerebral artery	4
A1 segment of anterior cerebral artery	2
Posterior communicating artery	3
Supraclinoid internal carotid artery	9
Cavernous paraclinoid segment	1
Posterior circulation	6
Posterior inferior cerebellar artery	2
Vertebral artery V4 segment	1
P1 segment of posterior cerebral artery	1
Distal posterior cerebral artery	1
Basilar top	1
Total	41

patients had severe vasospasm in postoperative period and one patient developed ventilator-associated pneumonia) and two patients are planned for stent/flow diverter placement. Examples of procedures are shown in ►**Fig. 1**.

Procedure-related complications in the form of thromboembolism were noted in three cases, who developed hemiparesis. Two patients recovered with power 4/5 at time of discharge. The other patient developed delayed MCA territory infarct on postoperative day 4. Decompressive hemicraniectomy was done, however the patient died. Four patients had nonprocedure-related mortality (1 patient had myocardial infarction on postoperative day 12, 1 patient succumbed to ventilator-associated pneumonia, and 2 patients succumbed to vasospasm).

Follow-up was available for 29 patients ranging from 1 month to years. On follow-up, 28 patients had modified Rankin Scale (mRS) 0 and 2 patients had mRS 1 (patients with thromboembolic complication). Two patients developed hydrocephalus on 1-month follow-up and were shunted.

Cerebral AVM Embolization

A total of 5 procedures were done (age ranging from 15 to 65 years, mean age 35.4 years). Successful, complete embolization was done in three patients while there were two cases of failure because of inability to reach the nidus (out of these two patients, one was operated and the other was referred for gamma knife radiosurgery). Embolization was done using detachable tip microcatheters with injection of liquid embolic agent (onyx/squid) under blank roadmaps. There were no periprocedural complications, morbidity, or mortality. Six-

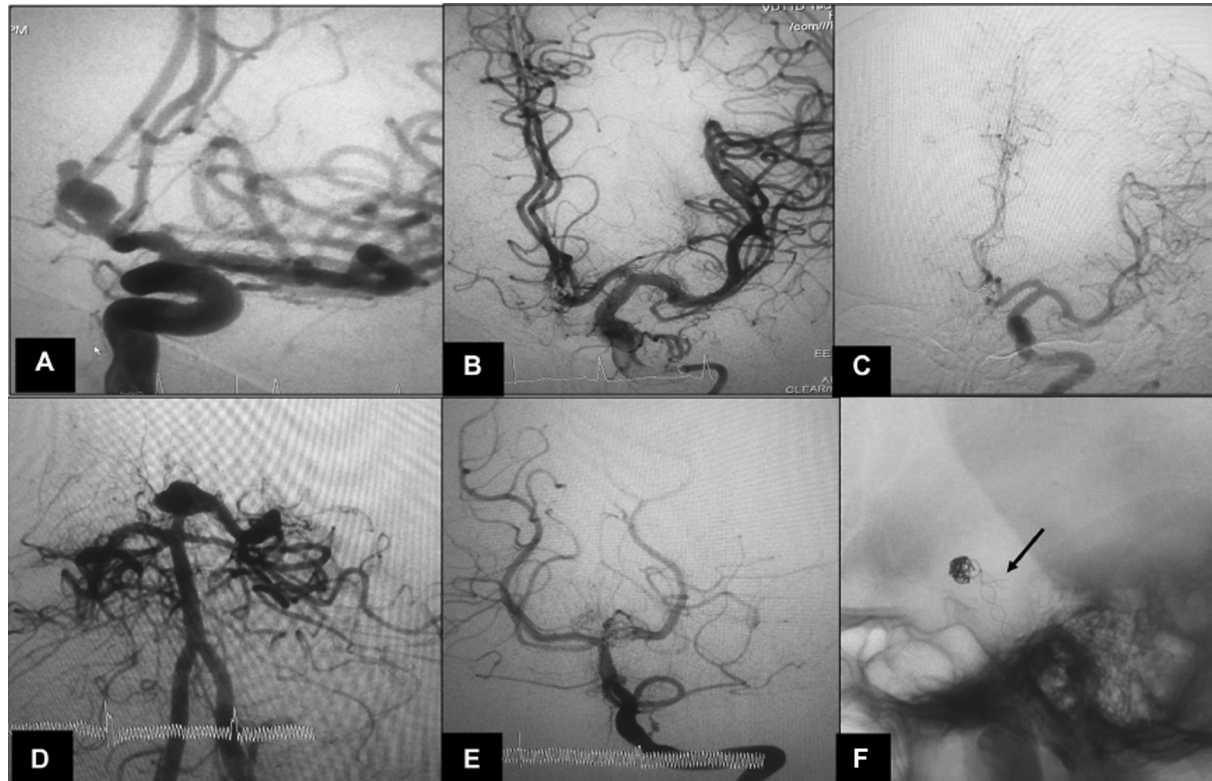


Fig. 1 Endovascular treatment of aneurysms. (A–C) Showing coiling of anterior communicating artery aneurysm. (A) Angiogram shows lobulated anterior communicating artery aneurysm. (B) Postcoiling angiogram and (C) 6-month follow-up angiogram showing obliteration of aneurysm with patent intracranial vessels. (D–F) Stent-assisted coiling of P1 segment aneurysm. (D) Anterior-posterior (AP) angiogram images showing left P1 segment fusio-saccular aneurysm. (E) Poststent assisted coiling image shows obliteration of aneurysm with patent left posterior cerebral artery (PCA). (F) Native image showing coil mass and Baby Leo stent in situ from left P1 till basilar artery.

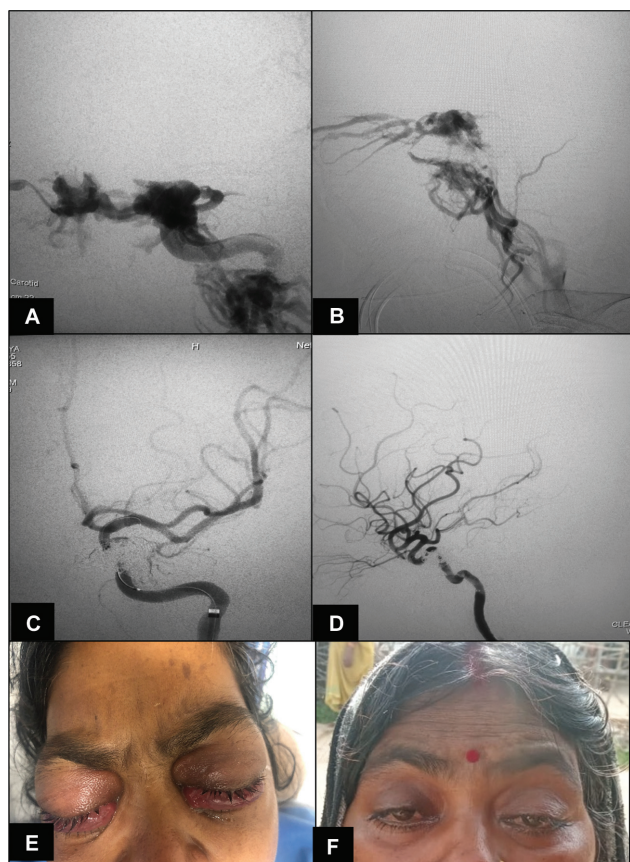


Fig. 2 Endovascular treatment of left direct carotico-cavernous fistula. (A, B) Anterior-posterior (AP) and lateral view of angiogram shows left side direct carotico-cavernous fistula with reflux into superior ophthalmic vein, pterygoid venous plexus with reflux noted through intercavernous connections into right cavernous sinus (causing bilateral symptoms). (C, D) Postcoiling and onyx embolization AP and lateral views show obliteration of fistula with normal filling of intracranial vessels. (E) Preprocedure image showing bilateral proptosis, chemosis, and conjunctival prolapse. (F) Three weeks postprocedure clinical image showing resolution of proptosis, chemosis, and conjunctival prolapse with mild partial ptosis.

month follow-up magnetic resonance angiography was available for one patient which showed no residual nidus.

Cranial Dural AVF Embolization

One case of transverse sinus dural AVF embolization was done in a 50-year-old patient using onyx through middle meningeal artery and occipital artery feeders. Complete occlusion of fistula was noted. No procedure-related complication was noted.

Direct Carotico-cavernous Fistula Embolization

A total of four procedures were done (age ranging from 16 to 64 years, mean age 41.2 years) through transarterial route, using combined coil and onyx/squid embolization with placement of balloon across the rent in ICA. Complete embolization was achieved in three cases. One patient had large rent and coils did not stay inside the sac even with balloon inflation. Due to this, balloon occlusion test was performed and surgical ICA occlusion was done because the

patient tolerated balloon occlusion test well. One patient had myocardial infarction 36 hours after procedure and expired. Remaining three patients are doing well on clinical follow-up with no recurrence of symptoms. ► **Fig. 2** shows example of transarterial embolization of direct CCF.

Pial AVF with Giant Varices Embolization

One case of pial fistula with giant venous varices, with arterial supply from anterior cerebral artery was embolized using coil and onyx in a 23-year-old patient. Complete embolization was achieved with no periprocedural complication.

Preoperative Tumor Embolization

In one case of sacral giant cell tumor preoperative tumor embolization was performed in a 59-year-old patient, through transarterial route using polyvinyl alcohol particles (350–500 μ m). Postoperative tumor resection was done and complete excision of tumor was possible with operative blood loss of 750 mL. No perioperative complications were noted.

Pediatrics: Vein of Galen Malformation Embolization

One case of vein of Galen transarterial embolization was done in a 3-year-old child using 50% glue. Complete occlusion of fistula was noted. No procedure-related complication was noted.

Others

Sclerotherapy

Percutaneous sclerotherapy were done in two patients (17 and 45 years old), using injection bleomycin and injection sodium tetradecyl sulfate. No periprocedural complications were noted.

Balloon Occlusion Test

A total of eight cases (age ranging from 16 to 65 years, mean age 45.2 years) were taken up for balloon occlusion test for various indications including direct CCF ($n = 5$), ICA aneurysm ($n = 2$), and meningioma encasing ICA ($n = 1$). Procedure was done under local anesthesia with and without hypotension challenge. There were no periprocedural complications, morbidity, or mortality.

Summary of Procedure-Related Complications

There were no hemorrhagic complications due to rupture or dissection. Ischemic complications were noted in form of thromboembolic complications in three cases and vessel occlusion (delayed MCA occlusion) in one case.

Summary of Outcomes

Angiographic outcome: Among the 72 cases of therapeutic procedures, angiographic success was noted in 60 cases, partial success was noted in 5 cases (RR grade 3 occlusion), and failure was noted in 7 cases (2 cases of mechanical thrombectomy, 1 case of coiling, 1 case of flow diverter, 1 case of CCF, and 2 cases of cerebral AVM).

Patient outcome: Among therapeutic cases ($n=72$), patient outcome was categorized as improved (with mRS 0–2 at discharge) in 64 cases (60 neurointerventions, 4 converted to surgery), morbidity in form of weakness was noted in 2 cases, and mortality was noted in 8 cases (► **Table 1**).

Management of Cost of Consumables

The total cost of consumables utilized in these cases was INR 13,341,873 (\$181,302.5). Note that 84.7% of our intervention cases (61/72) with consumables amounting to the cost of INR 11,192,400 (\$152,093.4) were done free of cost for poor patients using Ayushman Bharat Pradhan Mantri Jan Arogya Yojana (AB PMJAY). In this way, we were able to treat majority of patients free of cost.

Discussion

Our institute is located in Central India in the state of Madhya Pradesh which has a population of 72.7 million (2011 census) with a large portion comprising of rural and tribal population. Being a backward state, 32% population of Madhya Pradesh is below poverty line.⁴ Whatever limited neurointervention facilities present in the state, are mainly located in the private sector, which cannot be afforded by majority of population in the area. Poor patients needing neurointervention had to travel large distances (200–500 miles) to get these facilities in a public institute. As a large number of these cases need to be done on an emergency basis, a large population was deprived of these treatment facilities.

Establishing a new neurointervention facility in a government setup in a backward region is challenging. The main barriers are lack of equipment, deficiency of cath-laboratory trained individuals, lack of awareness, lack of consumables, and the extremely high cost of consumables for neurointerventions.

Super Speciality Hospital, Jabalpur, Madhya Pradesh, India, was started in 2018 where biplane neuroangiography suite (Artis Zee, Siemens) was installed. However, because of lack of trained professionals, the services were not started until November 2019. Neurointerventions were done by a team comprising of a neuroradiologist (N.Y.), neurosurgeons (A.K. and K.H.), and neuroanesthetists (K.R., A.J.).

We had to face several limitations leading to difficulty in establishment of the neurointervention facility. Nursing staff with no previous training in cath-laboratory were individually trained by conducting multiple lectures, boot camps, and hands-on training sessions. Similarly, general radiography technicians (trained only in handling X-ray radiography) were trained to handle biplane neuroangiography machine with the help of application experts and neuroradiologist. Teaching sessions were conducted by the neuroradiologist to train them in basic views of angiography, acquiring DynaCT, roadmaps, 3D acquisitions, and in reducing radiation exposure.

Collaboration with multiple departments was established to provide care for patients requiring neurointervention.

Neurosurgery, neurology, internal medicine, and neuroanesthesia departments were actively involved in patient care. Initially, multiple seminars and sessions were conducted with these departments to familiarize the type of cases which would benefit from neurointervention. Sessions were also conducted with residents attending the emergency services, who would be the first contact of many of these cases. They were also trained regarding the protocol to be followed for stroke patients. Similar training was also provided to technicians working at CT/MRI scan center to prioritize stroke patients.

Due to lack of awareness among the practicing doctors in the region of availability of neurointervention services, multiple interactive awareness sessions were also conducted outside the institute. Awareness among public was also created using media outlets. Gradually, we started getting referrals not only from within the city but also from neighboring cities with patients travelling 200 to 300 miles, due to lack of any other nearby public-funded facility for these procedures.

There was no established chain of supply of neurointervention consumables in the region. Due to remote location and no previous established infrastructure, companies had to be convinced to start supply in the region. After appointment of required personnel, the supply chain was established. Initially, consumables were dispatched from cities like Raipur, Bhopal, or Delhi (located 217, 200, and 530 miles away, respectively). Due to this initially, ischemic stroke cases could not be started. With increasing number of cases, the supply chain was shifted to the city and consumables were available in the laboratory. Following this, we were able to start mechanical thrombectomy cases.

Another major barrier was the high cost of consumables due to which most patients cannot afford neurointerventions. AB PMJAY is an ambitious project launched by the prime minister to help the poor patients with an aim toward universal health coverage.⁵ We utilized this scheme to provide financial support for neurointervention cases.

Results of our newly established center show procedural success rate of 90.2% (65/72), failure rate 9.7% (7/72), with 2.7% procedure-related morbidity (2/72), and 1.3% procedure-related mortality (1/72), which are comparable to the available literature.^{3,6} With availability of diagnostic angiography, management of cerebral and spinal vascular lesions have improved. Many of the complex cases which require detailed neurovascular anatomical information before neurosurgical procedures such as AVM, dural fistulas, etc. had to be referred to higher centers previously. With the availability of diagnostic and therapeutic angiographic procedures, these cerebrovascular disorders are now being successfully managed at our institute.

We suggest that team work with collaboration of neuroradiologists, neurosurgeons, neuroanesthetists, neurologists, physicians, nursing staff, and technicians is absolutely essential for starting neurointervention services. With the help of government's efforts of establishing infrastructure at public-funded institutions, and provision of universal health coverage schemes, these facilities can be

provided even in remote places. This can help in significantly reducing the burden on tertiary health centers. Such an effort at other places in the country will also help to provide access to these high-end neurointervention facilities for the general masses free of cost in the public sector.

Conclusion

Advanced neurointervention services can be provided even in backward regions in LMICs with outcomes similar to existing literature. The barriers can be overcome by supplying more government hospitals with angiography laboratory equipment and by training more doctors in the field of neurointervention. Training of nurses, general radiographers, and paramedical staff in cath-laboratory can be done at the institute level. Proper use of government schemes such as AB PMJAY will allow the poorest of the patients to get access to these life-saving procedures. With these efforts, our center is now capable of successfully handling majority of vascular neurointervention cases which had to be referred to higher centers previously. Our institute is now the only "Stroke Ready Institute" among the government hospitals in Central India.

Ethical Approval

The study has been approved by the appropriate ethics committee and has therefore been performed in accordance with the ethical standards laid down in the 1964 Declaration of Helsinki and its later amendments.

Informed Consent

Informed consent was gathered from the patient and consent to publish images was obtained.

Funding

The author(s) received no financial support for the research, authorship, and/or publication of this article.

Conflict of Interest

The author(s) declared no potential conflicts of interest with respect to the research, authorship, and/or publication of this article.

References

- 1 Pandian JD, Srikanth V, Read SJ, Thrift AG. Poverty and stroke in India: a time to act. *Stroke* 2007;38(11):3063–3069
- 2 Ambekar S, Madhugiri V, Pandey P, Yavagal DR. Cerebral aneurysm treatment in India: results of a national survey regarding practice patterns in India. *Neurol India* 2016;64(Suppl):S62–S69
- 3 Harsha KJ. Successful endovascular neurosurgical practice in resource-poor exclusive rural neuro-hospital setup. *J Neurosci Rural Pract* 2016;7(Suppl 1):S13–S17
- 4 India SDG. Accessed December 8, 2020 at: sdgindiaindex.niti.gov.in
- 5 Angell BJ, Prinja S, Gupt A, Jha V, Jan S. The Ayushman Bharat Pradhan Mantri Jan Arogya Yojana and the path to universal health coverage in India: overcoming the challenges of stewardship and governance. *PLoS Med* 2019;16(03):e1002759
- 6 Fennell VS, Martirosyan NL, Palejwala SK, Lemole GM Jr, Dumont TM. Morbidity and mortality of patients with endovascularly treated intracerebral aneurysms: does physician specialty matter? *J Neurosurg* 2016;124(01):13–17