



Depiction of Cerebral Aneurysm Wall by Computational Fluid Dynamics (CFD) and Preoperative Illustration

Riki Tanaka¹ Boon Seng Liew¹ Yasuhiro Yamada¹ Kento Sasaki¹ Kyosuke Miyatani¹
Fuminari Komatsu¹ Tsukasa Kawase¹ Yoko Kato¹ Yuichi Hirose¹

¹Department of Neurosurgery, Fujita Health University Bantane Hospital, Nagoya, Aichi, Japan

Address for correspondence Boon Seng Liew, MD, MS, Department of Neurosurgery, Hospital Sungai Buloh, Jalan Hospital, 47000 Sungai Buloh, Selangor, Malaysia (e-mail: liew_bs@yahoo.com).

AJNS 2022;17:43–49.

Abstract

Introduction Preoperative illustration is a part of an important exercise to study the configuration, direction, and presence of any perforations, and is the weakest point in the wall of the cerebral aneurysm. The same illustration is used to study the surrounding brain structures to decide the best and safe surgical approach prior to any surgical procedure. With the evolution of the aneurysm wall study and study of flow dynamic within the involved artery and its aneurysm wall using computational fluid dynamics (CFD), a better surgical plan can be formulated to improve the flow dynamics. As one of the clinical applications of CFD, we propose a study using a composite image that combines preoperative illustration and CFD, which is traditionally widely used in neurosurgery.

Keywords

- ▶ cerebral aneurysm
- ▶ computational fluid dynamics
- ▶ preoperative illustration
- ▶ preoperative planning

Methods and Materials We study the use of illustrations of the unruptured cerebral aneurysm of internal carotid-posterior communicating (ICPC) artery and anterior communicating artery (AcomA) treated at our hospital. The combinations of both preoperative illustrations and CFD images by using “ipad Pro” were used.

Result and Conclusion Medical illustration in the preoperative study of unruptured cerebral aneurysm with combinations of CFD and surrounding brain structures is helpful to decide the surgical approaches and successful surgical treatments.

Introduction

The architecture or configuration of an aneurysm must be understood by studying its three-dimensionality preoperatively.¹ Preoperative illustration is part of important exercise to study the configuration, direction, presence of any perforations and the weakest point in the wall of the cerebral aneurysm. The same illustration is used to study

the surrounding brain structures to decide the best and safe surgical approach prior to any surgical procedure. With the evolution of the aneurysm wall study and study of flow dynamic within the involved artery and its aneurysm wall using computational fluid dynamics (CFD), a better surgical plan can be formulated to improve the flow dynamics. As one of the clinical applications of CFD, we propose a study using a composite image that combines preoperative illus-

published online
June 13, 2022

DOI <https://doi.org/10.1055/s-0042-1749148>.
ISSN 2248-9614.

© 2022. Asian Congress of Neurological Surgeons. All rights reserved.

This is an open access article published by Thieme under the terms of the Creative Commons Attribution-NonDerivative-NonCommercial-License, permitting copying and reproduction so long as the original work is given appropriate credit. Contents may not be used for commercial purposes, or adapted, remixed, transformed or built upon. (<https://creativecommons.org/licenses/by-nc-nd/4.0/>)

Thieme Medical and Scientific Publishers Pvt. Ltd., A-12, 2nd Floor, Sector 2, Noida-201301 UP, India

tration and CFD, which is traditionally widely used in neurosurgery.

This spatial construct must be viewed from an intraoperative perspective by taking into account the limitations of the surgical corridor (based on the selected surgical approach), and to anticipate the most suitable sizes, shapes, and positions of clips.¹ The understanding and utilization of CFD in real life practice among European neurosurgeons were low in a study conducted by Singh et al in 2009.² The early identification of the region of aneurysm sac which is a high risk of intraoperative rupture is essential to avoid such incidence during surgery. A study showed intraoperative rupture cases have resulted in a 3.21-fold risk of unfavorable outcome compared with those without it.³

Methods and Materials

We study the use of illustrations of the unruptured cerebral aneurysm of internal carotid-posterior communicating (ICPC) artery and anterior communicating artery (AcomA) treated at our hospital. The combinations of both preoperative illustrations and CFD images by using "Ipad Pro" were used.

Data Acquisitions

Preoperative computed tomography (CT) angiography (CTA) was acquired in Digital Imaging and Communications in Medicine (DICOM) format at the planning station (Amin Corporation ZIO station2). Subsequently the constructed images were sent to another software, Hemoscope to generate the CFD images.

Preoperative Illustrations

1. Illustration equipment used, application:
 - iPad pro (10.5 inch) and Apple Pencil.
 - Procreate.
2. CFD equipment used, application:
 - Amin Corporation ZIO station2 and Hemoscope.
 - Parameters: pressure, WSS, streamline, vector.
3. Combination of both images
 - Adobe Photoshop MIX.

CFD Evaluation

The first study of CFD to learn about the origin and growth of intracranial aneurysms, was done by Gonzalez et al, using non-Newtonian viscosity of blood and other hemodynamic data via computer simulation.⁴ He found that due to the pressure changes during systolic and diastolic, these rapid changes of blood flow direction result in rapid changes in wall shear stress (WSS) and pressure at the proximal and distal walls of the cavity, rendering continuous damage to the intima at the cavity neck. More work has been done since then by the application of Newtonian viscosity in computing cerebral aneurysm hemodynamically.

Since CFD is a three-dimensional (3D) image, the amount of information is very large, and evaluating only CFD may lead to

misjudgment. The evaluation may be more useful with the study of the anatomical relationship with surrounding brain structures. An example of the image generated using CFD is shown below (► Fig. 1). The colors used are related to the blood flow velocity within the vessel. Most modelling are using 3D CTA images. While four-dimensional (4D) CTA images allow wall motion analysis which lead to a more accurate prediction of rupture,⁵ however, if the heterogeneous material properties and thicknesses of the aneurysm wall during cardiac cycles are to be known, the wall motion can be predicted. Other imaging modalities to generate CFD data include two-dimensional phase contrast magnetic resonance imaging (pcMRI) and 4D MRI.^{6,7} Time-averaged WSS is used to predict the wall degradation and remodelling.^{7,8} WSS "vector," is used to indicate the viscous force vector per unit area of the aneurysm wall. The oscillatory shear index (OSI) is used to quantify the changing direction of the WSS vector over the cardiac cycle.⁸ However, the software Hemoscope does not have the OSI value for the study in this paper.

Case 1: Internal Carotid-Posterior Communicating (ICPC) Artery Aneurysm

We showed an example of preoperative evaluation of an unruptured ICPC artery aneurysm. The cranial CT angiogram showed a saccular aneurysm of the left ICPC artery pointing toward the inferio-posterio-lateral temporal lobe (► Fig. 2)

Based on the CT angiogram, a CFD study was performed using the Amin Corporation ZIO station2 and Hemoscope. The analyses of the wall pressure, WSS, streamline, and vector were made (► Fig. 3). To obtain a proper CFD analysis, the truncated parent vessel plays an important role especially in posterior communicating artery (PcomA) and AcomA aneurysms where upstream curvature was substantial. Hence the inclusion of the upstream portion of the parent vessel of cerebral aneurysms is necessary in the CFD study for accurate analyses of the intra-aneurysmal hemodynamics.⁹ Hence long truncated internal carotid vessel was included in the CFD study of ICPC artery aneurysm as shown below.

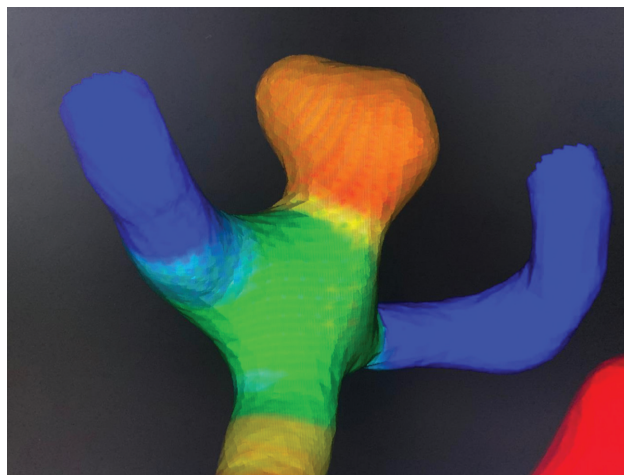


Fig. 1 Single image of vessels with computational fluid dynamics (CFD). Limited information on the side (right/left), approach (pterional, interhemispheric) and vessels involved (middle cerebral artery, MCA, or AcomA).

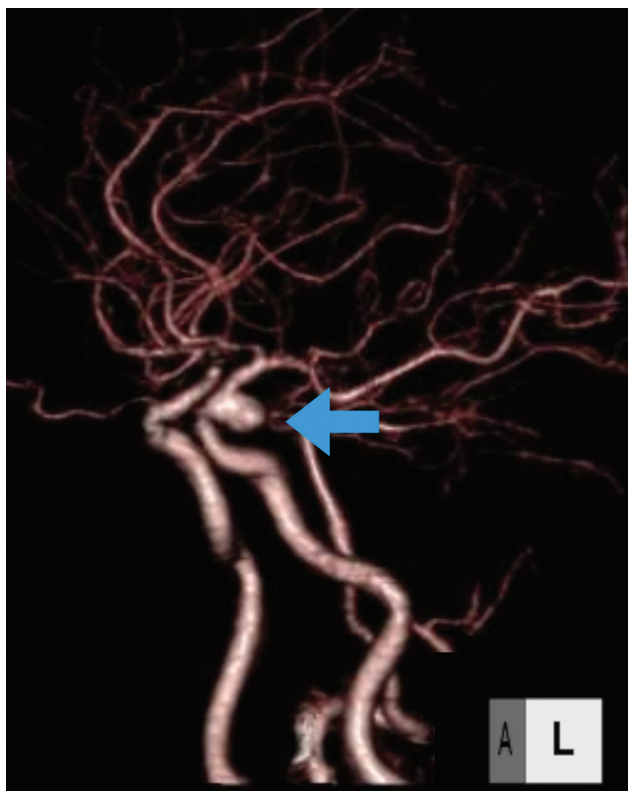


Fig. 2 Left ICPC artery saccular aneurysm. ICPC, internal carotid-posterior communicating.

The images generated using the Hemoscope was extracted as a single vessel (► Fig. 4).

An anatomical illustration of the surrounding brain structures viewed from the pterional approach was made using the iPad pro (10.5 inch), Apple Pencil, and Procreate (► Fig. 5).

The next step was combining both the images from the illustration and the vessels generated with CFD according to the CT angiogram using the Adobe Photoshop MIX (► Fig. 6).

In the actual surgical procedure with pterional approach, the exact anatomical relationship of the ICPC artery aneurysm and the surrounding brain structures was found (► Fig. 7).

Case 2: Left Anterior Communicating Artery (AcomA) Aneurysm (Right Pterional Approach)

The same steps were used in the second illustrated case of an unruptured AcomA aneurysm. The CTA is shown below (► Fig. 8).

After CFD of the aneurysm was performed, the illustration of the brain according to the surgical approach was made, and combination of both images can be visualized as shown below (► Fig. 9).

Discussion

The study of CFD has become an important preoperative step to determine the best surgical approach. A high-quality 3D dataset is fundamental and high-resolution images such as digital subtraction angiography or CT angiography are widely used.¹⁰ In our cases, we used CT angiogram Digital Imaging

and Communications in Medicine (DICOM) images to generate the CFD images. CFD simulations are for the prediction of aneurysm rupture. The geometry might have changed after a rupture, which will produce hemodynamic differences.¹⁰ Few assumptions are made to generate simulated flow dynamics. Those assumptions include incompressible laminar flow, blood material properties, and boundary conditions.¹⁰

WSS is a frictional force on the arterial wall produced by blood flow in a direction toward a local tangent plane. Although the relationship of the WSS value to the growth of the aneurysm sac was inconsistent in many reports, majority of studies found a low WSS associated with higher risk of rupture. This is because aneurysm wall could no longer sustain the arterial pressure due to the degeneration and thinning of the arterial walls caused by low WSS.¹⁰

High WSS at the blood flow jet impingement zone is related to the initiation of aneurysms.^{10,11} After aneurysm initiation, a high WSS causes degeneration of the cellular matrix and cell apoptosis. While at low WSS, the aneurysm may become larger because inflammation caused by slow recirculation and a disturbed flow environment promote the formation of atherosclerotic plaques, which exacerbate the effects on inflammatory cells.^{10,11} A low WSS may trigger aneurysm rupture. The change in the geometry of an aneurysm may also be affected by the different types of tissue and/or bone structures neighboring the aneurysm.

Choice of Imaging

Pre-rupture aneurysm imaging is selected for CFD study as to predict future rupture because the geometries reconstructed from the rupture arterial images have different values in CFD parameters.¹⁰ In another study of CFD modelling using cases of ruptured cerebral aneurysm, the modified Krieger model found that ruptured aneurysms are usually correlated with lower WSS values than unruptured ones.¹²

Aneurysmal Wall Properties

Wall stress due to the blood flow within a cerebral vessel and the mechanical properties of the arterial wall are the predominant factors for the rupture of aneurysm.¹³ A thin aneurysm sac wall was associated with low WSS, with higher risk of rupture.¹⁴ Between two saccular aneurysm with the same size of dome, the rupture risk is higher in the one with a larger diameter of the aneurysm neck.¹³ Aneurysm rupture occurs when the tissue stress exceeds the tissue strength. The CFD analyses provide an estimate of the intrasaccular hemodynamics based on rigid wall of aneurysm sac with no parameter of stress within the aneurysm wall.⁸ Newtonian assumption was used in almost 90% of published studies in a meta-analysis by Saqr et al.¹⁵ However, as too many assumptions are taken into account in the CFD analyses, especially in blood viscosity using either Newtonian and non-Newtonian CFD Models, more researches are needed to further characterize the nature of blood flow which contribute to the improved understanding of the formation and growth of cerebral aneurysms.¹⁶ Nevertheless, CFD models are useful in improving the understanding of these mechanisms, and

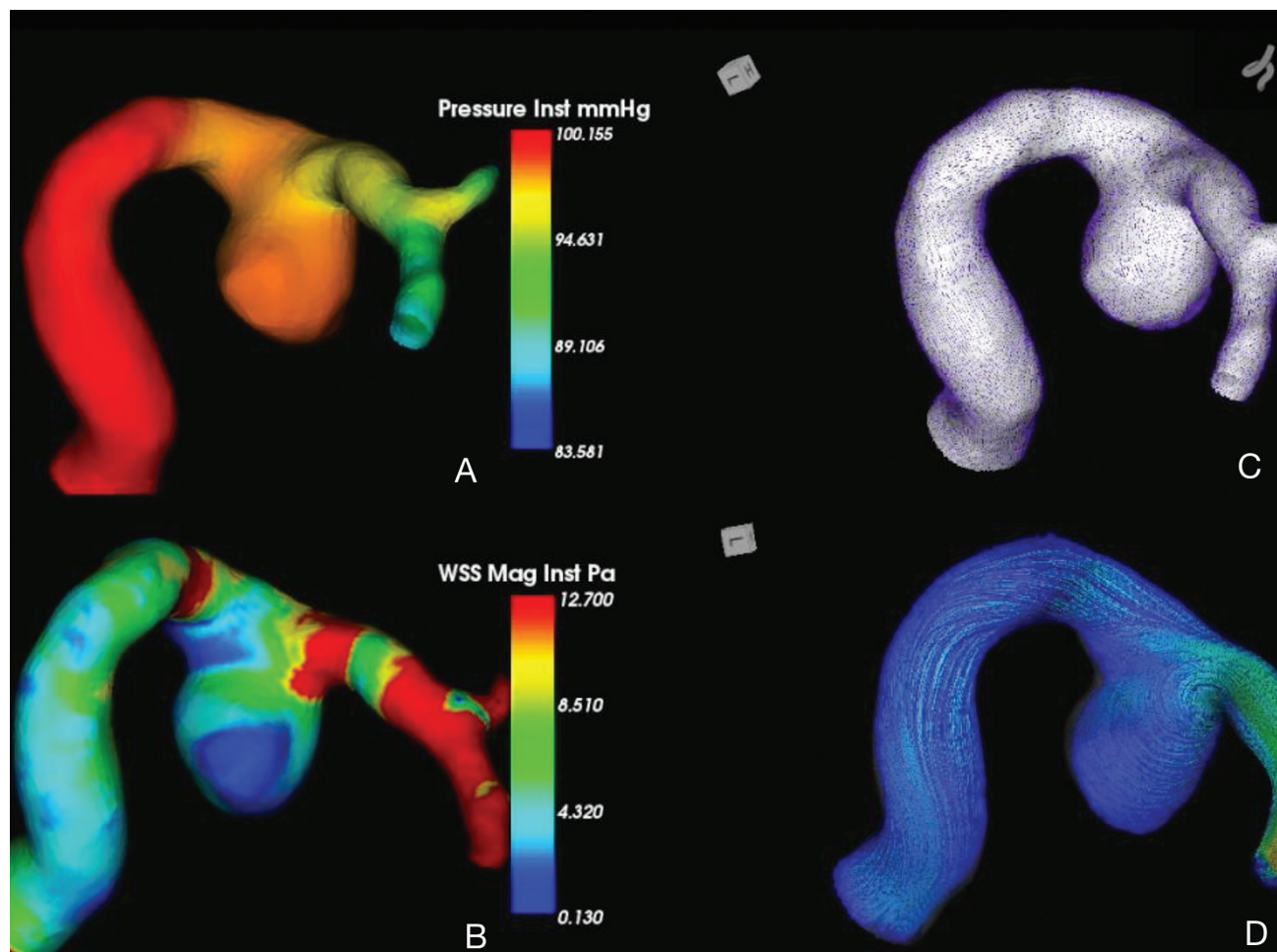


Fig. 3 Computational fluid dynamics (CFD) using the Amin Corporation ZIO station2 and Hemoscope. (A) Wall pressure showed higher wall pressure compared with the distal vessel. (B) The wall shear stress (WSS) showed low WSS indicating high risk of rupture especially over lateral wall of the dome. (C) The vector WSS showed divergent vectors indicating turbulence flow with the aneurysm sac. (D) The streamline indicating laminar flow directions within the aneurysm sac.

highlight the great potential of patient-specific computational models for clinical use in the assessment of aneurysm rupture risk and patient management.¹¹ A meta-analysis showed that decreased local WSS may be an important predictive parameter of intracranial aneurysm rupture.¹⁷ The differences in shape and geometry on aneurysms affect the hemodynamic trends.¹⁸

The Need to Have Preoperative Planning

The transition from large craniotomies to smaller ones provided a more tailored approach that minimizes brain exposure while continuing to provide adequate visualization without marginalizing safety.¹⁹ To achieve this, surgeons must have the ability to create a mental visualization of the aneurysm with the surrounding structures such as both proximal and distal vessels, perforators, cranial nerves, veins and brain parenchymal via the selected surgical approach. A neurosurgeon obtains proximal and distal control, performs dissection of perforators and the aneurysm neck, and eventually closes and obliterates the aneurysm with a tailored approach without additional risk to the patient.¹⁹ 3D DSA simulation alone or 3D DSA simulation with printed model

may be used for simulation of the best operative approach and selection of the most suitable aneurysm clips in the preoperative plan.^{20–22} However, the limitation of this 3D printed model or 3D DSA simulation images is the lack of other surrounding brain structures.

Preoperative Three-Dimensional Planning

A proper patient selection and preoperative planning and surgical simulation are indeed very important. A poor patient selection and proper preoperative planning may result in surgical mishaps.²³ A complete understanding of the 3D anatomy of the case preoperatively is important. The knowledge of the location of any perforators or main arterial branch is relative to the neck and dome of the aneurysm is important especially if located behind the operative field.¹⁹

Preoperative simulation with the presence of surrounding brain structures will enable the surgeon to choose a better head position which will allow the displacement of the brain after arachnoid dissection. This allows retractorless surgery to be performed. The placement of retractors can result in ischemia due to microcirculation spasms.¹⁹ The use of an endoscope allows for the final inspection of the anatomy

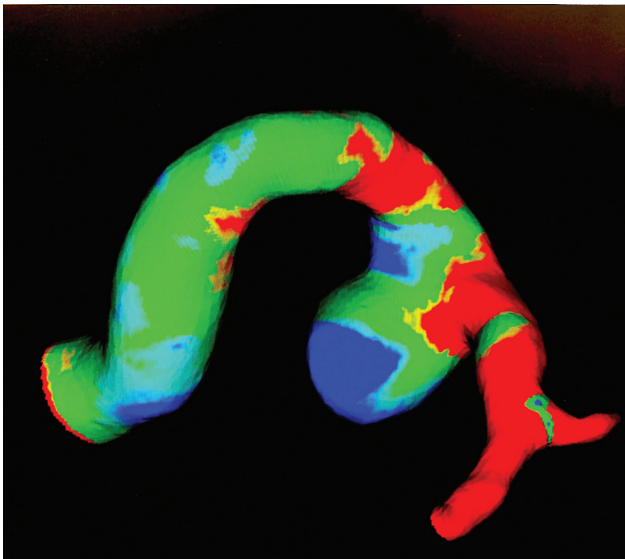


Fig. 4 The extracted wall shear stress image of the ICPC artery aneurysm. ICPC, internal carotid-posterior communicating.

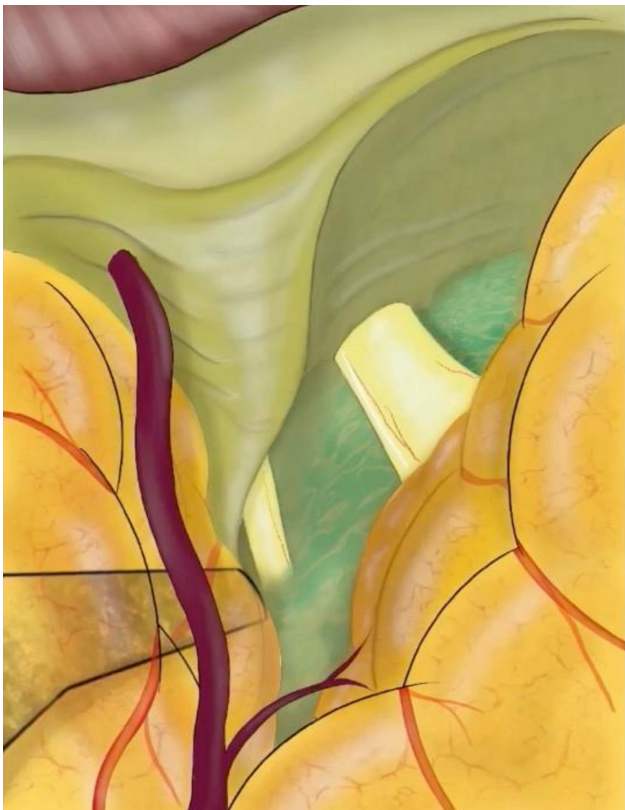

Fig. 5 An anatomical illustration of the surrounding brain structures viewed from the pterional approach was made using the iPad pro (10.5 inch), Apple Pencil, and Procreate.

around the aneurysmal neck before and after clipping in small deep spaces.¹⁹

Virtual reality workstations, such as the Dextroscope virtual reality used in the cerebral aneurysm clipping procedure, generate images of arterial blood vessels and the surrounding bone perfectly,¹ while images surrounding other structures

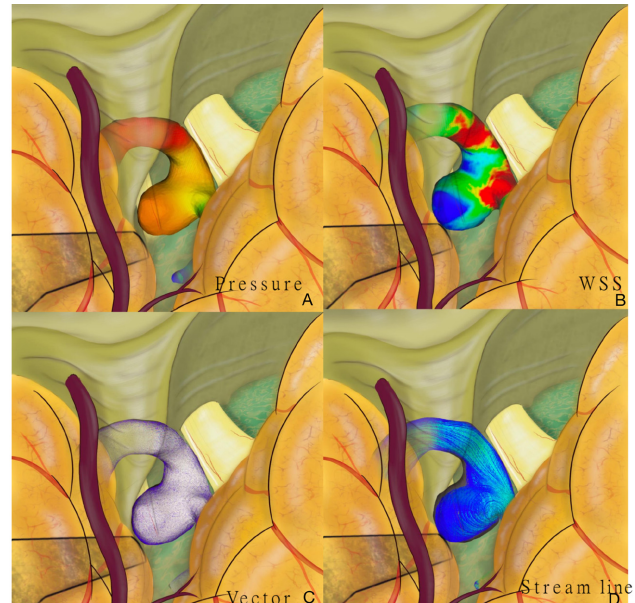


Fig. 6 Combined images of CFD images of the ICPC artery aneurysm with the brain structures. (A) Combined images showed high wall pressure over the whole aneurysm sac with wide neck. (B) Combined images showed an aneurysm dome with low WSS indicating risk of rupture pointing toward the temporal lobe and the cranial nerve (CN) III (below the aneurysm sac). (C) The combined vector. (D) The streamline within the ICPC artery aneurysm. CFD, computational fluid dynamics; ICPC, internal carotid-posterior communicating; WSS, wall shear stress.

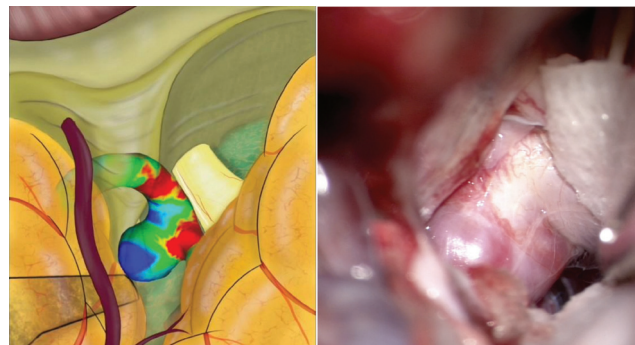


Fig. 7 The comparison with the preoperative medical illustration and the actual microscopic view.

such as cranial nerves, veins, and brain parenchymal may not be accurately constructed. Hence the option to utilize a cheaper option with preoperative illustration as shown in this paper may be applied.

The surgical outcomes associated with the clipping of ruptured aneurysms are usually poorer than those seen in unruptured cases.¹ Hence in our institution, early detection and treatment are the goals of the department. Those patients with symptomatic or asymptomatic but with risk factors such as advanced age and hypertension should be investigated with magnetic resonance angiogram. The success rate with no surgical morbidity and minimal morbidity can be achieved with surgical treatment of unruptured

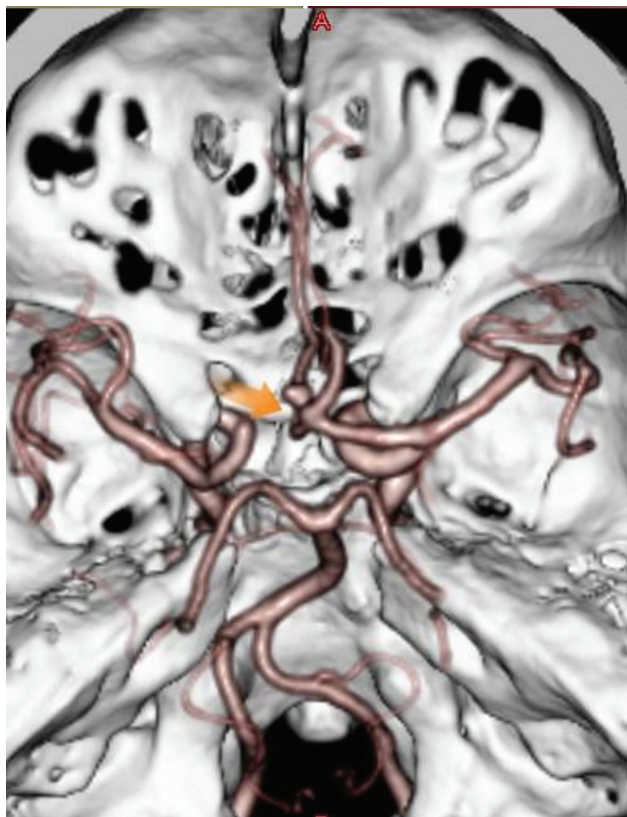

Fig. 8 AcomA saccular aneurysm pointing right side in the top view.

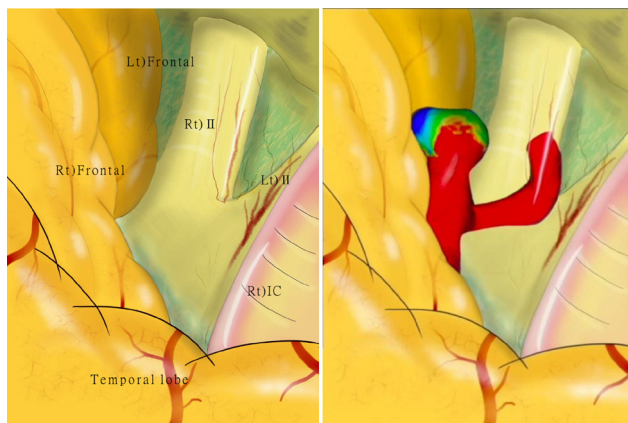


Fig. 9 The illustration of the structures seen in right pterional approach (left) and combination of both images including the one generated by CFD (right). CFD, computational fluid dynamics.

cerebral aneurysm by utilizing a proper preoperative evaluation and surgical strategies.

Conclusion

It is considered that it will be easier to compare and examine the intraoperative image by synthesizing and incorporating CFD in the illustration, and we propose it as one of the clinical utilization methods of CFD.

Funding

None.

Conflict of Interest

None declared.

References

- 1 Kockro RA, Killeen T, Ayyad A, et al. Aneurysm surgery with preoperative three-dimensional planning in a virtual reality environment: technique and outcome analysis. *World Neurosurg* 2016;96:489–499
- 2 Singh PK, Marzo A, Coley SC, et al. The role of computational fluid dynamics in the management of unruptured intracranial aneurysms: a clinicians' view. *Comput Intell Neurosci* 2009; 2009:760364
- 3 Hsu CE, Lin TK, Lee MH, et al. The impact of surgical experience on major intraoperative aneurysm rupture and their consequences on outcome: a multivariate analysis of 538 microsurgical clipping cases. *PLoS One* 2016;11(03):e0151805
- 4 Gonzalez CF, Cho YI, Ortega HV, Moret J. Intracranial aneurysms: flow analysis of their origin and progression. *AJNR Am J Neuroradiol* 1992;13(01):181–188
- 5 Vanrossomme AE, Eker OF, Thiran JP, Courbebaisse GP, Zouaoui Boudjeltia K. Intracranial aneurysms: wall motion analysis for prediction of rupture. *AJNR Am J Neuroradiol* 2015;36(10): 1796–1802
- 6 Karmonik C, Zhang YJ, Diaz O, et al. Magnetic resonance imaging as a tool to assess reliability in simulating hemodynamics in cerebral aneurysms with a dedicated computational fluid dynamics prototype: preliminary results. *Cardiovasc Diagn Ther* 2014;4(02):207–212
- 7 Brindise MC, Rothenberger S, Dickerhoff B, et al. Multi-modality cerebral aneurysm haemodynamic analysis: *in vivo* 4D flow MRI, *in vitro* volumetric particle velocimetry and *in silico* computational fluid dynamics. *J R Soc Interface* 2019;16(158):20190465
- 8 Robertson AM, Watton PN. Computational fluid dynamics in aneurysm research: critical reflections, future directions. *AJNR Am J Neuroradiol* 2012;33(06):992–995
- 9 Castro MA, Putman CM, Cebal JR. Computational fluid dynamics modeling of intracranial aneurysms: effects of parent artery segmentation on intra-aneurysmal hemodynamics. *AJNR Am J Neuroradiol* 2006;27(08):1703–1709
- 10 Murayama Y, Fujimura S, Suzuki T, Takao H. Computational fluid dynamics as a risk assessment tool for aneurysm rupture. *Neurosurg Focus* 2019;47(01):E12
- 11 Sforza DM, Putman CM, Cebal JR. Computational fluid dynamics in brain aneurysms. *Int J Numer Methods Biomed Eng* 2012;28(6-7):801–808
- 12 Saqr KM. Computational fluid dynamics simulations of cerebral aneurysm using Newtonian, power-law and quasi-mechanistic blood viscosity models. *Proc Inst Mech Eng H* 2020;234(07):711–719
- 13 Shishir SS, Miah MAK, Islam AKMS, Hasan ABMT. Blood Flow dynamics in cerebral aneurysm—A CFD Simulation. *Procedia Eng* 2015;105:919–927
- 14 Suzuki T, Takao H, Suzuki T, et al. Determining the presence of thin-walled regions at high-pressure areas in unruptured cerebral aneurysms by using computational fluid dynamics. *Neurosurgery* 2016;79(04):589–595
- 15 Saqr KM, Rashad S, Tupin S, et al. What does computational fluid dynamics tell us about intracranial aneurysms? A meta-analysis and critical review. *J Cereb Blood Flow Metab* 2020;40(05): 1021–1039
- 16 Mahrous S, Sidik C, Azwadi N, Saqr K. Newtonian and non-Newtonian CFD models of intracranial aneurysm: a review. *CFD Letters* 2020;12:62–86

- 17 Zhou G, Zhu Y, Yin Y, Su M, Li M. Association of wall shear stress with intracranial aneurysm rupture: systematic review and meta-analysis. *Sci Rep* 2017;7(01):5331
- 18 Sheh Hong L, Azrul Hisham Mohd Adib M, Uzair Matalif M, Shafie Abdullah M, Hartini Mohd Taib N, Hassan R. Modeling and simulation of blood flow analysis on simplified aneurysm models. *IOP Conf Ser Mater Sci Eng* 2020;917:12067
- 19 Kalani MYS, Wanebo JE, Martirosyan NL, Nakaji P, Zabramski JM, Spetzler RF. A raised bar for aneurysm surgery in the endovascular era. *J Neurosurg* 2017;126(05):1731–1739
- 20 Kang Y, Yu L-H, Xu T, et al. Three-dimensional printing technology for treatment of intracranial aneurysm. *Chinese Neurosurg J* 2016;2(01):24
- 21 Liu Y, Gao Q, Du S, et al. Fabrication of cerebral aneurysm simulator with a desktop 3D printer. *Sci Rep* 2017;7:44301
- 22 Sun J, Li Z, Lu C, et al. Application of 3D–DSA simulated surgical path in intracranial aneurysm clipping surgery. *Chinese Neurosurg J* 2017;3(01):41
- 23 Barrow DL. Intraoperative misadventures: complication avoidance and management in aneurysm surgery. *Clin Neurosurg* 2011;58:93–109