



Meningothelial Hamartoma Overlying a Prior Craniotomy: A Case Report and Review of Literature

Prashin Unadkat^{1,2} Taisia Vitkovski^{2,3} Raza Zaidi^{2,3} Mark Eisenberg^{1,2}

¹Department of Neurosurgery, North Shore University Hospital, Northwell Health, Manhasset, New York, United States

²Zucker School of Medicine at Hofstra/Northwell Health, Hempstead, New York, United States

³Department of Pathology, North Shore University Hospital, Northwell Health, Manhasset, New York, United States

Address for correspondence Mark Eisenberg, MD, Department of Neurosurgery, 900, Northern Blvd, Great Neck, NY 11021, United States (e-mail: punadkat@northwell.edu).

AJNS 2022;17:137–140.

Abstract

Keywords

- ▶ meningothelial hamartoma
- ▶ scalp tumor
- ▶ craniotomy
- ▶ Meningioma

Meningothelial hamartomas are benign lesions of the scalp with a handful of case reports published. Usually thought to be congenital lesions, they have, on occasion, been seen in older adults. In this report, we describe the first ever reported case of a patient diagnosed with a meningothelial hamartoma overlying a prior craniotomy performed two decades prior. We also briefly describe the literature surrounding these rare lesions, as well as their management and differential diagnosis.

Introduction

A wide range of pathologies are known to arise from the scalp, the majority of which are benign in nature with cysts accounting for 50% of all benign tumors followed by lipomas representing 30%.¹ While extremely rare, meningothelial hamartomas are benign lesions of the scalp, typically arising in the subcutaneous and dermal layers with a handful of case reports and series being described in the literature.^{2–4} First described by Lopez et al in 1974 and subsequently in a series by Suster and Rosai in 1990, they are characterized by ectopic meningothelial elements present in the dermis and subcutaneous tissue, admixed with vessels, adipose tissue, and connective tissue elements.^{4,5} Usually thought to be congenital, they are more commonly seen in pediatric populations;

however, they have been described in middle aged and elderly individuals as well.⁶

In this report, we describe the case of a 65-year-old male who presented with a solitary lesion of the scalp at the site of a prior craniotomy that was performed for a traumatic brain injury suffered two decades prior. Pathological analysis of the tissue demonstrated the presence of a meningothelial hamartoma. Extremely rare in and of itself, this represents the first reported case of a meningothelial hamartoma occurring at the site of a prior craniotomy without any intracranial communication. We briefly review the literature, as well as discuss management, and differential diagnosis. Institutional review board review and consent was waived given the retrospective nature and single patient reported which is in line with our institution's policies.

published online
July 5, 2022

DOI <https://doi.org/10.1055/s-0042-1749129>.
ISSN 2248-9614.

© 2022. Asian Congress of Neurological Surgeons. All rights reserved.

This is an open access article published by Thieme under the terms of the Creative Commons Attribution-NonDerivative-NonCommercial-License, permitting copying and reproduction so long as the original work is given appropriate credit. Contents may not be used for commercial purposes, or adapted, remixed, transformed or built upon. (<https://creativecommons.org/licenses/by-nc-nd/4.0/>)

Thieme Medical and Scientific Publishers Pvt. Ltd., A-12, 2nd Floor, Sector 2, Noida-201301 UP, India

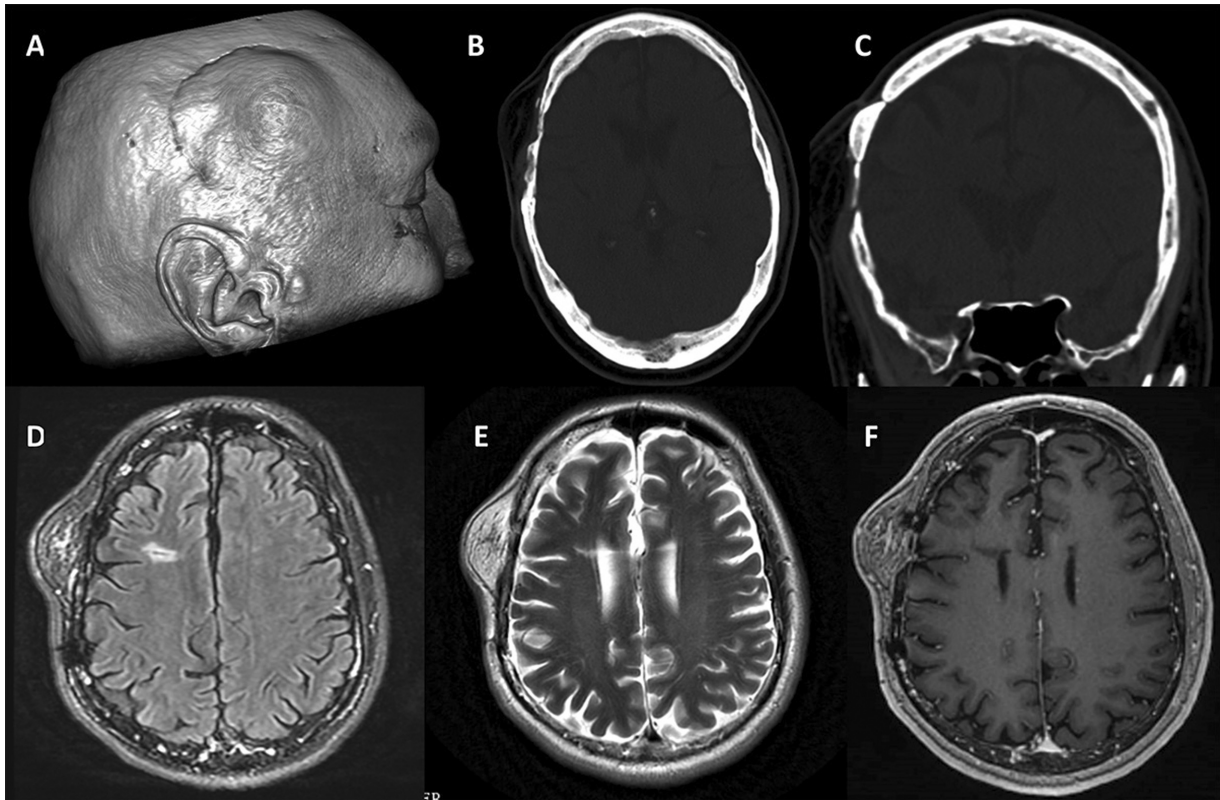


Fig. 1 (A) 3D rendering from MRI head showing the location of this R frontoparietal soft tissue mass. (B, C) Axial and coronal CT images in bone window showing prior craniectomy with a well healed bone flap. A small osseous overgrowth is also noted on the superior aspect of the bone flap. (D–F) Show the T2 FLAIR, T2 and T1 postcontrast images respectively of the fatty mass with multiple internal septations. 3D, three-dimensional; CT, computed tomography; FLAIR, fluid-attenuated inversion recovery; MRI, magnetic resonance imaging.

Case Report

A 65-year-old male presented to us with a prior history of an intracerebral hemorrhage following a biking accident that required a right parietal craniotomy approximately 20 years prior. The patient noticed an increasingly tender soft tissue mass 2 years back along the right scalp overlying the site of his prior craniotomy. On clinical examination and palpation, the lesion seemed consistent with a lipoma. However, given his prior surgical history further imaging with magnetic resonance imaging (MRI) and computed tomography (CT) of the head was acquired to rule out any intracranial communication. Imaging demonstrated a 3.9 cm × 2.2 cm × 2.8 cm fatty soft tissue mass overlying the prior craniotomy site. The presence of multiple internal septations suggested a higher grade process. There was no evidence of any intracranial lesions or intracranial communication of this scalp mass. Additional gliosis and expected encephalomalacia from the prior accident were seen intracranially. On CT imaging, the bone flap appeared to be well healed with the surrounding skull, with a small osseous overgrowth along the superior aspect of the bone flap (►Fig. 1).

Patient subsequently underwent resection of this mass which appeared confined to the scalp and seemed consistent with a lipoma with additional confirmation intraoperatively of no visual communication with the intracranial components. The protruding osseous overgrowth was drilled down to help with closure. Scalp was closed in multiple layers and a

surgical drain was left in place which was removed during follow-up. Postoperative course was uneventful. One-year follow-up MRI showed no evidence of recurrence (►Fig. 3).

Pathology

On gross examination, the mass was irregular, thinly encapsulated, firm, tan-yellow, and fatty. On histological examination, the lesion showed adipose tissue with interspersed islands of bland spindled cells with a whorled arrangement, exhibiting small nuclei with intranuclear inclusions, low nuclear-to-cytoplasmic ratios, and psammoma bodies (►Fig. 2). No mitosis or cytologic atypia was observed. On immunohistochemical staining (IHC), the lesional cells stained positive for progesterone receptor (PR) and epithelial membrane antigen (EMA) in keeping with meningothelial elements. These findings are consistent with meningothelial hamartoma (►Fig. 2).

Discussion

We describe the first case of a 65-year-old male who was found to have a meningothelial hamartoma overlying a prior craniotomy for trauma. Meningeal heterotopia was first described by Lopez et al in 1974 in a case series of 25 patients, classifying extracranial cutaneous meningiomas into three types.⁵ Type 1 or primary cutaneous meningiomas referred to benign congenital lesions present at birth and are thought to occur because of displaced arachnoid cell rests

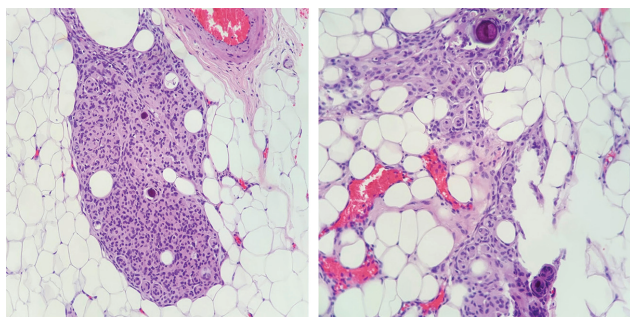


Fig. 2 Histopathological slides of a fat-rich tumor with islands and sheets of bland spindled cells with a whorled arrangement, intranuclear inclusions, and interspersed psammoma bodies.

into the subcutaneous tissue. Type 2 was typically adult onset and occurred as de novo lesions possibly from displaced arachnoid cell rests along nerve sheaths and other sensory organs. Both type-1 and -2 meningiomas are labeled as primary ectopic meningiomas (PEM). Type-3 or secondary cutaneous meningiomas occurred because of direct extension into the scalp via direct bony infiltration or through associated bony defects. However, the first description of a hamartomatous component within these lesions was published by Suster and Rosai in 1990 in a series of five patients.⁴

PEMs are extremely rare lesions and have been described to occur in other organs or as part of teratomas or hamartomas/chloristomas. Only 184 cases have been reported in the literature thus far with majority in the head and neck followed by the lungs and then spinal, mediastinal, or thoracic region.⁷ Hamartomas with ectopic meningeal elements have been described in the literature under a variety of names (acoelic meningeal hamartoma, cutaneous heterotopic meningeal nodules, and rudimentary meningocele).⁷ Like type-1 or cutaneous meningiomas, these lesions are pathologically distinct as they consist of meningeal elements admixed with haphazardly arranged mature connective tissue. Several case reports describing them along the head and neck have been published in the litera-

ture. The lesions are typically benign, solitary, and can occur across a wide age group; however, they are most commonly seen in pediatric populations.⁶ The meningeal component of these lesions appear to be histologically like meningoceles. The exact pathogenesis of these lesions remains unclear but various mechanisms have been postulated ranging from defective closure of the neural tube leading to displaced meningeal elements in the subcutaneous space to migration along cutaneous nerves; however, none of them have been associated with prior trauma or craniotomy. Rarely, these lesions have been found in conjunction with a nevus sebaceous.⁸

Patients typically present with soft tissue masses of the scalp that are generally nontender. In some cases, alopecia at the site of the lesion has been reported.⁹ On physical examinations, these tumors are most often mistaken for a lipoma. While gross-total surgical resection typically is curative and recurrences are rare, serial imaging over time is recommended to rule out delayed recurrence.

In this particular case, the pathogenesis of this lesion and its association with the patient's prior craniotomy is unclear and can only be speculated. One recent report described an extracranial meningioma at the site of a prior craniotomy that was distinct from the underlying calvarium and did not show any intracranial involvement.¹⁰ However, the lesion described appeared to be an extracranial meningioma without any hamartomatous component. Anecdotally, it is conceivable that meningeal elements were displaced into the scalp during the previous craniotomy and may have contributed to the formation of this lesion. However, it remains unclear what prompted the sudden growth of lesion (the mass was noticed and was increasing in size 2 years prior to presentation) two decades after the initial surgery. No evidence of intracranial extension was found on imaging or while inspecting the craniotomy site during the surgical procedure; however, the involution of a preexisting communication cannot be completely excluded due to a lack of available prior serial imaging.

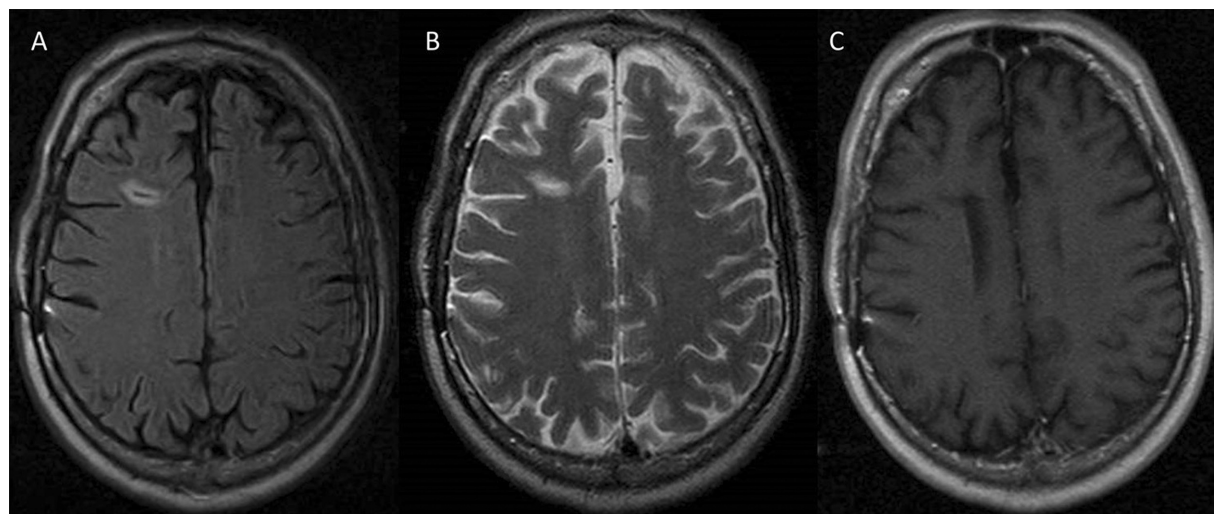


Fig. 3 (A–C) Axial T2 FLAIR, T2, and T1 postcontrast MRI at 1 year showing complete resection without recurrence. FLAIR, fluid-attenuated inversion recovery; MRI, magnetic resonance imaging.

Meningothelial hamartomas do not represent a true neoplasm, but both benign and malignant neoplasms may be in the differential diagnosis, including subtypes of lipoma (spindle cell lipoma and angiolipoma), carcinoma, melanoma, and vascular neoplasms, which can be excluded based on a combination of morphology and immunohistochemistry. Malignant vascular neoplasms, such as angiosarcomas, can appear clinically and histologically similar; however, they have very different clinical courses and are important to distinguish for prognostication and further management. Immunohistochemistry results for angiosarcomas stain positive for factor-VIII antigen. Other important distinctions from melanocytic tumors can be made using immunohistochemical stains such as S-100 and Human Melanoma Black-45 (HMB-45). While rather rare, proximal epithelioid sarcomas are aggressive malignant tumors and should be on the differential diagnosis, as they can have a staining pattern that can resemble rhabdoid meningiomas. In this case, the whorled architecture, lack of atypia, presence of psammoma bodies, and staining for EMA and PR were supportive of the diagnosis.

Conclusion

Meningothelial hamartomas are rare benign lesions that can occur on the scalp most often in the pediatric population, but rare cases have been described in older adults. This is the first reported case occurring at the site of a prior craniotomy. Gross-total resection is curative with few reported recurrences.

Conflict of Interest

The authors report no conflicts of interest for this study.

References

- 1 Prodingler CM, Koller J, Laimer M. Scalp tumors. *J Dtsch Dermatol Ges* 2018;16(06):730–753
- 2 Di Tommaso L, Fortunato C, Eusebi V. Meningothelial hamartoma located in the forehead. *Virchows Arch* 2003;442(05):509–510
- 3 David L, White W, Jain A, Argenta L. Meningothelial hamartoma of the scalp: two case reports and literature review. *Eur J Plast Surg* 1996;19(03):156–159
- 4 Suster S, Rosai J. Hamartoma of the scalp with ectopic meningothelial elements. A distinctive benign soft tissue lesion that may simulate angiosarcoma. *Am J Surg Pathol* 1990;14(01):1–11
- 5 Lopez DA, Silvers DN, Helwig EB. Cutaneous meningiomas—a clinicopathologic study. *Cancer* 1974;34(03):728–744
- 6 Cummings TJ, George TM, Fuchs HE, McLendon RE. The pathology of extracranial scalp and skull masses in young children. *Clin Neuropathol* 2004;23(01):34–43
- 7 Ozolek JA. Meninges outside the meninges: ectopic meningiomas and meningothelial proliferations. In: Agarwal A, ed. *Brain Tumors*. London, United Kingdom: IntechOpen; 2021
- 8 Biagiotti J, Beatty C, Zinn Z, Mason A. Symptomatic meningothelial hamartoma associated with nevus sebaceus. *J Pediatr Surg Case Rep* 2020;59:101483
- 9 Kim T, Kim J, Choi J, Oh S, Kwon S, Jeong W. Meningothelial hamartoma of the scalp. *Arch Craniofac Surg* 2020;21(03):180–183
- 10 Kieu DH, Trinh TH, Nguyen SL, Ngo HM. Extracranial meningioma in the scalp skin 25 years after epidural hematoma surgery: a case report. *Int J Surg Case Rep* 2021;81:105734