



Spontaneous Anal Extrusion of Ventriculoperitoneal Shunt Catheter: Case Report

Extrusão anal espontânea de catéter de derivação ventriculoperitoneal: Relato de caso

Lívio Pereira de Macêdo¹ Arlindo Ugulino Netto¹ Kauê Franke¹ Pierre Vansant Oliveira Eugenio² Lucas Ribeiro de Moraes Freitas² Victor Ribeiro Xavier Costa³ Eduardo Vieira de Carvalho Júnior¹ Igor Vilela Faquini¹ Nivaldo S. Almeida¹ Hildo Rocha Cirne Azevedo-Filho¹

¹Department of Neurosurgery, Hospital da Restauração, Recife, Pernambuco, Brazil

²Centro de Ciências Médicas, Universidade Federal da Paraíba, João Pessoa, Paraíba, Brazil

³Faculdade de Ciências Médicas da Paraíba, João Pessoa, Paraíba, Brazil

Address for correspondence Lívio Pereira de Macêdo, MD, Departamento de Neurocirurgia, Hospital da Restauração, Rua João Fernandes Vieira 544, Boa Vista, Recife, PE, 50050-200, Brasil (e-mail: livio21@gmail.com).

Arq Bras Neurocir 2022;41(4):e382–e385.

Abstract

Background Ventriculoperitoneal shunt (VPS) has become the standard treatment for congenital hydrocephalus. In the neurosurgical practice, it is a common procedure which usually results in low rates of complication. However, some serious complications can occur, including infections, intestinal perforation, and even death.

Case Description A 19-year-old, female, asymptomatic patient, with a history of appendectomy and revision of the VPS 6 years before, presented spontaneous transanal extrusion of the catheter. Abdominal radiographs and tomography scans showed perforation of the descending colon without peritonitis, with expulsion of the distal tip of the catheter through the anus. The patient underwent removal of the proximal part of the VPS and installation of an external ventricular drain (EVD). On the second postoperative day, there was spontaneous elimination of the distal portion of the catheter, dispensing any additional surgical procedures. With antimicrobial prophylaxis and the contralateral VPS performed, the patient evolved without further complications until discharge. Diverging from cases reported in the literature, the patient in question did not present any abdominal manifestations.

Conclusion Intestinal perforation by VPS may be asymptomatic until anal extrusion occurs. However, the early approach should avoid infections, which are associated with increased mortality. Removing only the proximal catheter, together with antimicrobial prophylaxis, can be an effective, safe and less invasive alternative to manage this complication of VPS.

Keywords

- ▶ ventriculoperitoneal shunt
- ▶ intestinal perforation
- ▶ hydrocephalus

received
January 8, 2022
accepted
April 6, 2022

DOI <https://doi.org/10.1055/s-0042-1748848>.
ISSN 0103-5355.

© 2022. Sociedade Brasileira de Neurocirurgia. All rights reserved. This is an open access article published by Thieme under the terms of the Creative Commons Attribution-NonDerivative-NonCommercial-License, permitting copying and reproduction so long as the original work is given appropriate credit. Contents may not be used for commercial purposes, or adapted, remixed, transformed or built upon. (<https://creativecommons.org/licenses/by-nc-nd/4.0/>)
Thieme Revinter Publicações Ltda., Rua do Matoso 170, Rio de Janeiro, RJ, CEP 20270-135, Brazil

Introduction

Ventriculoperitoneal shunt (VPS) has become the standard treatment for congenital hydrocephalus since its introduction into the neurosurgical practice in the 1950s.¹

Although uncommon, several abdominal complications resulting from VPS have been described, including fibrous entrapment of the catheter, blocking or twisting of the distal tube, extrusion by surgical incision, or migration of the shunt to a cavity other than the peritoneal one.² Intestinal perforation presents an incidence of 0.1% to 1% of the cases of catheter displacement, which can lead to infections, meningitis, seizures, fever and increased intracranial pressure, as well as abdominal manifestations, such as intestinal obstructions associated with adhesions, inflammatory pseudocysts and ascites.³ Despite the low incidence, when perforation is associated with infections, it is related to a mortality of up to 15%.⁴

The aim of the present study is to report an unusual case of an adult patient with intestinal perforation and spontaneous extrusion of the VPS catheter through the anus.

Case Report

A 19-year-old female patient underwent a VPS implant at the age of 2 due to congenital hydrocephalus. Over time, it evolved with a delay in neuropsychomotor development and bed restriction. At the age of 13, she underwent an open appendectomy, evolving in the postoperative period with obstruction and infection of the implant site of the VPS, and a shunt review was performed.

Six years later, when the patient was aged 19 years, her caregiver noticed exposure of the distal end of the VPS catheter through the patient's anus (► Fig. 1), which motivated her return to the neurosurgery service. Upon physical examination, the tip of the extruded VPS catheter was found 5 cm from the anal margin, without dripping cerebrospinal fluid (CSF). Signs of phlogistic skin were detected in the cervical path of the VPS, but she did not have fever, abdominal distension, pain on palpation of the abdomen, ascites, vomiting or headache, and peritonitis or encephalitis were ruled out.

An abdominal computed tomography (CT) scan showed that the catheter path had no evidence of knots or pneumoperitoneum. Moreover, this image showed the peritoneal

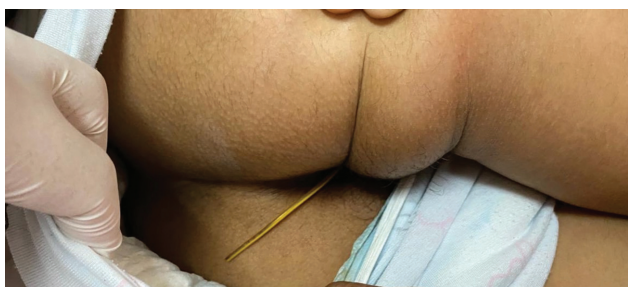


Fig. 1 Exposure of the distal end of the ventriculoperitoneal shunt catheter through the patient's anus.

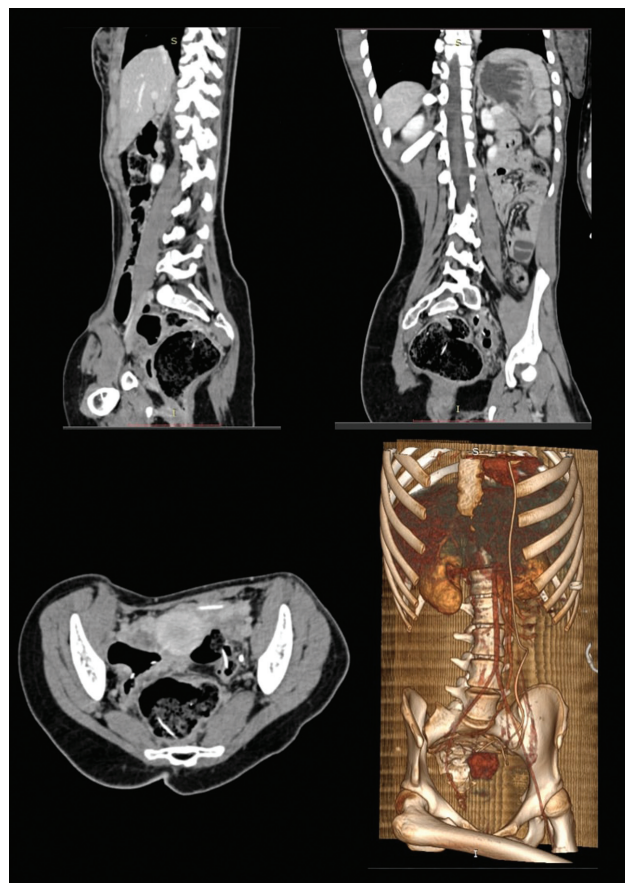


Fig. 2 Abdominal computed tomography scan showing the peritoneal catheter perforating the descending colon.

catheter perforating the descending colon and being extruded through the anus. The patient underwent surgery to remove the proximal portion of the VPS and to implant an external ventricular drain (EVD), without complications (► Fig. 2 and 3).

During hospitalization, antimicrobial prophylaxis with ceftriaxone and vancomycin was prescribed, the former being replaced on the seventh day by meropenem. While evaluating the possibility of laparoscopic exploration with the general surgery team, the patient spontaneously expelled the distal portion of the catheter on the ninth day of hospitalization (► Fig. 4). A new abdominal CT scan was requested, and no abscesses or signs of infection were noted. The CSF culture did not show bacterial growth, but showed normal glucose levels. With antimicrobial prophylaxis and the contralateral VPS performed, the patient evolved without further complications until discharge.

Discussion

Spontaneous intestinal perforation is an extremely uncommon complication, which was first reported by Wilson and Bertran⁵ in 2 pediatric patients in 1966. From the initial report to the present day, approximately 112 cases of intestinal perforation associated with a VPS have been reported in the literature, half of them in patients aged up to 10 years. The combination of thin intestinal musculature in the

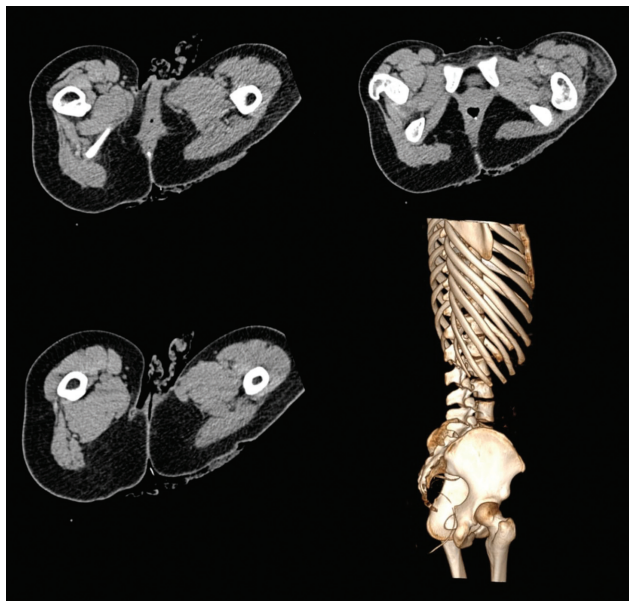


Fig. 3 Abdomen computed tomography scan, after the surgery to remove the proximal portion of the ventriculoperitoneal shunt and to implant an external ventricular drain (seven days later), showing the peritoneal catheter being extruded through the patient's anus.

myelomeningocele, placement of rigid peritoneal catheters, and local infectious adhesions can predispose intestinal perforation.³

In cases submitted to surgical intervention or autopsy, the authors⁴ have described a fibrotic scar that anchors the tube in a region of the intestine and causes ulceration and, theoretically, eventual perforation.

Although not found in the case herein reported, significant abdominal symptoms or peritonitis affect up to 25% of the cases.⁶ Surgeons must be aware of this complication to prevent the development of infections such as meningitis, ventriculitis and sepsis, which are associated with mortality in up to 15% of the cases.⁴

In the presence of pneumoperitoneum, radiographs can confirm the diagnosis of intestinal perforation. The exam also shows the trajectory of the peritoneal catheter to the perineal region. Meanwhile, abdominal CT scans enables physicians to rule out the presence of abscesses, in addition to suggesting a more precise location for the point of perforation.⁷ In view of the evidence, these were the tests chosen for the assessment of the case herein reported. Although there was no pneumoperitoneum, the radiographs enabled the observation of the catheter path, while the abdominal CT scan showed perforation in the descending colon.

The management of intestinal perforation is individualized and depends on the signs and symptoms of the patient. In a patient with intestinal perforation, but without other complications, a formal exploratory laparotomy is not necessary. Our patient fits into the subset of patients who can, therefore, be treated without laparotomy, by means of externalization of the ventricular shunt and antimicrobial prophylaxis until the CSF bacteriological cultures become

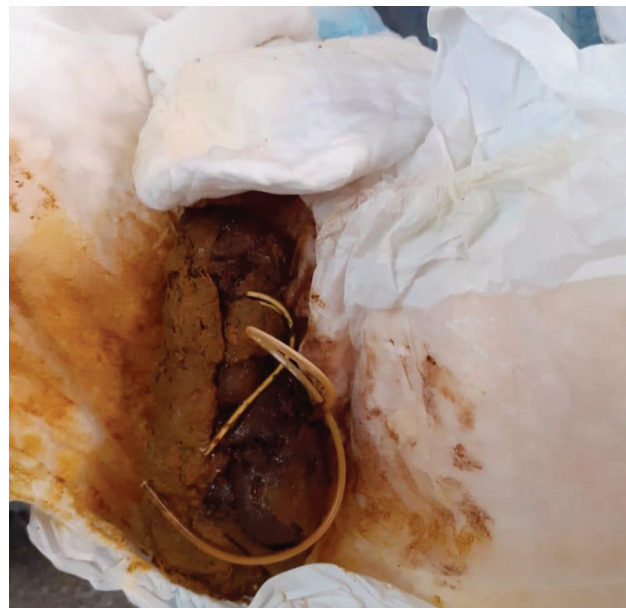

Fig. 4 The patient spontaneously expelled the distal portion of the catheter on the ninth day of hospitalization.

negative. It is important to emphasize that, when making a new derivation, it is recommended to choose a different terminal of the abdominal cavity, as there is a concern that the factors that triggered the perforation may still be present.⁸

If there is concern about abdominal abscess or peritonitis, laparotomy is the preferred treatment to control bacterial infection.⁹ In some cases, the knot of the long shunt catheter itself or tangling of the tube in the intestinal loops makes laparotomy mandatory, even in the absence of peritonitis. As an alternative, laparoscopic visualization and disconnection of the derivation tube can be performed.¹⁰

Although intestinal perforation is a complication already reported in the literature, we have not identified any reports of spontaneous anal extrusion from the distal portion of the catheter after surgical removal of the proximal portion and antimicrobial prophylaxis. Assessing the infection-free evolution of the patient, this strategy can avoid unnecessary laparotomies, reducing the cost, the risk of infections, and excessive invasive interventions in patients who are often debilitated.

Conclusion

Intestinal perforation with anal catheter extrusion is an uncommon complication, usually asymptomatic, more common in children, and which has a good prognosis in most cases. In the case herein reported, its treatment consisted of removing the proximal portion of the catheter and administering antibiotics. Laparotomy with repair of the perforation should be performed mainly in cases of peritonitis, intra-abdominal abscess, or catheter tangling. Knowledge of this atypical complication and of the natural evolution will enable early recognition and more accurate surgical indications.

Funding

The authors declare that they have received no financial support for the research, authorship, and/or publication of the present article.

Conflict of Interests

The authors have no conflict of interests to declare.

References

- 1 Agha FP, Amendola MA, Shirazi KK, Amendola BE, Chandler WF. Unusual abdominal complications of ventriculo-peritoneal shunts. *Radiology* 1983;146(02):323–326. Doi: 10.1148/radiology.146.2.684907
- 2 Hasan A, Sharma S, Chopra S, Purohit DK. Anal Extrusion of Ventriculoperitoneal Shunt: A Report of Two Cases and Review of Literature. *J Pediatr Neurosci* 2018;13(01):8–12. Doi: 10.4103/JPN.JPN_97_17
- 3 Bakshi S. Spontaneous trans-anal extrusion of caudally migrated ventriculo-peritoneal shunt tip in a child: a case report. *Surg Case Rep* 2020;6(01):50
- 4 Panagea S, Cartmill TD, Panigrahi H. Intracerebral sepsis due to intestinal perforation by ventriculo-peritoneal shunts: two cases. *J Infect* 1997;35(01):86–88. Doi: 10.1016/s0163-4453(97)91217-2
- 5 Wilson CB, Bertan V. Perforation of the bowel complicating peritoneal shunt for hydrocephalus. Report of two cases. *Am Surg* 1966;32(09):601–603
- 6 Handa R, Kale R, Harjai MM. Unusual complication of ventriculoperitoneal shunt: anal extrusion. *Med J Armed Forces India* 2007;63(01):82–84. Doi: 10.1016/S0377-1237(07)80122-5
- 7 Zhou F, Chen G, Zhang J. Bowel perforation secondary to ventriculoperitoneal shunt: case report and clinical analysis. *J Int Med Res* 2007;35(06):926–929. Doi: 10.1177/147323000703500624
- 8 Bales J, Morton RP, Airhart N, Flum D, Avellino AM. Transanal presentation of a distal ventriculoperitoneal shunt catheter: Management of bowel perforation without laparotomy. *Surg Neurol Int* 2016;7(Suppl 44):S1150–S1153
- 9 Hai A, Rab AZ, Ghani I, Huda MF, Quadir AQ. Perforation into gut by ventriculoperitoneal shunts: A report of two cases and review of the literature. *J Indian Assoc Pediatr Surg* 2011;16(01):31–33. Doi: 10.4103/0971-9261.74521
- 10 Sharma A, Pandey AK, Radhakrishnan M, Kumbhani D, Das HS, Desai N. Endoscopic management of anal protrusion of ventriculo-peritoneal shunt. *Indian J Gastroenterol* 2003;22(01):29–30