

Adrenal Histoplasmosis: An Uncommon Cause of Adrenal Crisis in an Immunocompetent Man

Mouza Alnuaimi¹ Maitha Alblooshi¹ Amna Alzaabi¹ Abdulghani Elomami² Raya Almazrouei³

¹Department of Internal Medicine, Tawam Hospital, Tawam, Abu Dhabi, United Arab Emirates

²Department of Pathology, Tawam Hospital, Tawam, Abu Dhabi, United Arab Emirates

³Division of Endocrinology, Tawam Hospital, Tawam, Abu Dhabi, United Arab Emirates

Address for correspondence Raya Almazrouei, MD, Division of Endocrinology, Tawam Hospital, Tawam, Abu Dhabi, United Arab Emirates (e-mail: rmazrooei@seha.ae).

J Diabetes Endocrine Practice 2022;5:40–43.

Abstract

Keywords

- ▶ adrenal insufficiency
- ▶ bilateral adrenal enlargement
- ▶ histoplasmosis
- ▶ adrenalitis
- ▶ adrenal crisis

Background Histoplasmosis is a rare cause of primary adrenal insufficiency. Adrenal involvement is commonly encountered with disseminated disease in immunocompromised individuals though some have been reported in immunocompetent patients. Primary adrenal histoplasmosis where adrenals are the only organs with demonstrable disease is uncommon.

Case Presentation A 33-year-old immunocompetent man presented with an adrenal crisis. Further evaluation of the underlying etiology of primary adrenal insufficiency revealed bilateral adrenal enlargement that was confirmed to be histoplasmosis on adrenal biopsy.

Conclusion The case highlights the importance of considering histoplasmosis as an underlying cause of primary adrenal insufficiency in patients from high endemic areas.

Introduction

Primary adrenal insufficiency (PAI) is a rare endocrine disorder where autoimmune adrenalitis accounts for almost 90% of the causes. Less-frequent causes include hereditary disorders, medications, vascular disorders, and infiltrative diseases. Infiltration of the adrenal cortex could be due to metastasis from non-adrenal tumors or lymphoma, systemic diseases such as sarcoidosis and histiocytosis and infections, which include histoplasmosis, tuberculosis, cryptococcosis, coccidioidomycosis and blastomycosis.¹

Histoplasmosis is caused by dimorphic fungus *Histoplasma capsulatum*. Humans are infected by a variety of mechanisms (fomites, direct inoculation, solid organ transplant, sexual contact), but commonly spores are inhaled into

the alveoli where these convert to yeast forms. The yeasts are taken up by alveolar macrophages where it replicates using the reticuloendothelial system as a gate to disseminate to other body's organs.² A T cell-mediated response results in the clearance of *Histoplasma* spores and organisms within approximately 2 weeks; however, in the setting of immunosuppression, this may not happen leading to progressive dissemination.²

Therefore, histoplasmosis can cause various clinical manifestations ranging from the more common asymptomatic self-limiting pulmonary infection to pulmonary histoplasmosis, progressive disseminated disease, and primary cutaneous histoplasmosis.³ Cases of disseminated histoplasmosis (DH) have been reported in immunocompetent patients, and adrenal involvement may be the only demonstrable site of

DOI <https://doi.org/10.1055/s-0042-1748666>.
ISSN 2772-7653.

© 2022. Gulf Association of Endocrinology and Diabetes (GAED). All rights reserved.

This is an open access article published by Thieme under the terms of the Creative Commons Attribution-NonDerivative-NonCommercial-License, permitting copying and reproduction so long as the original work is given appropriate credit. Contents may not be used for commercial purposes, or adapted, remixed, transformed or built upon. (<https://creativecommons.org/licenses/by-nc-nd/4.0/>)

Thieme Medical and Scientific Publishers Pvt. Ltd., A-12, 2nd Floor, Sector 2, Noida-201301 UP, India

active fungal disease in these patients.^{4,5} Adrenal insufficiency in adrenal histoplasmosis could be the cause of death and adrenal function must be evaluated. Here, we report a case of an immunocompetent patient presenting with huge bilateral adrenal enlargement, leading to adrenal crisis secondary to histoplasmosis, which is a rare finding in clinical practice.

Case

A 32-year-old Bangladeshi male patient presented to the emergency department (ER) with nausea, vomiting, and abdominal pain for 8 days associated with poor oral intake and 5 kg weight loss over the last 5 months. The rest of systems review was unremarkable specifically for cough, night sweats, or fever. He had an unremarkable medical history and used to work as a laborer for the last 4 years. He was a nonsmoker and did not consume alcohol or take any prescription medications or illicit drugs neither engaged in high-risk behavior. His wife was treated for pulmonary tuberculosis (TB) 2 years ago in-home country. Bedside examination revealed blood pressure of 96/64 mm Hg, heart rate of 93/min, oxygen saturation 99%, and body temperature of 36.7°C. His body mass index (BMI) was 18.6 kg/m². Hyperpigmentation was observed on the buccal mucosa, creases, and dorsal surface of the hands. He had no palpable lymphadenopathy or hepatosplenomegaly. Cardiovascular and respiratory examinations were unremarkable.

Table 1 Laboratory Investigations

Test	Patient's result	Normal range
Sodium (mmol/l)	107	136–145
Potassium (mmol/l)	5.6	3.2–5.5
Chloride (mmol/l)	77	98–107
HCO ₃ (mmol/l)	20	22–29
Urea (mmol/l)	6.2	2.8–8.1
Creatinine (μmole/L)	84	62–106
Serum glucose (mmol/L)	6	3.7–7.8
HbA1c %	5.5	4.4–6.4
TSH (milli IU/L)	2.11	0.4–4.2
AST (IU/L)	137	≤ 40
ALT (IU/L)	123	≤ 41
ALP (IU/L)	373	40–129
Albumin (g/L)	34	35–52
Total Bilirubin (μmole/L)	20.5	≤ 21
Direct bilirubin (μmole/L)	10	≤ 5
Amylase (units/L)	41	28–100
Lipase (IU/L)	23	13–60

Abbreviations: ALP, alkaline phosphatase; ALT, alanine aminotransferase; AST, separate aminotransferase; TSH, thyroid-stimulating hormone.

His initial blood tests showed hyponatremia of 107 (normal range [NR]: 136–145) mmol/L; hyperkalemia of 5.6 (NR: 3.2–5.5) mmol/L, and mild elevation in liver enzymes (► **Table 1**). Full blood count was unremarkable apart from mild anemia with a white blood cell count of $10.3 \times 10^9/L$ (NR: 4.5–11), eosinophils 4.8%, neutrophils 57.4%, lymphocytes 24.7%, platelet count of $292 \times 10^9/L$ (NR: 140–400), and hemoglobin of 13.1 (NR: 13.2–17.3) g/dL. C-reactive protein (CRP) was 6.4 (NR ≤ 5) mg/L. Random evening serum cortisol level was 63.4 (NR: 68–327) nmol/L. In addition to volume replacement, parenteral hydrocortisone therapy was initiated in suspect of adrenal insufficiency.

Subsequent synacthen stimulation test (after holding hydrocortisone) showed inadequate response with am cortisol levels of 68 nmol/L and peak stimulated cortisol levels of 78 nmol/L at 30 minutes and 76 nmol/L at 60 minutes. His adrenocorticotrophic hormone (ACTH) levels were elevated at 79.5 (NR: 1.6–13.9) pmol/L confirming primary adrenal insufficiency. Four days after steroid initiation, his LFT improved significantly with AST 48 (NR ≤ 40) IU/L and ALT 68 (NR ≤ 41) IU/L. Hepatitis serology and autoimmune screens were negative. Upon his initial presentation to ER, he had abdominal ultrasound for the abdominal pain and the initial abnormal LFT that showed gallbladder sludge with possible tiny gallstones. No gallbladder wall thickening or pericholecystic fluid and no dilated common bile duct seen. The spleen appeared normal with no focal lesions. However, there was a lobulated heterogenous hypoechoic subdiaphragmatic lesion in the right suprarenal area measuring $3.2 \times 6.6 \times 7.8$ cm. Subsequent abdominal computed tomography (CT) revealed massive bilateral ovoid enlargement of the adrenal glands (right adrenal: 6.5×3.2 cm, left adrenal: 6.9×3.3 cm axial plane) (► **Fig. 1A–D**). No enlarged lymph

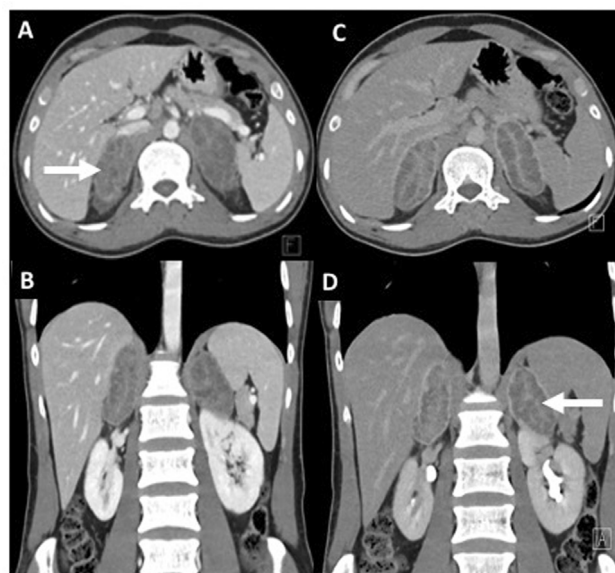


Fig. 1 Computed tomography venous (A, B) and delayed (C, D) phases showing bilateral ovoid enlargement of the adrenal glands (white arrows) with peripheral enhancement and nodular central hypoenhancement. No definite adrenal hemorrhage, calcification, or necrosis.

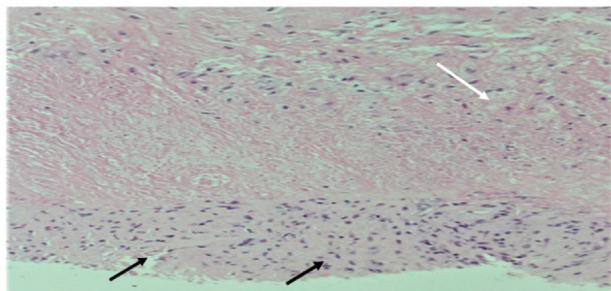


Fig. 2 Routine stain section of adrenal gland core biopsy shows the adrenal gland replaced by extensive necrosis (top of the image, white arrow), rimmed by histiocytes (black arrows), forming necrotic granulomatous inflammation.

nodes in the abdomen or pelvis. Other abdominal organs, bones, and visualized lung bases were unremarkable. Chest X-ray was normal. Further investigations were performed to establish the cause of the primary adrenal insufficiency with bilateral adrenal enlargement, including normal levels of 17 hydroxyprogesterone 2.9 (NR: 0.2–4.8) nmol/L and negative HIV serology and QuantiFERON-TB.

After ruling out pheochromocytoma with hormonal testing, he underwent ultrasound-guided adrenal biopsy that revealed extensively necrotic granulomatous inflammation (►Fig. 2). With the Grocott–Gomori methenamine silver (GMS) staining, there were heavy fungal spores identified round to oval shape with no obvious capsule and some with budding formation, which were morphologically similar to *Histoplasma capsulatum* (►Fig. 3). Stain for AFB was negative. Culture from adrenal biopsy was negative for TB and there was not enough specimen for fungal culture. Urine *Histoplasma* antigen testing was negative using the IMMY *Histoplasma capsulatum* galactomannan EIA. The clinical presentation and histologic findings were suggestive of bilateral adrenal histoplasmosis as the underlying cause of primary adrenal insufficiency. Patient was treated as adrenal insufficiency with prednisolone 5 mg daily, fludrocortisone 100 µg daily and was started on itraconazole 200 mg bid for 12 months for fungal adrenalitis. He was discharged with normal elec-

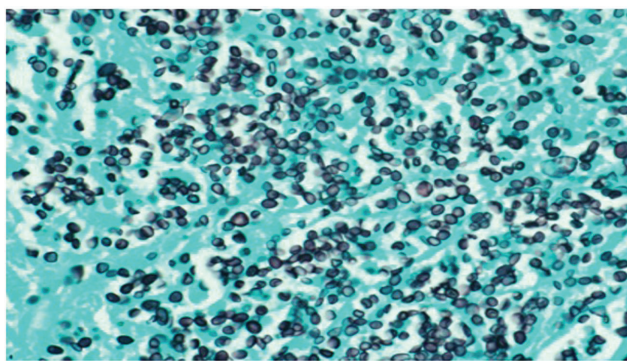


Fig. 3 Grocott–Gomori methenamine silver (GMS) special stain shows the necrotic area studded with fungal spores of round to oval shape with no obvious capsule and some with budding formation, suggestive of histoplasmosis.

trolytes. We were unable to assess patient's long-term outcome as he was lost to follow-up and went back to home country.

Discussion

Histoplasmosis is endemic in some parts of the world such as the Mississippi and Ohio river valleys in the United States, parts of Central and South America, China and Eastern India, which form part of the Indo-Gangetic plain.⁶ The Indo-Gangetic Plain is a fertile plain encompassing northern regions of the Indian subcontinent, including most of northern and eastern India, the eastern parts of Pakistan, virtually all of Bangladesh (from where our patient was) and southern plains of Nepal.⁷ Over the last decade, there has been a sharp increase in case reports and series of patients with DH from these areas.⁶

Histoplasma species are the commonest fungi involving the adrenals. Patients with adrenal histoplasmosis may have the classic signs and symptoms of adrenal insufficiency such as nausea, vomiting, postural dizziness, hyperkalemia, hyponatremia, and eosinophilia in addition to the usual constitutional symptoms or they can present with life-threatening adrenal crisis like our patient.⁸ In a recent study of patients with adrenal histoplasmosis, 73% of the patients had primary adrenal insufficiency at presentation and one-third had an adrenal crisis. Two out of eight patients, with normal cortisol at diagnosis, developed adrenal insufficiency on follow-up.⁶ Rarely, as in our patient, the adrenal gland can be the only organ with demonstrable disease. Primary adrenal histoplasmosis and adrenal involvement during disseminated disease are more common among males.^{6,8} Though our patient was immunocompetent, his low BMI could be related to the recent weight loss and poor oral intake over the 5 months preceding the admission.

In DH, abdominal imaging usually reveals mild-to-moderate hepatomegaly with or without splenomegaly, abdominal lymphadenopathy, and focal hypodense lesions in the spleen.⁹ Patients with adrenal histoplasmosis may have unilateral or bilateral adrenal enlargement with varied imaging features. On ultrasonography, the lesions may show a uniformly hypoechoic to a heterogenous echopattern with preservation of normal adrenal gland outlines. The typical though non-specific computed tomography (CT) findings of adrenal histoplasmosis are bilateral symmetrical adrenal enlargement with preservation of the contour of the gland and central hypodensity with peripheral enhancement. The presence of calcification has been described as well mainly in the chronic phase.^{8,9}

The range of adrenal involvement by histoplasmosis is variable and could range from mild form characterized by isolated cortical foci of parasitized macrophages to extensive caseative necrosis with enlargement of bilateral adrenals, extensive infarction, granulomatous replacement of adrenals, and calcified mass lesion that may mimic tubercular or metastatic lesions.^{10–12}

Diagnosis of adrenal histoplasmosis could be achieved by multiple methods including histopathology, specific fungal stains such as GMS, cultures, antigen detection, serological

tests, and molecular biology-based tests.^{13,14} The sensitivity and specificity of these methods are dependent on the patient's immune status, disease manifestation, and duration of symptoms prior to presentation. The sensitivity of *Histoplasma* urine antigen test increases in immunocompromised patients and in those with disseminated histoplasmosis.¹⁴ Therefore, a negative *Histoplasma* urine antigen test dose not exclude the disease like in our case.

Treatment depends on disease severity and condition of the patient with amphotericin used initially in severe infections, followed by maintenance prolonged (6–24 months) itraconazole therapy.¹³ Our patient had localized disease and therefore was started on itraconazole as the first-line treatment. While high remission rate can be achieved with antifungal therapy, overall mortality remains significant. Adrenal function recovery is unlikely though some reported patients gained adrenal functions after prolonged antifungal therapy.^{6,8}

Conclusions

Adrenal histoplasmosis is a rare cause of PAI and symmetrical adrenal enlargement. Apart from systemic evaluation of etiological cause of PAI, considering this diagnosis from high-endemic areas is crucial, especially in patients presenting with only adrenal insufficiency manifestations.

Ethics Approval and Consent to Participate

Ethical approval obtained from Hospital Human Research Ethics Committee with approval number: MF2058–2021–788. Consent to participate was obtained.

Consent for Publication

Written informed consent was obtained from the patient for publication of this case report and any accompanying images.

Financial Support and Sponsorship

None.

Conflict of Interest

None declared.

References

- 1 Herndon J, Nadeau AM, Davidge-Pitts CJ, Young WF, Bancos I. Primary adrenal insufficiency due to bilateral infiltrative disease. *Endocrine* 2018;62(03):721–728
- 2 De D, Nath UK. Disseminated histoplasmosis in immunocompetent individuals -not a so rare entity, in India. *Mediterr J Hematol Infect Dis* 2015;7(01):e2015028
- 3 Rog CJ, Rosen DG, Gannon FH. Bilateral adrenal histoplasmosis in an immunocompetent man from Texas. *Med Mycol Case Rep* 2016;14:4–7
- 4 Kathuria S, Capoor MR, Yadav S, Singh A, Ramesh V. Disseminated histoplasmosis in an apparently immunocompetent individual from north India: a case report and review. *Med Mycol* 2013;51(07):774–778
- 5 Vyas S, Kalra N, Das PJ, et al. Adrenal histoplasmosis: an unusual cause of adrenomegaly. *Indian J Nephrol* 2011;21(04):283–285
- 6 Singh M, Chandy DD, Bharani T, et al. Clinical outcomes and cortical reserve in adrenal histoplasmosis—a retrospective follow-up study of 40 patients. *Clin Endocrinol (Oxf)* 2019;90(04):534–541
- 7 Taneja G, Barun DP, Joshi PK, Aggarwal PK, Tyagi NA. Farmers preferences for climate-smart agriculture: an assessment in the Indo-Gangetic Plain. In: Pal B, Kishore A, Joshi P, Tyagi N, eds. *Climate Smart Agriculture in South Asia*. Springer, Singapore: Springer; 2019:91–111
- 8 Gajendra S, Sharma R, Goel S, et al. Adrenal histoplasmosis in immunocompetent patients presenting as adrenal insufficiency. *Turk Patoloji Derg* 2016;32(02):105–111
- 9 Rozenblit AM, Kim A, Tuvia J, Wenig BM. Adrenal histoplasmosis manifested as Addison's disease: unusual CT features with magnetic resonance imaging correlation. *Clin Radiol* 2001;56(08):682–684
- 10 Wheat LJ. Histoplasmosis: a review for clinicians from non-endemic areas. *Mycoses* 2006;49(04):274–282
- 11 Koene RJ, Catanese J, Sarosi GA. Adrenal hypofunction from histoplasmosis: a literature review from 1971 to 2012. *Infection* 2013;41(04):757–759
- 12 Larbcharoensub N, Boonsakan P, Aroonroch R, et al. Adrenal histoplasmosis: a case series and review of the literature. *Southeast Asian J Trop Med Public Health* 2011;42(04):920–925
- 13 Jayathilake WAPP, Kumarihamy KWMPP, Ralapanawa DMPUK, Jayalath WATA. A rare presentation of possible disseminated histoplasmosis with adrenal insufficiency leading to adrenal crisis in an immunocompetent adult: a case report. *Case Rep Med* 2020;2020:8506746
- 14 Zanotti P, Chirico C, Gulletta M, et al. Disseminated histoplasmosis as AIDS-presentation. Case report and comprehensive review of current literature. *Mediterr J Hematol Infect Dis* 2018;10(01):e2018040