



# Total Urethra and Penile Shaft Reconstruction with Combined Pedicled Anterolateral Thigh Flap and Radial Forearm Free Flap after Total Penectomy

Pietro Giovanni di Summa, MD, PhD<sup>1</sup> Gianluca Sapino, MD<sup>1</sup> Olivier Bauquis, MD<sup>1</sup>

<sup>1</sup>Department of Plastic, Reconstructive, Aesthetic and Hand Surgery, University Hospital of Lausanne, University of Lausanne, Lausanne, Switzerland

Arch Plast Surg 2022;49:448–452.

Address for correspondence Pietro Giovanni di Summa, MD, PhD, Department of Plastic, Reconstructive and Hand Surgery, Centre Hospitalier Universitaire Vaudois (CHUV), Lausanne, Switzerland, Rue du Bugnon 46, 1011 Lausanne, Switzerland (e-mail: Pietro.di-Summa@chuv.ch).

## Abstract

Total reconstruction of the penis (TPR) represents a challenge for urologists and plastic surgeons, especially when urethral length is severely reduced. We here describe, for the first time in an oncologic scenario, a double flap phalloplasty using a pedicled anterolateral thigh (ALT) flap for penile reconstruction and a radial forearm free flap (RFFF) for complete neourethra and glans reconstruction following penile amputation. A 48-year-old patient came to our department following a total penectomy with inferior urethral derivation. The indication for a double flap phalloplasty was posed as only way to fully reconstruct the urethra on its length avoiding possible complications of single flap reconstruction using tube-into-tube technique. Both flaps healed uneventfully with no neourethral strictures or fistulas described. At 18 months follow-up, the patient was extremely satisfied with the aesthetic result and was able to void in standing position.

## Keywords

- ▶ penile reconstruction
- ▶ urethra reconstruction
- ▶ ALT perforator flap
- ▶ double flap

We think that a double free tissue transfer for TPR should be considered, particularly when a urethral length > 14 cm needs to be reconstructed. While the pedicled ALT can be used to reconstruct a proper penile shaft with an easily concealed scar, the RFFF can provide adequate neourethra length with satisfactory sensory recovery at the neoglans.

Invasive ingrowth and early metastatic dissemination characterize the penile cancer, a relatively rare (0.9–2.1 cases per 100000 persons per year) but aggressive squamous cell carcinoma affecting the glans epithelium or the prepuce mainly, often associated with human papillomavirus infection (in 80% of cases).<sup>1</sup>

Surgical treatments range from local excision and penile organ-sparing approaches (early stages, Tis-T1) to partial and total penectomy eventually combined with inguinal lymph node ablation, in more advanced stages

(T2–T4). Unfortunately, because of the high social and psychological impact for the men affected, delayed diagnosis is common.<sup>2</sup>

Total reconstruction of the penis (TPR) represents a challenge for urologists and plastic surgeons. After tumor excision and total penectomy, the urethra can be even shorter than in female to male sex reassignment, with even a greater need of a full separate urethra reconstruction. Moreover, radical oncologic treatment of the penis is generally associated with groin node dissection, jeopardizing the great

DOI <https://doi.org/10.1055/s-0042-1748662>.  
ISSN 2234-6163.

© 2022. The Korean Society of Plastic and Reconstructive Surgeons. All rights reserved.

This is an open access article published by Thieme under the terms of the Creative Commons Attribution-NonDerivative-NonCommercial-License, permitting copying and reproduction so long as the original work is given appropriate credit. Contents may not be used for commercial purposes, or adapted, remixed, transformed or built upon. (<https://creativecommons.org/licenses/by-nc-nd/4.0/>)

Thieme Medical Publishers, Inc., 333 Seventh Avenue, 18th Floor, New York, NY 10001, USA

saphenous veins and therefore complicating microsurgical free tissue transfer.

The neophallus should be aesthetically acceptable, should permit the insertion of a penile inflatable prosthesis to allow sexual intercourse, and, most importantly, should contain a neourethra that facilitates voiding in standing position. Thanks to microsurgical advancements, a wide range of surgical options can now be offered to those patients to accomplish these goals. Particularly, the radial forearm free flap (RFFF) tube-in-tube phalloplasty represents a workhorse in this field; its thin and pliable tissue and the reliable surgical anatomy allow the construction of normal size penis, with a good grade of expected resensibilization of the skin.<sup>3</sup> However, because of the large flap size necessary, donor site morbidity is conspicuous. The pedicled ALT flap is considered a good alternative in thin patients and donor site scar is easily concealed when dressed, while the color match resembles the perineal skin.<sup>4</sup> The combined application of these techniques has been proposed in transgender surgery, as the RFFF can be used to reconstruct urethra and glans only, while the ALT flap addresses the soft tissue reconstruction.<sup>5</sup> This association retains the double advantages of a less conspicuous scar with lower urethral complications (such as fistulas and stenosis), when compared with the tube into tube technique.<sup>6</sup>

We here describe a double flap phalloplasty using a pedicled ALT flap for penis reconstruction and an RFFF for complete neourethra and glans reconstruction following the amputation of the penis due to cancer. Critical surgical steps and long-term outcomes are analyzed and discussed.

## Case Presentation

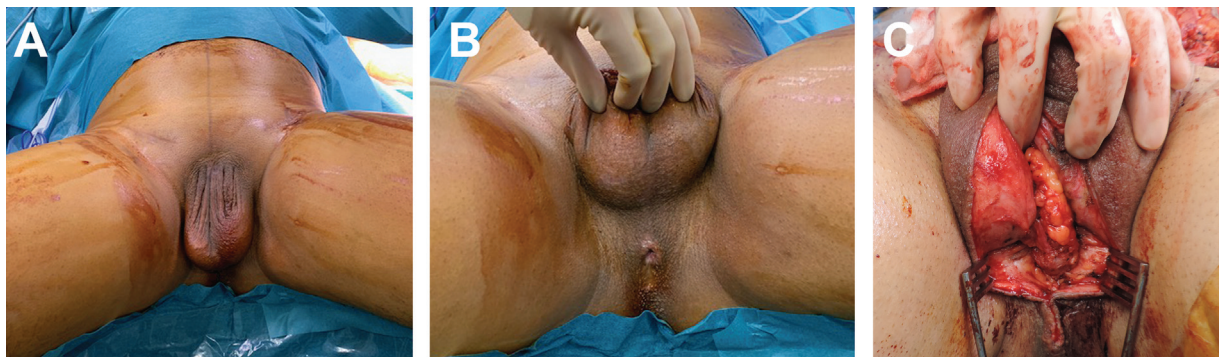In December 2019, a 48-year-old patient, heavy smoker, came to our department following a total penectomy with inferior urethral derivation and bilateral inguinal lymph node dissection due to a squamous cell carcinoma of the glans T3N0M0 (performed 6 months before). The oncologic resection was performed in other institution and included resection of both great saphenous veins and crosssectomy (→ Fig. 1).

The indication for a double flap phalloplasty was posed as only way to fully reconstruct the urethra on its length

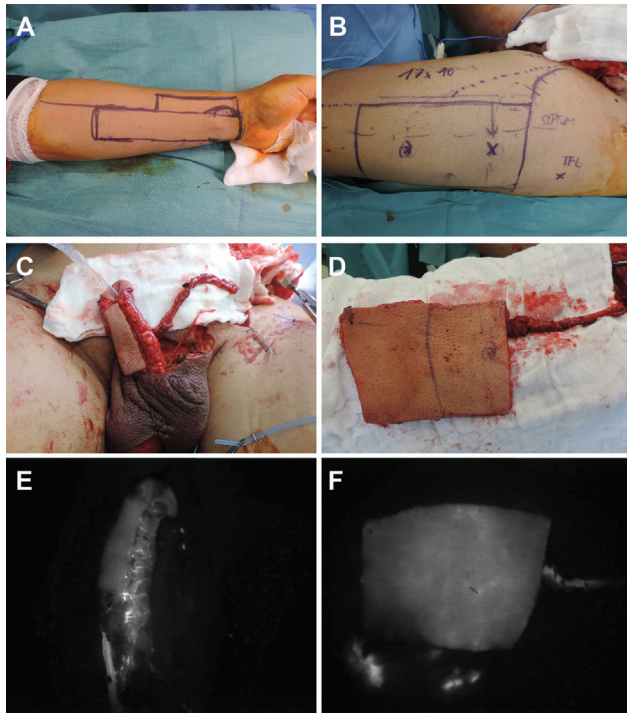
avoiding possible complications of single flap reconstruction using tube into tube technique. Among the preoperative imaging, a magnetic resonance imaging was realized to exclude distal spread of the disease and metastaticity. An angio-computed tomography was performed to evaluate recipient vessels at the pubic level.

Patient was installed in gynecological position. After disinfection, first step was inserting a urinary catheter size 16 at the level of the urethrostomy. Proximal urethra was mobilized over 2 to 3 cm to allow further suture to the RFFF neourethra. After exploration of both inguinal carrefours, no adequate receiving vein branches were found (necessary for the free flap venous outflow), due to the previous demolitive procedure. We then decided to approach the right deep inferior epigastric artery and vein (DIEA-V). This pedicle was dissected from the level of the inguinal ligament cranially for 10 to 12 cm, to be used as main pedicle to perform microsurgical anastomosis. At the level of the inguinal canal, the left ilioinguinal nerve was isolated.

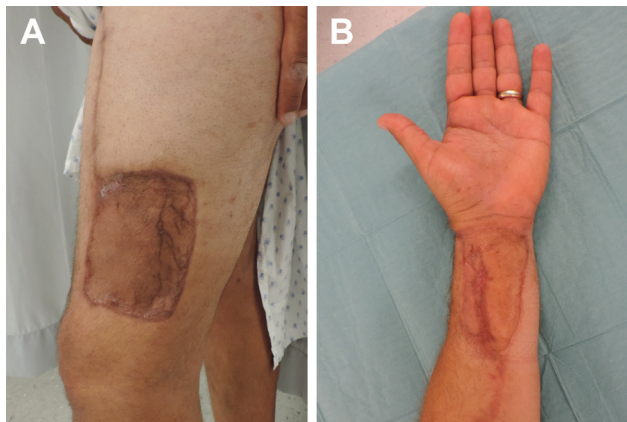
Harvesting of RFFF was performed simultaneously with anterolateral thigh (ALT) perforator flap. RFFF was raised in standard fashion from distal to proximal, relying on both superficial and deep venous drainage, including both medial and lateral antebrachial cutaneous nerves. ALT flap (11 × 11 cm) was raised on a single distal perforator with a long intramuscular course, allowing for a long pedicle length, with the descending branch of the lateral circumflex femoral artery followed up to the rectus branch, which was ligated. Perfusion of both flaps (neourethra and glans from RFFF and penile shaft from the ALT flap), was assessed by indocyanine green perfusion and fluorescence lamp (Fluobeam, Grenoble, France) (→ Fig. 2). After urethral sutures (Maxon 4.0), the RFFF was microsurgically anastomosed in end-to-end pattern to the DIEA-V and revascularization was uneventful. The ALT flap was then passed under the rectus femoris and sartorius muscle and wrapped around the neourethra. Nerve anastomosis was performed between ilioinguinal and antebrachial nerves. Donor sites were partially closed and then skin grafted. For the wrist, we applied a dermal matrix interface before application of the skin graft, to maximize aesthetic and functional results<sup>7</sup> (→ Fig. 3).



**Fig. 1** Preoperative images. (A) A 48-year-old patient came to our department following a total penectomy with inferior urethral derivation (B) and bilateral inguinal lymph node dissection due to a squamous cell carcinoma of the glans. (C) Proximal urethra was mobilized over 2 to 3 cm to allow further suture to the radial forearm free flap neourethra.



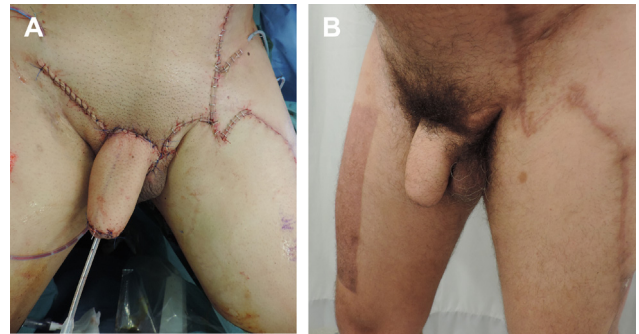**Fig. 2** (A) Preoperative skin markings of the radial forearm free flap (RFFF). RFFF was 18 in length, width was 4 cm proximally, and 6 distally to preserve the radial pedicle. (B) The pedicle anterolateral thigh (ALT) flap preoperative markings with a skin paddle of 17 × 10 cm. (C) RFFF inset at the pubic area, flap pedicle, and the antebrachial nerve is seen. (D) The pedicled ALT at the donor site. (E–F) Perfusion of both flaps (neourethra from RFFF and penile shaft from the ALT flap), was assessed by indocyanine green perfusion and fluorescence lamp (Fluobeam, Grenoble, France).



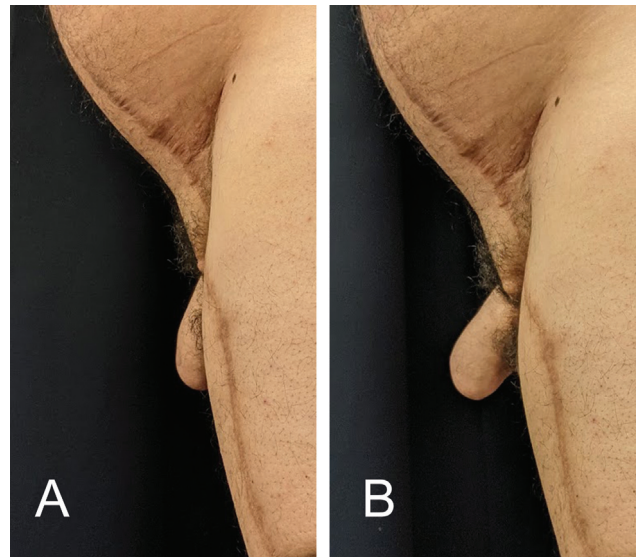
**Fig. 3** Donor site appearance ([A] thigh, [B] forearm) at 3 months follow-up.

Operative time was 9 hours. Patient was kept in bed for 5 days, then progressively mobilized and discharged at postoperative day 13, after removal of the catheter the day before.

No major or minor complication occurred in the early or late postoperative period and both flaps healed uneventfully with no neourethral strictures or fistulas described. Twelve months follow-up confirmed optimal functional outcomes and the patient underwent a day hospital surgery for penile



**Fig. 4** Functional result after the implant of penile inflatable prosthesis (A–B).



**Fig. 5** Neophallus appearance in the immediate postoperative period (A), and at 18 months follow-up (B).

implant positioning (► Fig. 4). At 18 months follow-up, the patient was extremely satisfied with the aesthetic result and was able to void in standing position without functional discomfort or urinary retention (► Fig. 5).

## Discussion

Total phalloplasty following penile amputation due to cancer represents a fundamental step to improve patient's quality of life and poses unique challenges even when compared with female-to-male sex reassignment surgery.

Despite using the RFFF is considered nowadays the gold standard in TPR, various drawbacks need to be acknowledged, including the conspicuous donor-site morbidity, atrophy of bulk over time, color mismatch, and the necessity for microsurgery.<sup>8</sup>

The pedicled ALT flap represents a good option for TPR in patients who do not want the conspicuous scar associated with the RFFF, as donor site morbidity is lower and the color match with the inguinal region is good, providing a satisfactory aesthetic result.

Because of the flap thickness however, it is not always possible to reconstruct the urethra using a tube-in-tube technique. In fact, harvesting a thin flap above the Scarpa fascia bear the risk to damage the nervous sensitive skin branches that runs above the muscular fascia.<sup>9</sup> The use of tissue expansion to obtain a thinner and larger flap is of little use in literature,<sup>10</sup> as it requires multiple surgical steps with increased reconstruction time and patient discomfort.

However, considering the importance for men to void in standing position, various surgical urethroplasties strategies have been developed, including double flap procedures and flap prelamination using a skin graft.

According to D'Arpa et al in their comparative study on more the 90 penile reconstructions using pedicled ALT flap and various different urethroplasty technique, the ALT prelamination with a skin graft is associated with a high rate of urethral strictures and should therefore be reserved to selected cases.<sup>5</sup>

Among secondary flap procedures for urethroplasty, the harvest of a pedicled superficial circumflex artery perforator (SCIP) flap allows avoiding a microsurgical transfer with low donor site morbidity (inconspicuous scar and no sacrifice of a major artery compared with RFFF) and has become the first choice for many surgeons.<sup>6</sup> Unfortunately, our patient had previously undergone bilateral inguinal lymph node dissection, with possible jeopardization of the SCIP pedicle. Moreover, this procedure would have carried the nonnegligible risk of iatrogenic lower limb lymphedema.

On the other side, most of authors agree that when using a pedicled ALT flap alone for phalloplasty, the skin sensitivity remains an important concern, being significantly less compared with that of patients treated with RFFF.<sup>11</sup> In our case, the use of the sensate RFFF for the reconstruction of the glans ensured a satisfactory sensory recovery at the level of the urinary meatus.

Urethral complications, including strictures or fistulas, are among the most common complications following phallus reconstruction with a rate that can be as high as 50% and secondary procedures are often needed.<sup>5</sup> Strictures most frequently occur at the anastomosis between the phallic and the fixed part of the urethra and are probably due to a scarring/secondary healing process occurring because of suboptimal flaps vascularization.<sup>11</sup>

In 2017, Van der Sluis et al first described this combined procedure in 19 transgender patients who desired less conspicuous forearm scars, describing promising results in terms of donor site scars and color match of the reconstructed penis.<sup>12</sup>

The choice of a double flap reconstruction was driven by the urethral defect that was assessed at 18cm, which is significantly longer than typical urethral reconstructed length (12–14 cm, e.g., in transgender surgery).

Such length could have been potentially addressed by the usual tube-into-tube technique using the radial forearm flap only. However, such choice would have implied a huge skin paddle raise and would have led to an even more conspicuous defect at the level of the forearm. RFFF in transgender can

reach skin paddle surfaces of 16 × 16 cm,<sup>13</sup> but bigger skin paddles present more risks of venous insufficiency at the flap borders. In the reported case, we wanted to avoid harvesting of a single flap only, as we wanted to dedicate the full perfusion of the RFFF to the neourethra, which had to be reconstructed on a particularly important length, avoiding excessive flap plication. According to our results, we think that a double tissue transfer for TPR should be considered, particularly when a urethral length over 14 cm needs to be reconstructed. While the pedicled ALT can be used to reconstruct a proper penile shaft with an easily concealed scar, the RFFF can provide adequate neourethra length with satisfactory sensory recovery.

#### Author Contributions

P.d.S. designed the study. G.S. drafted the first version of the manuscript. O.B. and P.d.S. were the senior consultants involved in the surgery. All authors read and approve the final version of the manuscript.

#### Ethical Approval

The study was conducted accordingly to the guiding principles following the Declaration of Helsinki of 1975, informed consent was obtained from the patients.

#### Patient Consent

The patient signed an informed consent, allowing for publication of sensible data as well as photo/video material.

#### Funding

None.

#### Conflict of Interest

None declared.

#### References

- Hakenberg OW, Dräger DL, Erbersdobler A, Naumann CM, Jünnemann KP, Protzel C. The diagnosis and treatment of penile cancer. *Dtsch Arztebl Int* 2018;115(39):646–652
- Marchioni M, Berardinelli F, De Nunzio C, et al. New insight in penile cancer. *Minerva Urol Nefrol* 2018;70(06):559–569
- Chang TS, Hwang WY. Forearm flap in one-stage reconstruction of the penis. *Plast Reconstr Surg* 1984;74(02):251–258
- Felici N, Felici A. A new phalloplasty technique: the free anterolateral thigh flap phalloplasty. *J Plast Reconstr Aesthet Surg* 2006; 59(02):153–157
- D'Arpa S, Claes K, Lumen N, Oieni S, Hoebeke P, Monstrey S. Urethral reconstruction in anterolateral thigh flap phalloplasty: a 93-case experience. *Plast Reconstr Surg* 2019;143(02): 382e–392e
- Veerman H, de Rooij FPW, Al-Tamimi M, et al. Functional outcomes and urological complications after genital gender affirming surgery with urethral lengthening in transgender men. *J Urol* 2020;204(01):104–109
- Wafsa W, di Summa PG, Meuli J, Raffoul W, Bauquis O. MatriDerm decreases donor site morbidity after radial forearm free flap harvest in transgender surgery. *J Sex Med* 2017;14(10): 1277–1284
- Morrison SD, Son J, Song J, et al. Modification of the tube-in-tube pedicled anterolateral thigh flap for total phalloplasty:

- the mushroom flap. *Ann Plast Surg* 2014;72(Suppl 1): S22-S26
- 9 Hong JP, Choi DH, Suh H, et al. A new plane of elevation: the superficial fascial plane for perforator flap elevation. *J Reconstr Microsurg* 2014;30(07):491-496
- 10 D'Arpa S, Colebunders B, Stillaert F, Monstrey S. Pre-expanded anterolateral thigh perforator flap for phalloplasty. *Clin Plast Surg* 2017;44(01):129-141
- 11 Lumen N, Monstrey S, Ceulemans P, van Laecke E, Hoebeke P. Reconstructive surgery for severe penile inadequacy: phalloplasty with a free radial forearm flap or a pedicled anterolateral thigh flap. *Adv Urol* 2008. Doi: 10.1155/2008/704343
- 12 van der Sluis WB, Smit JM, Pigot GLS, Buncamper ME, Winters HAH, Mullender MG, Bouman MB. Double flap phalloplasty in transgender men: Surgical technique and outcome of pedicled anterolateral thigh flap phalloplasty combined with radial forearm free flap urethral reconstruction. *Microsurgery* 2017;37(8):917-923
- 13 Garaffa G, Raheem AA, Christopher NA, Ralph DJ. Total phallic reconstruction after penile amputation for carcinoma. *BJU Int* 2009;104(06):852-856