




# Knee Defect Reconstruction Using the Distally Based Anterolateral Thigh Flap Based on the Reverse Flow from the Oblique Branch of the Lateral Circumflex Femoral Artery

Danying Wang, MD<sup>1</sup> Mengqing Zang, MD<sup>1</sup> Hengyuan Ma, MD<sup>1</sup> Yuanbo Liu, MD<sup>1</sup> 

<sup>1</sup>Department of Plastic and Reconstructive Surgery, Plastic Surgery Hospital, Chinese Academy of Medical Sciences and Peking Union Medical College, Beijing, China

Arch Plast Surg 2022;49:444–447.

Address for correspondence Yuanbo Liu, MD, Department of Plastic and Reconstructive Surgery, Plastic Surgery Hospital, Chinese Academy of Medical Sciences and Peking Union Medical College, No. 33 Ba-Da-Chu Road, Beijing 100144, China (e-mail: ybpumc@sina.com).

## Abstract

Reconstruction of soft tissue defects around the knee is challenging, and the most common solution is to use various locoregional flaps or, in some difficult cases, a free flap. The distally based anterolateral thigh (dALT) flap is a commonly used flap that relies on reverse blood flow from the descending branch of the lateral circumflex femoral artery (d-LCFA). Here, we present the case of an anteromedial knee reconstruction using a dALT flap after resection of a pleomorphic undifferentiated sarcoma. The tumor resection resulted in a 14 × 7 cm defect, and a dALT flap, measuring 20 × 8 cm was elevated. During the surgery, we found a robust oblique branch of the LCFA (o-LCFA) sending off two sizable perforators to the anterolateral thigh region, whereas the d-LCFA was relatively small with no usable perforators. Therefore, we harvested a dALT flap relying on reverse flow from the o-LCFA. The patient's postoperative course was uneventful, and the flap survived without complications. This report demonstrates that reverse flow from the o-LCFA may be an alternative to nourish a dALT flap in cases where the d-LCFA is hypoplastic or suitable perforators from the d-LCFA are unavailable.

## Keywords

- ▶ anterolateral thigh flap
- ▶ distally based anterolateral thigh flap
- ▶ knee defect reconstruction

The reconstruction of soft tissue defects around the knee still challenges plastic surgeons. Many surgical options can be chosen, including various locoregional flaps and even free flaps.<sup>1–3</sup> The distally based anterolateral thigh (dALT) flap utilizes the reverse blood flow from the descending branch of the lateral circumflex femoral artery (d-LCFA) and is commonly used to reconstruct knee defects. The vascular anastomosis between the d-LCFA and the superior lateral

genicular artery and the reverse flow from the d-LCFA constitute the anatomical basis of the dALT flap.<sup>4</sup>

Although usage of the dALT flap has been reported, anatomic variations in the vascular supply of the flap as well as the variable location of the dominant perforators remain a major concern for surgeons.<sup>5</sup> In cases where the d-LCFA is hypoplastic or suitable perforators from the d-LCFA are unavailable, elevating a dALT flap could be difficult. In the

DOI <https://doi.org/10.1055/s-0042-1748661>.  
ISSN 2234-6163.

© 2022. The Korean Society of Plastic and Reconstructive Surgeons. All rights reserved.

This is an open access article published by Thieme under the terms of the Creative Commons Attribution-NonDerivative-NonCommercial-License, permitting copying and reproduction so long as the original work is given appropriate credit. Contents may not be used for commercial purposes, or adapted, remixed, transformed or built upon. (<https://creativecommons.org/licenses/by-nc-nd/4.0/>)

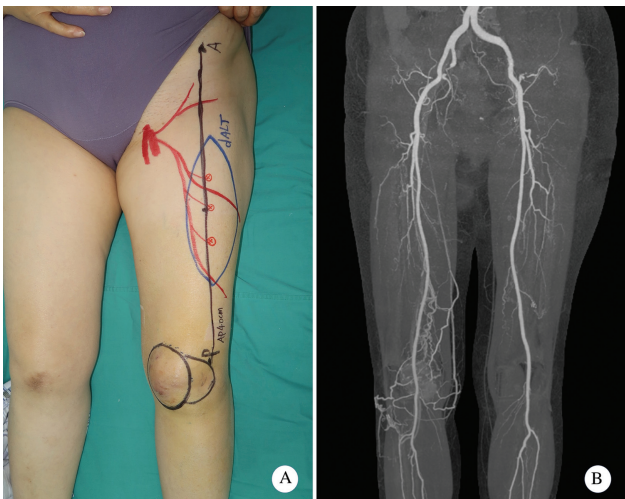
Thieme Medical Publishers, Inc., 333 Seventh Avenue, 18th Floor, New York, NY 10001, USA

following case, we present knee defect coverage by using a dALT flap based on reverse flow from the oblique branch of the LCFA (o-LCFA). To the best of our knowledge, this is the first report of this type of dALT flap to appear in the literature.

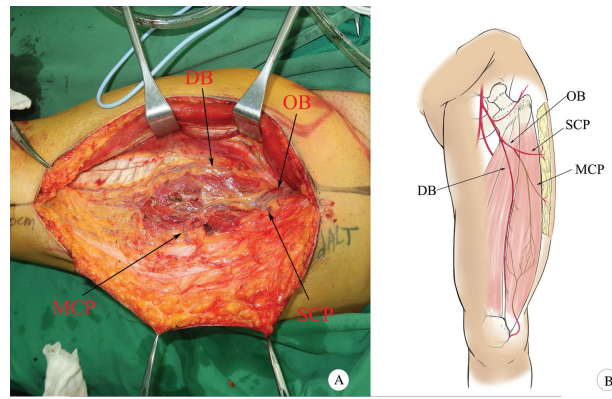
**Case**

A 63-year-old woman presented with an undifferentiated pleomorphic sarcoma on her left anteromedial knee. Perforators were explored using the hand-held Doppler along the line connecting the anterior superior iliac spine and the superolateral border of the patella. Three perforators were identified and marked on the skin (►Fig. 1A). Preoperative computed tomography angiography revealed a well-developed o-LCFA, while the d-LCFA seemed to be hypoplastic (►Fig. 1B).

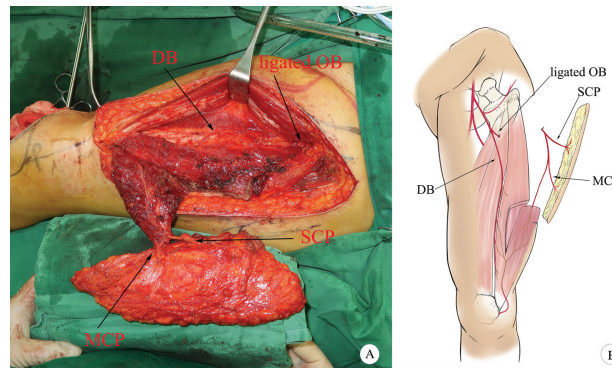
The flap was raised using a previously described method.<sup>6</sup> The medial margin of the flap was first incised down to the deep fascia and the lateral intermuscular septum was opened. The overall characteristics of the LCFA were observed. A robust oblique branch was found that originated from the descending branch; this oblique branch sent one septocutaneous perforator and one musculocutaneous perforator to the anterolateral thigh skin. The descending branch traveled along the medial border of the vastus lateralis muscle without sending off any sizable perforators (►Fig. 2). The flap was elevated based on the two perforators from the o-LCFA. The antegrade flow from the proximal end of the o-LCFA was temporarily blocked with a vascular clamp. One hour later, we found that the flap had a good arterial supply and venous drainage. The proximal oblique branch was then ligated and cut. To increase the length of the vascular pedicle, and more importantly, to maximally protect the vascular connection between the o-LCFA and the vascular network of the knee joint, we preserved a cuff of vastus lateralis muscle at the distal end of the vascular



**Fig. 1** (A) Preoperative view showing the location of the sarcoma and flap design. (B) Preoperative computed tomography (CT) angiography reveals a well-developed oblique branch (OB) originating from the descending branch (DB). The DB itself appeared hypoplastic.



**Fig. 2** (A) A robust oblique branch (OB) originating from the descending branch (DB) and sending off one septocutaneous perforator (SCP) and one musculocutaneous perforator (MCP) to the anterolateral thigh region. The descending branch travels along the medial margin of the vastus lateralis muscle without sending off any sizable perforators. (B) This schematic diagram shows the overall arborization of the lateral circumflex femoral artery and anatomical basis for harvesting a distally based anterolateral thigh flap.



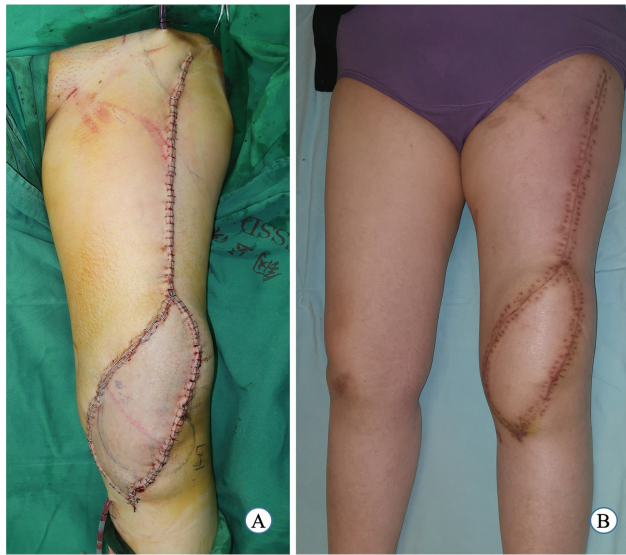**Fig. 3** (A) A distally based anterolateral thigh flap based on one septocutaneous perforator (SCP) and one musculocutaneous perforator (MCP) originating from the oblique branch (OB) was completely elevated. (B) This schematic diagram illustrates the anatomical basis of the distally based anterolateral thigh flap based on the perforators from the OB of the lateral circumflex femoral artery (LCFA).

pedicle (►Fig. 3). The flap was rotated 180 degrees and transferred to the recipient site through a subcutaneous tunnel to reconstruct the defect with primary closure of the donor site. The flap showed a good arterial supply and venous drainage (►Fig. 4A).

The patient's postoperative course was uneventful. The flap completely survived without any major complications. Three weeks after the surgery, the stitches were removed, and the patient was encouraged to start ambulatory training. At the 6-month follow-up, the flap had completely healed (►Fig. 4B), and good functional and aesthetic results were obtained.

**Discussion**

Since its description,<sup>7</sup> the dALT flap has become one of the commonly used methods for reconstructing defects around



**Fig. 4** (A) The flap perfusion during surgery. (B) Postoperative appearance at the 6-month follow-up.

the knee.<sup>8</sup> A consistent and reliable vascular anastomosis exists between the d-LCFA and the articular geniculate network, particularly the superior lateral genicular artery, which constitutes the anatomical basis for the dALT flap procedure. Wong et al<sup>9</sup> first described the o-LCFA, which travels between the transverse LCFA and d-LCFA and sends perforators into the anterolateral thigh skin. A proximally based or free anterolateral thigh flap can be elevated based on the o-LCFA. Additionally, when elevating an anterolateral thigh myocutaneous flap, the muscle component can be nourished by the d-LCFA, while the cutaneous component may become necrotic because the blood supply to the skin comes entirely from the o-LCFA. This relatively rare condition has been defined as the “oblique branch trap.”<sup>10</sup>

If the perforators originate from the oblique branch and there is a long enough common trunk between the oblique and descending branches, a dALT flap can still be elevated; this type of flap relies on the o-LCFA perforator and reverse flow from the d-LCFA.<sup>5,6</sup> The most notable advantage of this type of dALT flap is that it can have a very long vascular pedicle, ensuring that the flap can be transferred a greater distance. However, the biggest disadvantage of this approach is that it necessitates cutting off the main trunk of the d-LCFA, which can compromise the blood supply to the thigh muscles.<sup>5,11</sup> Under similar preconditions, we have successfully elevated a dALT flap based on the perforating vessels from the o-LCFA; the flap itself was nourished by the reverse flow from the oblique branch. To the best of our knowledge, this is the first description of this kind of dALT flap.

During the surgery, we found that the oblique branch was larger and sent off two sizable perforators to the anterolateral thigh region. On the contrary, the descending branch was comparatively small. No usable perforators could be identified originating from the descending branch. After elevating the flap, we temporarily blocked the antegrade flow from the proximal oblique branch with a vascular clamp. We found that

the dALT flap had good arterial blood supply and venous drainage. We then elevated a dALT flap based on the reverse flow from the o-LCFA. The transverse, descending, and rectus femoris branches of the LCFA could be spared, thereby greatly reducing the difficulties surrounding the surgery, donor-site morbidities, and devascularization of the pertinent musculature. Instead of further intramuscular dissection of the oblique branch in the vastus lateralis muscle, a cuff of this muscle was preserved around the distal end of the oblique branch to avoid compromising the vascular anastomoses between the o-LCFA and the superior lateral genicular artery within the muscle. It is worth noting that clamping of the proximal vascular pedicle to ensure an adequate perfusion from the distal portion of the o-LCFA with either testing of skin bleeding or intraoperative angiography is always advisable before flap transfer.<sup>12</sup> Even for the dALT flap based on the d-LCFA, adequate perfusion of the flap must be determined before the flap transfer, since not all descending branches have anastomosis with the superior lateral genicular artery.<sup>13</sup>

Previous studies have suggested that the oblique branch terminates in the substance of the vastus lateralis muscle without retrograde inflow<sup>5</sup>; as such, the perfusion of a dALT flap based on reverse flow from the o-LCFA may not be reliable. Nevertheless, our case confirmed the existence of vascular connections between the o-LCFA and the articular geniculate network. However, it is inappropriate to draw any positive conclusion from a single case. Further anatomic studies and clinical observations are needed to investigate the anastomotic characteristics of this vascular connection. The reliability of elevating this dALT flap should also be evaluated. Even so, we believe that this new type of dALT flap is worthy of consideration by surgeons in cases where the d-LCFA is hypoplastic or suitable perforators from the d-LCFA are unavailable.

#### Author Contributions

Conceptualization: D.W. and Y.L. Data curation: M.Z. and H.M. Writing-original draft: D.W. Writing-review and editing: Y.L., M.Z., H.M.

#### Ethical Approval

The study was performed in accordance with the principles of the Declaration of Helsinki. Written informed consent was obtained.

#### Patient Consent

The patient's legal guardian provided written informed consent for the publication and the use of her images.

#### Conflict of Interest

None declared.

#### References

- Mayoly A, Mattei JC, Moullot P, et al. Gastrocnemius myocutaneous flaps for knee joint coverage. *Ann Plast Surg* 2018;81(02): 208–214
- Kerfant N, Ta P, Trimaille A, et al. Soft tissue coverage options around the knee. *Ann Chir Plast Esthet* 2020;65(5-6):517–523

- 3 Sapino G, Zaugg P, Cherix S, et al. ALT flap with vascularized fascia lata for one-stage functional patellar tendon reconstruction. *J Plast Reconstr Aesthet Surg* 2019;72(03):467–476
- 4 Jenwitheesuk K, Sukprasert P, Winaikosol K, Jantajang N. Knee reconstruction using a distally based anterolateral thigh flap: an anatomical cadaveric study. *J Wound Care* 2018;27(Sup9a):S28–S31
- 5 Wong CH, Goh T, Tan BK, Ong YS. The anterolateral thigh perforator flap for reconstruction of knee defects. *Ann Plast Surg* 2013;70(03):337–342
- 6 Liu Y, Ding Q, Zang M, et al. Classification and application of the distally-based thigh flap based on the lateral circumflex femoral artery system. *Ann Plast Surg* 2017;78(05):497–504
- 7 Zhang G. [Reversed anterolateral thigh island flap and myocutaneous flap transplantation]. *Zhonghua Yi Xue Za Zhi* 1990;70(12):676–678
- 8 Sahasrabudhe P, Panse N, Baheti B, Jadhav A, Joshi N, Chandanwale A. Reconstruction of complex soft-tissue defects around the knee joint with distally based split vastus lateralis musculocutaneous flap: a new technique. *J Plast Reconstr Aesthet Surg* 2015;68(01):35–39
- 9 Wong CH, Wei FC, Fu B, Chen YA, Lin JY. Alternative vascular pedicle of the anterolateral thigh flap: the oblique branch of the lateral circumflex femoral artery. *Plast Reconstr Surg* 2009;123(02):571–577
- 10 Wong CH. The oblique branch trap in the harvest of the anterolateral thigh myocutaneous flap. *Microsurgery* 2012;32(08):631–634
- 11 Lin RY, Chien WH. Experiences in harvesting type II distally based anterolateral thigh flaps. *Plast Reconstr Surg* 2006;118(01):282–284
- 12 Bekarev M, Goch AM, Geller DS, Garfein ES. Distally based anterolateral thigh flap: an underutilized option for peri-patellar wound coverage. *Strateg Trauma Limb Reconstr* 2018;13(03):151–162
- 13 Boonrod A, Thammaroj T, Jianmongkol S, Prajaney P. Distal anastomosis patterns of the descending branch of the lateral circumflex femoral artery. *J Plast Surg Hand Surg* 2016;50(03):167–170