



Acquired Cutis Laxa on the Upper Eyelids and Earlobes: A Case Report and Literature Review

Kyoko Katsuren, MD^{1,2} Ryogo Kuba, MD^{1,2} Shogo Kasai, MD² Yusuke Shimizu, MD, PhD²

¹Department of Plastic Surgery, Chubu Tokushukai Hospital, Okinawa, Japan

²Department of Plastic and Reconstructive Surgery, Ryuky University Hospital, Okinawa, Japan

Address for correspondence Kyoko Katsuren, MD, Department of Plastic Surgery, Chubu Tokushukai Hospital, 901-2393, 801, Higa, Kitanakagusuku-son, Okinawa, Japan (e-mail: inainakyonpi@gmail.com).

Arch Plast Surg 2022;49:418–422.

Abstract

Keywords

- ▶ cutis laxa
- ▶ elasticity
- ▶ laxity
- ▶ urticaria
- ▶ surgery

Acquired cutis laxa is a rare disease. Owing to few reports on the condition, no statistical data have been produced. Cutis laxa is characterized by drooping skin, caused by decreased levels of dermal elastin, leading to reduced skin elasticity. The disease usually emerges on the neck or trunk and spreads throughout the body; however, it rarely involves the extremities.² Moreover, cases localized to the face are rare. The objective of this clinical case report was to highlight this unusual disease in a 24-year-old female, with localization on the face and neck. The patient underwent surgery for treatment of bilateral ear lobe and eyelid skin laxity.

Cutis laxa is a disease characterized by drooping skin. Decreased elastin in the dermis results in loss of skin elasticity.^{1–7} Acquired cutis laxa is a rare form of cutis laxa and is often preceded by an urticaria-like skin rash in response to drugs or insect bites.^{2–5} Acquired cutis laxa usually emerges on the neck or trunk and develops to involve other parts of the body; however, it rarely affects the extremities.² Acquired cutis laxa confined to the face is also rare.^{3,7,8}

We report a case of acquired cutis laxa localized on the face and neck that was treated with bilateral ear lobe and eyelid surgery, and we present a review of the literature.

Case Report

A 24-year-old Japanese female was referred to the Department of Plastic Surgery for pronounced facial skin laxity. The patient had visited our dermatology department for facial skin laxity when she was 18 years old, following the first onset of the condition at the age of 14 years. Urticaria was

recorded over the patient's abdomen 2 years before the appearance of skin laxity. The patient was diagnosed with acquired cutis laxa by a dermatologist. Since there was no specific treatment, the patient was placed under observation. When symptoms progressed, she was referred to our department. At her first visit, skin laxity was limited to the face and neck (▶Fig. 1A, B). The patient's past medical history included meningitis at 1 year of age, Kawasaki's disease at 3 years, and hand-foot-and-mouth disease in childhood. There was no family history of cutis laxa and the patient was not taking any medications. No evidence of alopecia, bleeding diathesis, delayed wound healing, or difficulty in opening the mouth was recorded. Urticaria-like redness was observed over the abdomen. Bone marrow examination and blood test results showed no evidence of neoplasia, such as multiple myeloma or mastocytosis. Cardiac ultrasonography, computed tomography of the chest and abdomen, chest radiographs, and electrocardiography were normal. None of the currently reported gene mutations for cutis laxa was found and no mutations were found in the

DOI <https://doi.org/10.1055/s-0042-1748657>.
ISSN 2234-6163.

© 2022. The Korean Society of Plastic and Reconstructive Surgeons. All rights reserved.

This is an open access article published by Thieme under the terms of the Creative Commons Attribution-NonDerivative-NonCommercial-License, permitting copying and reproduction so long as the original work is given appropriate credit. Contents may not be used for commercial purposes, or adapted, remixed, transformed or built upon. (<https://creativecommons.org/licenses/by-nc-nd/4.0/>)

Thieme Medical Publishers, Inc., 333 Seventh Avenue, 18th Floor, New York, NY 10001, USA

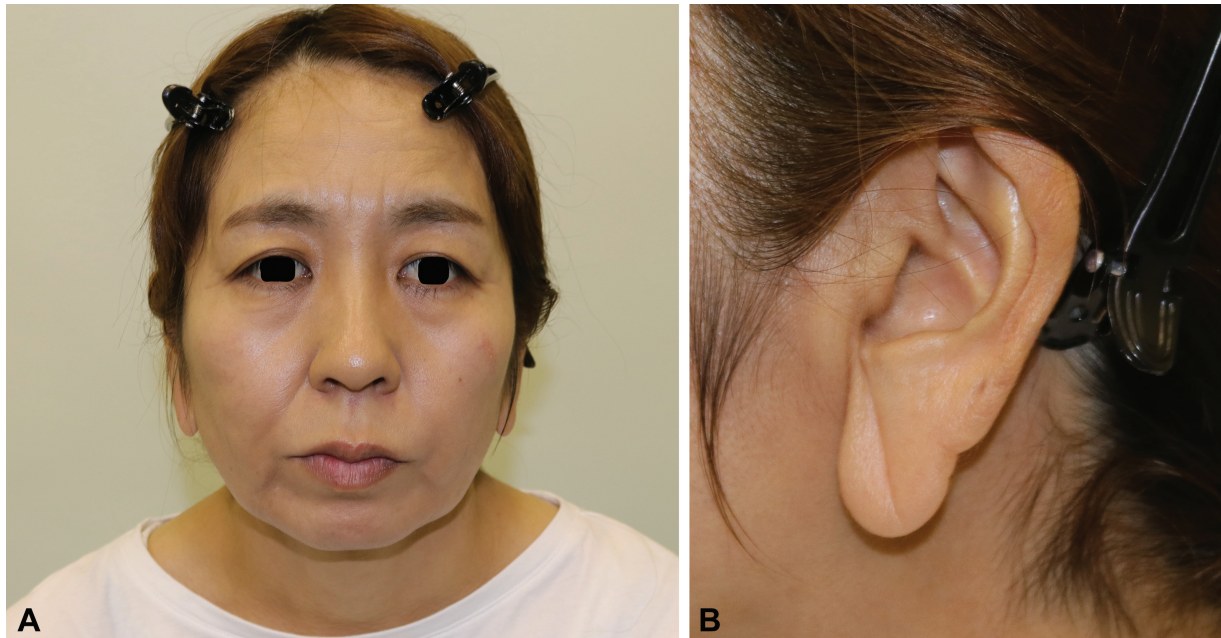

Fig. 1 (A) Generalized drooping of the skin of the face. (B) Drooping of the skin on the left earlobe.

following genes: *ELN*, *ALDH18A1*, *FBLN5*, *LTBP4*, *FBLN4*, *ATP6VOA2*, *PYCR1*, *ATP6V1E1*, *ATP6V1A*, *PYCR1*, *ALDH18A1*, and *ATP7A*. Hematoxylin and eosin (H&E)-stained skin biopsy specimens from the cheek, upper limb, and abdomen revealed predominantly lymphocytic perivascular inflammatory cell infiltrates that spared sweat glands, sebaceous glands, and hair follicles. The Verhoeff-Van Gieson elastic (EVG) staining showed reduced, torn, and thinned elastic fibers in all tissue layers; however, there were no changes in elastic fibers of the vessel walls (►Fig. 2).

Surgery was performed under local anesthesia. Spindle-shaped sections of the skin and orbicularis oculi muscle (maximum width of 7 mm) were excised. Care was taken to make sure that the wound was flush with the original position of the eyelid fold. The wound was sutured with 6-0 nylon to reduce excess skin at the suture edge (►Fig. 3A). A

wedge-shaped section of the earlobe along the contour of the auricular cartilage was removed at the facial attachment and the incision was sutured with 6-0 nylon (►Fig. 3B, C).

The resected right upper eyelid and right earlobe tissues were pathologically examined, and they demonstrated mild lymphocytic perivascular infiltrates with H&E staining and fragmentation and reduction of dermal elastic fibers with

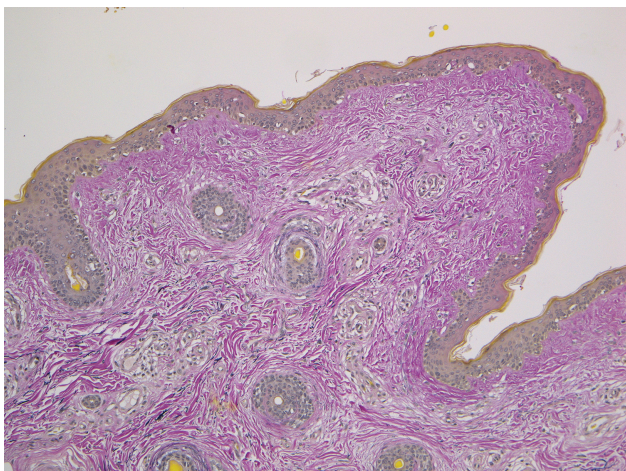


Fig. 2 EVG staining ($\times 100$): decreased number of elastic fibers and tears in the fibers. EVG, Verhoeff-Van Gieson elastic.

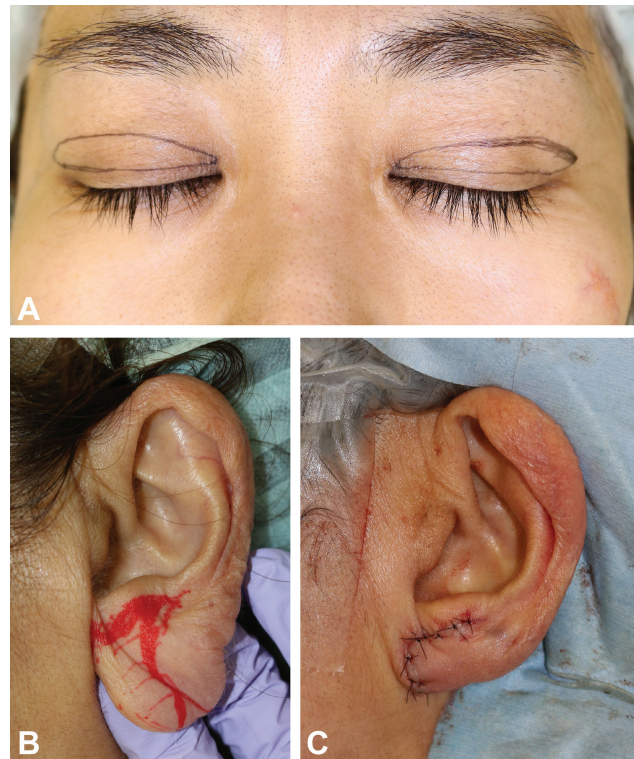

Fig. 3 (A) Upper eyelid design. (B) Left earlobe design. (C) Postoperative left earlobe surgery.

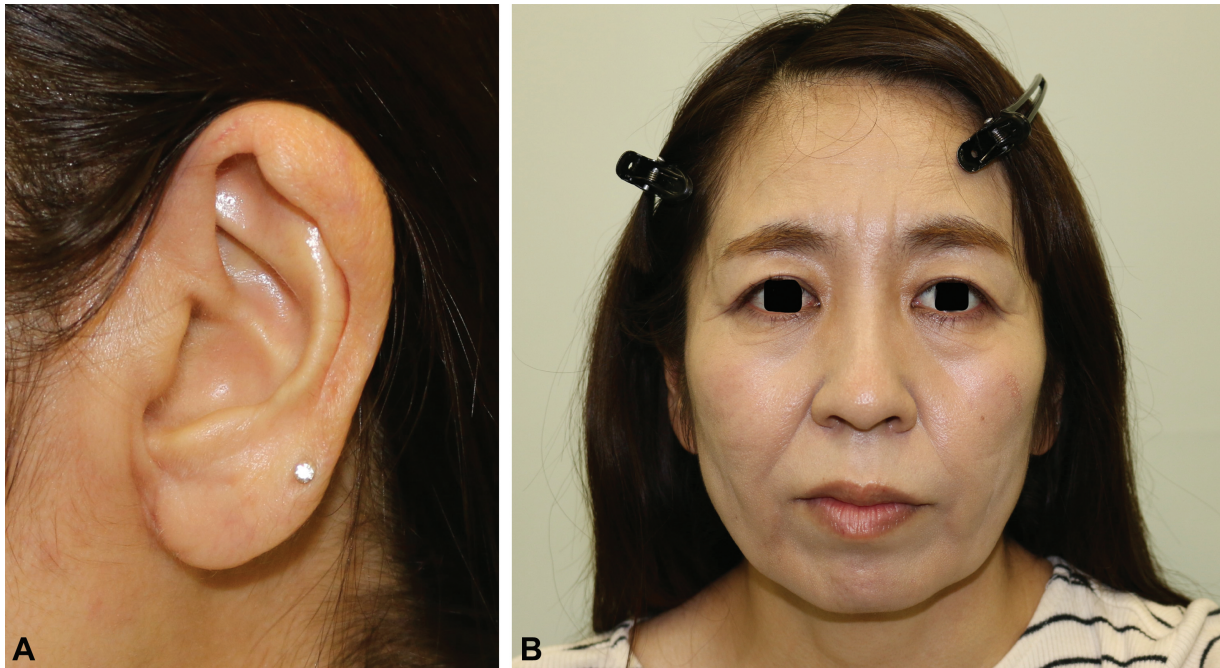


Fig 4. (A) Fifteen months after surgery. The upper eyelid shows mild skin laxity. (B) Fifteen months after surgery. There is no obvious skin laxity in the left auricle.

EVG staining. No inflammation or myofiber degeneration was seen in the orbicularis oculi muscle.

Skin laxity progressed after surgery; however, at a 15-month postsurgical follow-up examination, the patient did not wish to undergo further surgical treatment (► **Fig. 4A, B**).

Discussion

Cutis laxa is a disease characterized by premature skin aging due to decreased dermal elastin.^{2,7,9–12} Cutis laxa may be congenital, acquired, or a cutis laxa–related disorder. Precise estimates of prevalence are unavailable due to the rarity of cases.^{2,5} Congenital cutis laxa may be inherited as an autosomal dominant trait, autosomal recessive trait, or X-linked recessive trait.^{1,2,4,5,9} Cases of congenital cutis laxa exhibit mutations in the genes that encode elastin, ALDH18A1, fibulin5, latent transforming growth factor (TGF)- β -binding protein4 (LTBP4), fibulin4, ATP6VOA2, PYCR1, ATP6V1E1, ATP6V1A, and ATP7A. Complications of congenital cutis laxa include pulmonary atelectasis and emphysema, multiple intestinal diverticula, hernia, vascular and skeletal abnormalities, and mental retardation.^{1–5} Acquired cutis laxa may be associated with urticaria, drug intake, poisoning, infection, collagen disease, or hematological malignancies² and may involve complications such as aortic ectasia, aortic aneurysm, and pulmonary emphysema.^{2,4} Acquired cutis laxa may clinically resemble hematological malignancies or Ehlers–Danlos syndrome; therefore, diagnosis requires comprehensive systematic examination, clinical testing, and histopathological examination of the skin.^{2,3,5,6}

The cutaneous manifestations of congenital cutis laxa may disappear with age; follow-up is suggested until symptoms disappear.³ In contrast, symptoms progress with age for

those with acquired cutis laxa.⁵ Currently, no treatment slows disease progression. Surgery is the only therapeutic intervention.^{13,14} Unlike connective tissue diseases, such as Ehlers–Danlos syndrome, cutis laxa is confined to the skin and does not compromise surgical safety by slowing wound healing or causing vascular fragility.^{3,5}

► **Table 1** summarizes case reports in which surgical treatment was performed.^{3,4,6,7,9,11,15–20} Studies reported improvement of facial skin laxity by face lift.^{4,11,12,15,16} Thomas et al performed additional surgery to excise excess skin from the nasolabial folds. Nahas et al performed an additional surgery for anterior forehead lift within a year of the first surgery.^{11,15} Wong et al reported a second face lift, using the superficial muscular aponeurotic system flap 3 months after the first face-lift surgery.¹² Several studies reported that removal of excess upper eyelid skin improved laxity.^{4,6,10,12,17} Shah-Desai et al improved upper eyelid entropion of a 5-month-old infant by removing excess upper eyelid skin. Tas et al performed a simultaneous surgery for excision of excess upper eyelid skin using the Tripiet flap and an internal strabismus surgery in a 12-year-old girl with congenital cutis laxa and internal strabismus.^{6,10}

Riveros et al and Ben Jemaa et al resected excess auricular region skin, thereby improving skin laxity.^{4,18} Reddy et al excised excess lower eyelid skin and Ben Jemaa et al transplanted autologous fatty tissue into the forehead and nasolabial folds to improve skin laxity.^{3,18} Mitra et al and Gverić et al improved skin laxity by excising excess skin on the lower abdomen and anterior neck, respectively.^{7,19} In all the cases, surgeries went well with no perioperative complications.^{3,4,6,7,9,11,15–20} Although more than one operation was required, especially in face-lift cases, the cosmetic satisfaction was high in almost all cases.^{3,4,6,7,9,11,15–20} Only

Table 1 Summary of cases in which surgery was performed for cutis laxa

Case	Published	Age (y)	Sex	Congenital/ acquired	Surgical site	Surgical method	Study
1.	1972	6	Female	Congenital	Face	Unknown	Beighton ⁹
2.	1981	17	Male	Unknown	Unknown	Unknown	Breitbart et al ²⁰
3.	1993	10	Unknown	Congenital	Face, nasolabial fold	Face: facelift, nasolabial fold: skin excision	Thomas et al ¹¹
4.	1999	23	Female	Congenital	Face	Facelift	Nahas et al ¹¹
5.	1999	0 (5 months)	Male	Congenital	Bilateral eyelids	Skin excision	Shah-Desai et al ¹⁰
6.	2002	29	Male	Unknown	1st: bilateral eyelids 2st: face 3nd: face	1st: skin excision 2nd: facelift 3nd: facelift	Wong et al ¹²
7.	2002	17	Unknown	Unknown	Nasolabial fold, forehead, bilateral ear lobes	Nasolabial fold, forehead: fat grafting Bilateral ear lobes: reduction	Ben Jemaa et al ¹⁸
8.	2004	27	Female	Acquired	Bilateral earlobes, face, bilateral eyelids	Bilateral ear lobes: reduction Face: rhytidectomy Bilateral eyelids: blepharoplasty	Riveros et al ⁵
9.	2007	20	Female	Unknown	Bilateral upper eyelids	Blepharoplasty	Ozsoy et al ¹⁷
10.	2008	22	Male	Acquired	Face	Facelift	De Almeida et al ¹⁶
11.	2010	30	Female	Acquired	Abdomen	Skin excision	Gverić et al ¹⁹
12.	2013	12	Female	Congenital	Bilateral upper eyelids	Skin excision (with oculoplastic for strabismus)	Tas et al ⁷
13.	2013	14	Female	Acquired	Front neck	Skin excision	Mitra et al ⁸
14.	2019	26	Male	Acquired	Bilateral lower eyelids	Skin excision	Reddy et al ³

the study by Nahas et al included long-term follow-up and discussed a 10-year postoperative course. Other studies terminated follow-up several years after surgery.¹⁵ Since cutis laxa is a progressive disease, we believe that long-term follow-up after surgery is essential.

Although face-lift surgery would have been effective in improving the appearance of our patient with acquired cutis laxa limited to the face and neck, we performed bilateral upper eyelid and earlobe plasty since she did not want to undergo invasive face-lift surgery. Significant skin drooping may cause stress to the patient because of its appearance. Surgical removal of flaccid skin to improve a patient's appearance can alleviate the psychological burden; however, regular surgical treatment is expected since symptoms continue to progress after surgery. Repeated surgery increases the risk of complications, such as skin necrosis, hematoma formation, and damage to important functional tissues such as the facial nerve.

In this case, the patient did not request additional surgical treatment for progressive symptoms 15 months postsurgery. However, previous upper arm and abdominal skin biopsies showed tearing of elastic fibers, suggesting that skin laxity symptoms could spread over the body in the future. Therefore, we believed that it was necessary to propose surgical treatment after consultation with the patient. It is safe to perform surgery for this disease. We believe that plastic surgery aimed at improving the appearance reduces the patient's mental burden and contributes to an improved quality of life.

Author Contributions

All persons who meet authorship criteria are listed as authors, and all authors certify that they have participated sufficiently in the work to take public responsibility for the content, including participation in the concept, design, analysis, writing, or revision of the manuscript.

Furthermore, each author certifies that this material or similar material has not been and will not be submitted to or published in any other publication before its appearance in the *Archives of Plastic Surgery*.

Patient Consent

Consent for publication was obtained from the patient.

Conflict of Interest

None declared.

Acknowledgment

We would like to thank Editage (www.editage.com) for English language editing.

References

- Morava E, Guillard M, Lefeber DJ, Wevers RA. Autosomal recessive cutis laxa syndrome revisited. *Eur J Hum Genet* 2009;17(09):1099–1110
- Beyens A, Boel A, Symoens S, Callewaert B. Cutis laxa: a comprehensive overview of clinical characteristics and pathophysiology. *Clin Genet* 2021;99(01):53–66
- Reddy GP, Mishra B, Upadhyaya DN. Acquired localized cutis laxa: a case report and the role of plastic surgery. *Indian J Dermatol* 2019;64(01):55–58
- Riveros CJP, Gavilán MFB, França LFS, Sotto MN, Takahashi MD. Acquired localized cutis laxa confined to the face: case report and review of the literature. *Int J Dermatol* 2004;43(12):931–935
- Gara S, Riley CA, Litaïem N. Cutis laxa. In: G, Abai B, Abu-Ghosh A, et al. *StatPearls* [Internet]. Treasure Island, FL.: StatPearls Publishing;; 2021
- Tas A, Gundogan FC, Kocaturk T, Altun S, Bayram Y. Oculoplastic approach to congenital cutis laxa syndrome. *Aesthetic Plast Surg* 2013;37(02):417–420
- Mitra S, Agarwal AA, Das JK, Gangopadhyay A. Cutis laxa: a report of two interesting cases. *Indian J Dermatol* 2013;58(04):328
- Mehta B, Amladi S. Acquired localized cutis laxa of the face: a rare presentation. *Pediatr Dermatol* 2011;28(04):421–423
- Beighton P. The dominant and recessive forms of cutis laxa. *J Med Genet* 1972;9(02):216–221
- Shah-Desai SD, Collins AL, Tyers AG. Surgical correction of entropion and excess upper eyelid skin in congenital cutis laxa: a case report. *Orbit* 1999;18(01):53–58
- Thomas WO, Moses MH, Craver RD, Galen WK. Congenital cutis laxa: a case report and review of loose skin syndromes. *Ann Plast Surg* 1993;30(03):252–256
- Wong MC, Georgeu GA, Sassoon EM, O'Neill TJ. A case report of cutis laxa in one of identical twins. *Aesthetic Plast Surg* 2002;26(06):486–489
- Strohecker B. Cutis laxa: etiology, pathophysiology, characteristics, and management. *Plast Surg Nurs* 1995;15(04):201–203
- Wilsch L, Schmid G, Haneke E. Late-onset cutis laxa (generalized elastolysis) [in German]. *Dtsch Med Wochenschr* 1977;102(41):1451–1454
- Nahas FX, Sterman S, Gemperli R, Ferreira MC. The role of plastic surgery in congenital cutis laxa: a 10-year follow-up. *Plast Reconstr Surg* 1999;104(04):1174–1178
- de Almeida HL Jr, Wolter M, de Farias MV, de Castro LA. Elastic tissue damage in cephalic acquired cutis laxa. *J Cutan Pathol* 2008;35(01):58–61
- Ozsoy Z, Gozu A, Dayicioglu D, Mete O, Buyukbabani N. Localized cutis laxa and blepharoplasty. *Dermatol Surg* 2007;33(12):1510–1512
- Ben Jemaa H, Chevrier S, Georgieff N, Pailheret JP, Watier E. Post-inflammatory cutis laxa. A case report [in French]. *Ann Chir Plast Esthet* 2002;47(06):647–650
- Gverić T, Barić M, Bulat V, et al. Clinical presentation of a patient with localized acquired cutis laxa of abdomen: a case report. *Dermatol Res Pract* 2010;2010:402093
- Breitbart E, Mensing H, Meigel W. Surgical treatment of skin changes in cutis laxa (author's transl) [in German]. *Z Hautkr* 1981;56(02):90–97