



Cranioplasty Using Three-Dimensional-Printed Polycaprolactone Implant and Free Latissimus Dorsi Musculocutaneous Flap in a Patient with Repeated Wound Problem following Titanium Cranioplasty

Hee Tae Koo, MD¹ Jeongseok Oh, MD, PhD¹ Chan Yeong Heo, MD, PhD¹

¹Department of Plastic and Reconstructive Surgery, Seoul National University Bundang Hospital, Seoul National University College of Medicine, Seongnam, Korea

Arch Plast Surg 2022;49:740–744.

Address for correspondence Chan Y. Heo, MD, PhD, Department of Plastic and Reconstructive Surgery, Seoul National University Bundang Hospital, Seoul National University College of Medicine, 82 Gumi-ro 173 beon-gil, Bundang-gu, Seongnam 13620, Korea (e-mail: lionheo@snu.ac.kr).

Abstract

Titanium mesh is an alloplastic material widely used for the reconstruction of moderate-to-large skull defects. Repeated wound problems or infection following these reconstructions inevitably lead to the replacement of the cranioplasty material. Among the various alloplastic materials, polycaprolactone implants are usually used for the coverage of small defects such as burr holes.¹ Herein, we present a case of a large cranial defect successfully reconstructed with three-dimensional-printed polycaprolactone implant and a free latissimus dorsi musculocutaneous flap. Until 1-year follow-up, the patient showed a favorable esthetic outcome with no complications or wound relapse.

Keywords

- ▶ polycaprolactone
- ▶ free tissue flaps
- ▶ skull

Introduction

While cranioplasty following craniectomy is a common neurosurgical procedure, there is no consensus on the choice of materials for cranioplasty due to the lack of data regarding long-term outcomes. The first-line treatment for patients who visit the clinic with wound dehiscence after previous cranioplasty is debridement of the devitalized wound margin, coverage of the previous implant with a blood-rich periosteal flap, and reelevation of the local flap minimizing its tension.

However, the results are not always promising, especially in patients with a history of infection or radiation. Therefore, proper selection of cranioplasty materials and replacement of damaged soft tissue with free flaps with good blood supply

and strong resistance to infection are essential for the reconstruction of the relapsing wound, and this can be challenging.

In this report, we describe a patient who underwent scalp and skull reconstruction with a three-dimensional (3D)-printed polycaprolactone (PCL) implant followed by free latissimus dorsi (LD) musculocutaneous flap coverage for repeated scalp wound problems that did not resolve after titanium cranioplasty and serial revision operations.

Case

Informed consent was obtained from the patient for using the medical photographs, writing, and publication of this

received
September 30, 2021
accepted after revision
February 17, 2022

DOI <https://doi.org/10.1055/s-0042-1748656>.
eISSN 2234-6171.

© 2022. The Korean Society of Plastic and Reconstructive Surgeons. All rights reserved.

This is an open access article published by Thieme under the terms of the Creative Commons Attribution-NonDerivative-NonCommercial-License, permitting copying and reproduction so long as the original work is given appropriate credit. Contents may not be used for commercial purposes, or adapted, remixed, transformed or built upon. (<https://creativecommons.org/licenses/by-nc-nd/4.0/>)

Thieme Medical Publishers, Inc., 333 Seventh Avenue, 18th Floor, New York, NY 10001, USA

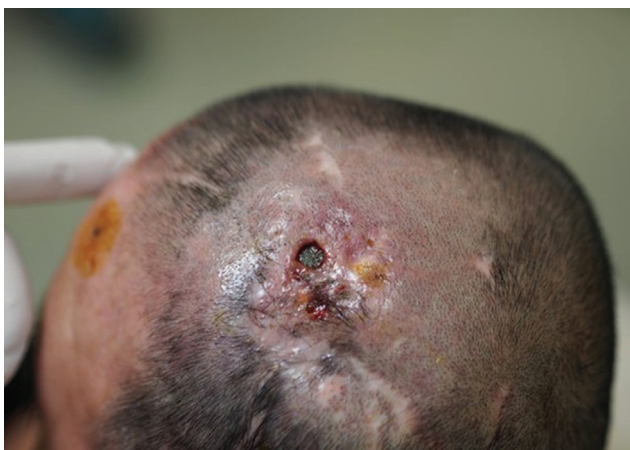

Fig. 1 A 3 mm × 5 mm sized scalp defect with exposure of titanium mesh. Surrounding scalp shows chronic inflammation and atrophy.

case report. A 73-year-old man visited our center following titanium mesh exposure (→**Fig. 1**).

Four years earlier, the patient underwent an intra-arterial thrombectomy for a middle cerebral artery (MCA) territory infarct. Decompressive craniectomy was performed on the day after thrombectomy, and a superficial temporal artery–MCA bypass—was performed. Wound dehiscence occurred 1 month postoperatively, and wound debridement with an autologous bone graft was performed. The wound was again disrupted with methicillin-resistant *Staphylococcus aureus* (MRSA) growth after 3 weeks, and the patient underwent

debridement and coverage of the scalp wound with a rotation cutaneous flap and full thickness skin graft.

Despite serial debridement and closure with a local flap, wound dehiscence recurred within intervals of a few months. The patient visited the Department of Neurosurgery at our hospital 2 years after the first surgery with severe infection, scalp defect, bone flap infection, and epidural and subdural abscesses. Removal of the previous bone flap and osteomyelitic bone with surrounding infected soft tissue was performed, followed by duroplasty. MRSA growth was observed, and the patient was discharged 3 months after the surgery with no surgical complications during which he was administered intravenous vancomycin and meropenem for 7 weeks.

Seven months later, the patient underwent titanium cranioplasty, and the wound was stable without signs of infection. However, the wound was disrupted several times at intervals of a few months. The defect was of pinhole sized, and wound culture confirmed no signs of infection. Despite repeated conservative management with intravenous antibiotic administration and debridement with wound closure, a 3 mm × 5 mm wound dehiscence with titanium mesh plate exposure was observed. There was no sign of infection, and the C-reactive protein level was within the normal range. Removal of the previous plate with replacement of the PCL implant was planned in the neurosurgery department. Pre-operative computed tomography (CT) was performed, and there was no focal sign of abscess or overt infections. Porous PCL mesh (Osteomesh, Osteopore International, Singapore) was customized according to this CT scan (→**Fig. 2**).

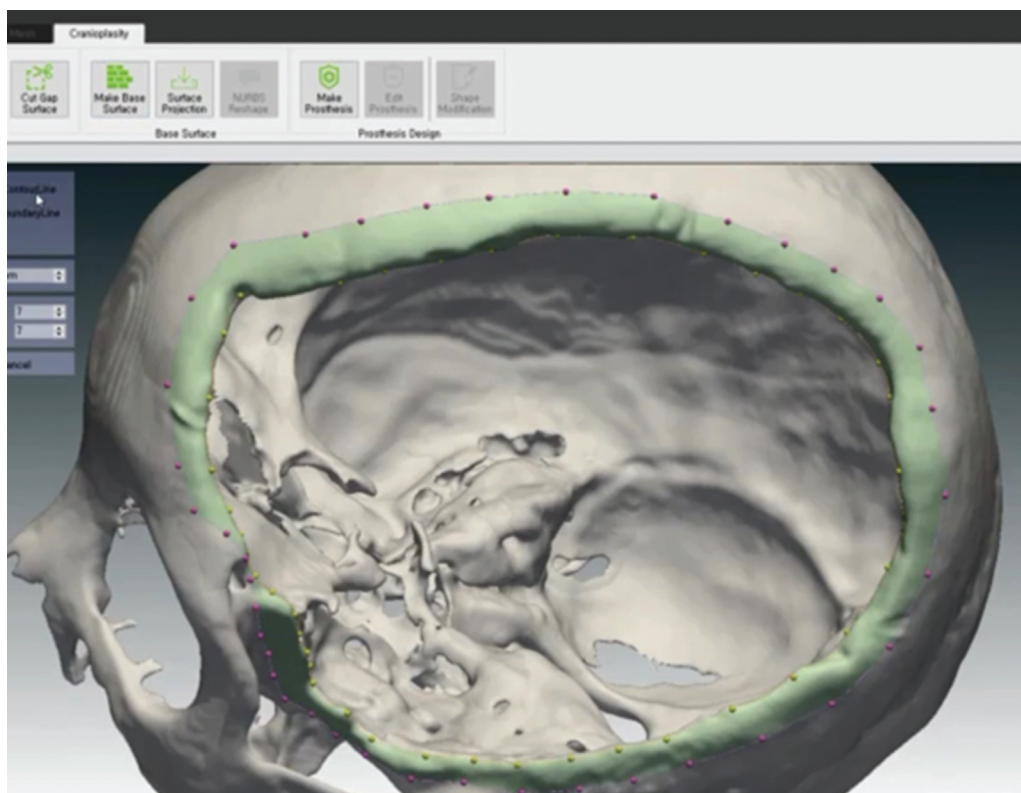


Fig. 2 Rendering of polycaprolactone (PCL) implant with computer-aided design/computer-aided manufacture (CAD/CAM).

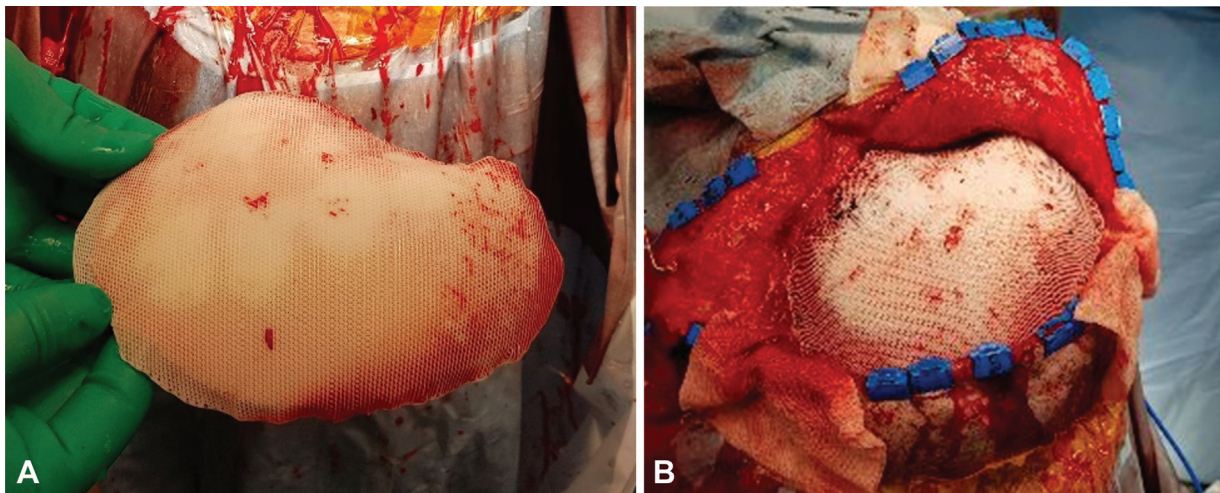


Fig. 3 Intraoperative image of 3D-customized polycaprolactone implant (A) outer surface, (B) precise fitting of implant to defect site. 3D, three-dimensional.

Removal of titanium mesh and bone cement was performed by neurosurgeons with fixation of the prepared Osteomesh using a mini screw. The prefabricated implant showed excellent bony contact when implanted in the defect (►Fig. 3). Radical excision of unhealthy scalp tissue with a previous scar was performed by plastic surgeons, and a free LD musculocutaneous flap was harvested from the left back.

The left superficial temporal artery and vein were prepared as recipient vessels, and end-to-side anastomosis with the thoracodorsal artery and end-to-end anastomosis with the thoracodorsal vein were performed.

The patient was discharged on postoperative day 25 with a viable flap and no other complications. At the 1-year follow-up, there were no wound-related complications, and favorable cosmetic outcomes were achieved with restoration of the natural bony contour and minimal flap bulkiness and sagging (►Fig. 4). CT at 2 months and 1 year postoperatively showed some degree of osseointegration around the implant (►Fig. 5).

Discussion

Recent advancements in computer-aided design/computer-aided manufacturing (CAD/CAM) allow various cranioplasty materials, including titanium, to fit each patient's skull defect precisely.² Although titanium cranioplasty has excellent short-term outcomes, a previous study reported that the retention rate for titanium mesh plates continued to decrease, reaching 46.8% at 4 years of follow-up, while non-titanium alloplastic cranioplasties remained stable (76.0%).³ Risk factors for titanium mesh exposure, such as preoperative radiotherapy, free flap coverage, and soft tissue atrophy, have been suggested.⁴

Alloplastic biodegradable materials are introduced as alternatives, supported by their biodegradable nature and evidence of successful osteoconduction. Polycaprolactone is an Food and Drug Administration (FDA)-approved polymer and is rapidly gaining popularity with its indication for small-to-moderate-sized defects such as burr-hole or orbital

wall fractures.¹ As a burr-hole cover, PCL showed 60% stiffness when compared with normal bone *in vivo* and showed successful integration into the surrounding bony tissue after 2 years.¹

With regard to large calvarial defect, reconstruction with PCL is rare, while cranioplasty, utilizing other alloplastic materials, such as polymethylmethacrylate (PMMA), is well described in the literature. One case using custom-made Osteomesh of PCL with a titanium scaffold embedded with bone morphogenetic protein (BMP) for a large calvarial defect after failure of previous cranioplasty using PMMA implant was reported, showing new bone formation over the Osteomesh at 18 months of follow-up.⁵ However, we do not know whether the sustained rigidity in this case was achieved by the rigidity of the PCL implant itself or by reinforcement of the titanium scaffold.

In patients with plate exposure after titanium mesh cranioplasty, restriction of an unabsorbable foreign body is essential, and free flap can release the tension and prevent infection through improved soft tissue insufficiency and blood flow.⁶ The patient in our case presented with a small scalp defect. However, previous efforts to maintain titanium mesh plates had failed, and the surrounding scalp was atrophied and unhealthy. Local recruitment of vascular-compromised tissue was not possible, and titanium mesh plate removal was essential. In this situation, we decided to perform PCL cranioplasty with immediate reconstruction using a free LD musculocutaneous flap.

To the best of our knowledge, this is the first case utilizing 3D-customized PCL implants and a free LD musculocutaneous flap to treat intractable scalp wounds. Despite previous studies reporting successful integration of alloplastic materials with free flap coverage of composite cranial defects, PCL could be a better option for an alloplastic material in combination with a free flap due to its easy availability, cost efficacy, and suitability for modification.⁷⁻⁹

In our case, application of PCL to free LD flap was convenient and effective for following reasons. First, PCL implant is well anchored to surrounding bone stump which prevented

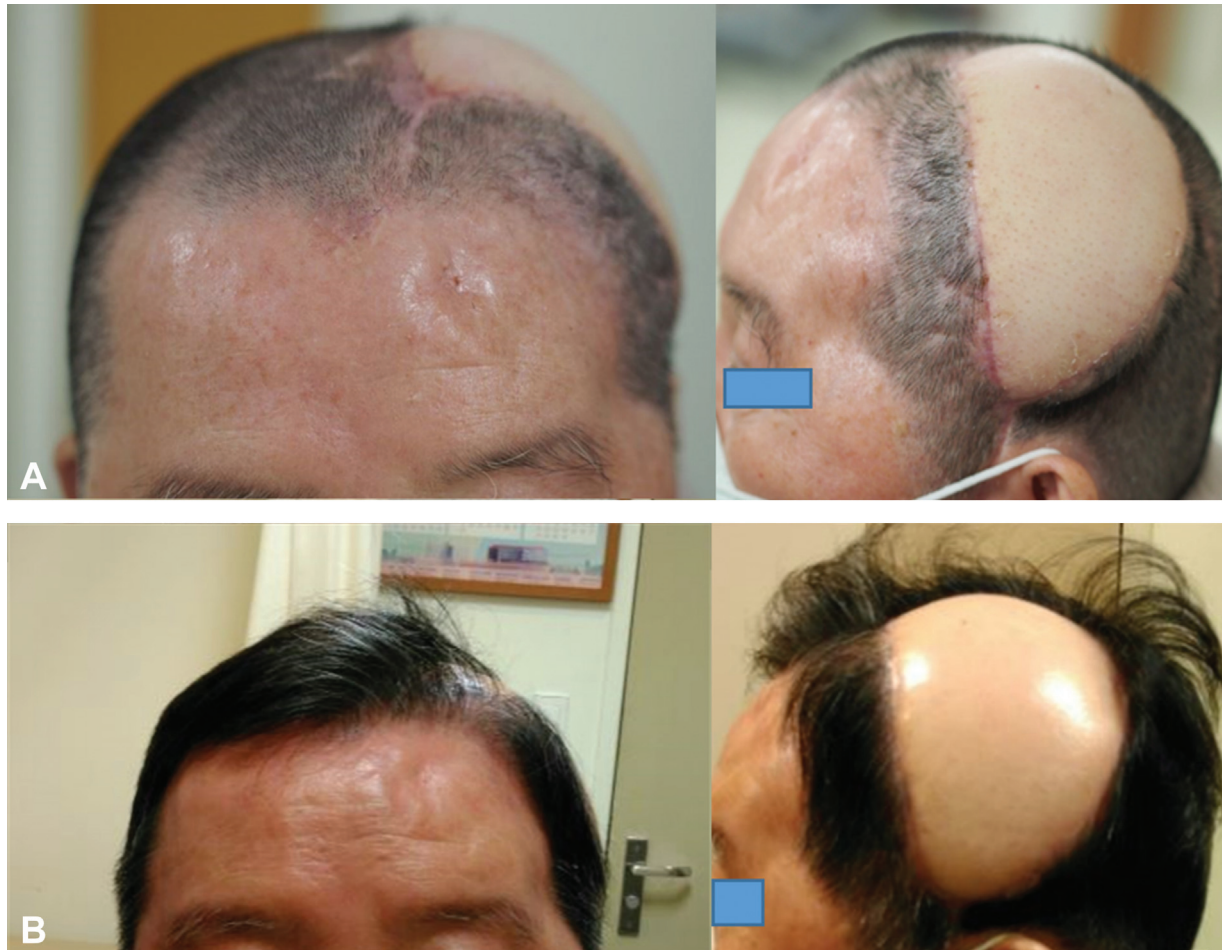

Fig. 4 Medical photo taken at outpatient clinic. (A) 2-month visit and (B) 1-year visit. Restoration of normal lateral head contour is seen with minimal flap sagging.

malposition of the implant. Follow-up CT at 1 year showed successful osseointegration which was possible due to excellent fit of the implant to the defect with almost no dead space. From previous study, application of PCL membrane

showed bone neoformation, not only at the bone stump but also at the center of the defect in vivo.¹⁰ This osseointegration is well achieved in unmodified PCL scaffold even when compared with nanostructured porous PCL scaffold.¹¹

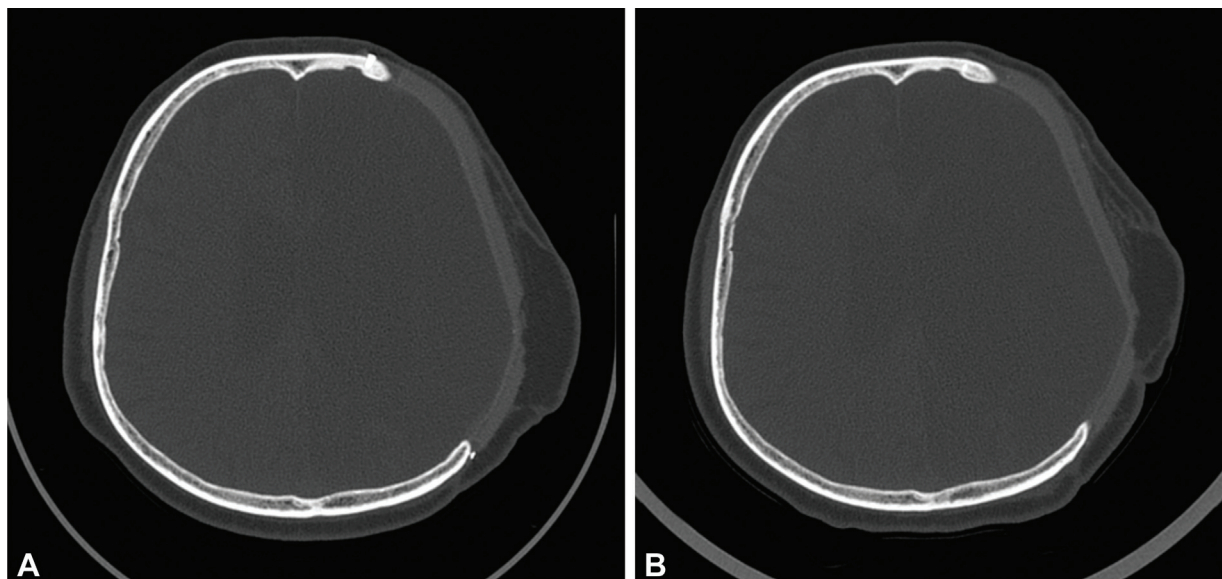


Fig. 5 Postoperative computed tomography at (A) 2 months and (B) 1 year. Successful osseointegration achieved.

Second, the attachment of the LD muscle to the PCL implant seemed sufficient, resulting in a favorable soft tissue contour with minimal flap sagging. We believe that this is achieved through the porous structure and rough surface compared with the titanium mesh plate. This is supported by a previous study including an in vivo analysis of PCL matrix placed subcutaneously above the LD muscle in a rat model, showing favorable biocompatibility at the histological level.¹²

Third, PCL is expected to be osteoinductive through further utilization of biological additives such as BMP2 or bone marrow-derived mesenchymal stem cells.¹³ In-vivo experiments showed that BMP2-adsorbed PCL scaffold showed larger regenerated bone volume regeneration,¹⁴ and there is a case report of successful calvarial reconstruction with stem cell-impregnated PCL Osteomesh in combination with a local flap.⁵ Osteogenic inorganic material, such as hydroxyapatite, could be used as an additive; hydroxyapatite/polycaprolactone nanoparticles showed superior osteogenicity compared with hydroxyapatite nanoparticles.¹⁵ The application of these innovative ideas in our case could improve the clinical outcomes of the neuroplastic surgery.

Ethical Approval

Informed consent was obtained from the patient for the use of medical photographs, writing, and publication of this case report.

Author Contributions

Conceptualization: CY Heo. Data curation: J Oh. Writing - original draft: HT Koo. Writing - review & editing: HT Koo, J Oh, CY Heo. All authors read and approved the final manuscript.

Patient Consent

Informed consent was obtained from all individual participants included in the study.

Conflict of Interest

None declared.

References

- 1 Low SW, Ng YJ, Yeo TT, Chou N. Use of osteoplug polycaprolactone implants as novel burr-hole covers. *Singapore Med J* 2009;50(08):777-780
- 2 Cho HR, Roh TS, Shim KW, Kim YO, Lew DH, Yun IS. Skull reconstruction with custom made three-dimensional titanium implant. *Arch Craniofac Surg* 2015;16(01):11-16
- 3 Kwiecien GJ, Rueda S, Couto RA, et al. Long-term outcomes of cranioplasty: titanium mesh is not a long-term solution in high-risk patients. *Ann Plast Surg* 2018;81(04):416-422
- 4 Maqbool T, Binhammer A, Binhammer P, Antonyshyn OM. Risk factors for titanium mesh implant exposure following cranioplasty. *J Craniofac Surg* 2018;29(05):1181-1186
- 5 Yogishwarappa CN, Srinivasan S, Teoh SH, et al. Customized osteomesh cranioplasty. *Journal of Advanced Plastic Surgery Research* 2016;2:25-32
- 6 Dong L, Dong Y, Liu C, et al. Latissimus dorsi-myo-cutaneous flap in the repair of titanium mesh exposure and scalp defect after cranioplasty. *J Craniofac Surg* 2020;31(02):351-354
- 7 Morice A, Kolb F, Picard A, Kadlub N, Puget S. Reconstruction of a large calvarial traumatic defect using a custom-made porous hydroxyapatite implant covered by a free latissimus dorsi muscle flap in an 11-year-old patient. *J Neurosurg Pediatr* 2017;19(01):51-55
- 8 Scaglioni MF, Giunta G. Reconstruction of cranioplasty using the thoracodorsal artery perforator (TDAP) flap: a case series. *Microsurgery* 2019;39(03):207-214
- 9 Dwivedi R, Kumar S, Pandey R, et al. Polycaprolactone as biomaterial for bone scaffolds: review of literature. *J Oral Biol Craniofac Res* 2020;10(01):381-388
- 10 Farnezi Bassi AP, Ferreira Bizelli V, Mello Francatti T, et al. Bone regeneration assessment of polycaprolactone membrane on critical-size defects in rat calvaria. *Membranes (Basel)* 2021;11(02):12
- 11 Jensen J, Rölfing JHD, Le DQ, et al. Surface-modified functionalized polycaprolactone scaffolds for bone repair: in vitro and in vivo experiments. *J Biomed Mater Res A* 2014;102(09):2993-3003
- 12 Gredes T, Schönitz S, Gedrange T, Stepien L, Kozak K, Kunert-Keil C. In vivo analysis of covering materials composed of biodegradable polymers enriched with flax fibers. *Biomater Res* 2017;21(01):8
- 13 Rindone AN, Nyberg E, Grayson WL. 3D-printing composite polycaprolactone-decellularized bone matrix scaffolds for bone tissue engineering applications. In: *Decellularized Scaffolds and Organogenesis*. New York, NY: Humana Press; 2017:209-226
- 14 Patel JJ. Single and dual growth factor delivery from poly-ε-caprolactone scaffolds for pre-fabricated bone flap engineering [dissertation]. Ann Arbor, Michigan: University of Michigan; 2015
- 15 El-Habashy SE, Eltaher HM, Gaballah A, Zaki EI, Mehanna RA, El-Kamel AH. Hybrid bioactive hydroxyapatite/polycaprolactone nanoparticles for enhanced osteogenesis. *Mater Sci Eng C* 2021; 119:111599