



Mucormycosis Management in COVID-19 Era: Is Immediate Surgical Debridement and Reconstruction the Answer?

Samarth Gupta, MBBS, MS, MCh¹ Pradeep Goil, MBBS, MS, MCh¹ Arbab Mohammad³
Joseph M. Escandón, MD⁴

¹ Department of Plastic, Reconstructive and Burns Surgery, Sawai Man Singh Hospital, Jaipur, Rajasthan, India

² St Andrew's Centre of Plastic Surgery and Burns, Broomfield Hospital, Chelmsford, Essex, United Kingdom

³ Aarupadai Veedu Medical College and Hospital, Puducherry, India

⁴ Division of Plastic and Reconstructive Surgery, Strong Memorial Hospital, University of Rochester Medical Center, Rochester, New York

Address for correspondence Samarth Gupta, MBBS, MS, MCh, Department of Plastic, Reconstructive and Burns Surgery, Sawai Man Singh Hospital, Jaipur 302001, Rajasthan, India (e-mail: guptasamarth@hotmail.com).

Arch Plast Surg 2022;49:397–404.

Abstract

Background Excessive use of corticosteroids therapy along with gross immunocompromised conditions in the novel coronavirus disease 2019 (COVID-19) pandemic has raised the risks of contracting opportunistic fungal infections. Here, we describe our experience with the implementation of a surgical protocol to treat and reconstruct rhino-orbital-cerebral mucormycosis.

Methods A retrospective review of our prospectively maintained database was conducted on consecutive patients diagnosed with mucormycosis undergoing immediate reconstruction utilizing our “Mucormycosis Management Protocol.” All patients included in this study underwent reconstruction after recovering from COVID-19. Wide local excision was performed in all cases removing all suspected and edematous tissue. Reconstruction was done primarily after clear margins were achieved on clinical assessment under a cover of injectable liposomal amphotericin B.

Results Fourteen patients were included. The average age was 43.6 years and follow-up was 24.3 days. Thirteen patients had been admitted for inpatient care of COVID-19. Steroid therapy was implemented for 2 weeks in 11 patients and for 3 weeks in 3 patients. Eight patients (57.1%) had a maxillectomy and mucosal lining resection with/without skin excision, and six patients (42.8%) underwent maxillectomy and wide tissue excision (maxillectomy and partial zygomatic resection, orbital exenteration, orbital floor resection, nose debridement, or skull base debridement). Anterolateral thigh (ALT) flaps were used to cover defects in all patients. All flaps survived. No major or minor complications occurred. No recurrence of mucormycosis was noted.

Conclusion The approach presented in this study indicates that immediate reconstruction is safe and reliable in cases when appropriate tissue resection is accomplished. Further studies are required to verify the external validity of these findings.

Keywords

- ▶ COVID-19
- ▶ free tissue flaps
- ▶ mucormycosis
- ▶ antifungal agents
- ▶ reconstructive surgical procedures

DOI <https://doi.org/10.1055/s-0042-1748654>.
ISSN 2234-6163.

© 2022. The Korean Society of Plastic and Reconstructive Surgeons. All rights reserved.

This is an open access article published by Thieme under the terms of the Creative Commons Attribution-NonDerivative-NonCommercial-License, permitting copying and reproduction so long as the original work is given appropriate credit. Contents may not be used for commercial purposes, or adapted, remixed, transformed or built upon. (<https://creativecommons.org/licenses/by-nc-nd/4.0/>)

Thieme Medical Publishers, Inc., 333 Seventh Avenue, 18th Floor, New York, NY 10001, USA

Excessive use of corticosteroids therapy along with gross immunocompromised conditions in the novel coronavirus disease 2019 (COVID-19) pandemic has increased the risks of contracting opportunistic fungal infections.¹ An epidemiological study from China describes the possibility of an increased incidence of mucormycosis in COVID-19 patients with history of trauma, diabetes mellitus (DM), unregulated glucocorticoid use, hematopoietic malignancies, prolonged neutropenia, allogeneic hematopoietic stem cell transplant, and solid organ transplant.¹ Mucormycosis, a rare angioinvasive fungal infection caused by mucormycetes that notoriously famed for its ability to increase mortality in the absence of prompt management, is largely encountered in immunocompromised patients; although its incidence in immunocompetent individuals is rare, several cases have been reported.²⁻⁶ Results of epidemiological studies have indicated that rhino-orbito-cerebral mucormycosis (ROCM) is the most commonly encountered variant of this invasive fungal disease, closely followed by cutaneous mucormycosis.⁷ Sinusitis, periorbital edema, blindness, proptosis, and eventually cranial invasion are some of the classical features of ROCM.⁸ All types of mucormycosis indiscriminately follow a common pathological disease process, angioinvasion and subsequent thrombosis causing tissue necrosis, preventing migration of leukocytes and antifungal agents; thus, rendering medical management futile in non-immediate presentations or late treatment.⁸ Although employing liposomal amphotericin B as first-line therapy, minimizing immunosuppression, and alleviating the nutritional status have demonstrated to be effective therapies, their value in management can be best attributed as concurrent and not definitive. In this setting, invasive mucormycosis is still largely considered a disease that requires prompt debridement and necrotic tissue resection followed by defect reconstruction.⁹ According to Mignogna et al, low- and middle-income countries have been reported to be mucormycosis front runners; this can be attributed to environmental, socioeconomic, and penurious hygienic conditions.⁷ Additionally, an orphaned health care system leading to underreporting of DM and a mucormycosis delayed diagnosis can also be deemed as justified culprits.⁷ Recent reports support a strong association between COVID-19, corticosteroid therapy, and mucormycosis, although preexisting immunosuppressive conditions like DM should be considered as strong confounders.¹⁰ The current article describes our evidence and practice-based treatment protocol to treat COVID-19-related mucormycosis. We have described our immediate surgical debridement-reconstruction approach to optimize outcomes, as well as the elaborated reconstructive armamentarium employed by our team to facilitate adequate defect coverage. Additionally, this article also highlights our medical therapy protocol that is aimed at early reduction of fungal load and improvement of immunity.

Methods

Study Design

We conducted a retrospective review of patients of a prospectively maintained database at our institution utilizing our "Mucormycosis Management Protocol" to treat patients

presenting to the mucormycosis unit. The study period ranged from April 2021 to June 2021. All study activities were approved by the Hospital Institutional Review Board. The manuscript was prepared in accordance with the STROBE guidelines.

Study Population

Out of a total of 554 patients diagnosed with mucormycosis, 14 were included in this study. The inclusion criteria were as follows: patients undergoing maxillary, cutaneous, and mucosal lining resection requiring free flap coverage. Eligible patients were also aged 18 years or older, patients with a history of COVID-19 with subsequent negative results, and patients referred to the special mucormycosis unit with complaints of foul-smelling rhinorrhea with or without orbital cellulitis. Patients not requiring reconstruction or denying immediate reconstruction and patients in whom an obturator was used after maxillectomy were excluded from the study. Patients refusing to give consent for this study were also excluded. Fifteen patients were initially included. However, one patient was managed with a local flap as debridement resulted solely in a small cutaneous defect with no mucosal excision, therefore the patient was excluded (→ **Supplementary Appendix A**, available in the online version) which exhibits the patient managed with local reconstructive options). Ultimately, 14 patients qualified in accordance with the inclusion criteria.

Clinical Variables

We collected the following variables: age, gender, day of a positive COVID-19 report, day of a negative COVID-19 report, day of first symptom for mucormycosis after testing positive for COVID-19, day of surgery, COVID-19 pharmacological treatment protocol, total dosage of liposomal amphotericin B, COVID-19 hospitalization (categorical: yes/no), COVID-19 oxygen therapy (categorical: yes/no), intensive care unit (ICU stay; categorical: yes/no), significant past medical history, diagnostic report (KOH (Potassium hydroxide) test/D-dimer/C-reactive protein [CRP]), start date of mucormycosis pharmacological therapy, duration of mucormycosis pharmacological therapy (days), surgical debridement details (date/resection margins/defect dimension), reconstructive procedure details (flap used, flap dimensions, total operative time, and flap outcome), postoperative outcomes, and recurrence on final follow-up.

Standard of Procedure for COVID-19-Related Mucormycosis Management

Treatment algorithm:

1. Induction therapy: liposomal amphotericin B (5 mg/kg/day) was started in patients having a confirmed diagnosis with a tissue specimen demonstrating fungal invasion or if examination and medical history raised the index of suspicion for mucormycosis in patients not having a confirmed diagnostic report suggestive of mucormycosis. Liposomal amphotericin B was used in all patients instead of injection amphotericin B, owing to the minimal renal toxicity of the former.

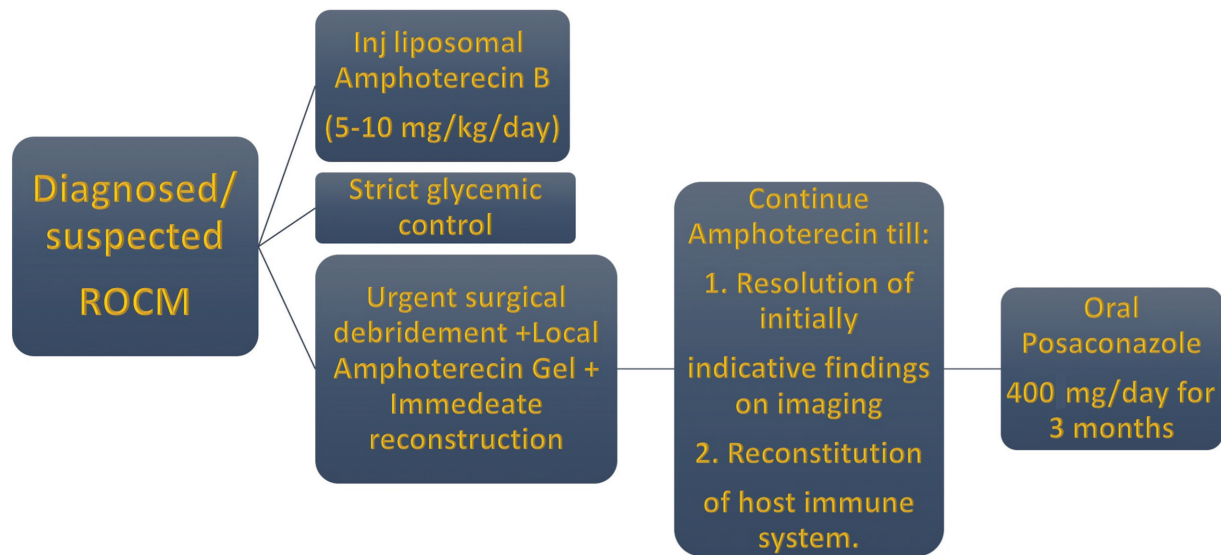


Fig. 1 Treatment algorithm. ROCM, rhino-orbito-cerebral mucormycosis.

Duration: induction therapy was continued for 14 to 21 days depending on the severity and until total clinical resolution and radiological stabilization were observed. After this period, if the patients were clinically stable, they were started on oral posaconazole (400 mg twice a day).

2. Step down or salvage therapy: posaconazole, 200 mg, four times per day or alternatively, posaconazole delayed-release tablets (300 mg every 12 hours on the first day, then 300 mg once daily) taken with food (► **Fig. 1**).

Surgical Procedure

Any suspicion or confirmed diagnosis of mucormycosis was taken to the operating room on an urgent basis for radical debridement. All the patients included in this study, who underwent reconstruction, were COVID-19 recovered based on the real time-polymerase chain reaction (PCR) test. Debridement was performed by the ENT (ear-nose-throat) surgeon utilizing the endoscopic approach to clear the sinuses and an operating microscope to visualize the margins. Wide local excision was performed in all cases removing all suspected and edematous tissue followed by washing with 0.1% amphotericin gel. Margins of 1.5 cm were taken beyond the point of induration and the specimens were sent for histopathology. Reconstruction was done in the immediate setting after clear margins were achieved on clinical assessment, as well as examination under the microscope under the cover of injectable liposomal amphotericin B. Further local application of amphotericin B was applied to ensure prevention of residual fungus. Free ALT flap was utilized for reconstructing the defects in all the patients with a special emphasis on restoring form and function while leaving the aesthetic improvement for a later time after the patient has recovered. Vastus lateralis was harvested when needed along with the skin flap to fill the maxillary cavity. As a donor vessel, the facial artery on the ipsilateral site was used for anastomosis just at the upper border of the mandible whenever feasible. This not only reduced the required

pedicle length of the flap but also avoided an unnecessary neck incision. All the donor sites were closed primarily without the need for skin grafting.

Results

Eight male and six female patients were included. The average age was 43.6 ± 8 years. Eleven patients (78.6%) had past medical history of DM and three (21.4%) of hypertension (HTN). The mean follow up was 24.3 ± 5.97 days. Thirteen (92.9%) were admitted for inpatient care of COVID-19, and 10 (71.4%) required admission to the ICU. Eleven (78.6%) required supplementary oxygen therapy. Dexamethasone 6 mg was administered twice a day at least for 2 (78.6%) weeks in 11 patients and for 3 weeks in 3 patients (21.4%; ► **Table 1**). The patients had a negative COVID-19 report at 18.4 ± 2.21 days after an initial positive COVID-19 test. The patients presented symptoms at 18.4 ± 2.21 days after a positive COVID-19 report. Surgical debridement and reconstruction were performed at 20.6 ± 2.34 days after a first positive COVID-19 report. With the implementation of our protocol, the delay in surgery after onset of symptoms was 1.14 ± 0.36 days (► **Table 1**).

Last D-dimer of patients was 0.473 ± 0.164 nm/L and the CPR was 30.6 ± 28.6 mg/L. The number of liposomal-amphotericin doses before surgery (vials) were 4.79 ± 1.42 . Eight patients (57.1%) had a maxillectomy, mucosal lining resection with/without skin excision (► **Table 2**). Six patients (42.8%) underwent maxillectomy and wide tissue excision as follows: maxillectomy + partial zygomatic resection ($n=3$, 21.4%), maxillectomy + orbital exenteration ($n=1$, 7.1%), maxillectomy + partial zygoma + orbital floor resection ($n=1$, 7.1%), and maxillectomy + partial zygoma + orbital exenteration + nose debridement + skull base debridement ($n=1$, 7.1%).

Patients with an extended maxillectomy (maxillectomy + mucosal lining ± zygoma ± orbital exenteration ± cheek skin ± lip ± nose ± skull base) were prone to have DM or

Table 1 Demographic and clinical information of patients

Demographic	Mean \pm SD/n (%)
Age (y)	43.6 \pm 8
Medical history	
• Hypertension	3 (21.4)
• Diabetes mellitus	11 (78.6)
COVID-19 hospitalization	
• Yes	13 (92.9)
• No	1 (7.1)
Oxygen therapy	
• Yes	11 (78.6)
• No	3 (21.4)
ICU Stay before symptoms	
• Yes	10 (71.4)
• No	4 (28.6)
Steroid duration	
• 2 Weeks	11 (78.6)
• 3 Weeks	3 (21.4)
Day of COVID-19 negative report	18.4 \pm 2.21
Day of first Symptoms	19.4 \pm 2.41
Day of Surgery after first COVID-19 report	20.6 \pm 2.34
Delay in surgery after onset of symptoms	1.14 \pm 0.36

Abbreviations: COVID-19, novel coronavirus disease 2019; ICU, intensive care unit; SD, standard deviation.

DM \pm HTN in comparison to patients who had a maxillectomy (odds ratio [OR] = 8.27, 95% confidence interval [CI]: 0.34–198; $p = 0.209$). Patients with an extended maxillectomy had higher CRPs (38.3 \pm 32.7) in comparison to patients who had a maxillectomy (24.8 \pm 25.7, $p = 0.06$).

ALT flaps were used to cover defects in all patients. The average flap dimension was 229 \pm 55.2 cm² (range: 14 \times 10–26 \times 12 cm²). The average operative time was 303 \pm 22.8 minutes. All flaps survived. No partial flap necrosis, congestion, wound dehiscence, or revisions of the anastomosis was required. All histopathology samples showed negative margins and no recurrence of mucormycosis was noted (\rightarrow Table 2).

Case 1

A 56-year-old female with a known case of DM and HTN presented with black growth over face involving nose, maxilla, zygoma, eye, and all the sinuses. Radical debridement was done by the otorhinolaryngologist clearing the frontal, ethmoidal, and maxillary sinuses. The dura was found to be intact. Orbital exenteration along with maxillectomy was done. Zygoma had to be removed in due to its involvement. The defect was covered with a large free ALT flap measuring 26 cm \times 12 cm folded on itself to form the sulcus and reconstruct the lip. Elective tracheostomy was done to maintain

Table 2 Surgical management of ROCM

Parameter	Mean \pm SD/n (%)
Last D-dimer (μ g/L)	0.473 \pm 0.164
Last CRP (mg/L)	30.6 \pm 28.6
Number of L-amphotericin doses before surgery (vials)	4.79 \pm 1.42
Type of resection	
• Maxillectomy	8 (57.1)
• Maxillectomy + wide tissue resection	6 (42.8)
ALT flap	14 (100)
Total operative time (mins)	303 \pm 22.8
Final follow-up date	24.3 \pm 5.97
Flap dimension (cm ²)	229 \pm 55.2
Successful flap	14 (100)
Recurrence of mucormycosis	0 (0)

Abbreviations: ALT, anterolateral thigh; CRP, C-reactive protein; ROCM, rhino-orbito-cerebral mucormycosis; SD, standard deviation.

the airway. \rightarrow Fig. 2A–E show defect reconstruction by ALT flap.

Case 2

This patient is a 43-year-old male presenting with black growth involving anterior cheek wall, ala, lip, and infra orbital region. After adequate debridement, the defect was reconstructed by a free ALT flap of 18 cm \times 12 cm dimensions. Here, the floor of the orbit was removed resulting in hypophthalmos. This was reconstructed using a tensor fascia lata sling to support the eyeball. Vastus lateralis was used to fill in the maxillary dead space and the skin was deepithelialized judiciously to reconstruct the ala, lip, outer and the inner lining. Postoperatively, the patient was tracheostomized and kept in ICU. No recurrence was found at 1 month follow-up. \rightarrow Fig. 3A–D shows defect reconstruction by ALT flap.

Case 3

This is a case of a young 43-year-old female presenting with foul smelling rhinorrhea and edema over face. Maxillectomy was done; however the floor of the orbit was left intact. Free ALT flap of 18 cm \times 12 cm dimension was done to cover the defect utilizing vastus lateralis to fill in the maxillary dead space. The flap was deepithelialized since the lip was intact to reconstruct the inner lining. The patient was discharged on day 14 with no signs of recurrence at a month's follow-up. \rightarrow Fig. 4A–C shows defect reconstruction by ALT flap. \rightarrow Fig. 5 depicts a case reconstructed using Mustarde flap.

Discussion

Mucormycosis was first coined and described by Paltauf in 1885 who indicated that the causative mucor fungi had an airborne transmission potential.¹¹ Angioinvasive property of

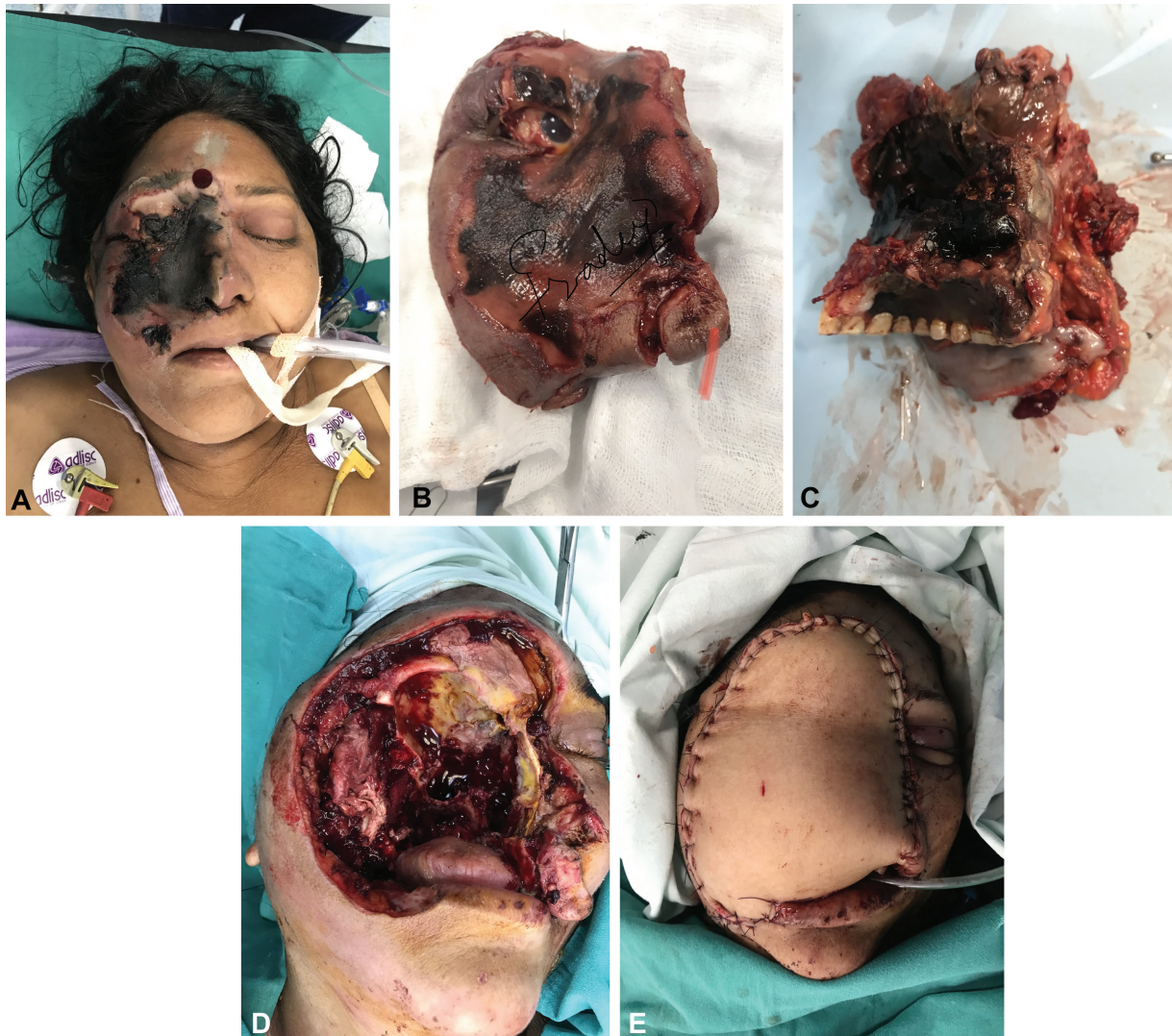

Fig. 2 Case 1: A patient who was operated using free ALT flap. (A) Preoperative picture of invasive ROCM. (B) Anterior aspect of excised segment. (C) Posterior aspect of excised segment. (D) Residual defect created. (E) Flap inset. ALT, anterolateral thigh.

the fungi causing thrombosis and subsequently tissue necrosis is considered the classic defining characteristic of the disease.¹¹ Invasive mucormycosis has been described to have five variants, namely, (1) rhino-orbito-cerebral, (2) cutaneous, (3) pulmonary, (4) gastrointestinal, and (5) disseminated and other uncommon forms that present as osteomyelitis,

endocarditis, and infection involving the renal system.¹¹ Patients with immunocompromising conditions, like DM, organ transplant status, history of hematological malignancy, and uncontrolled corticosteroid usage, have been described to have the highest predilection of being affected by the aforementioned fungal infection.¹² In a recent meta-

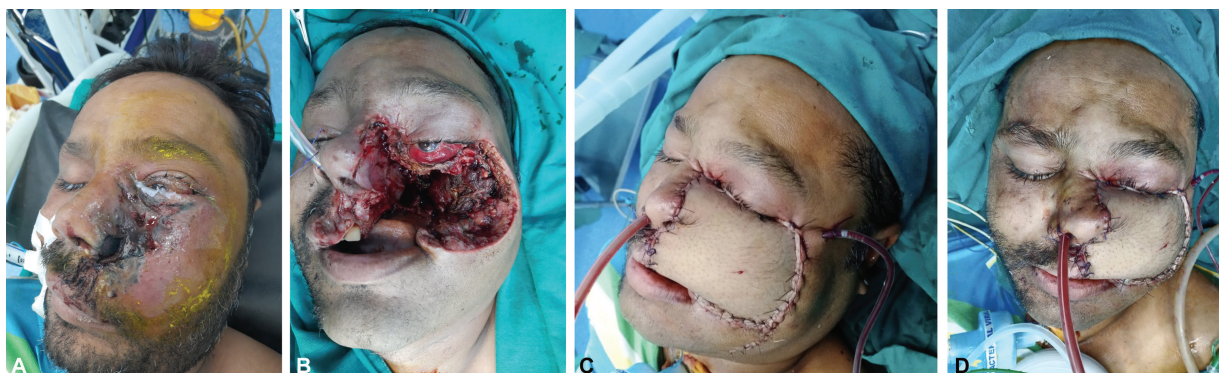

Fig. 3 Case 2: Another patient was operated using free ALT flap. (A) Preoperative picture of invasive mucormycosis. (B) Residual defect after excision. (C) Flap inset. (D) Flap inset. ALT, anterolateral thigh.

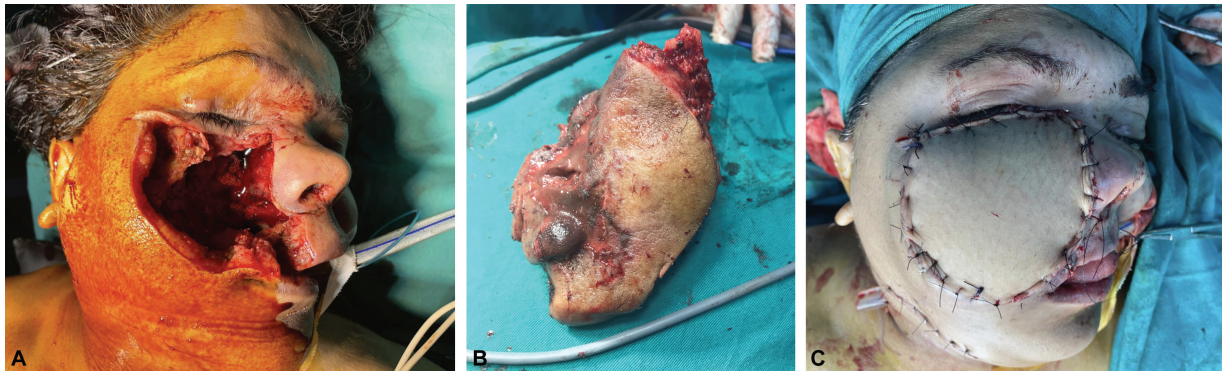


Fig. 4 Case 3: Another patient was operated using free ALT flap. (A) Excised segment. (B) Residual defect. (C) Flap inset.

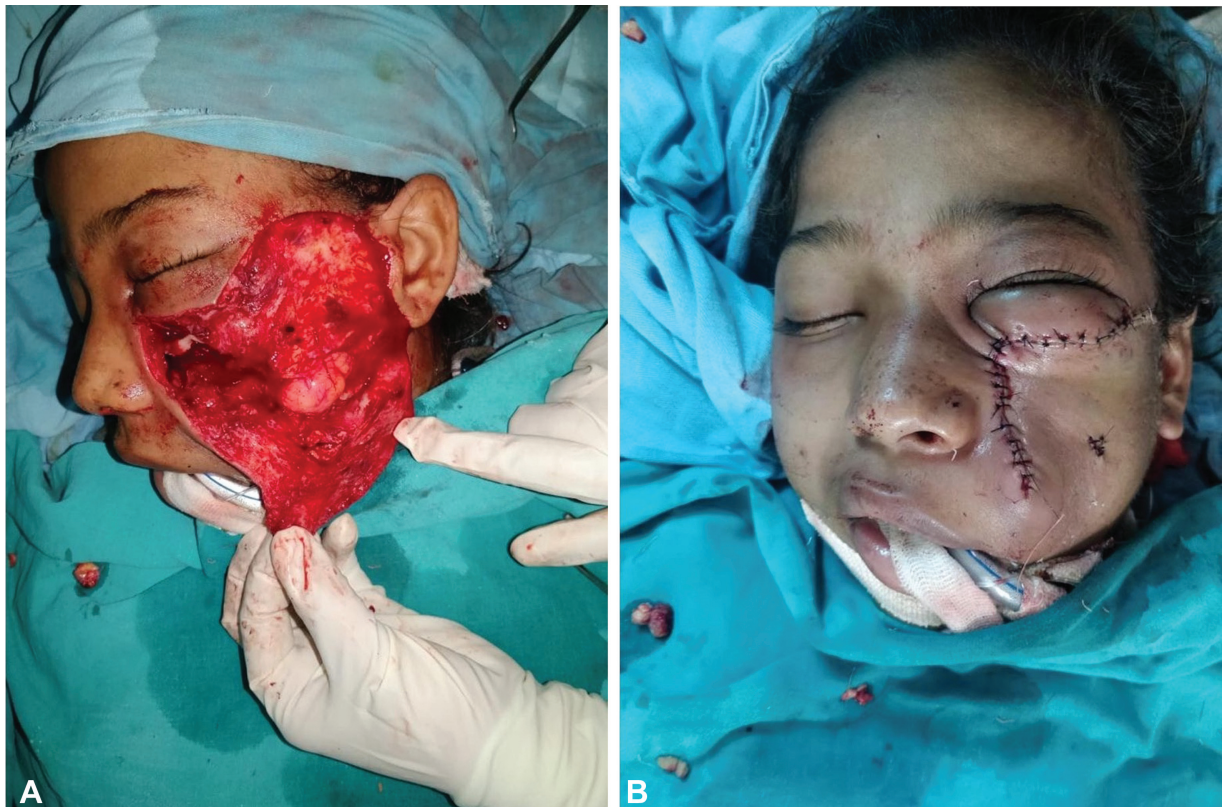

Fig. 5 Case reconstructed using Mustarde flap. (A) Residual defect after excision of diseased segment and flap raised. (B) Flap inset.

analysis of patients with mucormycosis and COVID-19, the disease was present in patients with active COVID-19 (59.4%) and patients who recovered (40.6%) from COVID-19.¹³ In a recent systematic review, hyperglycemia at presentation (new-onset hyperglycemia, new-onset diabetes, diabetic ketoacidosis [DKA], or preexisting DM) was the single most important risk factor observed in majority of cases (83.3%) of mucormycosis in people with COVID-19, followed by cancer (3.0%). Corticosteroid administration for the treatment of COVID-19 was recorded in 76.3% of cases.¹³

Rhino-orbito-cerebral variant commonly mimics the symptomatology of sinusitis and orbital cellulitis, hence swelling and pain are the most common initial presentations.³ In mucormycosis, local disease progression along with thrombosis and tissue infarction leads to the formation

of black necrotic eschars in the nasal mucosa or palate.³ Hard palate ulceration is indicative of extension beyond maxillary sinus boundaries.³ Orbital involvement can be attributed to angioinvasion nature of the mucor fungi which is responsible for causing ophthalmoplegia, either due to infection or vascular compromise.¹⁴ Owing to the aggressive nature of ROCM, early diagnosis, immunity stabilization, immediate commencement of antifungal therapy, and surgical care are of paramount importance to arrest the mortalizing and debilitating progression of the disease.¹⁵

In the oral and maxillofacial region, mucormycosis mimics various other pathologies like osteomyelitis,¹⁶ delaying definite diagnosis hence possibly fueling its insidious progression that can prove to be fatal. Reports in current literature suggest KOH culture and histopathology to be the most accurate and useful

diagnostic tools to confirm presence of characteristic mucor hyphae responsible for causing mucormycosis infection.¹⁷ Hence to counter the insidious presentation of ROCM, our protocol recommends immediate KOH culture and histopathology testing for all necrotic facial infection cases, regardless of COVID-19 status. Patients with definite clinical symptoms like rhinorrhea and any type of necrotic tissue presentation in the facial region with or without orbital cellulitis are started on liposomal amphotericin B. Amphotericin B has been reported to be the drug of choice for mucormycosis, owing to its antifungal potential which is mediated through its ability to bind with ergosterol.¹⁷ The liposomal amphotericin B is preferred in treatment of mucormycosis over its conventional counterpart as the former has been reported to have minimal renal toxicity and hence can be used in higher doses and for longer duration as required in mucormycosis treatment. In accordance with the dosage recommendations described in the current literature, we administered 5 mg/kg/day of liposomal amphotericin B in our patients preoperatively and continued the same over the postoperative period.^{18,19} Although 800 mg/day/30 days dose of posaconazole has been recommended as an alternative therapy in patients who are unable to tolerate amphotericin B, none of our patients showed signs of intolerance to the drug, and, hence, we continued on the liposomal amphotericin B therapy.^{18,19} Vasoocclusion property of the disease is responsible for reduced drug delivery to the affected sites, therefore in agreement with recommendations from previous studies, we irrigate the surgical site with amphotericin B gel and so far have found it to be effective.¹⁷ In addition to antifungal therapy, prompt surgical debridement has been described to facilitate a 2- to 2.5-fold improvement in the clinical outcomes and 1.5-fold increase in the survival rate; therefore, our protocol has adopted an “immediate drug-debridement-reconstruction” action plan through which we have been able to demonstrate superior clinical and survival outcomes in the most recent follow-up of our patient cohort.¹⁸ Although prosthetic reconstruction has been recommended by oral and maxillofacial surgeons because of its ability to provide an aesthetically sound outcome and ability to allow dental rehabilitation, we believe autologous reconstruction is the superior reconstructive choice as the former is contraindicated in situations where structures are exposed.²⁰ Some authors have also reported multiple debridement sessions to gain disease control and delayed reconstruction.^{21,22} In comparison to most of the studies reported in literature in which reconstructions of almost (88%) all published head and neck mucormycosis cases are performed secondarily,²³ in our study, we postulate extensive wide tissue resection and immediate reconstruction as an adequate treatment option for patients with ROC mucormycosis to decrease further operations and improve recovery. Even though an additional revision procedure is required to restore cosmesis, autologous reconstruction ensures adequate coverage of the defect, all the while supporting the facial contour.²⁰

Limitations

The limited number of patients of the study limits the methodology for external validity. Due to the early resection

and reconstruction, we are unable to predict the effect of the antifungal treatment alone versus antifungal treatment in combination with surgical debridement.

Conclusion

A multidisciplinary and comprehensive approach must be implemented for the early detection and treatment of ROCM, especially in the current COVID-19 pandemic. The mainstay of treatment includes reversal of immunosuppression, local and systemic antifungal administration, immediate or early surgical excision, and, if possible, immediate reconstruction with early rehabilitation. The approach presented in this study indicates that immediate reconstruction is safe and reliable in cases when appropriate tissue resection is accomplished. However, further studies with a higher sample size are required to assess the viability of this approach in patients with history of COVID-19.

Author Contributions

Conceptualization: all authors. Data curation: all authors. Formal analysis: all authors. Funding acquisition: P.G. and S.G. Investigation: all authors. Methodology: all authors. Project administration: all authors. Resources: all authors. Software: all authors. Supervision: P.G. and S.G. Validation: all authors. Visualization: all authors. Writing-original draft: all authors. Writing-review and editing: all authors.

Patient Consent

Informed consent was obtained from all individual participants included in the study.

Funding

None.

Conflict of Interest

None declared.

References

- Song G, Liang G, Liu W. Fungal co-infections associated with global COVID-19 pandemic: a clinical and diagnostic perspective from China. *Mycopathologia* 2020;185(04):599–606
- Cornely OA, Arikan-Akdagli S, Dannaoui E, et al; European Society of Clinical Microbiology and Infectious Diseases Fungal Infection Study Group European Confederation of Medical Mycology. ESCMID and ECMM joint clinical guidelines for the diagnosis and management of mucormycosis 2013. *Clin Microbiol Infect* 2014; 20(Suppl 3):5–26
- Ibrahim AS, Spellberg B, Walsh TJ, Kontoyiannis DP. Pathogenesis of mucormycosis. *Clin Infect Dis* 2012;54(Suppl 1):S16–S22
- Prabhu RM, Patel R. Mucormycosis and entomophthoromycosis: a review of the clinical manifestations, diagnosis and treatment. *Clin Microbiol Infect* 2004;10(Suppl 1):31–47
- Tidwell J, Higuera S, Hollier LH Jr. Facial reconstruction after mucormycosis in an immunocompetent host. *Am J Otolaryngol* 2005;26(05):333–336
- Ingram PR, Suthanathan AE, Rajan Ret al. Cutaneous mucormycosis and motor vehicle accidents: findings from an Australian case series. *Med Mycol* 2014;52(08):819–825

- 7 Mignogna MD, Fortuna G, Leuci S et al. Mucormycosis in immunocompetent patients: a case-series of patients with maxillary sinus involvement and a critical review of the literature. *Int J Infect Dis* 2011;15(08):e533–e540
- 8 Petrikos G, Skiada A, Lortholary O, Roilides E, Walsh TJ, Kontoyiannis DP. Epidemiology and clinical manifestations of mucormycosis. *Clin Infect Dis* 2012;54(Suppl 1):S23–S34
- 9 Kueht M, Villarreal JA, Reece E et al. Cutaneous mucormycosis in solid organ transplant recipients after Hurricane Harvey: short- and long-term management. *Plast Reconstr Surg Glob Open* 2019;7(01):e2041
- 10 Verma DK, Bali RK. COVID-19 and mucormycosis of the craniofacial skeleton: causal, contributory or coincidental? *J Maxillofac Oral Surg* 2021;20(02):1–2
- 11 Roden MM, Zaoutis TE, Buchanan W et al. Epidemiology and outcome of zygomycosis: a review of 929 reported cases. *Clin Infect Dis* 2005;41(05):634–653
- 12 Talmi YP, Goldschmied-Reouven A, Bakon M et al. Rhino-orbital and rhino-orbito-cerebral mucormycosis. *Otolaryngol Head Neck Surg* 2002;127(01):22–31
- 13 Singh AK, Singh R, Joshi SR, Misra A. Mucormycosis in COVID-19: A systematic review of cases reported worldwide and in India. *Diabetes Metab Syndr* 2021;15(04):102146
- 14 Hosseini SM, Borghei P. Rhinocerebral mucormycosis: pathways of spread. *Eur Arch Otorhinolaryngol* 2005;262(11):932–938
- 15 Claustre J, Larcher R, Jouve T et al. Mucormycosis in intensive care unit: surgery is a major prognostic factor in patients with hematological malignancy. *Ann Intensive Care* 2020;10(01):74
- 16 Kim JG, Park HJ, Park JH et al. Importance of immediate surgical intervention and antifungal treatment for rhinocerebral mucormycosis: a case report. *J Korean Assoc Oral Maxillofac Surg* 2013;39(05):246–250
- 17 Srikanth V, Pradeep KN, Anantheswar Y et al. Cranio-facial mucormycosis—the plastic surgeon's perspective. *Eur J Plast Surg* 2020;43:239–246
- 18 Spellberg B, Edwards J Jr., Ibrahim A. Novel perspectives on mucormycosis: pathophysiology, presentation, and management. *Clin Microbiol Rev* 2005;18(03):556–569
- 19 Riley TT, Muzny CA, Swiatlo E, Legendre DP. Breaking the mold: a review of mucormycosis and current pharmacological treatment options. *Ann Pharmacother* 2016;50(09):747–757
- 20 Oswal NP, Gadre PK, Sathe P, Gadre KS. Mucormycosis of mandible with unfavorable outcome. *Case Rep Dent* 2012;2012:257940
- 21 Silberstein E, Krieger Y, Rosenberg N et al. Facial reconstruction of a mucormycosis survivor by free rectus abdominis muscle flap, tissue expansion, and ocular prosthesis. *Ophthalmol Plast Reconstr Surg* 2016;32(06):e131–e132
- 22 Bhatnagar A, Agarwal A. Naso-orbital fistula and socket reconstruction with radial artery forearm flap following orbital mucormycosis. *Natl J Maxillofac Surg* 2016;7(02):197–200
- 23 Juarez Palacios J, Hanson V, Medina Rendon MA, Lopez-Infante RS. Reconstruction of head and neck mucormycosis: a literature review and own experience in immediate reconstruction. *J Reconstr Microsurg Open*. 2019;04:e102–e102