



Single-Port Transaxillary Robot-Assisted Latissimus Dorsi Muscle Flap Reconstruction for Poland Syndrome: Concomitant Application of Robotic System to Contralateral Augmentation Mammoplasty

Yong-Jae Hwang, MD¹ Jae-Ho Chung, MD, PhD¹ Hyung-Chul Lee, MD, PhD¹
Seung-Ha Park, MD, PhD¹ Eul-Sik Yoon, MD, PhD¹

¹Department of Plastic and Reconstructive Surgery, Korea University Anam Hospital, Seoul, Republic of Korea

Address for correspondence Eul-Sik Yoon, MD, PhD, Department of Plastic and Reconstructive Surgery, Korea University Anam Hospital, 73, Goryeodae-ro, Seongbuk-gu, Seoul 02841, Republic of Korea (e-mail: yesanam2@korea.ac.kr).

Arch Plast Surg 2022;49:373–377.

Abstract

Currently, robot-assisted latissimus dorsi muscle flap (RLDF) surgery is used in treating patients with Poland syndrome and for breast reconstruction. However, conventional RLDF surgery has several inherent issues. We resolved the existing problems of the conventional system by introducing the da Vinci single-port system in patients with Poland syndrome. Overall, three patients underwent RLDF surgery using the da Vinci single-port system with gas insufflation. In the female patient, after performing RLDF with silicone implant, augmentation mammoplasty was also performed on the contralateral side. Both surgeries were performed as single-port robotic-assisted surgery through the transaxillary approach. The mean operating time was 449 (335–480) minutes; 8.67 (4–14) minutes were required for docking and 59 (52–67) minutes for robotic dissection and LD harvesting. No patients had perioperative complication and postoperative problems related to gas inflation. The single-port robot-assisted surgical system overcomes the drawbacks of previous robotic surgery in patients with Poland syndrome, significantly shortens the procedure time of robotic surgery, has superior cosmetic outcomes in a surgical scar, and improves the operator's convenience. Furthermore, concurrent application to another surgery demonstrates the possibility in the broad application of the robotic single-port surgical system.

Keywords

- ▶ Poland syndrome
- ▶ robotic surgical procedures
- ▶ surgical flaps
- ▶ mammoplasty
- ▶ breast implants

Currently, robotic surgery is actively employed in plastic surgery in various areas of reconstruction, such as head and neck reconstruction, breast reconstruction, and lymph node transfer.^{1–5} Previous studies have demonstrated the surgical

outcomes of robot-assisted latissimus dorsi flap (RLDF) surgery in patients with mastectomy and Poland syndrome.^{6,7} RLDF surgery was first introduced by Selber et al in 2011⁸ as a new method that involves a short incision, and shortens the

DOI <https://doi.org/10.1055/s-0042-1748647>.
ISSN 2234-6163.

© 2022. The Korean Society of Plastic and Reconstructive Surgeons. All rights reserved.

This is an open access article published by Thieme under the terms of the Creative Commons Attribution-NonDerivative-NonCommercial-License, permitting copying and reproduction so long as the original work is given appropriate credit. Contents may not be used for commercial purposes, or adapted, remixed, transformed or built upon. (<https://creativecommons.org/licenses/by-nc-nd/4.0/>)

Thieme Medical Publishers, Inc., 333 Seventh Avenue, 18th Floor, New York, NY 10001, USA

length of the patient's hospital stay, reduces postoperative pain, and has superior cosmetic outcomes compared with those of the conventional open technique.⁹ With these merits, it was primarily used for patients with Poland syndrome and for breast reconstruction. However, the previous da Vinci surgical system has several inherent issues. In addition to the axillary incision, additional small incisions are necessary, and it is difficult to resolve other problems, such as the limited field of view due to the curved chest wall, frequent arm fighting, and frequent collisions between the patient's body and the robot arm. In this study, we aimed to resolve the existing problems of robotic surgery using the da Vinci single-port (SP) system in patients with Poland syndrome.

Idea

Patient Details

Three patients with Poland syndrome underwent robotic surgery.

Case 1: The patient was an 18-year-old female with left Poland syndrome. Severe hypoplasia of the left breast and nipple was confirmed by visual examination, and agenesis of the pectoralis major was confirmed on computed tomography. The patient also had hypoplasia of the LD (►Fig. 1).

Case 2 and 3: Case 2 and 3 were a 22-year-old male patient and an 18-year-old male patient, respectively, with agenesis of the pectoralis major muscles on the left and right side.

All the three patients did not have hand anomalies. In all three cases, SP RLDF was performed using da Vinci SP with the transaxillary approach. In the case of the female patient, after performing RLDF with silicone implant and augmentation mammoplasty was performed on the contralateral side with additional silicone implants, and both surgeries were performed as SP robotic-assisted surgery through the transaxillary approach

Surgical Procedures

Preoperative Design

The neo-inframammary fold (IMF) lines for repositioning were marked on both sides. On the affected side, the border of the implant pocket for dissection was indicated. The midaxillary

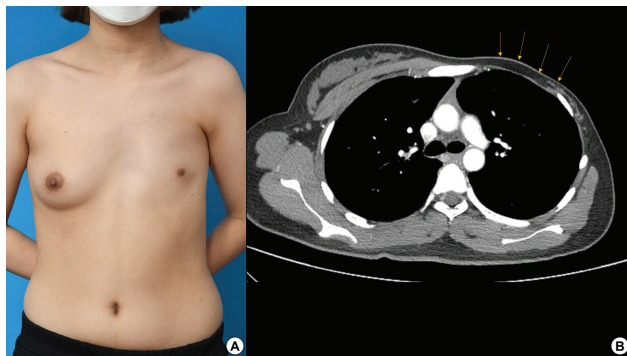


Fig. 1 Case 1, 18-year-old female with left Poland syndrome (left side). (A) Severe breast and nipple hypoplasia on left breast. (B) Pectoralis major muscle agenesis demonstrated on computer tomographic scan image.

line was also indicated, and the border was marked along the area of the LD. The tail of the Spence area was designed to be symmetrical with the normal side using slashed lines. A straight incision was made 5 cm from the anterior axillary crease along the midaxillary line. A line from the scapular tip to the neo-IMF line was drawn, the proximal part was set as the manual working space area (Zone I), and the remaining part was set as the robot-assisted dissection area (Zone II) (►Fig. 2).

Manual Dissection

After general anesthesia was administered, the patient was placed in the ventrolateral position and draped so that the ipsilateral arm could move freely. After making appropriate skin incisions according to the design, the subcutaneous plane above the LD fascia was dissected over Zone I, and the insertion site was circumferentially dissected to isolate the thoracodorsal pedicle and nerve.

SP System Docking and Robot-Assisted LD Harvesting

The upper pole of the 5 cm incision was temporarily repaired and narrowed to 3 cm. A uniport was inserted for insufflation using 12 mm Hg of CO₂ and then docking of the robotic surgery system was performed. A camera was placed at the 12 o'clock position; monopolar curved scissors at 3 o'clock; Cadieere forceps at 6 o'clock; and Maryland bipolar forceps at 9 o'clock. In the process of dissection, after performing a complete dissection until the inferior margin was exposed in the subcutaneous plane, division was performed along the lateral border; afterwards, the muscle was retracted using Cadieere forceps and submuscular plane dissection was performed. When the submuscular dissection was complete, we returned to the subcutaneous plane, divided the medial border, and lifted the muscle with Cadieere forceps to remove the remnant stalk. After confirming the free elevation status, a negative suction drain was inserted, and the robot was undocked (►Video 1).

Video 1

Single-port robot-assisted latissimus dorsi flap reconstruction for Poland syndrome. Online content including video sequences viewable at: <https://www.thieme-connect.com/products/ejournals/html/10.1055/s-0042-1748647>.

Breast Pocket Dissection, Position Change, and Flap Insetting

Through the midaxillary incision, subcutaneous dissection was performed manually along the pectoralis minor and chest wall up to the predesigned implant pocket margin. After transposition of the muscle flap to the anterior pocket, the patient was changed to the supine position. Flap insetting was performed for the transferred flap to reinforce the anterior coverage of the implant and the fullness of the superolateral region (tail of Spence) with preserving insertion of LD muscle, and the flap was fixed with an absorbable suture. Parts that were difficult to be reached using sutures were fixed with a bolster using a pull-out suture.

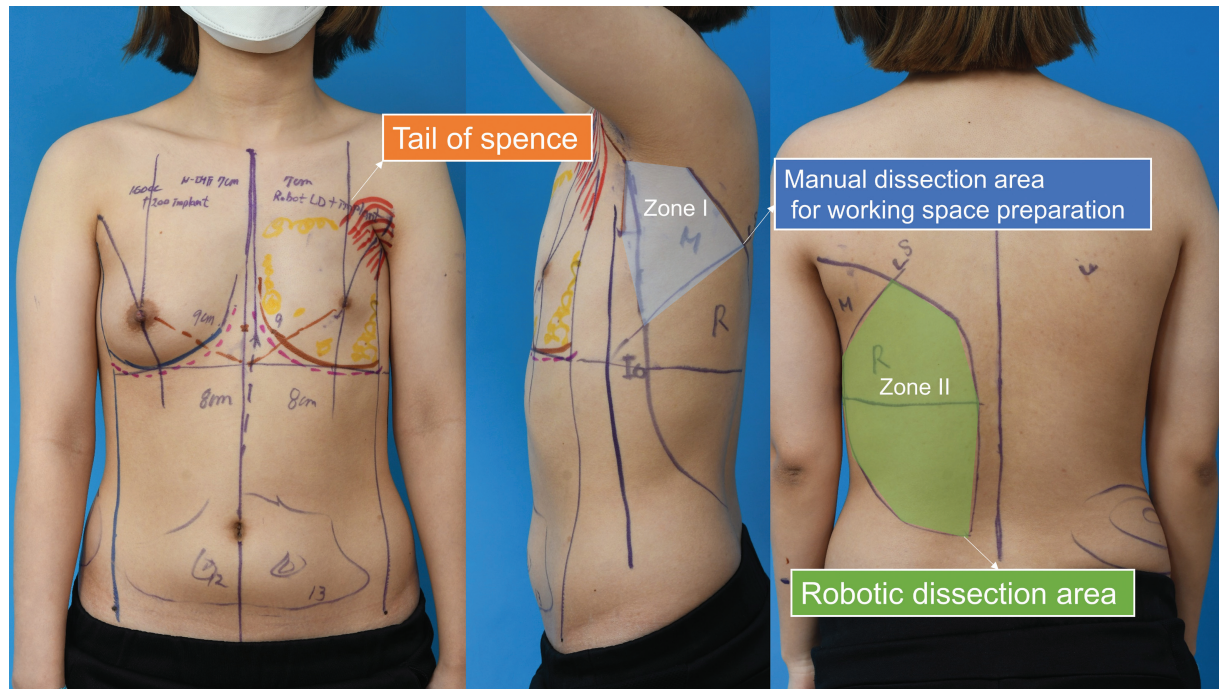


Fig. 2 Preoperative design. Red slashes in axilla indicate the absence of Spence's tail, and the blue area indicates the manual dissection area for securing the working space of the robot arm. The green area represents the robot-assisted dissection area.

Contralateral Robot-Assisted Transaxillary Augmentation Mammoplasty

Through a 3-cm incision along the crease of the axilla, subcutaneous tunneling was performed up to the insertion of the pectoralis major muscle, and a working space of approximately 5 cm in diameter was secured under the pectoral fascia. After inserting the uniport, insufflation was performed using 12 mm Hg of CO₂, and docking of the da Vinci SP system was performed. A camera was placed at the 12 o'clock position; monopolar curved scissors at 3 o'clock; and Maryland bipolar forceps at 9 o'clock; two robot arms were used. Subfascial dissection was performed using the robot system while checking the dissection border through the boundary where the camera's light illuminated up to the predesigned implant pocket border (→ **Video 2**).

Video 2

Single-port robot-assisted breast augmentation. Online content including video sequences viewable at: <https://www.thieme-connect.com/products/ejournals/html/10.1055/s-0042-1748647>.

Implant Insertion

The round smooth silicone implants were inserted on both sides, the symmetry of the breasts was assessed in the sitting position, and the places with contour irregularity were indicated by slashes.

Fat Harvesting and Lipofilling

Fat was harvested from both flanks and from the lower abdomen. After tumescent solution injection, fat harvesting

was performed using the Coleman's technique, and lipofilling was performed in places with contour irregularity. The remaining fat was stored frozen and used for secondary lipofilling at 8 weeks postoperatively.

Surgical Outcomes

One female and two male patients underwent RLDF surgery using the da Vinci SP system. The mean operating time was 449 (335–480) minutes; 8.67 (4–14) minutes were required for LD docking and 59 (52–67) minutes for robotic dissection. In female patients, for contralateral transaxillary augmentation mammoplasty, 30 minutes were required for axillary tunneling and manual working space dissection, 3 minutes for docking, and 30 minutes for pocket dissection. The patients had minimal intraoperative hemorrhage and no postoperative complications. After 8 weeks, the female patient underwent secondary lipofilling and nipple tattooing (→ **Fig. 3**). For male patients, no additional procedures were required (→ **Fig. 4**). No patients had perioperative complications, such as hematoma, seroma, infection, and implant loss, and there were no postoperative problem related to CO₂ inflation, such as hypercapnia, air embolism, and respiratory acidosis, except for mild subcutaneous emphysema that occurred in one patient

Discussion

Our study demonstrated favorable surgical outcomes with SP robotic system for LD harvesting in patients with Poland syndrome and breast reconstruction. Compared with the conventional robot system, the da Vinci SP system has specific advantages for LD harvesting in addition to the overall convenience of surgery. The advantages of a SP are

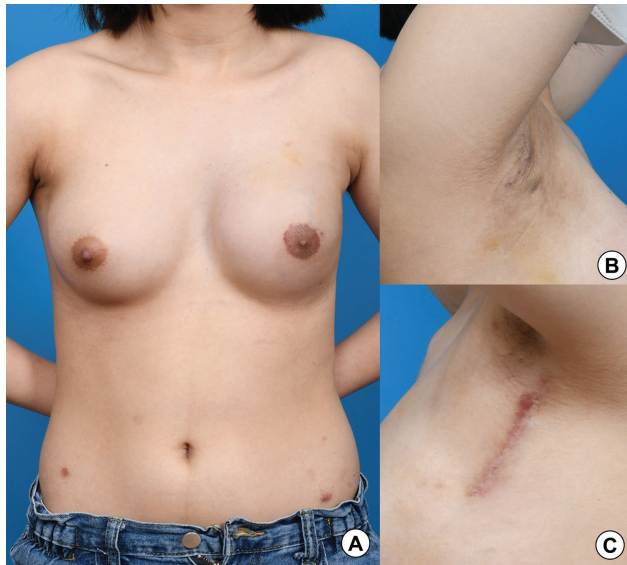

Fig. 3 Case 1, 18-year-old female patient with Poland syndrome (left side). (A) Six-month postoperative clinical image. (B, C) Postoperative scar on both axilla.

as follows: the problem of the robot arm inserted from the patient's head side frequently colliding with the patient's head and arm in the previous da Vinci system was resolved and no additional incision was required, thus demonstrating aesthetic superiority. The articulation of the flexible camera and the instruments led to drastic improvements in the field of view in the deep inferior margin beyond the posterior curvature of chest wall and the range of motion of the robotic arm.

In the conventional robotic system, because three ports were used, it took a considerable amount of docking time because the setting of the respective robotic arms had to be considered to reduce the arms from interfering with each other, and as dissection progressed, readjustment was needed, and this required additional time. However, since the da Vinci SP system does not require these processes, the docking time was greatly reduced compared with that reported in a previous study⁶ (4–14 vs. 35–58 minutes).

When using the conventional robotic system, RLDF surgery is a gasless surgery that involves the use of a long retractor because it is difficult to retract the LD using a robot arm alone. However, in the case of the da Vinci SP system, since the third arm is always within the field of view, stable retraction can be performed and harvesting is possible only with gas inflation. In addition, surgery using a SP system with gas enables smaller incisions. In previous studies, an incision of 5 to 6 cm was required.^{6,10} Joo et al performed prosthetic breast reconstruction through an incision of 2.5 to 4.7 cm using the da Vinci SP system with a gasless technique.¹¹ In our study, RLDF surgery was performed through a 5-cm incision in the midaxillary crease and augmentation mammoplasty was performed through a 3-cm incision in the axillary crease with gas inflation. With the da Vinci SP system, the prognosis of postoperative skin necrosis or scarring is superior because not only is the length and

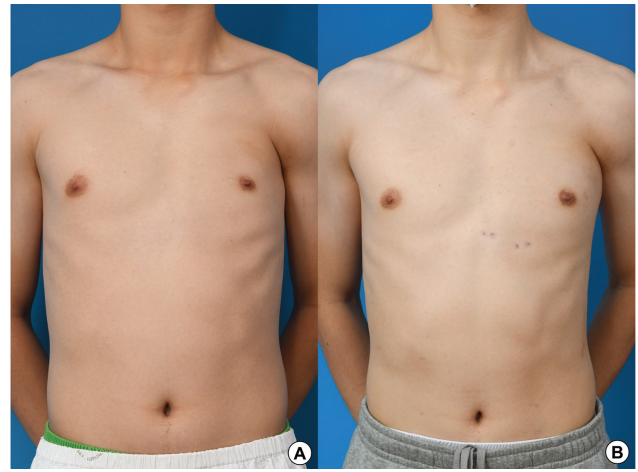


Fig. 4 Case 2, 18-year-old male patient with Poland syndrome (left side). (A) Preoperative clinical image. (B) Six-month postoperative clinical image.

number of the incision reduced, but also the damage to the incision skin flap from the retractor is significantly reduced.

In the case of augmentation mammoplasty, compared with the conventional endoscopic technique, transaxillary augmentation using a robot has superiority in the utility of surgery during pocket dissection through a flexible arm and a three-dimensional view. Also, during gas insufflation, the implant pocket inflates into a dome shape, helping to create a pocket with a uniform round shape.¹² However, since repeated docking is cumbersome, it is necessary to accurately plan the implant size and the extent of the pocket dissection before surgery to reduce unnecessary operation time. Also, at present, expensive equipment is a limiting point for practical application.

There are a few precautions to keep in mind in robotic surgery. First, it has been reported that securing a working space using the gas-inflation technique involves a risk of CO₂-related complications of hypercapnia, respiratory acidosis, air embolism, and tachycardia.¹³ However, in the cases of this study, inflation was maintained only for a short duration of approximately 60 minutes and the surgeries were not intra-abdominal surgeries. Thus, the reported cases were not affected by problems and complications associated with pressure. There was one case of mild subcutaneous emphysema without other specific problems, and the patient improved within a few days with conservative supportive treatment. Second, surgery should be started only after the learning curve has been raised through simulation surgery and sufficient prior education. It is only possible to reduce the frequency of manual conversion and guarantee a short operation time only when the skill of the assistant performing docking is matched as well as the skill of the operator.

The isolation of LD muscle pedicle and the anterior breast pocket dissection were performed manually, and in the process, the longer length of incision (~5 cm) was needed than the actual incision required for docking of the robot arm with gas insufflation (around 3 cm). With an improving learning curve and an increase in its applicability, most of

the procedures are expected to be performed by the surgical robot. It is expected that the length of the incision can be reduced.

In conclusion, the SP robot-assisted surgical system overcomes the drawbacks of previous robotic surgery in breast and chest reconstruction of patients with Poland syndrome, dramatically shortens the surgical time, has superior cosmetic outcomes in a scar length, number, and prognosis, and improves the operator's convenience. In addition, its versatile applicability allows flexible applications in surgeries other than reconstruction. If the problem of cost can be resolved in the future, the SP robotic surgery may be applied to other cosmetic surgeries.

Author Contributions

Conceptualization: E.-S.Y. Data Curation: Y.-J.H., H.-C.L. Formal analysis: S.-H.P., Y.-J.H. Methodology: H.-C.L., Y.-J.H. Writing-original draft: Y.-J.H. Writing-review and editing: E.-S.Y., H.-C.L., S.-H.P.

Ethical Approval

The study was approved by the Institutional Review Board of Korea University Anam Hospital (IRB No. 2021AN0333) and performed in accordance with the principles of the Declaration of Helsinki. Written informed consent was obtained.

Patient Consent

The patients provided written informed consent for the publication and the use of their images.

Prior Presentation

This article was presented at the 11th Research & Reconstruction Forum on May 7–8, 2021.

Funding

None.

Conflict of Interest

None declared.

References

- Ahn SJ, Song SY, Park HS, et al. Early experiences with robot-assisted prosthetic breast reconstruction. *Arch Plast Surg* 2019;46(01):79–83
- Ciudad P, Date S, Lee MH, et al. Robotic harvest of a right gastroepiploic lymph node flap. *Arch Plast Surg* 2016;43(02):210–212
- Song HG, Yun IS, Lee WJ, Lew DH, Rah DK. Robot-assisted free flap in head and neck reconstruction. *Arch Plast Surg* 2013;40(04):353–358
- Jeon DN, Kim J, Ko BS, et al. Robot-assisted breast reconstruction using the prepectoral anterior tenting method. *J Plast Reconstr Aesthet Surg* 2021;74(11):2906–2915
- Selber JC. The robotic DIEP flap. *Plast Reconstr Surg* 2020;145(02):340–343
- Moon KC, Yeo HD, Yoon ES, et al. Robotic-assisted latissimus dorsi muscle flap for autologous chest reconstruction in Poland syndrome. *J Plast Reconstr Aesthet Surg* 2020;73(08):1506–1513
- Chung JH, You HJ, Kim HS, Lee BI, Park SH, Yoon ES. A novel technique for robot assisted latissimus dorsi flap harvest. *J Plast Reconstr Aesthet Surg* 2015;68(07):966–972
- Selber JC, Baumann DP, Holsinger FC. Robotic latissimus dorsi muscle harvest: a case series. *Plast Reconstr Surg* 2012;129(06):1305–1312
- Winocour S, Tarassoli S, Chu CK, Liu J, Clemens MW, Selber JC. Comparing outcomes of robotically assisted latissimus dorsi harvest to the traditional open approach in breast reconstruction. *Plast Reconstr Surg* 2020;146(06):1221–1225
- Houvenaeghel G, Bannier M, Rua S, et al. Robotic breast and reconstructive surgery: 100 procedures in 2-years for 80 patients. *Surg Oncol* 2019;31:38–45
- Joo OY, Song SY, Park HS, Roh TS. Single-port robot-assisted prosthetic breast reconstruction with the da Vinci SP Surgical System: first clinical report. *Arch Plast Surg* 2021;48(02):194–198
- Lee H, Lee J, Lee K, Kim JY, Park HS. Comparison between gasless and gas-inflated robot-assisted nipple-sparing mastectomy. *J Breast Cancer* 2021;24(02):183–195
- Gutt CN, Oniu T, Mehrabi A, et al. Circulatory and respiratory complications of carbon dioxide insufflation. *Dig Surg* 2004;21(02):95–105