



Complex Elbow Fracture-Dislocation with Distal Humerus Involvement: Clinical Case Report

Luxofractura compleja del codo con compromiso del húmero distal: Reporte de caso clínico

Pablo Sebastián Escudero-Acurio¹ Carlos Escudero Orozco^{2,3} Carlos Moreno-Castillo⁴

¹ Medicine School, Facultad de Medicina y Ciencias, Universidad San Sebastián, Concepción, Chile

² Vascular Physiology Laboratory, Department of Basic Sciences, Universidad del Bío-Bío, Chillán, Chile

³ Vascular Health Research and Innovation Group (GRIVAS Health), Chillán, Chile

⁴ Shoulder and Elbow Team – Traumatology, Centro Clínico de Especialidades Quirúrgicas, Complejo Asistencial Dr. Víctor Ríos Ruiz, Los Ángeles, Chile

Address for correspondence Dr. Carlos Moreno-Castillo, MD, PhD, Av. Ricardo Vicuña 147, Los Ángeles, Los Ángeles, Chile (e-mail: drmorenocastillo@gmail.com).

Rev Chil Ortop Traumatol 2022;63(2):e123–e127.

Abstract

It is known that the elbow is dislocated frequently, representing the first cause of dislocation in children and the second cause in adults. Regarding distal humerus fractures, they represent a third of all humerus fractures in the adult population. They generally occur in a bimodal distribution, affecting young men or elderly women. In the present article, we report a rare clinical case of a complicated left elbow dislocation due to a distal humerus fracture in a 64-year-old woman. The lesion includes a posterolateral dislocation of the left elbow complicated by a sagittal, multifragmentary, partial articular fracture (compromise of the condyle and external humeral trochlea) of the distal humerus which required three surgical interventions and rehabilitation therapy for six months and resulted in functional recovery of the stability of the elbow joint. The case herein reported is particular due to the individuality of the patient, with her comorbidities, the mechanism of production of the fracture-dislocation, the surgical approach, and the success of the established treatment. This therapeutic success must be confirmed in series of cases.

Level of Evidence Case report.

Keywords

- ▶ dislocation
- ▶ fracture
- ▶ elbow
- ▶ clinical case
- ▶ osteosynthesis

Resumen

Palabras Clave

- ▶ luxación
- ▶ fractura
- ▶ codo
- ▶ caso clínico
- ▶ osteosíntesis

Es conocido que el codo se disloca con frecuencia, y corresponde a la primera causa de luxación en niños y a la segunda causa en adultos. Respecto a las fracturas distales, representan un tercio de todas las fracturas del húmero en población adulta. Por lo general, se presentan en una distribución bimodal que afecta a hombres jóvenes o a mujeres ancianas. En este artículo, reportamos un caso clínico poco frecuente de luxación de codo izquierdo complicada, producto de fractura del húmero distal, en una mujer de 64 años. La lesión comprende una luxación posterolateral de codo izquierdo

received
December 11, 2020
accepted
February 18, 2022

DOI <https://doi.org/10.1055/s-0042-1748027>.
ISSN 0716-4548.

© 2022. Sociedad Chilena de Ortopedia y Traumatología. All rights reserved.

This is an open access article published by Thieme under the terms of the Creative Commons Attribution-NonDerivative-NonCommercial-License, permitting copying and reproduction so long as the original work is given appropriate credit. Contents may not be used for commercial purposes, or adapted, remixed, transformed or built upon. (<https://creativecommons.org/licenses/by-nc-nd/4.0/>)

Thieme Revinter Publicações Ltda., Rua do Matoso 170, Rio de Janeiro, RJ, CEP 20270-135, Brazil

complicada con fractura articular parcial (compromiso del cóndilo y de la tróclea humeral externa), sagital, multifragmentaria, de húmero distal que requirió tres intervenciones quirúrgicas y terapia de rehabilitación por seis meses que finalizaron en recuperación funcional de la estabilidad de la articulación del codo. El caso reportado es particular debido a la individualidad del paciente con sus comorbilidades, el mecanismo de producción de la luxofractura, el abordaje quirúrgico, y el éxito del tratamiento instaurado. Sin embargo, este éxito terapéutico debe ser confirmado en series de casos.

Nivel de evidencia Reporte de caso.

Introduction

It is known that the elbow dislocates frequently, and corresponds to the first cause of dislocation in children and the second most frequent cause in adults.^{1,2} In the United States in 2012,³ an annual incidence of elbow dislocations of 5.21 per 100 thousand inhabitants (children and adults) was determined, mainly affecting men. The most common mechanism of elbow dislocations is traumatic, by falls on the hand with the elbow in extension.¹ Finally, dislocations can be simple, if they only injure capsular or ligamentous structures, or complex, if they compromise bone structures,^{1,2} such as those associated with distal humerus fractures.

Regarding distal humerus fractures, they represent ~ 2% of all fractures and 33% of all humerus fractures in the adult population.⁴ They usually occur in a bimodal distribution, affecting younger men or older women.¹ There are two main fracture mechanisms: the first, in the elderly due to low-energy trauma with direct impact on the elbow or indirect impact resulting from a fall with the elbow extended. And the second, resulted from high-energy trauma in young patients.⁵

There are several classification criteria mainly based on the involvement of the medial and lateral columns of the distal humerus and on the presence of sagittal or coronal fracture patterns. The most used is that of the Arbeitsgemeinschaft für Osteosynthesefragen (AO, the Working Group for Bone Fusion Issues), which classifies fractures into extra-articular, partial articular and articular.⁴ In addition, there are other classifications such as the one by Milch, which is more used for pediatric patients,⁶ or the Dubberley or Brayan and Morrey classification of capitulum fractures.⁷ Regardless of their nature, distal humerus fractures require surgical intervention due to the great functional disability of the joint. However, despite the surgical advances, there is little information on controlled clinical trials that report the effectiveness of the surgical treatment of condylar fractures of the distal humerus in adults.⁸ The information available is mainly composed of reports of experiences by centers or reports of clinical cases.^{2,8} [superscript]

Considering this background, the objective of the present article is to report a rare clinical case of complex elbow fracture-dislocation due to distal humerus fracture.

Clinical case

A 64-year-old female patient with a history of chronic obstructive pulmonary disease (COPD), compensated dilated cardiomyopathy, and no allergies. She was referred from a rural area due to an accidental fall, reporting having fallen with all her weight on her hand (in supination) and the left elbow in extension. The patient arrived with a lot of pain, edema and functional impotence of the affected elbow. Upon physical examination, the left arm was found in semiflexion, with a deformity compatible with posterolateral dislocation without neurovascular involvement. Subsequently, radiographs and computed tomography (CT) scans with three-dimensional (3D) reconstruction (→ **Figure 1**) confirmed a posterolateral dislocation of the left elbow complicated by a partial joint (involvement of the humeral condyle and trochlea), multifragmentary, sagittal fracture of the distal humerus.

A first intervention was decided during the emergency shift by the doctor on duty, who performed reduction and immobilization in flexion and pronation and reported great clinical instability during the procedure, which was suggestive of significant ligament compromise. In the next day, CT scans were performed, showing the elbow joint was again dislocated. The medical team decided on surgery: a new reduction was performed, and the olecranon-humeral joint was stabilized with a 2.5 mm Kirschner wire, to subsequently immobilize it with a brachiopalmar plaster cast. The patient was evaluated by the Shoulder and Elbow Team of the hospital, new radiological and tomographic controls were requested, the injury was classified, and the preoperative planning for the definitive surgical procedure was carried out.

The definitive surgery was performed one week after the second reduction in the elective pavilion. A universal posterior approach to the elbow was performed in the supine position and under general anesthesia, dissecting a fasciocutaneous plane, exposing the articular surface of the distal humerus (lateral condyle), evidencing the multifragmentary coronal fracture of the humeral condyle and trochlea, as well as indemnity of the radial dome. A lateral approach through lateral complex avulsion was performed, as well as anatomical reduction of the joint fragments and internal fixation through the lateral traumatic interval (avulsion of the lateral collateral ligament, LCL) with 2.5 mm Accutrack (Oviedo, FL, US) screws (20 mm, 28 mm, and 30 mm), satisfactorily restoring the

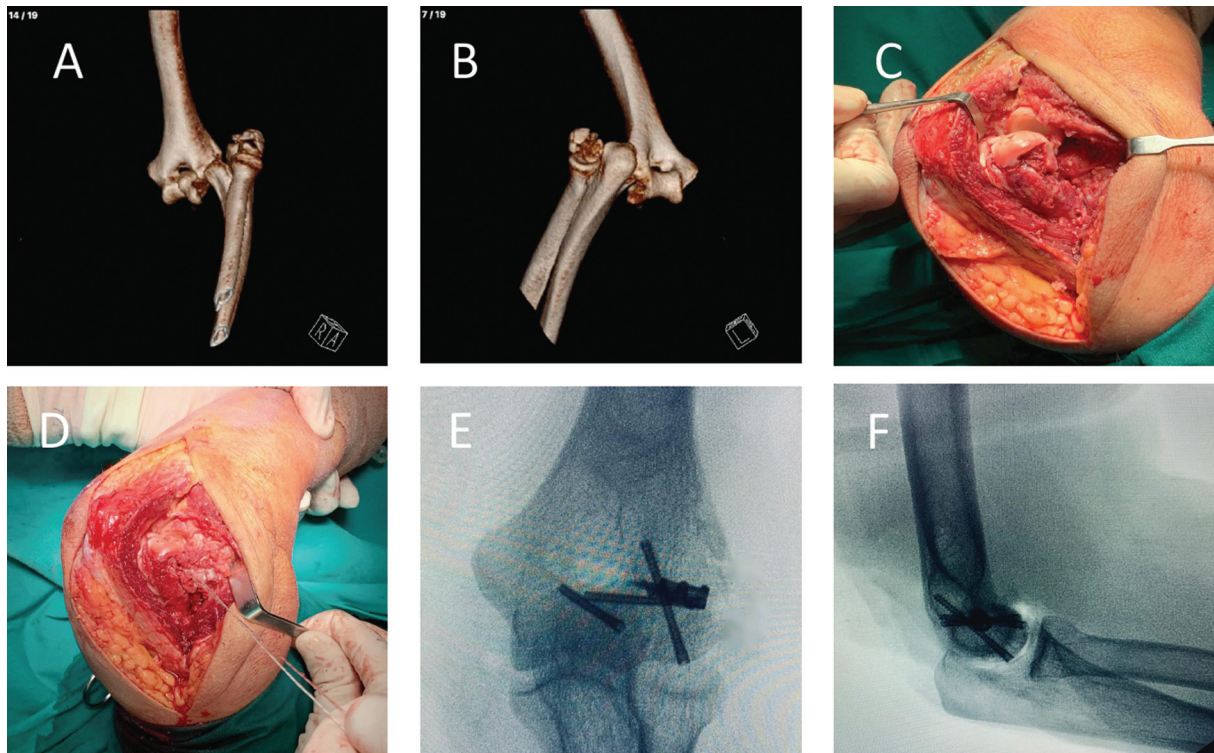


Fig. 1 Complex elbow fracture-dislocation. Case report. (A) Three-dimensional (3D) reconstruction of a computed tomography (CT) scan on anterior view of the elbow, with involvement of the humeral capitellum. (B) 3D reconstruction of a CT scan on posterior view of the elbow, with involvement of the humeral capitellum and trochlea. (C) Fixation of the fracture of the humeral capitellum and trochlea with screws. (D) Anchor at the level of the lateral epicondyle, with complete absence of the humeral attachment of the lateral collateral complex. (E) Anteroposterior intraoperative radiograph. (F) Lateral intraoperative radiograph.

anatomy of the distal humerus. The stability of the elbow was evaluated, and we decided to perform the primary repair of the lateral ligament complex on its avulsion in the humeral epicondyle using a 5.5-mm Arthrex (Naples FL, US) metal anchor (► **Figure 1**). Then, the lateral and medial stability was evaluated again, and effective flexion-extension, pronosupination, and stability were achieved intraoperatively. We decided not to perform any procedures on the medial collateral complex. The intraoperative control radiographs showed correct reduction of the fracture dislocation (► **Figure 1**). The patient left the ward with a brachio-palmar plaster splint for pain control, which was removed five days after the procedure, at the time of her discharge (which was prolonged due to her distant residence).

Results

The postoperative period was uneventful, with good evolution, and the patient was discharged five days after the definitive surgery, without immobilization and after evaluation by a kinesiologist from the elbow team of the care complex, who left recommendations to exercise passive and active mobility as tolerated.

First follow-up: 3 weeks after discharge, the patient was examined in a polyclinic, and was in good condition, without pain or functional limitation, with good mobility, achieving 30° to 110° of flexion-extension and 60° to 60°

of pronosupination. The first radiological control was performed, the stitches were removed, and the start of formal rehabilitation therapy was authorized by a kinesiologist, 3 times a week.

Second follow-up: at 6 weeks postoperatively, the patient was in good condition, without pain, with a range of motion of 20° to 130° of flexion-extension and complete pronosupination (80° to 85°), clean and dry wound, performing rehabilitation as indicated, even without weight bearing. Stability tests were performed, with no pathological findings.

Third follow-up: at 12 weeks, the patient was in excellent condition in terms of mobility: 10° to 140° of flexion-extension and 80° to 85° of pronosupination. The second radiological control was performed (► **Figure 2**).

Fourth follow-up: at 6 months, the last check-up was carried out, the patient was in good condition, performing all her activities without limitations, without pain or instability, achieving mobility of 5° to 145° of flexion-extension and 80° to 85° of pronosupination. The patient was discharged.

Discussion

The clinical case herein reported is that of a dislocated fracture of the left elbow in an adult patient, which required three surgeries (two emergency and 1 elective surgeries) that resulted in functional recovery of the stability of the left elbow joint. This type of injury is more common in

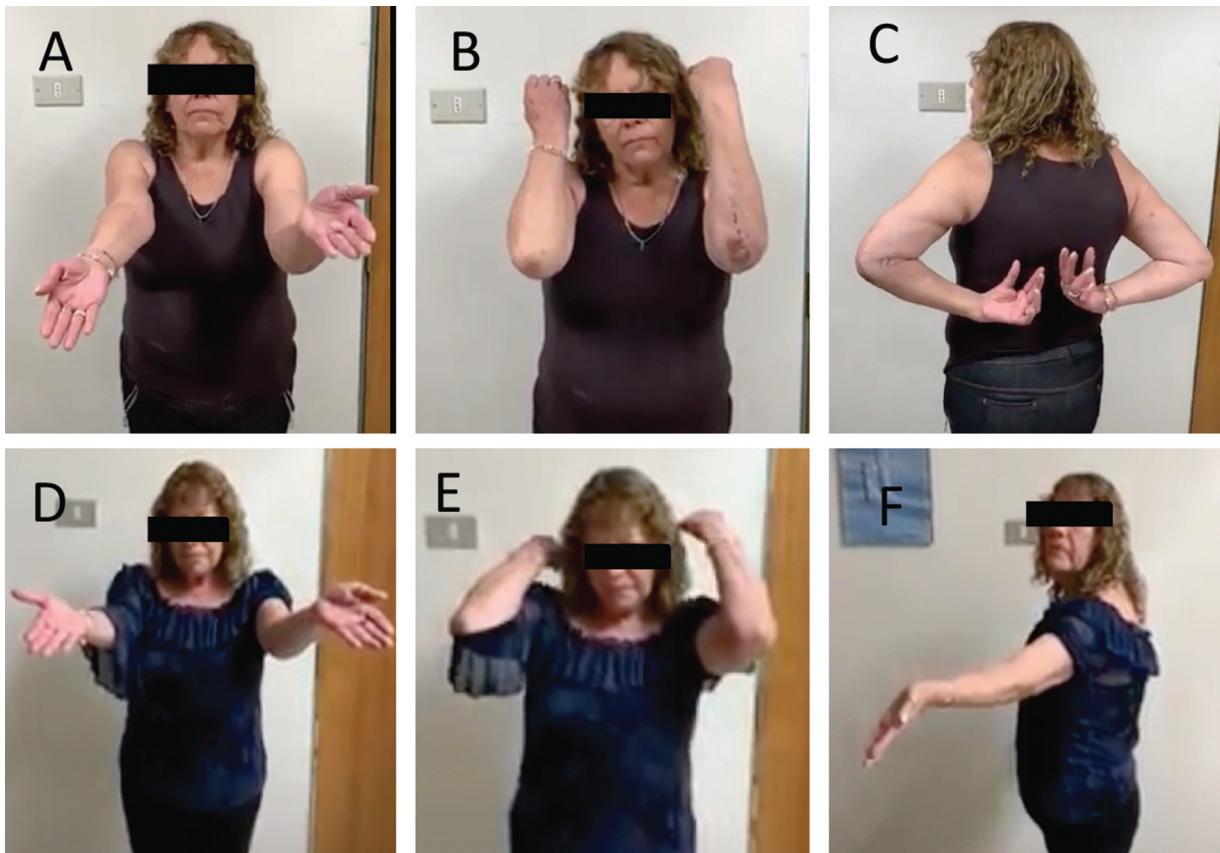

Fig. 2 Postoperative result of complex elbow fracture-dislocation. Case report. (A) Extension, flexion, and flexion with supination and internal rotation of the shoulder three weeks postoperatively. (B) Flexion and extension 12 weeks postoperatively.

children.^{1,2} However, as they differ from the pediatric population, in the adult population, both the mechanism and type of fracture-dislocation, the patient comorbidities, the previous functional capacity, the type of approach, and the anatomical structures to be repaired are variables to consider for the definitive treatment.^{1,4,9} This emphasizes the importance of reporting this type of injury in the adult population.

In terms of anatomy and function, three joints make up the elbow joint. The medial aspect of the elbow includes the ulnotrochlear joint, which is responsible for flexion and extension, while the lateral radiocapitellar and proximal radioulnar joints are primarily responsible for pronation and supination.¹ Mechanically, the elbow is stabilized by the congruence of the articulating surfaces, and supported by static structures, such as the ulnohumeral joint, the medial collateral ligament (MCL), and the LCL.^{1,10} Added to this, the dynamic stabilizers, such as the anconeus, triceps and brachialis muscles.¹⁰

Elbow dislocations are the second most common cause of dislocations in adults.^{1,2} Up to 20% of dislocations are associated with fractures, the most frequent being those of the medial condyle, radial head, and coronoid process.⁸ These complex dislocations can result in significant patient morbidity, and they are associated with an increased risk of chronic instability, posttraumatic osteoarthritis, and poor functional outcomes compared to simple dislocations.¹¹ On the other hand, distal humerus fractures correspond to 2% of all fractures, and condylar involvement is extremely rare in

adults (less than 0.001%).⁴ In this context, the clinical case herein reported corresponds to a posttraumatic injury with a dislocation-fracture of the elbow, precisely affecting the external condyle.

In the literature, it is known that the most frequent mechanism of elbow injuries in adult patients, particularly women, are falls.^{1,9} Compatible with this, in our clinical case the mechanism of the reported fracture dislocation was direct impact of the lateral condyle of the humerus with the elbow in extension, exerting an axial load on the elbow joint. The classification of the injury corresponded to a complex posterior dislocation associated with a lateral condylar fracture of the distal humerus (B1 according to the OA classification), or Dubberley type IB of the left elbow in an adult patient.

The fundamental objective in the treatment of complex dislocations of the elbow is the restoration of osteoarticular restrictions. The non-surgical treatment seems to be advisable only in cases of non-displaced fractures, in patients not suitable for surgery, or as a provisional treatment in the elderly before arthroplasty to avoid stiffness and heterotopic ossification,⁴ while most elbow fractures are surgical, especially those complex dislocations. Open reduction and internal fixation (ORIF), the use of an external fixator, and total elbow arthroplasty (TEA) are all therapeutic options for this type of injury. However, the latter would force younger patients or active adults to tolerate functional restriction, with the risk of bone loss and polyethylene wear associated

with TEA.⁴ Another option could be minimally-invasive surgery with an external fixator, which shows good results in elderly people.² The comparison of these different therapeutic options is limited in the literature. Despite this, the effectiveness of surgical treatments comes from experiences with a limited number of patients.⁹ This is understandable due to the individuality of each injury and how fortuitous this type of injury can be. But it is important to mention that, with the continuous increase in the elderly population in the world, fractures of the distal humerus could be more frequent, given the traumatic events resulting from falls in this age group. Therefore, it is necessary to report experiences by centers or by clinical cases, such as the one we have herein reported, in order to discuss the surgical results and outcomes of our patients.

In surgical terms, the type of fracture, the pattern of instability, and the laterality of the lesion, along with the soft tissues, are conditions that will determine the surgical approach,¹ and the most frequent for distal humerus fractures are olecranon osteotomy, triceps division, triceps preservation, and triceps elevation.⁴ For type-B1 fractures (or Dubberley type IB), such as the one herein reported, a lateral approach has been shown to be feasible and safe, exposing the lateral condyle by developing the interval between the triceps, the brachioradialis and the extensor long carpal radial.⁴

As for the LCL injury, its involvement is common due to its humeral union, and generates varus instability. Therefore, surgical treatment is necessary for its repair in elbow dislocations with associated fractures.^{1,11} A grasping suture using non-absorbable (#2) sutures can be placed through the holes in the distal lateral epicondyle to aid in the repair of the LCL. After verification of reduction, the elbow is flexed at 90° and pronated, finally tying the LCL sutures.¹¹

Within the limitations of our work, this is a single example of dislocated elbow fracture in which the surgical plan had to be adjusted. Initially, a posterior elbow approach (universal) was chosen, considering the need to repair the lateral and medial collateral complex, or an olecranon osteotomy, if necessary. However, intraoperatively, we decided not to perform any intervention on the medial collateral ligament (MCL) due to the anatomical repair of the condyle, the integrity of the radial head, and the stability of the joint with the LCL repair. Few orientations are available for the repair of the MCL. The available evidence has shown good results without systematic repair of this ligament,¹² in cases of complex approaches and ligamentous bundles that are difficult to identify after trauma.

In conclusion, the clinical case herein reported, of post-traumatic injury with dislocation-fracture of the left elbow, affecting the external condyle in an adult woman, is one of the few reports available. This reported case is unique due to the individuality of the patient, with her comorbidities, the mechanism of the fracture-dislocation, the surgical approach, and the success of the established treatment. This experience must be confirmed in a series of cases, which is precisely one of the medium-to-long-term objectives of our surgical team.

Funding and Acknowledgements

To the Fondecyt 1200250 (CEO) project.

Conflict of interests

The authors have no conflict of interests to declare.

References

- Layson J, Best BJ. Elbow Dislocation. [Updated 2021 Aug 11]. In: StatPearls [Internet]. Treasure Island (FL): StatPearls Publishing; 2021 Jan-. Available from: <https://www.ncbi.nlm.nih.gov/books/NBK549817/>
- Schep NWL, De Haan J, Iordens GIT, et al. A hinged external fixator for complex elbow dislocations: a multicenter prospective cohort study. *BMC Musculoskelet Disord* 2011;9(12):130
- Stoneback JW, Owens BD, Sykes J, Athwal GS, Pointer L, Wolf JM. Incidence of elbow dislocations in the United States population. *J Bone Joint Surg Am* 2012;94(03):240-245
- Amir S, Jannis S, Daniel R. Distal humerus fractures: a review of current therapy concepts. *Curr Rev Musculoskelet Med* 2016;9(02):199-206
- Egol KA, Walsh M, Romo-Cardoso S, Dorsky S, Paksima N. Distal radial fractures in the elderly: operative compared with nonoperative treatment. *J Bone Joint Surg Am* 2010;92(09):1851-1857
- Milch H. Fractures and fracture dislocations of the humeral condyles. *J Trauma* 1964;4(05):592-607
- Bryan RS, Morrey BF. Fractures of the distal humerus. En: Morrey BF, (Ed). *The Elbow and its Disorders*. Philadelphia, Pa: WB Saunders; 1985:302-39
- Moreno Lozano F. Fractura-luxación compleja de codo. *Rev S And Traum y Ort.* 2007;24-25:61-64
- Robinson CM, Hill RMF, Jacobs N, Dall G, Court-Brown CM. Adult distal humeral metaphyseal fractures: epidemiology and results of treatment. *J Orthop Trauma* 2003;17(01):38-47
- O'Driscoll SW, Jupiter JB, King GJ, Hotchkiss RN, Morrey BF. The unstable elbow. *Instr Course Lect* 2001;50:89-102
- Wyrick JD, Dailey SK, Gunzenhaeuser JM, Casstevens EC. Management of complex elbow dislocations: a mechanistic approach. *J Am Acad Orthop Surg* 2015;23(05):297-306
- García Portabella M, Pedemonte Jansana J, Massons Albareda J, Mir Bulló J. Inestabilidad compleja aguda de codo: etiopatogenia, diagnóstico y estrategia quirúrgica razonada. *Rev Esp Cir Ortop Traumatol* 2010;54(01):77-85