



# Recurrence Rate of Giant-Cell Tumor Treated by Curettage and Cementation

## *Índice de recurrencia de tumor de células gigantes con curetaje y cementación*

Jose Humberto Rodríguez-Franco<sup>1</sup>

<sup>1</sup> Pediatric Traumatology, UMAE Dr. Victorio de la Fuente Narváez, Mexico City, Mexico

Rev Chil Ortop Traumatol 2022;63(1):e33–e39.

Address for correspondence Jose Humberto Rodríguez Franco, Dr., Instituto Mexicano del Seguro Social (IMSS), Calzada Héroes de Chapultepec, 621, Col. Centro, Oaxaca de Juárez, México, ZIP code 68000 (e-mail: beto\_rquezfranco@hotmail.com).

### Abstract

**Objective** To identify the recurrence rate of giant-cell tumor (GCT) in patients treated by curettage and adjuvant therapy with polymethyl metacrylate with a minimum follow-up of 3 years.

**Methods** Observational and retrospective cohort with patients with diagnoses of Enneking stages 1 and 2 GCT treated through intralesional curettage and cementation between 1981 and 2011. Age, gender, anatomic location and relapse period were recorded. The data was analyzed with measures of central tendency and dispersion (standard deviation) for the quantitative variables, percentages for the qualitative variables.

**Results** Between 1981 and 2011 375 cases of GCT were identified, 141 (36.7%) of which were treated by this method. The follow-up ranged from 48 to 240 months, the age was of  $27 \pm 9$  years, 45% of the patients were female, and 55%, male, with a female:male ratio of about 1.2:1. The tibia was the most frequent affected bone (38%), followed by the femur (32%), the humerus (16%), and the radius (10%). The resection technique was intralesional curettage in about 88.6% of the cases, and marginal resection in the remaining cases. Pathologic fracture was present in approximately 15.7%, and recurrence occurred in approximately 12.7%.

**Discussion** We demonstrated that this treatment method decreases the risk of recurrence due to the local adjuvant effects of acrylic cementation. Recurrence events occur in the first two years after resection. However, some authors defend that the surgical margin is the only factor that influences the risk of local recurrence. The extraosseous extension of GCT is not a contraindication to perform intralesional curettage or to prescribe the adjuvant treatment with polymethyl metacrylate.

**Conclusions** We reported a recurrence rate similar to that of the literature, and this is a feasible resource for limb reconstruction.

### Keywords

- ▶ giant-cell tumor
- ▶ treatment
- ▶ resection
- ▶ polymethyl metacrylate

received  
March 10, 2021  
accepted after revision  
August 19, 2021

DOI <https://doi.org/10.1055/s-0041-1740640>.  
ISSN 0716-4548.

© 2022. Sociedad Chilena de Ortopedia y Traumatología. All rights reserved.

This is an open access article published by Thieme under the terms of the Creative Commons Attribution-NonDerivative-NonCommercial-License, permitting copying and reproduction so long as the original work is given appropriate credit. Contents may not be used for commercial purposes, or adapted, remixed, transformed or built upon. (<https://creativecommons.org/licenses/by-nc-nd/4.0/>)

Thieme Revinter Publicações Ltda., Rua do Matoso 170, Rio de Janeiro, RJ, CEP 20270-135, Brazil

## Resumen

**Objetivo** Identificar la tasa de recurrencia de tumor de células gigantes (TCG) en pacientes tratados con curetaje y cementación con seguimiento mínimo de tres años.

**Material y métodos** Cohorte retrospectiva y observacional de pacientes con diagnóstico de TCG en estadios 1 y 2 de Enneking tratados con curetaje intralesional y cementación entre 1981 y 2011. Se registraron edad, sexo, región anatómica, y tiempo de recurrencia. Se utilizó estadística descriptiva con medidas de tendencia central y medidas de dispersión (desviación estándar) para variables cuantitativas, y porcentajes para variables cualitativas.

**Resultados** Entre 1981 y 2011, se identificaron 375 casos de TCG, de los cuales 141 (37,6%) fueron tratados con este método. El seguimiento fue de 48 a 240 meses, y la edad, de  $27 \pm 9$  años; 45% de los pacientes eran mujeres, y 55%, varones, con una relación mujer:hombre de 1,2:1. El hueso más afectado fue la tibia (38%), seguida del fémur (32%), del húmero (16%), y del radio (10%). En 88,6%, la resección fue curetaje intralesional, y el resto, marginal. Hubo 15,7% de casos de TCG con fractura, y recidiva en 12,7%.

**Discusión** Se ha demostrado que este método de tratamiento reduce el riesgo de recurrencia por los efectos adyuvantes locales de la cementación acrílica. La recurrencia ocurre en los dos primeros años de seguimiento. Sin embargo, hay autores que respaldan que el margen quirúrgico es el único factor que influencia el riesgo de recurrencia local. La extensión extraósea del TCG no es contraindicación para curetaje intralesional y adyuvante con metilmetacrilato.

**Conclusiones** Reportamos una tasa de recurrencia similar a la de la literatura, siendo un recurso factible de reconstrucción de miembros.

## Palabras clave

- ▶ tumor de células gigantes
- ▶ tratamiento
- ▶ resección
- ▶ polimetilmetacrilato

## Introduction

Giant cell tumor (GCT) of the bone is a neoplasm of mesenchymal origin that commonly presents as an osteolytic lesion at the epiphyseal-metaphyseal region of long bones. It accounts for more than 20% of all primary bone neoplasms and 5% of primary bone tumors in adults. It typically affects patients aged from 20 to 50 years, with no gender-related differences.<sup>1,2</sup> It is locally aggressive in skeletally-mature patients in more than 80% of cases, and it occurs around the knee in 75% of patients.<sup>2</sup> The distal radius is affected in 10% of 15% of the cases,<sup>3</sup> and this is a site particularly prone to recurrence.<sup>4</sup>

Local recurrence is commonly due to narrow surgical margins.<sup>3</sup>

Several modalities have been used to treat GCTs. However, recurrence rates range from 10% to 54%, reflecting therapeutic efficacy.<sup>5</sup> The optimal treatment for GCTs remains controversial.<sup>6</sup>

The present study aims to identify the recurrence rate of CGT in patients treated with curettage and cementation during a minimum follow-up of 3 years (► **Figure 1**).

## Material and Methods

Retrospective and observational cohort of a registry of patients diagnosed with GCT of any gender and age treated with intralesional curettage and cementation from 1981 to

2011. The cases eligible for this treatment were those in Enneking stages 1 and 2 (with no soft-tissue invasion). Age, gender, anatomical region, recurrence, and mean time until recurrence were identified.

The sampling technique was convenience of consecutive cases.

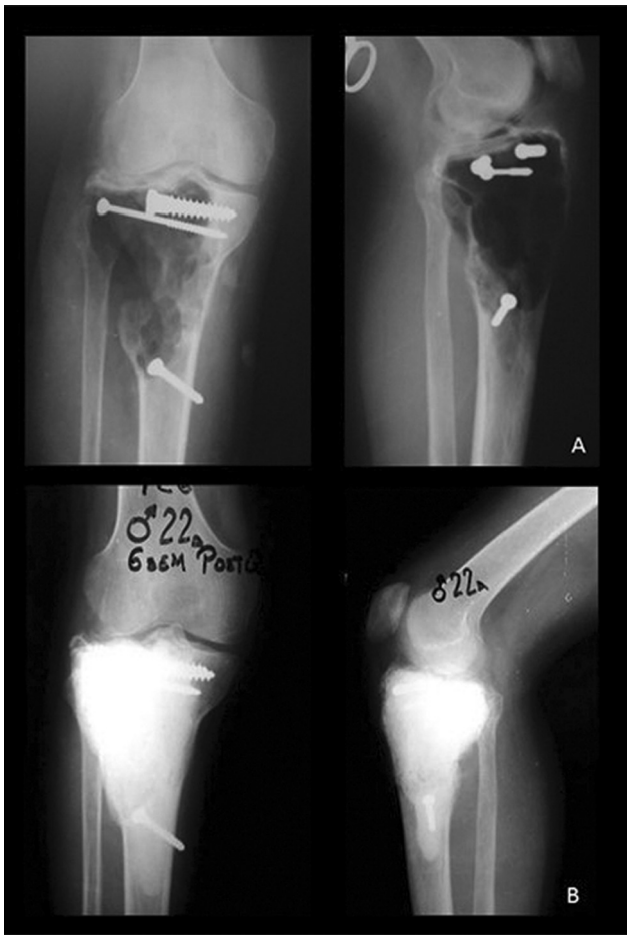Descriptive statistics were used with measures of central tendency (mean, median, and mode) for non-grouped quantitative variables, in addition to dispersion measures (standard deviation). We used descriptive statistics with frequency measures, that is, percentages for qualitative variables. Incidence calculations were performed.

The present article is in accordance with the ethical standards for scientific research on human beings of the Nuremberg Declaration and its amendments. In addition, it is in full compliance with the Regulations of the Mexican General Health Law on Health Research and institutional ethical standards. Informed consent letters were not required since information was obtained from secondary sources.

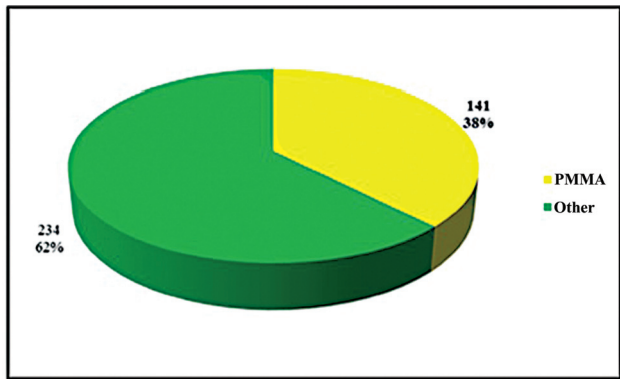
The research team did not receive third party contributions or sponsorships.

## Results

In total, 375 cases of GCT were reviewed. The mean age at presentation was 27 years, (mean:  $27 \pm 11.9$  years; range: 12 to 80 years), with a peak of incidence in the third decade of



**Fig. 1** Trans- and postsurgical exemplification: (A) Transoperative radiograph after intralesional curettage and preparation of the Campanacci stage-II giant-cell tumor cementing bed associated with a pathological fracture of the tibial plateau. (B) Radiograph at 15 years of follow-up with no cement loosening and 6.5-mm screws, without radiographic data indicating recurrence.



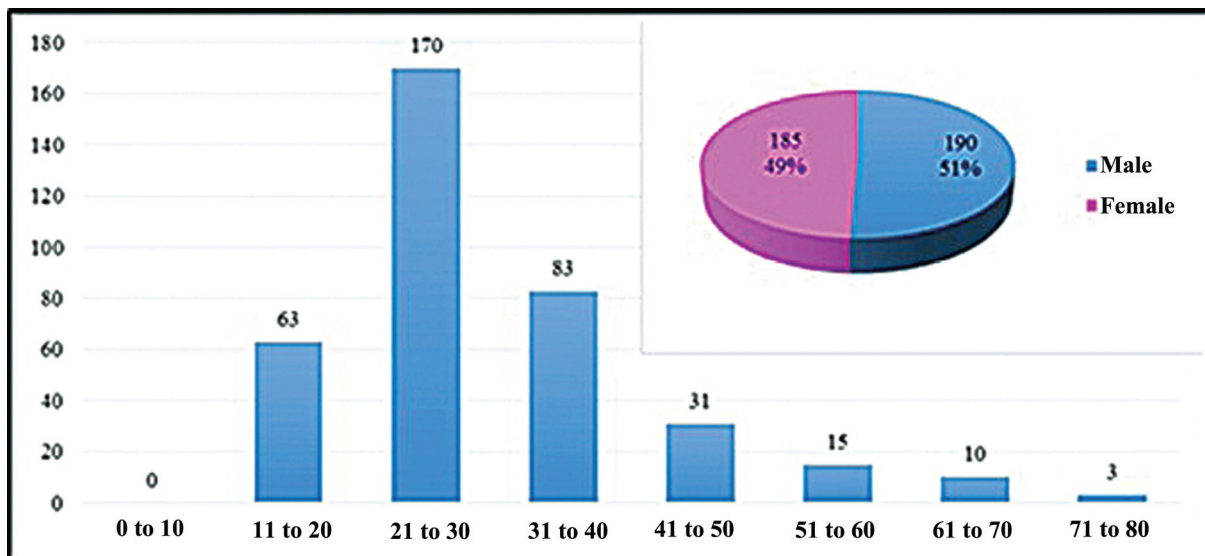
**Fig. 3** Treatment modality for giant-cell tumor. PMMA (polymethyl methacrylate): Curettage and cementation. Other: other treatment modalities.

life (45.33%,  $n = 233$ ). Regarding gender, 190 cases (50.6%) occurred in men, and 185 (49.4%), in women, with a male-to-female ratio of 1.03:1 (► **Figure 2**).

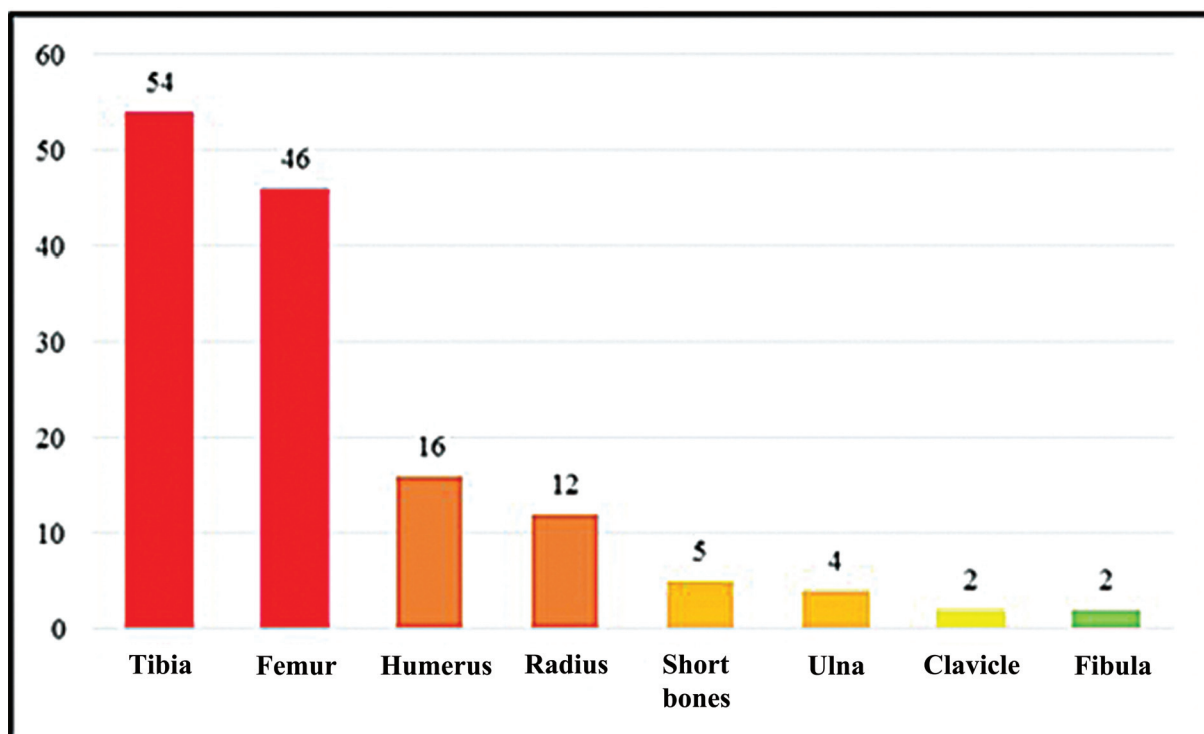
A total of 141 cases (37.6%) were treated by curettage and cementation (► **Figure 3**). The mean follow-up was of 144 months, ranging from 48 to 240 months. In subjects treated with this method, the mean age was  $27 \pm 9$  years (range: 13 to 64 years); regarding gender, 77 (54.6%) cases occurred in men, and 64 (45.4%), in women.

All treated cases occurred in the appendicular skeleton, including 38.3% (54 cases) in the tibia, 32.6% (46 cases) in the femur, 11.3% (16 cases) in the humerus, 8.5% (12 cases) in the radius, 3.5% (5 cases) in short bones, 2.8% (4 cases) in the ulna, 1.4% (2 cases) in the clavicles, and 1.4% (2 cases) in the fibula. Pathological fracture was observed in 22 (15.7%) cases (► **Figure 4**).

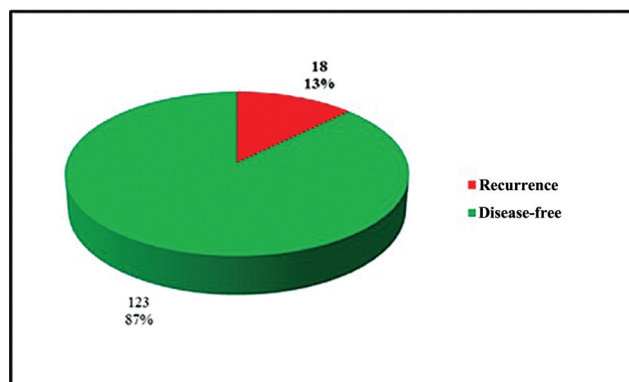
Recurrence occurred in 12.7% (18) of the cases (► **Figure 5**). In total, 16 patients underwent en bloc resection as the surgical treatment, and reconstruction was carried out with resection arthrodesis with an endomedullary nail in 6



**Fig. 2** Distribution of cases of giant-cell tumor regarding age and gender.



**Fig. 4** Sites of anatomical involvement with giant-cell tumor treated by curettage and cementation. Note the higher number of cases in the long bones of the lower limb.



**Fig. 5** Recurrence rate in giant-cell tumor treated with curettage and cementation. No case was submitted to revision curettage and

cases, tumor prosthesis in 9 cases, and external fixation in 1 case; another case underwent a new marginal resection and cementation, and 1 case was not treated due to hematological complications (*coagulopathy*).

## Discussion

The classic treatment for CGTs has been curettage and bone grafting to preserve the function of the adjacent joint.<sup>7</sup> In 1969, Vidal et al.<sup>8</sup> treated 2 cases of GCT with acrylic cement in an attempt to create stability after surgical curettage. Persson et al.<sup>7</sup> treated 14 patients using this method, with a recurrence rate of 15%. This technique is simple, with no

need for bone grafting. In addition, it provides immediate fixation and stabilization, and spares joint function. Disease control is improved, and local recurrence is easy to detect.<sup>5</sup>

Regarding cementation, heat treatment lowers cell viability.<sup>5</sup> Wilkins et al.<sup>9</sup> demonstrated bone necrosis at 60° C. Leeson<sup>10</sup> showed that the polymerization reaction produces necrosis, extending the macroscopic surgical margin and decreasing the probability of recurrence; on the other hand, it releases a toxic monomer.<sup>11</sup> The margins obtained with this technique are between 1.5 mm to 2 mm in cancellous bone and of 0.5 mm in cortical bone.<sup>12</sup>

Another advantage of cementation is the possibility of immediate fixation and stabilization of large defects, especially in load-bearing bones.<sup>5</sup> In contrast, if the construct fails, methyl methacrylate does not prevent other forms of treatment, such as bone grafting or total joint reconstruction.<sup>6</sup>

Currently, there is no consensus on the optimal curettage surgical technique, including adjuvants to limit recurrence, and possibly combined with high-speed reaming to improve the effectiveness of the curettage.<sup>3,13,14</sup>

Most recurrences occur within 2 years of the initial surgery, but can be observed up to 7 years after the surgical treatment.<sup>13</sup>

O'Donnell et al.<sup>16</sup> studied 69 patients and noted a local recurrence rate of 25%, with a mean time until onset of 2 years, regardless of age and gender; the recurrence rate was higher in patients not treated with high-speed ream or phenol application. For Jamshidi et al.,<sup>2</sup> recurrence occurred after a mean time of 30 months (range: 6 to 54 months), with higher rates after simple curettage (33.3%) compared to high-

speed reaming (16.6%); there were no differences regarding cementation, confirming the findings from O'Donnell et al.<sup>16</sup> Zuo et al.<sup>3</sup> demonstrated that this method reduces the risk of recurrence. Bini et al.<sup>6</sup> observed a recurrence rate of 8% in 38 patients. In one case, recurrence was in soft tissues, while the remaining were local, suggesting that the low primary recurrence depends on meticulous and aggressive debridement and on the local adjunctive effects of acrylic cementation.<sup>6</sup> Boons et al.<sup>12</sup> described one case of recurrence in four patients. Becker et al.<sup>14</sup> reported a higher risk of local recurrence in extracompartmental tumors, and this method reduces the risk of local recurrence by 22% compared to simple curettage and bone graft provision. Recurrence-free outcomes were observed in 87% of intracompartmental tumors treated with this method compared to 64% of extracompartmental lesions.<sup>14</sup> Kivioja et al.<sup>17</sup> reported a rate of 19% of local recurrence, including 75% of cases diagnosed within the first 2 years after surgery, and none after 5 years. Gitelis et al.<sup>18</sup> reported recurrences in 12.5% (5) of their patients during a mean follow-up of 58.2 months.<sup>18</sup> Labs et al.<sup>19</sup> reported a local recurrence rate of 13.3% (2 patients), with only one case treated with methyl methacrylate adjuvant. Fraquet et al.<sup>20</sup> studied 30 patients and reported a recurrence rate of 30%, including 77% within the first 2 years of follow-up, and 66% in the distal femur. According to these

authors,<sup>20</sup> the cytotoxic properties of the cement can reduce recurrence from 25% to 17%. Zhang et al.<sup>21</sup> evaluated 101 patients with a recurrence of 12.7%, and concluded that the key aspect is aggressive curettage and the use of cement as an adjuvant. In 91 patients, Balke et al.<sup>22</sup> described recurrences in 27.6% of the patients treated with this method, reducing this possibility by a factor of 8 when compared with isolated intralesional curettage. Portabella et al.<sup>23</sup> treated 10 cases of GCTs with curettage and cementation during a mean follow-up period up of 11 years without observing recurrences; these outcomes were attributed to the surgical technique.<sup>24</sup>

In the Mexican population, Moreno-Wright et al.<sup>11</sup> found a recurrence rate of 25.7% from 6 to 16 months of follow-up, and 1 (2.8%) patient died due to tumor activity, and the remaining subjects were treated with en bloc resection.<sup>11</sup>

Regarding the treatment consisting of intralesional curettage and phenol and methyl methacrylate as adjuvants.<sup>25</sup> Klenke et al.<sup>26</sup> evaluated 41 patients submitted to intralesional curettage treatment, and observed a recurrence rate of 25% and a mean interval of recurrence of 16 ± 12 months; subjects treated with local methyl methacrylate and phenol had a better recurrence-free survival rate (85%) compared to those submitted to a bone graft with the application of phenol (66%); as such, the use of phenol did not improve the recurrence-free rate.<sup>26</sup> Lackman et al.<sup>27</sup> evaluated 63

**Table 1** Details from published series on giant cell tumors and cementation

AUTHOR	YEAR	CASES	FOLLOW-UP (months)	TREATMENT	RECURRENCE
Persson et al. <sup>7</sup>	1984	14	—	MR and PMMA	15.0%
Rock <sup>30</sup>	1990	677	—	Variable	25.5%
O'Donnell et al. <sup>16</sup>	1994	69	48	MR, PMMA, phenol	25.0%
Bini et al. <sup>6</sup>	1995	38	63	MR, PMMA	8.0%
Dreinhöffer et al. <sup>32</sup>	1995	10	—	MR, PMMA	40.0%
Portabella et al. <sup>23</sup>	1998	10	132	MR, PMMA	0.0%
Zhang et al. <sup>21</sup>	1999	101	96	MR, PMMA	12.7%
Labs et al. <sup>19</sup>	2001	11	56	MR, PMMA	13.3%
Boons et al. <sup>12</sup>	2002	4	84	MR, PMMA	25.0%
Moreno-Wright et al. <sup>11</sup>	2003	31	56.5	MR, PMMA	27.5%
Saiz et al. <sup>28</sup>	2004	40	—	MR, PMMA, phenol	12.5%
Gitelis et al. <sup>18</sup>	2005	40	58.2	MR, PMMA	12.5%
Lackman et al. <sup>27</sup>	2005	63	108	MR, PMMA, phenol	5.4%-7.7%
Jamshidi et al. <sup>2</sup>	2008	82	74	MR, PMMA	16.6%
Becker et al. <sup>14</sup>	2008	102	64.2	MR, PMMA	22.0%
Kivioja et al. <sup>17</sup>	2008	194	2.4-216	MR, PMMA	19.0%
Balke et al. <sup>22</sup>	2008	91	12.4	MR, PMMA	27.6%
Fraquet et al. <sup>20</sup>	2009	30	76	MR, PMMA	30.0%
Klenke et al. <sup>26</sup>	2011	41	108	MR, PMMA, phenol	25.0%
Zuo et al. <sup>3*</sup>	2013	374	60-108	MR, PMMA	—
Gao et al. <sup>29</sup>	2014	31	38.8	MR, PMMA	12.9%
Abat et al. <sup>24</sup>	2015	71	144	MR, BG	28.2%

Abbreviations: BG, bone graft; PMMA, polymethyl methacrylate; MR, marginal resection.

Note: \*Systematic review and meta-analysis



patients, and reported a local recurrence rate ranging from 5.4% to 7.7%. Saiz et al.<sup>28</sup> evaluated 40 patients submitted to this type of treatment, and described a recurrence rate of 12.5% in a mean period of 11 months.

Gao et al.<sup>29</sup> reported local recurrence in 12.9% of the cases treated with curettage and cementation, including 81.3% within the first 2 years of follow-up.

In 677 cases treated with intralesional resection and various adjuvants, Rock<sup>30</sup> observed a total recurrence rate of 25.5% in a mean period of 21 months, including 81% of recurrences within the first 3 years of follow-up. McDonald et al.<sup>31</sup> identified the surgical margin as the only factor influencing the risk of local recurrence.

Dreinhöfer et al.<sup>32</sup> reported 10 cases of fracture upon presentation which were treated with curettage and cementation. These authors<sup>32</sup> described a recurrence rate of 20% within the first year of follow-up, and a total recurrence rate of 40%. They recommend this method for pathological fractures.<sup>32</sup> However, O'Donnell et al.<sup>17</sup> reported a recurrence rate of 50% in patients with pathological fractures (► **Table 1**).

According to Lackman et al.,<sup>27</sup> Dreinhöfer et al.,<sup>32</sup> and other authors, the extraosseous extension of a GCT is not a contraindication to intralesional curettage and adjuvant treatment with methylmethacrylate.<sup>26,32</sup>

Using adjuvants, the recurrence rate ranges from 27% to 15% compared to 49% with isolated intralesional curettage.<sup>15</sup> Turcotte<sup>33</sup> reported similar recurrence rates without methyl methacrylate or other adjuvants, contradicting this premise. However, Abat et al.<sup>24</sup> observed a recurrence rate of 28.2% in 71 cases treated with resection and bone grafting in the residual defect, with a mean follow-up time of 12 years.

Gambini et al.<sup>34</sup> reported the use of adjuvant therapy as part of the treatment for GCT. In addition, they described a lower risk of recurrence due to thorough tumor excision, since adjuvants alone cannot prevent recurrence if the tumor is not properly removed.

Some of the recommendations of surgical techniques made by other authors for GCT treatment include adequate exposure, tumor isolation, careful manipulation to avoid soft-tissue contamination, thorough curettage, intracavitary reaming, adjuvant use, and proper bone reconstruction.<sup>35</sup>

## Conclusion

According to the available evidence, in our environment, intracompartmental resection combined with acrylic cementation for the treatment of GCT is a viable option, with recurrence rates consistent with those reported by other authors.

### Conflict of Interests

The authors have no conflict of interests to declare.

## References

- Kafchitsas K, Habermann B, Proschek D, Kurth A, Eberhardt C. Functional results after giant cell tumor operation near knee joint and the cement radiolucent zone as indicator of recurrence. *Anticancer Res* 2010;30(09):3795–3799
- Jamshidi K, Sami S, Modares-Nejad HR, Jhansoz A. Local recurrence in giant cell tumor of bone: Comparative study of two methods of surgical approach. *JRMS* 2008;13(05):223–229
- Zuo D, Zheng L, Sun W, Fu D, Hua Y, Cai Z. Contemporary adjuvant polymethyl methacrylate cementation optimally limits recurrence in primary giant cell tumor of bone patients compared to bone grafting: a systematic review and meta-analysis. *World J Surg Oncol* 2013;11(156):1–7
- Wysocki RW, Soni E, Virkus WW, Scarborough MT, Leurgans SE, Gitelis S. Is intralesional treatment of giant cell tumor of the distal radius comparable to resection with respect to local control and functional outcome? *Clin Orthop Relat Res* 2015;473(02):706–715
- Komiya S, Inoue A. Cementation in the treatment of giant cell tumor of bone. *Arch Orthop Trauma Surg* 1993;112(02):51–55
- Bini SA, Gill K, Johnston JO. Giant cell tumor of bone. Curettage and cement reconstruction. *Clin Orthop Relat Res* 1995;(321):245–250
- Persson BM, Ekelund L, Lövdahl R, Gunterberg B. Favourable results of acrylic cementation for giant cell tumors. *Acta Orthop Scand* 1984;55(02):209–214
- Vidal J, Mimran R, Alliev Y, Goaldard JM. Plastie de comblement par metacrylate méthyle traitement de certaines tumeurs osseuses bénignes. *Montpellier Chir* 1969;15(04):389–397
- Wilkins RM, Okada Y, Sim FH, Chao EYS, Gorgki J. Methylmethacrylate replacement of subchondral bone: a biomechanical, biochemical, and morphologic analysis. In: Enneking WF, ed. *Limb salvage in oncology*. Churchill Livingstone New York 1987:479–485
- Leeson MC, Lippitt SB. Thermal aspects of the use of polymethylmethacrylate in large metaphyseal defects in bone. *Clin Orthop Rel Res* 1993;295:239–245
- Moreno-Wright E, Moreno-Hoyos LF, Técuat-Gómez R, et al. Utilidad del metilmetacrilato en el tumor de células gigantes óseo. *Acta Ortop Mex* 2003;17(06):281–286
- Boons HW, Keijser LC, Schreuder HW, Pruszczynski M, Lemmens JA, Veth RP. Oncologic and functional results after treatment of giant cell tumors of bone. *Arch Orthop Trauma Surg* 2002;122(01):17–23
- Davies AM, Vanel D. Follow-up of musculoskeletal tumors. I. Local recurrence. *Eur Radiol* 1998;8(05):791–799
- Becker WT, Dohle J, Bernd L, et al; Arbeitsgemeinschaft Knochen-tumoren. Local recurrence of giant cell tumor of bone after intralesional treatment with and without adjuvant therapy. *J Bone Joint Surg Am* 2008;90(05):1060–1067
- Frassica FJ, Sim FH, Pritchard DJ, Chao EY. Subchondral replacement: a comparative analysis of reconstruction with methyl methacrylate or autogenous bone graft. *Chir Organi Mov* 1990;75(1, Suppl):189–190
- O'Donnell RJ, Springfield DS, Motwani HK, Ready JE, Gebhardt MC, Mankin HJ, O'Donnell RJ. Recurrence of giant-cell tumors of the long bones after curettage and packing with cement. *J Bone Joint Surg Am* 1994;76(12):1827–1833
- Kivioja AH, Blomqvist C, Hietaniemi K, et al. Cement is recommended in intralesional surgery of giant cell tumors: a Scandinavian Sarcoma Group study of 294 patients followed for a median time of 5 years. *Acta Orthop* 2008;79(01):86–93
- Gitelis S, Saiz P, Virkus W, Piasecki P, Shott S. Functional and oncological outcomes for giant cell tumor treated by intralesional excision with joint preservation. *J Bone Joint Surg [BR]* 2005;87-B: SUPP III
- Labs K, Perka C, Schmidt RG. Treatment of stages 2 and 3 giant-cell tumor. *Arch Orthop Trauma Surg* 2001;121(1-2):83–86
- Fraquet N, Faizon G, Rosset P, Phillippeau J, Waast D, Gouin F. Long bones giant cells tumors: treatment by curettage and cavity filling cementation. *Orthop Traumatol Surg Res* 2009;95(06):402–406

- 21 Zhang Q, Cai Y, Niu X, Hao L. [Curettage plus cement reconstruction for treating giant cell tumor of limbs]. *Zhonghua Wai Ke Za Zhi* 1999;37(12):730-732
- 22 Balke M, Schremper L, Gebert C, et al. Giant cell tumor of bone: treatment and outcome of 214 cases. *J Cancer Res Clin Oncol* 2008;134(09):969-978
- 23 Portabella to the list: Portabella-Blaria F, Illobre-Yebra J, Orduña-Serra M. Tratamiento del tumor de células gigantes mediante legrado y relleno con cemento acrílico. *Revista de Ortopedia y Traumatología* 1996;42:86-90
- 24 Abat F, Almenara M, Peiró A, Trullols L, Bagué S, Gràcia I. Tumor de células gigantes óseo. Noventa y siete casos con seguimiento medio de 12 años. *Rev Esp Cir Ortop Traumatol* 2015;59(01):59-65
- 25 Wang CS, Lou JH, Liao JS, et al. Recurrence in giant cell tumour of bone: imaging features and risk factors. *Radiol Med (Torino)* 2013;118(03):456-464
- 26 Klenke FM, Wenger DE, Inwards CY, Rose PS, Sim FH. Giant cell tumor of bone: risk factors for recurrence. *Clin Orthop Relat Res* 2011;469(02):591-599
- 27 Lackman RD, Hosalkar HS, Ogilvie CM, Torbert JT, Fox EJ. Intralesional curettage for grades II and III giant cell tumors of bone. *Clin Orthop Relat Res* 2005;438(438):123-127
- 28 Saiz P, Virkus W, Piasecki P, Templeton A, Shott S, Gitelis S. Results of giant cell tumor of bone treated with intralesional excision. *Clin Orthop Relat Res* 2004;(424):221-226
- 29 Gao ZH, Yin JQ, Xie XB, et al. Local control of giant cell tumors of the long bone after aggressive curettage with and without bone cement. *BMC Musculoskelet Disord* 2014;15:330
- 30 Rock M. Curettage of giant cell tumor of bone. Factors influencing local recurrences and metastasis. *Chir Organi Mov* 1990;75(1, Suppl):204-205
- 31 McDonald DJ, Sim FH, McLeod RA, Dahlin DC. Giant-cell tumor of bone. *J Bone Joint Surg Am* 1986;68(02):235-242
- 32 Dreinhöfer KE, Rydholm A, Bauer HC, Kricbergs A. Giant-cell tumours with fracture at diagnosis. Curettage and acrylic cementing in ten cases. *J Bone Joint Surg Br* 1995;77(02):189-193
- 33 Turcotte RE. Giant Cell Tumor of Bone. *Orthop Clin N Am* 2006;37:35-51
- 34 Gambini A, Di Giorgio L, Valeo M, Trinchi R, Marzolini M, Mastantuono M. Giant cell tumor of bone: effect of different surgical techniques and adjuvants on local recurrence rate. *J Orthop Traumatol* 2003;3:126-132
- 35 McGough RL, Rutledge J, Lewis VO, Lin PP, Yasko AW. Impact severity of local recurrence in giant cell tumor of bone. *Clin Orthop Relat Res* 2005;438(438):116-122