



# Parachute Method: A Novel Method to Retrieve a Stuck Degloved Finger

Madhu Periasamy Kumanan Asokan Monusha Mohan Vamseedharan Muthukumar  
Hari Venkatramani S. Raja Sabapathy

Department of Plastic, Hand and Reconstructive Microsurgery,  
Ganga Hospital, Coimbatore, Tamil Nadu, India

Indian J Plast Surg 2022;55:307–310.

Address for correspondence S. Raja Sabapathy, MS, MCh, DNB, FRCS (Edin), Hon. FRCS (Glasgow), Hon. FACS, Department of Plastic, Hand and Reconstructive Microsurgery, Ganga Hospital, 313, Mettupalayam Road, Coimbatore, Tamil Nadu, 641043, India (e-mail: rajahand@gmail.com).

## Abstract

An entrapped finger is a relatively uncommon domestic injury. When the finger gets stuck proximal to the proximal interphalangeal joint, the resultant distal edema and inappropriate attempts at retrieval can result in circumferential degloving of the skin and injury to the neurovascular structures. We report a technique that can be used in such circumstances. Strategically placed skin sutures are used to get the skin through the constricting ring, and retrieval is aided by a cut finger glove that wraps the finger and can be lubricated. This non-cutting technique is named as the parachute technique since the withdrawn skin sutures look like the strings of the parachute. This technique is valuable when the finger gets stuck in an idli plate, a common South Indian kitchen utensil, where there is difficulty of access to cutting equipment and where inappropriate attempts at retrieval can result in skin injury making further attempts more difficult.

## Keywords

- ▶ idli plate
- ▶ finger
- ▶ domestic injury

## Introduction

Fingers getting stuck in kitchen utensils, doorknobs, and railings are not uncommon injuries in children. It happens when the edges of the entry point are smooth and the other end is sharp making retrieval difficult. Once the finger gets stuck, the resultant distal edema prevents easy return of the finger. The ill-judged attempts of pulling the finger could result in circumferential degloving and injury to the neurovascular structures. The distal bunching up of the skin and soft tissue makes retrieval almost impossible.

We are reporting a technique for safe retrieval of such fingers stuck in tight rings.

## Case Report

The left index finger of a 4-year-old child was stuck in the central hole of an idli plate (▶ **Fig. 1**). Idli plate is a common

kitchen utensil in South India. The margin of the hole is made of tough stainless steel. This central hole is surrounded by a cup of 3 cm that facilitates the stacking of one plate over another. The cup is soldered to the base plate. This cup-like extension of the utensil restricts access to cutting equipment and makes simple non-cutting removal techniques such as the string wrap,<sup>1–3</sup> elastic pull,<sup>4</sup> or glove pull impossible.<sup>5</sup>

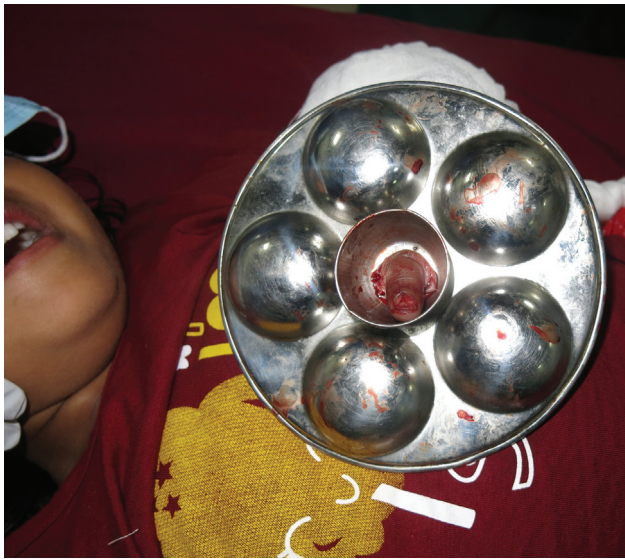The child was taken to a hospital where manipulation to retrieve the finger under local anesthesia resulted in a circumferential skin wound in the middle of proximal phalanx, dividing the dorsal veins, palmar vessels, and nerves.

## The “Parachute Technique”

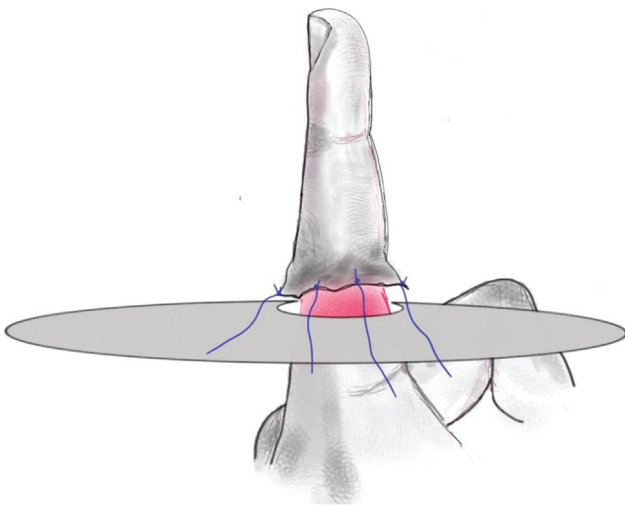
On admission, the child was made pain free with ultrasound-guided axillary nerve block under intravenous sedation.<sup>6</sup> Examination revealed circumferential skin laceration with possible injury to vessels and nerves. The finger was vascular

DOI <https://doi.org/10.1055/s-0042-1744455>.  
ISSN 0970-0358.

© 2022. Association of Plastic Surgeons of India. All rights reserved. This is an open access article published by Thieme under the terms of the Creative Commons Attribution-NonDerivative-NonCommercial-License, permitting copying and reproduction so long as the original work is given appropriate credit. Contents may not be used for commercial purposes, or adapted, remixed, transformed or built upon. (<https://creativecommons.org/licenses/by-nc-nd/4.0/>)  
Thieme Medical and Scientific Publishers Pvt. Ltd., A-12, 2nd Floor, Sector 2, Noida-201301 UP, India



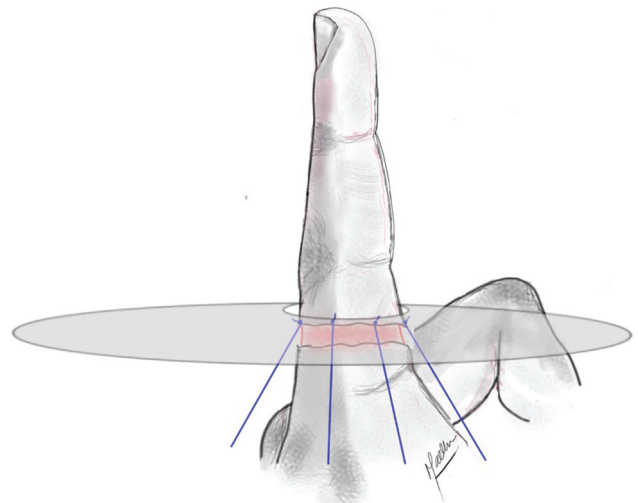
**Fig. 1** Picture of the ring finger stuck in an idli plate with circumferential laceration in the base and venous congestion.



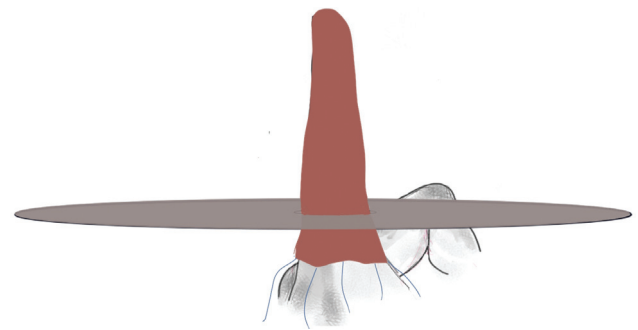
**Fig. 2** Application of thick Prolene sutures to the skin edges.

but congested. There was bunching up of skin distal to the constricting plate.

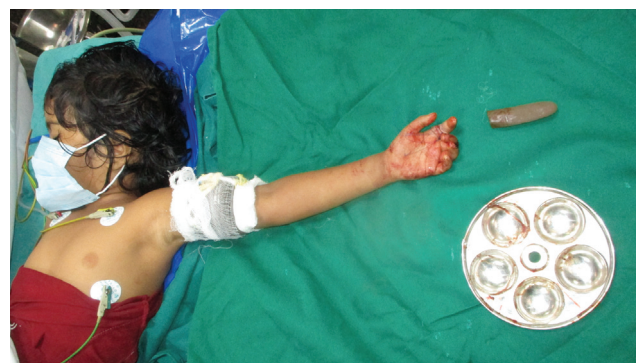A pneumatic tourniquet was applied after good hand elevation. The distal degloved skin edges were tagged with strong 3-0 Prolene horizontal mattress grasping sutures at six points, three over the dorsum and three over the palmar side of the finger and left long (→ **Fig. 2**). Each suture was then passed underneath the ring sequentially and kept on gentle traction with artery forceps. The skin edges were then gently guided beneath the plate until the entire circumference was withdrawn beneath the ring. All sutures were then held on traction like the strings of a parachute (→ **Fig. 3**). To prevent secondary iatrogenic injury, the finger of a surgical glove was cut and placed over the finger, with its base underneath the plate to form a soft shield and edges held with artery forceps (→ **Fig. 4**).



**Fig. 3** Sutures with the skin passing beneath the constricting ring and the skin was brought with traction at the edges.



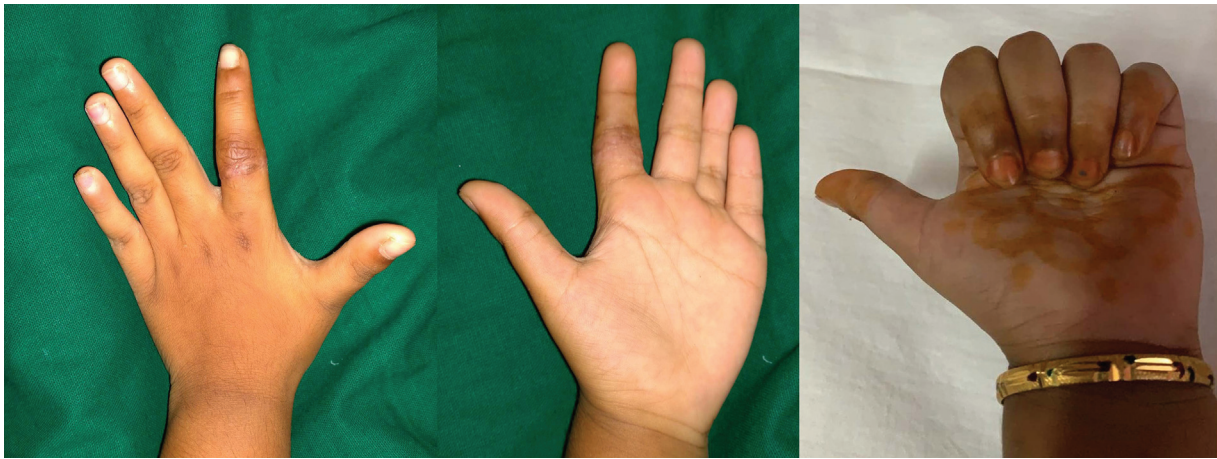
**Fig. 4** Thick surgical glove wrapping the finger and passing beneath the ring.



**Fig. 5** Picture immediately after removal of the plate.

### “Walking” the Idli Plate Out

By maintaining constant traction on the proximal end of the degloved skin and with lubrication around the glove, the plate was slowly and gently walked out by alternative movements of its dorsal and palmar halves. The maneuver done needs patience as it moves only by approximately 0.5 to 1 mm with each attempt. Gentle but firm skin traction is



**Fig. 6** The hand at 10 months follow-up

maintained with the sutures. Once the plate reached the proximal interphalangeal (PIP) joint, it again met with resistance of the bunched up and swollen dorsal skin. This was overcome by gently flexing the PIP joint and walking the dorsal edge of the plate over the joint (► **Supplementary Video 1**, online only). The palmar edge of the plate then slipped out by straightening the finger (► **Fig. 5**).

#### Supplementary Video 1

A short illustrative video demonstrating the “parachute technique.” Online content including video sequences viewable at: <https://www.thieme-connect.com/products/ejournals/html/10.1055/s-0042-1744455>.

After removal of the plate, the wound was explored. Both ulnar and radial digital arteries and nerves were found divided. A branch of the ulnar digital artery maintained distal arterial circulation, but the finger showed venous compromise. Microvascular repair of a dorsal vein was done with 11-0 Ethilon, and the digital nerves were coapted. Skin edges were loosely approximated.

The finger survived, and the patient was discharged after a week. At 10 months follow-up, the finger joints showed full range of motion with a good aesthetic appearance (► **Fig. 6**). She is using the hand for all daily activities, and the parents expressed complete satisfaction with the outcome.

## Discussion

An entrapment injury can be caused by any object which has a hole adequate enough to admit the finger of a child, ranging from the so-called safe plastic toys, kitchen utensils,<sup>7,8</sup> door latches,<sup>9</sup> rubber bands to even toy hair thread. Entrapment usually occurs proximal to the PIP joint which is the point of greatest circumference.

If appropriate retrieval efforts are not made, it results in damage to neurovascular structures and skin. We provide brachial plexus block under sedation or general anesthesia

as the first step. We do not prefer digital blocks. It can cause more local swelling. An unsedated child makes any attempt impossible, and the child’s response can result in further injury. Methods of removal of the trapping object include cutting and non-cutting methods.<sup>9</sup>

Management of idli plate entrapment of the pediatric finger with mechanical cutters has been described.<sup>7,8</sup> They are difficult to sterilize and can cause injuries.<sup>10</sup> Our atraumatic technique is useful when there is distal bunching up of the skin and there are limitations to accessing power tools. This technique also avoids the risk of further injury to both the patient and the “novice” power tool operator—the surgeon. The use of the smooth glove to cover the finger allows us to lubricate it well and helps in walking the plate out of the hand. The use of the glove differs from a previously described technique where it is used for traction.<sup>5</sup> Patience is essential, and this can only be done in a calm child. The same anesthesia is used to debride and repair the damaged structures after the finger retrieval.

## Conclusion

Once degloving of the skin happens in a stuck finger, further attempts result in complicating the procedure. We have described a procedure for getting the damaged skin through the ring with the help of strategically placed skin sutures and the use of a glove to provide a smooth surface to walk the finger out through the ring. Good anesthesia is essential. This technique is called the parachute technique as sutures that come out resemble the side strings of the parachute.

#### Conflict of Interest

None declared.

## References

- 1 Cresap CR. Removal of a hardened steel ring from an extremely swollen finger. *Am J Emerg Med* 1995;13(03):318–320
- 2 Hiew LY, Juma A. A novel method of ring removal from a swollen finger. *Br J Plast Surg* 2000;53(02):173–174
- 3 Mizrahi S, Lunski I. A simplified method for ring removal from an edematous finger. *Am J Surg* 1986;151(03):412–413

- 4 McElfresh EC, Peterson-Elijah RC. Removal of a tight ring by the rubber band. *J Hand Surg [Br]* 1991;16(02):225–226
- 5 Inoue S, Akazawa S, Fukuda H, Shimizu R. Another simple method for ring removal. *Anesthesiology* 1995;83(05):1133–1134
- 6 Sabapathy SR, Venkateswaran G, Boopathi V, Subramanian JB. “On Arrival Block”-management of upper extremity trauma with resuscitation in the operating room. *Plast Reconstr Surg Glob Open* 2020;8(10):e3191
- 7 Patwardhan S, Patwardhan S, Shyam A. Digital strangulation by idli plate/mould. *J Orthop Case Rep* 2017;7:100–101
- 8 Alexander G, Alexander R. An unusual form of ‘finger stuck in a hole’ injury in a child. *Indian J Plast Surg* 2012;45(03):585–586
- 9 Tiwari A, Bhatnagar N, Thora A, Sharma A, Kishan H, Jena S. Finger trapped in door latch removed using an electric saw. A new technique and review of other techniques. *J Clin Orthop Trauma* 2016;7(03):215–217
- 10 Sozbilen MC, Dastan AE, Gunay H, Kucuk L. A prospective study of angle grinder injuries in the hands and forearms during a one-year period. *Hand Surg Rehabil* 2018;37(05):300–304