



# Outcomes Associated with Nasal Reconstruction Post-Rhinectomy: A Narrative Review

Jithin John, BS<sup>1</sup> Rohun Gupta, BA<sup>1</sup> Anne Grossbauer, BS<sup>1</sup> Michael Chung, MD<sup>2</sup> Anita Sethna, MD<sup>3</sup>  
 Michel Abboud, MD<sup>2</sup> Eric Cox, DO<sup>4</sup> Justin Hart, DO<sup>5</sup> Adam Folbe, MD<sup>4</sup> Kongkrit Chaiyasate, MD<sup>5</sup>

<sup>1</sup>School of Medicine, Oakland University William Beaumont School of Medicine, Rochester, Michigan

<sup>2</sup>Department of Otolaryngology, Wayne State University, Detroit, Michigan

<sup>3</sup>Department of Otolaryngology, Emory University, Atlanta, Georgia

<sup>4</sup>Department of Otolaryngology, Beaumont Health Systems, Royal Oak, Michigan

<sup>5</sup>Department of Plastic Surgery, Beaumont Health Systems, Royal Oak, Michigan

Address for correspondence Jithin John, BS, 586 Pioneer Dr, Rochester, MI 48309 (e-mail: jithinjohn@oakland.edu).

Arch Plast Surg 2022;49:184–194.

## Abstract

The face and the external nose define an individual's physical appearance. Nasal deformities can cause facial disfigurement along with unwanted psychological repercussions. Nasal deformities range in severity, with the most severe cases being indications for a rhinectomy, due to the complexity of the nasal defect. According to published literature, there is no consensus among otolaryngologists and plastic surgeons on which technique or flap use is preferred in terms of complications, aesthetic outcome, or patient satisfaction. The goal of this study is to provide a comprehensive analysis of published studies on nasal reconstruction following rhinectomy. Using the Preferred Reporting Items for Systematic Review and Meta-Analysis Protocols guidelines for writing systematic reviews, a systematic review was conducted. Four databases were searched using a search strategy. These articles were then imported into the COVIDENCE software and went screening and thorough article review. After screening 2,237 articles, 23 studies were then extracted for data collection analysis. We collected data from 12 case series, 4 case studies, 1 prospective case series, and 4 retrospective chart review studies. The most commonly reported flaps were forehead flaps, superior extended nasal myocutaneous island, forearm free flaps, anterolateral thigh (ALT) free flap, medial femoral condyle free flap ( $n = 8$ ), and zygomaticus implants ( $n = 6$ ), and retained nasal prosthesis. Although not specifically indicated by a certain number, the most common indication for the rhinectomy was malignancy, followed by traumas, postsurgical complications, radionecrosis, and congenital nasal malformations.

## Keywords

- ▶ rhinectomy
- ▶ nasal reconstruction
- ▶ flaps
- ▶ total reconstruction

DOI <https://doi.org/10.1055/s-0042-1744426>.  
 ISSN 2234-6163.

© 2022. The Korean Society of Plastic and Reconstructive Surgeons. All rights reserved.

This is an open access article published by Thieme under the terms of the Creative Commons Attribution-NonDerivative-NonCommercial-License, permitting copying and reproduction so long as the original work is given appropriate credit. Contents may not be used for commercial purposes, or adapted, remixed, transformed or built upon. (<https://creativecommons.org/licenses/by-nc-nd/4.0/>)

Thieme Medical Publishers, Inc., 333 Seventh Avenue, 18th Floor, New York, NY 10001, USA

Although several donor flaps can be used after rhinectomy, we conclude that there is no preference over what flap has superior patient outcomes after analysis. As of current, there are no prospective studies that exist. Therefore, more research is necessary to determine the results of each flap.

The face and the external nose define an individual's physical appearance. The nose is an essential facial feature key for facial recognition and attractiveness. Nasal deformities can cause facial disfigurement along with unwanted psychological repercussions. The nose is a complex structure that is important in facial aesthetics and respiratory physiology. As a result, nasal imperfections present a challenge to reconstructive surgeons who must recreate a symmetrical nose while maintaining nasal function. Furthermore, a detailed understanding of nasal anatomy and surgical techniques is vital for preoperative analysis and optimal patient outcomes.

The nose is an osteochondral structure covered by a perichondroperiosteal envelope, muscle, and cutaneous covering tissues.<sup>1</sup> The nasal cavity is divided by the nasal septum, which extends from the choanae to the nares.<sup>2</sup> The roof of the mouth forms the inner part of the noseal meatus, which contains the external nostrils. The external nostrils are separated by the nasal septum, which is made of various tissues such as cartilage, bone, and mucous membrane.<sup>2</sup> Mucous membranes and cilia line the nasal passages and aid in filtering air along with the nasal sinuses.<sup>2</sup>

Nasal deformities range in severity, with the most severe cases being indications for a rhinectomy, due to the complexity of the nasal defect.<sup>3</sup> Approximately 2,000 cases of nasal and paranasal cancers are diagnosed every year in the United States,<sup>3</sup> with basal cell and squamous cell carcinoma being the most common etiology.<sup>3,4</sup>

Nasal malignancies are one of the more common indications for a rhinectomy.<sup>4</sup> Although the procedure is relatively straightforward, the resulting central face defect has immense aesthetic implications. For decades, nasal prosthesis devices have been the standard of care.<sup>5</sup> However, surgical advancements have allowed post-rhinectomy patients to have a natural-looking external nose again. The reconstruction of these defects is complex and requires surgical interventions for several hours to days, which may have its complications. Deciding between utilizing a nasal prosthesis or undergoing nasal reconstruction depends on several factors such as patient age, size of defect, past medical and surgical history, patient prognosis, and patient and provider preferences.<sup>6</sup> Several grafts can be used when conducting reconstructive surgery to replace the missing nasal tissue. Some of the grafts used in the literature are rotated frontal flaps or microvascularized free flaps such as auricular, forearm, thigh flaps, or combinations.<sup>4</sup> There are several advantages and disadvantages of receiving flaps compared with nasal prostheses that should be considered. Benefits include better skin color and texture match, which provides a permanent solution for individuals who cannot tolerate or manage prosthetic care.<sup>6</sup> Disadvantages of reconstructive

surgery include increased risk of surgical complications, complications associated with the graft site, expensive care, or even patient dissatisfaction with the outcome.<sup>6</sup>

There are contraindications, and complications are worth mentioning in regards to rhinectomy and reconstructive procedure. Comorbid diseases with a high risk for general anesthesia and indications for nonsurgical treatment should not receive a rhinectomy and are indicated for chemotherapy, radiation therapy, or chemoradiotherapy.<sup>4,6</sup> Patients with metastasis who are in danger of bleeding are more appropriate for palliative care rather than a rhinectomy.<sup>6</sup> Some common complications of rhinectomies include hemorrhage, periorbital hematomas, injuries to the hard palate, or cerebrospinal fluid leak leading to more severe complications such as brain abscess or meningoencephalitis.<sup>6,7</sup>

Currently, there are no reviews or randomized controlled studies to guide the clinical management following rhinectomies. Treatment protocols are based on surgeon preferences, expert opinions, and observational studies. According to published literature, there is no consensus among otolaryngologists and plastic surgeons on which technique or flap is preferred in terms of complications, aesthetic outcome, or patient satisfaction. This study aims to provide a comprehensive analysis of published studies on nasal reconstruction following rhinectomy.

## Methods

This systematic review was conducted using the Preferred Reporting Items for Systematic Review and Meta-Analysis Protocols guidelines for systematic reviews and sent for registration to PROSPERO, The International Prospective Register for Systematic Reviews. The objectives and inclusion/exclusion criteria were recorded before starting the study. Inclusion criteria included studies in which patients required total or subtotal rhinectomy. Papers published before the year 2000, non-English articles, abstracts, letters to editors, and textbook chapters were excluded.

## Search Strategies

A search strategy was used to identify articles pertaining to a total or subtotal rhinectomy and outcomes such as complications and associated procedural effects. The complete search strategy is provided in the index. On September 15, 2021, MEDLINE, COCHRANE, EMBASE, and CINAHL were used to conduct an electronic search on the topics as mentioned earlier.

## Study Selection

After these studies were identified, the COVIDENCE software, an application used for screening and conducting data

extractions for systematic reviews, was used. Two independent reviewers were used, and a separate third reviewer resolved all conflicts after thorough discussion. After all duplicate articles were removed, title and abstract screening were conducted. After removing irrelevant studies, a full-text review was done to ensure papers matched with the inclusion and exclusion criteria.

### Data Extraction

Data extraction was conducted using a spreadsheet. Several data points such as study characteristics (study type, authorship, number of patients in the study, age range [years], and sex), surgery indication, flap details (type of flap and size of flap), procedural information, complications (immediate, long-term, and whether reoperation was needed), outcome (subjective aesthetic outcome and patient satisfaction), and author comments were collected and recorded. The aesthetic result was rated by a reviewer using the before and after pictures. Characteristics such as matching skin color, adequate size, and symmetry were used as criteria to rate aesthetic outcomes. Any information regarding aesthetic outcomes mentioned in the articles was also recorded. This data was then organized into tables and figures. The study type categorized the studies according to the Oxford Centre for Evidence-Based Medicine (OCEBM) levels of evidence.

### Results

The keywords' initial search yielded 2,237 articles after 878 duplicates were removed. After titles and abstract screening were done, 281 articles remained. After the full-text review, 23 studies were extracted for data collection analysis. We collected data from 12 case series, 4 case studies, 1 prospective case series, and 4 retrospective chart review studies (→ Fig. 1).

### Flap/Prosthesis Summary

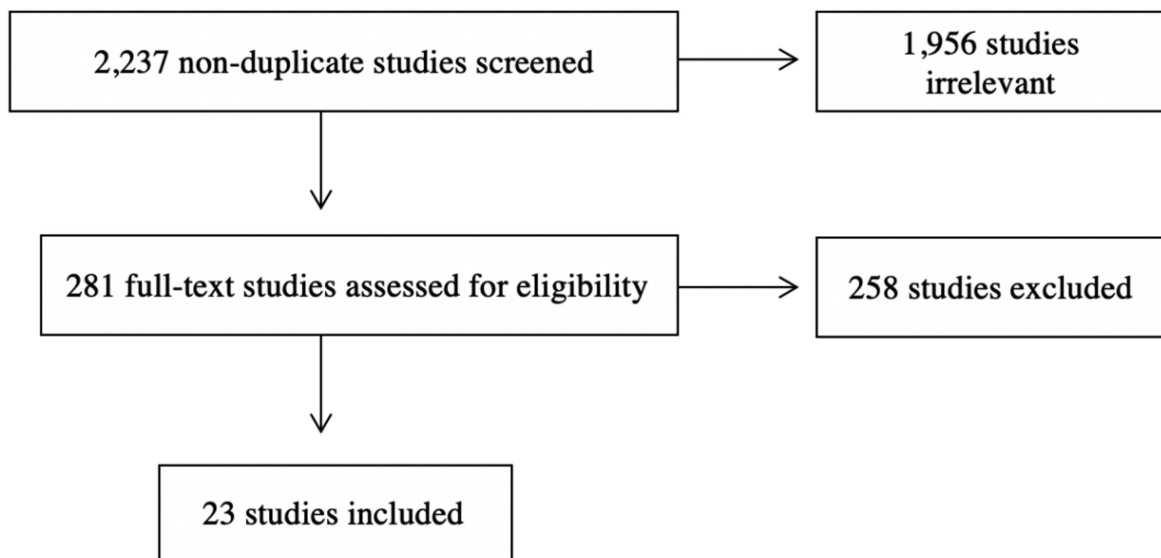
Although reporting of flap details was inconsistent among the studies, available data were still extracted (→ Table 1). The most commonly reported flaps were forehead flaps ( $n = 625$ , bipediced, paramedian, median, nasal turndown, island, nasolabial, and unspecified), superior extended nasal myocutaneous island (SENMI;  $n = 53$ ), forearm free flaps ( $n = 11$ , ulnar and radial), ALT free flap ( $n = 11$ ), medial femoral condyle free flap (MFCFF;  $n = 8$ ), zygomatic implants ( $n = 6$ ), and retained nasal prosthesis ( $n = 1$ ). The most common indication for the rhinectomy was malignancy, followed by traumas, postsurgical complications, radionecrosis, and congenital nasal malformations.

### Aesthetic Outcome and Patient Satisfaction

While all studies provided before and after photos, none of the studies commented on objective data which could be quantified using questionnaires like FACE-Q. It is important to note that the reviewer used these subjective scores based on before and after photos. The aesthetic scores were split into four categories, ranging from poor, fair, good, and excellent. Out of the 23 studies, 5 studies reported good aesthetic outcomes with fair patient satisfaction, 4 studies reported good aesthetic outcomes, 4 studies reported excellent aesthetic outcomes with excellent patient satisfaction, 3 studies reported good aesthetic outcomes with excellent patient satisfaction, and 1 study reported poor aesthetic outcome.

### Complications

Out of the 767 total number cases that received various nasal reconstructions, 731 patients had no complications, 10 cases had blood supply-related complications (ischemia and necrosis), 7 cases had flap failures, 7 cases had infections, 7 cases had structural abnormalities (nostril stenosis,



**Fig. 1** The methodology used for study selection based on the Preferred Reporting Items for Systematic Review and Meta-Analysis Protocols (PRISMA-P) guidelines.

**Table 1** Characterization and type of flap used in each study

Study	Study design	Level of evidence	Technique	Randomization	Blinding
Agostini et al (2013)	Case series	IV	Bipedicled forehead flap	No	No
Ahmadi et al (2017)	Case report	IV	Paramedian forehead flap	No	No
Ahmed et al (2015)	Case series	IV	Median (1) and paramedian (2) flap	No	No
Bashir et al (2013)	Clinical study	IV	Nasal turndown flap and paramedian flap	No	No
Beederman et al (2021)	Retrospective chart review	IIB	Forehead flap and cartilage grafts	No	No
Bowden et al (2006)	Case series	IV	Zygomatic implants	No	No
Boyd et al (2000)	Retrospective case series	IV	Forehead flap	No	No
Cherubino et al (2020)	Case series	IV	Medial femoral condyle flap and paramedian forehead flap	No	No
Giugliano et al (2004)	Case series	IV	Forehead flap	No	No
Hsiao et al (2016)	Case series	IV	Ulnar forearm flap	No	No
Javanmard et al (2020)	Case report	IV	Implanted-retained nasal prosthesis	No	No
Kim and Choi (2021)	Retrospective chart review	IIB	Forehead flap	No	No
King et al (2017)	Case series	IV	Zygomatic implants for nasal prosthesis retention	No	No
Krakowczyk et al (2020)	Retrospective chart review	IIB	Auricular, radial, or combination of both	No	No
Livaoğlu et al (2009)	Case series	IV	Free anterolateral thigh flap	No	No
Ahmadi Moghadam and Ahmadi Moghadam (2017)	Case report	IV	Paramedian forehead flap	No	No
Moore et al (2014)	Case report	IV	Osteocutaneous radial forearm free flap	No	No
Madorsky et al (2020)	Retrospective case series	IV	Superior extended nasal myocutaneous island (SENMI) flap	No	No
Menick (2002)	Case series	IV	Forehead flap	No	No
Paddack et al (2012)	Retrospective chart review	IIB	Paramedial forehead flap or nasolabial flap	No	No
Rosenberg and Gupta (2015)	Case report	IV	Paramedian forehead flap	No	No
Salama et al (2021)	Case series	IV	Prefabricated flaps (paramedian, nasolabial, cheek advancement)	No	No
Seth et al. (2013)	Case series	IV	Free anterolateral thigh fascia lata flap	No	No
Siddiqui and Ditmars (2005)	Retrospective chart review	IV	Island rotation flap	No	No

nasocutaneous fistula, and nasal obstruction), 4 cases had wound healing-related complications (delayed wound healing and wound dehiscence), and 1 case had complications following radionecrosis.

## Discussion

This review of current literature on the outcomes of nasal reconstruction methods following a rhinectomy yielded a total of 23 studies. Commentaries and conclusions of these studies are explained subsequently. Articles are ordered by alphabetical order and by type of publication.

### Case Series (►Table 2)

#### Agostini et al (2013)

This study is a case series looking at seven patients who underwent subtotal rhinectomy for nonmelanoma skin cancer and utilized a bipediced forehead flap for reconstruction. Best indicated for full-thickness nasal defects, this flap technique is a versatile and feasible option for reconstruction. The aesthetic outcomes were acceptable, and surgery was well-tolerated by all patients.<sup>8</sup>

#### Ahmed et al (2015)

This study is a case series looking at three patients who underwent subtotal rhinectomy and utilized a paramedian forehead flap in two patients and a median forehead flap in one patient. Advantages of the forehead flaps include a broad pedicle with a rich vascular supply and an excellent color and texture matching. At the same time, the disadvantages of this technique include the need for a two-stage procedure and additional surgeries for cosmetic outcomes. The results were satisfactory by the patients' standards, and the aesthetic outcome was good.<sup>9</sup>

#### Bowden et al (2006)

This case series looks at two patients who underwent total rhinectomy for squamous cell carcinoma of the nose and received zygomatic implants for total nasal reconstruction. The implants were needed for retention of the nasal prosthesis. The aesthetic outcome was excellent, and both patients were alive and well, with implants functioning satisfactorily for more than 2 years following the procedure.<sup>10</sup>

#### Boyd et al (2000)

This study is a retrospective case series detailing the accounts of 147 patients who experienced subtotal rhinectomy due to nonmelanoma skin cancer. The patients underwent a two-stage procedure using forehead flaps for nasal reconstruction. High aesthetic and functional goals were achieved with this technique.<sup>11</sup>

#### Cherubino et al (2020)

This case series looks at eight patients who went through subtotal rhinectomy due to squamous cell carcinoma and basal cell carcinoma of the nose. The flaps utilized in this study were a combination of MFCFFs and paramedian fore-

head flaps. The authors note that the advantages of these flaps include the ability to reconstruct all three nasal layers with minimal discomfort at the donor site. At the same time, the disadvantages were the necessity for a two-stage procedure and difficulty harvesting the MFCFF.<sup>12</sup>

#### Giugliano et al (2004)

This is a case series looking at 10 pediatric patients under the age of 10 who had subtotal rhinectomy surgeries for various reasons, such as dog bites, nasal malformations, and skin tumors. The flap used for this three-stage nasal reconstruction was the forehead flap. Due to the lack of research on children compared with adults for nasal reconstruction, this study analyzes pediatric patients' unique requirements and considerations.<sup>13</sup>

#### Hsiao et al (2016)

This study is a case series highlighting 10 patients who underwent either subtotal or total rhinectomy for mixed reasons and received ulnar forearm flaps for reconstructive purposes. The ulnar forearm flap was suggested to be an alternative to the radial forearm flap, which has hair and is less aesthetically pleasing. While some immediate surgical complications included infection and partial flap necrosis, all patients were satisfied with the aesthetic and functional results.<sup>14</sup>

#### King et al (2017)

This case series looked at three patients who received zygomatic implants for nasal prosthesis retention following either subtotal or total rhinectomy due to squamous cell carcinoma. Traditionally, nasal prosthesis requires tissue undercuts and adhesives for retention, and in this study, zygomatic implants were utilized. The use of these implants helps to simplify rehabilitation and reduces the need for further surgeries.<sup>15</sup>

#### Livaoğlu et al (2009)

This is a case series describing the use of a free ALT flap in five patients undergoing total nasal reconstruction subsequent to a rhinectomy. The authors describe the strength of using ALT flap includes the decreased morbidity of donor region, the availability of large vessels, reduced bulkiness of the tissue, and aesthetically pleasing result due to the lack of apparent scars. There were also no reported complications either.<sup>16</sup>

#### Madorsky et al (2020)

This is a retrospective case series highlighting 53 patients who underwent subtotal rhinectomy due to carcinoma and scar revision. The flap used in this study is a SENMI flap, which acts as an alternative to the forehead flap and is advantageous because of its potential as a single-stage procedure, minimal to no tissue waste, and the avoidance of temporary visible deformity of the pedicle. The aesthetic outcome was excellent, and the technique was effective.<sup>17</sup>

#### Menick (2002)

This is a case series that includes 90 patients treated with a forehead flap for nasal reconstructive surgery following

**Table 2** Characterization and summary of case series pertaining to nasal reconstruction after rhinectomy

Study	Number of patients	Age at intervention	Surgical indication	Flap utilized	Number of subunits removed	Subtotal or total rhinectomy	Follow-up period	Complications	Outcome
Agostini et al (2013)	7	58–86	Squamous and basal cell carcinoma	Bipedicled forehead flap	1–2 per patient	Subtotal	18–56 mo	None	Good aesthetic outcome
Ahmed et al (2015)	3	25–70	Basal cell carcinoma (Case 1), nevus (Case 2), mistreated abscess (Case 3)	Paramedian forehead flap (Case 1 and 3), medial forehead flap (Case 2)	2	Subtotal	N/A	None	Good aesthetic outcome with fair patient satisfaction
Bowden et al (2006)	2	60–72	Squamous cell carcinoma	Zygomatic Implants	All	Total	> 2 y	None	Excellent aesthetic outcome with excellent patient satisfaction
Boyd et al (2000)	147	29–92	Nonmelanotic skin cancer	Forehead flap	1	Subtotal	4–6 mo	2 patients developed mild superficial partial-thickness necrosis with eventual healing	Excellent aesthetic outcome with excellent patient satisfaction
Cherubino et al (2020)	8	40–73	Squamous and basal cell carcinoma	Medial femoral condyle free flap and paramedian forehead flap	> 2	Subtotal	16 mo	None	Excellent aesthetic outcome with excellent patient satisfaction
Hsiao et al (2016)	10	31–76	Infection, squamous cell carcinoma, trauma, lymphoma, congenital	Ulnar forearm flap	> 2	Subtotal and total	25.2 mo	Infection, partial flap loss, and severe infection	Good aesthetic outcome with fair patient satisfaction
King et al (2017)	3	69–76	Squamous cell carcinoma	Zygomatic implants for nasal prosthesis retention	> 2	Subtotal and total	N/A	Titanium bar fracture soon after placement	Good aesthetic outcome with fair patient satisfaction. One patient struggled psychologically with appearance
Madorsky et al (2020)	53	30–92	Basal cell carcinoma, squamous cell carcinoma, melanoma, Merkel cell carcinoma, scar revision	Superior extended nasal myocutaneous island (SENI) flap	1–2 per patient	Subtotal	N/A	Nasal valve stenosis, partial flap ischemia	Excellent aesthetic outcome
Menick (2002)	90			Forehead flap				Infection	Excellent aesthetic outcome
Siddiqui and Ditmars (2005)	92	68	Squamous and basal cell carcinoma	Island rotation flap	Variable	Subtotal	> 2 y	Flap loss, infection, delayed healing	Excellent aesthetic outcome

(Continued)

**Table 2 (Continued)**

Study	Number of patients	Age at intervention	Surgical indication	Flap utilized	Number of subunits removed	Subtotal or total rhinectomy	Follow-up period	Complications	Outcome
Giugliano et al (2004)	10	1-9	Dog bite, nasal malformation, skin tumors	Forehead flap	1-3	Subtotal	.5-10 y	Nostril stenosis, partial brow flap necrosis	Good aesthetic outcome with fair patient satisfaction
Salama et al (2021)	20	10-72	carcinoma, trauma, burn, human bite, radionecrosis	Prefabricated Flaps (Paramedian, Forehead, Nasolabial, Cheek advancement)	> 1	Subtotal	N/A	wound infection and dehiscence	Good aesthetic outcome with excellent patient satisfaction
Seth et al (2013)	5	54-76	Basal cell carcinoma (2), melanoma (2), squamous cell carcinoma (1)	Anterolateral thigh (ALT)	> 1	Subtotal and total	Variable	None	Good aesthetic outcome with excellent patient satisfaction
Livaoglu et al (2009)	6	54-85	Basal cell carcinoma (4), epidermoid carcinoma (1), malignant fibrous histiocytoma (1)	ALT	> 1	Total	Not stated	None	Good aesthetic outcome with excellent patient satisfaction

rhinectomy. The surgery was broken into three stages with immediate complications of infection. Overall, the forehead flap proved advantageous and achieved near-normal aesthetic results.<sup>18</sup>

**Salama et al (2021)**

This study is a case series highlighting 20 patients who underwent subtotal rhinectomy for various reasons, including carcinoma, trauma, burns, bites, and radionecrosis. The flaps utilized in this study were prefabricated flaps, including paramedian forehead, nasolabial, and cheek advancement. The results from this study suggest that prefabricated flaps can be successful and offer good aesthetic results with minimal complications.<sup>19,20</sup>

**Seth et al (2013)**

This is a case series in which five patients underwent total nasal reconstruction using free ALT fascia lata flaps due to complex nasal lining defects. The advantages of using these flaps include single-stage replacement requiring fewer stages of reconstruction, a thin lining of the donor flap which allows precise airway contouring, decreased donor site morbidity, and pliability and versatility of the donor flap to develop soft tissue or muscle flaps to repair adjacent defects.<sup>21</sup>

**Siddiqui and Ditmars (2005)**

This retrospective case review looks at 92 patients who underwent subtotal rhinectomy following basal cell carcinoma and squamous cell carcinoma. The flap utilized for nasal reconstruction is the island rotation flap, which is advantageous in that it allows for precise positioning and symmetry. This study shows that the island rotation flap is robust, reliable, and offers adequate healing with minimal revision.<sup>22</sup>

**Case Reports (- Table 3)**

**Javanmard et al (2020)**

This is a case report detailing the nasal reconstruction of a 78-year-old male who received implant-retained nasal prosthesis following total rhinectomy from squamous cell carcinoma. The nasal prosthesis was supported by two implants and stabilized with bar and clip attachments. The patient was satisfied with the reconstruction results and did not have any complaints.<sup>5</sup>

**Ahmadi Moghadam and Ahmadi Moghadam (2017)**

This study is a case report detailing the nasal reconstruction of a 28-year-old male who underwent subtotal rhinectomy due to nasal tip traumatic injury. The flap utilized in this case is a paramedian forehead flap, which is advantageous because it matches the skin color and texture of the reconstruction site. The aesthetic outcome of this flap was acceptable, and the authors noted the technique to be reliable and well-established.<sup>23</sup>

**Moore et al (2014)**

This is a case report of a 66-year-old male who received an osteocutaneous radial forearm free flap following subtotal rhinectomy for squamous cell carcinoma. Skin from the donor site was used to recreate nasal lining, the radial bone was used to reconstruct the dorsal contour of the

**Table 3** Characterization and summary of case reports pertaining to nasal reconstruction after rhinectomy

Study	Number of patients	Age at intervention	Surgical indication	Flap utilized	Subtotal or total rhinectomy	Follow-up period	Complications	Outcome	Conclusion
Ahmadi Moghadam and Ahmadi Moghadam (2017)	1	28	Traumatic nasal tip injury	Paramedian forehead flap	Subtotal	3 wk	None	Good aesthetic outcome	Flap matches skin color and texture leading to optimal patient results
Javanmard et al (2020)	1	78	Squamous cell carcinoma	Implant-retained nasal prosthesis	Total	4 wk	None	Excellent aesthetic outcome with excellent patient satisfaction	Implant supported silicone nasal prosthesis showed to be a safe and economical method. Bar and clip attachments were used to retain and enhance stability of the nasal prosthesis, which is preferred over magnetic systems. This is an alternative to microvascular free flaps, which require multiple surgical stages and increase the risk of complications
Moore et al (2014)	1	66	Squamous cell carcinoma	Osteocutaneous radial forearm free flap	Subtotal	1 y	None	Good aesthetic outcome	Flaps can be utilized for full-thickness defects and to recreate nasal lining and reconstruct the dorsal contour of the nose
Rosenberg and Gupta (2015)	1	48	Squamous cell carcinoma	Paramedian forehead flap	Subtotal	2 wk	None	Good aesthetic outcome	Patient had a history of a coagulation disorder and prior pulmonary embolus, which were taken into account in surgical planning. Paramedian forehead flap was used to reconstruct internal nasal lining and rib cartilage grafts were used to reconstruct nasal framework. The paramedian flap's use in resurfacing large nasal defects is "unparalleled" and has excellent vascularity for nasal lining defects



nose, and a paramedian forehead flap was used for external coverage. This study suggests that this technique can yield good aesthetic and functional outcomes.<sup>24</sup>

#### **Rosenberg and Gupta (2015)**

This is a case report of a 48-year-old male who underwent subtotal rhinectomy following squamous cell carcinoma. The paramedian forehead flap was used to reconstruct the internal nasal lining, and rib cartilage grafts were used to reconstruct the nasal framework. The authors declared the use of the paramedian forehead flap as unparalleled and having excellent vascularity for nasal defects.<sup>25</sup>

#### **Patient Chart Review (– Table 4)**

##### **Beederman et al (2021)**

This retrospective chart review highlights the forehead flap technique for nasal reconstruction in 96 patients who underwent subtotal rhinectomy. The purpose of this paper was to compare forehead flap reconstruction in two clinical settings: local anesthesia in an office-based outpatient setting and general or intravenous anesthesia in the operating room. This study shows that nasal reconstruction using forehead flaps can be performed successfully and safely in an outpatient setting.<sup>26</sup>

##### **Kim and Choi (2021)**

This is a retrospective chart review of 36 patients who experienced either total or subtotal rhinectomy for mixed reasons and received forehead flaps for nasal reconstruction. This study aimed to compare the “one nose concept” to the concept that the nose is divided into multiple, individual subunits. The results suggest that total nasal reconstruction using the “one nose concept” can be a successful option.<sup>27</sup>

##### **Krakowczyk et al (2020)**

This study is a retrospective chart review analyzing 48 patients who underwent subtotal or total rhinectomy due to nasal neoplasms. Microvascular-free flaps were used in this study, which included auricular flaps, radial flaps, or a combination of both. This technique achieved functional and aesthetic goals in all patients.<sup>28</sup>

##### **Paddack et al (2012)**

This is a retrospective chart review detailing 107 patients who received either paramedian forehead flaps or nasolabial flaps following rhinectomy for carcinoma and other causes. While complications include flap failure, nasal obstruction, and thick scars, the reconstructive surgeries had a success rate of 94.4%. Comorbidities, such as hypertension, diabetes mellitus, vascular diseases, and smoking habits, were analyzed, and none of these were found to be a statistically significant factor in the failure rate.<sup>29</sup>

#### **Prospective Study (– Table 4)**

##### **Bashir et al (2013)**

This clinical study looked at 18 patients who underwent subtotal rhinectomy due to posttraumatic nasal defects and

utilized a nasal turndown flap for reconstruction with a paramedian forehead flap for resurfacing. The reconstruction used a modified technique for turn-in flaps by lifting the flaps so that well-vascularized tissue was used for the lining. Patient satisfaction had mixed results, and some immediate complications from the surgery included necrosis, graft loss at the donor site, and nostril stenosis.<sup>30</sup>

### **Concluding Remarks**

Several published individual case reports and studies are describing the used flap. However, no comprehensive review exists to our knowledge regarding a summary of all flaps currently used in total nasal reconstruction following a rhinectomy. As of November 2021, most published data on nasal reconstruction use forehead flaps, followed by SENMI, forearm free flaps, ALT free flaps, MFCFF, and zygomatic implants, and retained nasal prosthesis.

Since nasal reconstruction following rhinectomy is a rare procedure and the ethical indications involved in conducting studies, we understand it is difficult to have approved studies. The available literature from our search included retrospective chart reviews, case reports, and case series. Due to this, it is important to recognize the bias in the literature. The data was organized by study type according to the OCEBM level of evidence. After thorough analysis, we found it extremely difficult to compare studies and group them based on data due to the variability, differences in approach, and the preferential qualitative approach as opposed to more quantitative methods used by the studies. Most papers briefly mentioned outcomes related to aesthetics and patient satisfaction; however, they all lacked an objective method to report the results. We recommend future studies report outcomes in a standardized, reliable, and uniform manner.

The purpose of the review was to characterize and identify the outcomes associated with using various flaps for post-rhinectomy patients. The review comprises case series, case reports, patient chart reviews, and a prospective study. Based on the available studies, we observed no preference among types of flaps used in post-rhinectomy patients. Studies demonstrated that the type of flap used depends on several factors, including if one may have cartilage defects, the vasculature of the flap, preferences/skills of the surgeon, clinical indications for repair, surgery technique, etc.,<sup>7,31</sup> with each type of flap having the potential to lead to comparative results and patient satisfaction. Studies are encouraged to use questionnaires like FACE-Q and PSQ-18 (Patient Satisfaction Questionnaire Short-Form).

We also encourage novel research in post-rhinectomy patients, including more prospective data as there is only one study that was found. A recently published review analyzing microsurgical techniques after nasal reconstruction, reported that auricular helical and radial forearm flaps were the most used free flaps, which was inconsistent with this study.<sup>32</sup> These differences are most likely due to variations in inclusion criteria, search terms, and databases used. In one of the analyzed studies, Javanmard et al describe nasal prostheses as a solution to rhinectomy. This is a newly explored avenue

**Table 4** Characterization and summary of prospective study pertaining to nasal reconstruction after rhinectomy

Study	Number of patients	Age at intervention	Surgical indication	Flap utilized	Subtotal or total rhinectomy	Follow-up period	Complications	Outcome	Conclusion
Bashir et al (2013)	18	36 ± 12.24	Posttraumatic nasal defect	Nasal turndown flap and paramedian forehead flap for resurfacing	Subtotal	6 mo	Necrosis (4); graft loss at donor area (1); nostril stenosis (1)	Poor aesthetic outcome	The nasal turndown flap was a reliable method for forming inner lining and allowing for the primary placement of cartilage grafts. Advantageous in that it is not wasteful of residual nasal and forehead skin
Beederman et al (2021)	96	45-92	Skin cancer, trauma, infection	Forehead flap	Subtotal	Complications	Flap loss, necrosis, infection, bleeding	Outcome	Conclusion
Kim and Choi (2021)	36	51.23 (subtotal) and 50.43 (total)	Tumor excision, deformity stemming from cosmetic surgery, trauma	Forehead flap	Both		Wound dehiscence, infection, nascutaneous fistula, nasal stenosis	Excellent aesthetic outcome and good patient satisfaction in patients undergoing total rhinectomy	The forehead flap reconstructive surgery for nasal defects can be performed safely and successfully in an office-based setting with local anesthesia, without increasing the patient's risk for surgical complications
Krakowczyk et al (2020)	48	n/a	Nasal neoplasms	Microvascular free flap (auricular, radial, or a combination of both)	Both		Necrosis	Good aesthetic outcome with medium patient satisfaction	Extensive nasal resections can use radial and auricular flaps
Paddock et al (2012)	107	23-85	Basal cell carcinoma and squamous cell carcinoma	Paramedian forehead (PMFF) or nasolabial flaps (NLF)			Flap failure, nasal obstruction, thick scars	N/A	Overall the interpolation flaps were successful in the reconstruction of nasal defects, with a success rate of 94.4%

that more research needs to be investigated. As technology advances take place, more realistic, natural-looking, and aesthetically well-designed prostheses can be designed.

#### Search Terms

("nasal reconstruction" OR "rhinectomy" OR "Nasal reconstructive surger\*" OR "total nasal recon\*" OR "total nose recon\*" OR "septal reconstruction" OR "epithetic nasal recon\*" OR "nose removal" OR "nose neoplasm" OR "rhinoplasty" OR "nose surgery") AND ("local flap" OR "forehead flap" OR "cartilage graft" OR "free flap" OR "ALT flap" OR "forearm flap" OR "forearm free flap" OR "surgical flap" OR "anterolateral thigh flap" OR "osteocutaneous radial forearm free flap" OR "nasal prost\*")

#### Author Contributions

J.J.: Conceptualization, formal analysis, investigation, methodology, supervision, visualization, writing—original draft, writing—review and editing. R.G.: Corresponding author, formal analysis, investigation, methodology, supervision, writing—review and editing. A.G.: project administration, supervision, visualization, writing—original draft, Writing—review and editing. M.C.: Conceptualization, formal analysis, investigation, methodology, validation, visualization. A.S.: Supervision, validation, writing—review and editing. M.A.: Supervision, validation, writing—review and editing, resources. E.C.: Conceptualization, data curation, investigation, project administration, resources, supervision. J.H.: Supervision, validation, writing—review and editing. A.F.: Supervision, validation, writing—review and editing. K.C.: Supervision, validation, writing—review and editing.

#### Conflict of Interest

None declared.

#### References

- Nguyen PS, Bardot J, Duron JB, Jallut Y, Aiach G. Surgical anatomy of the nose [in French]. *Ann Chir Plast Esthet* 2014;59(06):380–386
- Patel RG. Nasal anatomy and function. *Facial Plast Surg* 2017;33(01):3–8
- Mimica X, Yu Y, McGill M, et al. Organ preservation for patients with anterior mucosal squamous cell carcinoma of the nasal cavity: rhinectomy-free survival in those refusing surgery. *Head Neck* 2019;41(08):2741–2747
- Girardi FM, Hauth LA, Abentroth AL. Total rhinectomy for nasal carcinomas. *Rev Bras Otorrinolaringol (Engl Ed)* 2020;86(06):763–766
- Javanmard A, Mohammadi F, Mojtahedi H. Reconstruction of a total rhinectomy defect by implant-retained nasal prosthesis: a clinical report. *Oral and Maxillofacial Surgery Cases* 2020;6(01):100141
- Hosal SA, Aydin C. 101 - Rhinectomy. In: *Operative Otolaryngology*. 3rd ed. Elsevier Inc.; 2018:674–680.e1
- Ramji M, Kim GY, Pozdnyakov A, McRae MH. Microvascular lining options for subtotal and total nasal reconstruction: a scoping review. *Microsurgery* 2019;39(06):563–570
- Agostini T, Perello R, Russo GL, Spinelli G. Through-and-through nasal reconstruction with the bi-pedicled forehead flap. *Arch Plast Surg* 2013;40(06):748–753
- Ahmed SS, Ghassemi A, Rehman SA, Ansari MK. Forehead flap in maxillofacial surgery: our experiences. *Natl J Maxillofac Surg* 2015;6(01):72–75
- Bowden JR, Flood TR, Downie IP. Zygomaticus implants for retention of nasal prostheses after rhinectomy. *Br J Oral Maxillofac Surg* 2006;44(01):54–56
- Boyd CM, Baker SR, Fader DJ, Wang TS, Johnson TM. The forehead flap for nasal reconstruction. *Arch Dermatol* 2000;136(11):1365–1370
- Cherubino M, Stocco C, Tamborini F, et al. Medial femoral condyle free flap in combination with paramedian forehead flap for total/subtotal nasal reconstruction: level of evidence: IV (therapeutic studies): level of evidence: IV (therapeutic studies). *Microsurgery* 2020;40(03):343–352
- Giugliano C, Andrades PR, Benitez S. Nasal reconstruction with a forehead flap in children younger than 10 years of age. *Plast Reconstr Surg* 2004;114(02):316–325
- Hsiao YC, Huang JJ, Zelken JA, et al. The folded ulnar forearm flap for nasal reconstruction. *Plast Reconstr Surg* 2016;137(02):630–635
- King E, Abbott C, Dovgalski L, Owens J. Orofacial rehabilitation with zygomatic implants: CAD-CAM bar and magnets for patients with nasal cancer after rhinectomy and partial maxillectomy. *J Prosthet Dent* 2017;117(06):806–810
- Livaoglu M, Karacal N, Bektaş D, Bahadır O. Reconstruction of full-thickness nasal defect by free anterolateral thigh flap. *Acta Otolaryngol* 2009;129(05):541–544
- Madorsky S, Do A, Meltzer O. Superior extended nasal myocutaneous island flap: an alternative to forehead flap reconstruction of the nose. *Facial Plast Surg Aesthet Med* 2020;22(04):294–300
- Menick FJ. A 10-year experience in nasal reconstruction with the three-stage forehead flap. *Plast Reconstr Surg* 2002;109(06):1839–1855
- Salama SK, El-Nggar ANM, Basset MSA, Hawass EM, El-Mobark BA. Prefabricated flaps for complex defects nasal reconstruction. *J Aesthet Reconstr Surg* 2021;7(03):1
- Hwas EM, Almubarak BA. Prefabricated flaps for complex defects nasal reconstruction. *Turkish Journal of Physiotherapy and Rehabilitation* 2016;32:3
- Seth R, Revenaugh PC, Scharpf J, Shipchandler TZ, Fritz MA. Free anterolateral thigh fascia lata flap for complex nasal lining defects. *JAMA Facial Plast Surg* 2013;15(01):21–28
- Siddiqui A, Ditmars DM Jr. Island rotation flap for nasal reconstruction. *Plast Reconstr Surg* 2005;116(06):1604–1609
- Ahmadi Moghadam M, Ahmadi Moghadam S. Use of forehead flap for nasal tip reconstruction after traumatic nasal amputation. *World J Plast Surg* 2017;6(03):361–364
- Moore AM, Montgomery J, McMahon J, Sheikh S. Osteocutaneous radial forearm free flap in subtotal nasal reconstruction. *BMJ Case Rep* 2014;2014(nov26 1):bcr2014207147–bcr2014207147
- Rosenberg JD, Gupta N. The paramedian forehead flap for nasal lining reconstruction. *Ear Nose Throat J* 2015;94(03):103–104
- Beederman M, Jaffe J, Kuchta K, Warner J. Office-based forehead flaps: a safe and reliable reconstructive option. *Ann Plast Surg* 2021;86(03):287–291
- Kim MJ, Choi JW. Total nasal reconstruction with a forehead flap: focusing on the facial aesthetic subunit principle. *J Plast Reconstr Aesthet Surg* 2021;74(08):1824–1831
- Krakowczyk Ł, Szymczyk C, Wierzoń J, et al. Microvascular nose reconstruction after extended tumor resection. *Pol Przegl Chir* 2020;92(05):1–7
- Paddack AC, Frank RW, Spencer HJ, Key JM, Vural E. Outcomes of paramedian forehead and nasolabial interpolation flaps in nasal reconstruction. *Arch Otolaryngol Head Neck Surg* 2012;138(04):367–371
- Bashir MM, Khan BA, Abbas M, Khan FA. Outcome of modified turn in flaps for the lining with primary cartilage support in nasal reconstruction. *J Craniofac Surg* 2013;24(02):454–457
- Iorio CB, Christophel JJ, Park SS. Nasal reconstruction: defects that cross anatomical subunits. *Facial Plast Surg* 2020;36(01):91–101
- Gasteratos K, Spyropoulou GA, Chaiyasate K, Siotos C, Vlachopoulos N, Friedstat J. Microsurgical techniques and postoperative outcomes after total and subtotal nasal reconstruction: a systematic review. *Ann Plast Surg* 2021. Doi: 10.1097/SAP.0000000000003032