



Anterior Cranial Base Reconstruction in Complex Craniomaxillofacial Trauma: An Algorithmic Approach and Single-Surgeon's Experience

Sameer Shakir, MD¹ Elizabeth B. Card, MD¹ Rotem Kimia, BS¹ Matthew R. Greives, MD, MS²
Phuong D. Nguyen, MD²

¹Perelman School of Medicine, University of Pennsylvania, Philadelphia, Pennsylvania

²Division of Plastic Surgery, McGovern Medical School, University of Texas Health Science Center at Houston, Houston, Texas

Address for correspondence Phuong D. Nguyen, MD, FACS, FAAP, Division of Plastic Surgery, McGovern Medical School, University of Texas Health Science Center at Houston, 6410 Fannin Street, Suite 1400, Houston, TX 77030 (e-mail: pdnguyendoc@gmail.com).

Arch Plast Surg 2022;49:174–183.

Abstract

Management of traumatic skull base fractures and associated complications pose a unique reconstructive challenge. The goals of skull base reconstruction include structural support for the brain and orbit, separation of the central nervous system from the aerodigestive tract, volume to decrease dead space, and restoration of the three-dimensional appearance of the face and cranium with bone and soft tissues. An open bicoronal approach is the most commonly used technique for craniofacial disassembly of the bifrontal region, with evacuation of intracranial hemorrhage and dural repair performed prior to reconstruction. Depending on the defect size and underlying patient and operative factors, reconstruction may involve bony reconstruction using autografts, allografts, or prosthetics in addition to soft tissue reconstruction using vascularized local or distant tissues. The vast majority of traumatic anterior cranial fossa (ACF) injuries resulting in smaller defects of the cranial base itself can be successfully reconstructed using local pedicled pericranial or galeal flaps. Compared with historical nonvascularized ACF reconstructive options, vascularized reconstruction using pericranial and/or galeal flaps has decreased the rate of cerebrospinal fluid (CSF) leak from 25 to 6.5%. We review the existing literature on this uncommon entity and present our case series of $n = 6$ patients undergoing traumatic reconstruction of the ACF at an urban Level 1 trauma center from 2016 to 2018. There were no postoperative CSF leaks, mucocèles, episodes of meningitis, or deaths during the study follow-up period. In conclusion, use of pericranial, galeal, and free flaps, as indicated, can provide reliable and durable reconstruction of a wide variety of injuries.

Keywords

- ▶ anterior cranial fossa
- ▶ cranial base
- ▶ craniofacial trauma
- ▶ skull base reconstruction
- ▶ pericranial flap
- ▶ titanium mesh cranioplasty

Injury to the upper third of the craniofacial skeleton can have devastating consequences, particularly with intracranial extension. Of the 30 million trauma-related hospital visits reported annually in the United States, 16% relate to head

injury resulting in traumatic brain injury (TBI).¹ Further stratification of head injuries reveals a 12% rate of skull base fractures, most commonly encountered after motorized vehicle collisions or other blunt trauma.^{1–3} These injuries carry

DOI <https://doi.org/10.1055/s-0042-1744406>.
ISSN 2234-6163.

© 2022. The Korean Society of Plastic and Reconstructive Surgeons. All rights reserved.

This is an open access article published by Thieme under the terms of the Creative Commons Attribution-NonDerivative-NonCommercial-License, permitting copying and reproduction so long as the original work is given appropriate credit. Contents may not be used for commercial purposes, or adapted, remixed, transformed or built upon. (<https://creativecommons.org/licenses/by-nc-nd/4.0/>)

Thieme Medical Publishers, Inc., 333 Seventh Avenue, 18th Floor, New York, NY 10001, USA

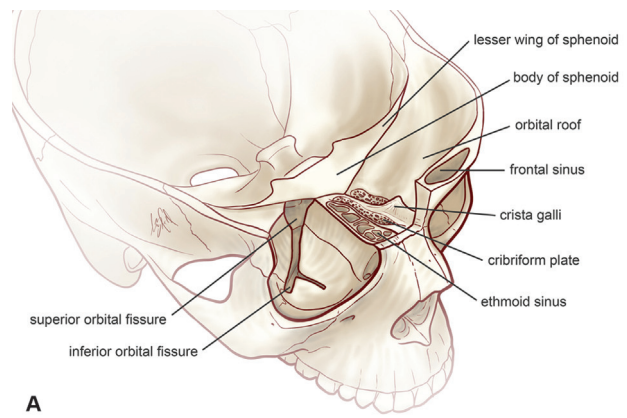
significant morbidity including infection, fistula, injury to the cranial neurovasculature, and cerebrospinal fluid (CSF) leak, occurring in nearly 25% of cases.³ While minor fractures may obviate surgical intervention, major trauma with potential for adverse functional and/or aesthetic outcomes often require interdisciplinary operative collaboration between neurosurgery, otorhinolaryngology, and plastic surgery.

Management of skull base fractures and associated complications pose a unique reconstructive challenge. While endoscopic techniques have gained popularity in recent years for resection of tumors of the cranial base, posttraumatic reconstruction often requires an open approach, which is historically linked to high rates of morbidity and mortality.^{4,5} As stated by Pusic et al, the goals of skull base reconstruction include: (1) structural support for the brain and orbit, (2) separation of the central nervous system (CNS) from the aerodigestive tract, (3) lining for the nasal cavity, (4) reestablishment of the nasal and oropharyngeal cavities, (5) volume to decrease dead space, and (6) restoration of the three-dimensional appearance of the face and cranium with bone and soft tissues.⁶ Depending on the size of the defect and extent of injury, this may require pedicled local muscle flaps and/or fascial flaps with free tissue transfer. Reconstruction requires extensive knowledge of the anatomic relationships of the skull base to the underlying meninges and neurovasculature, as well as the variety of available treatment modalities.

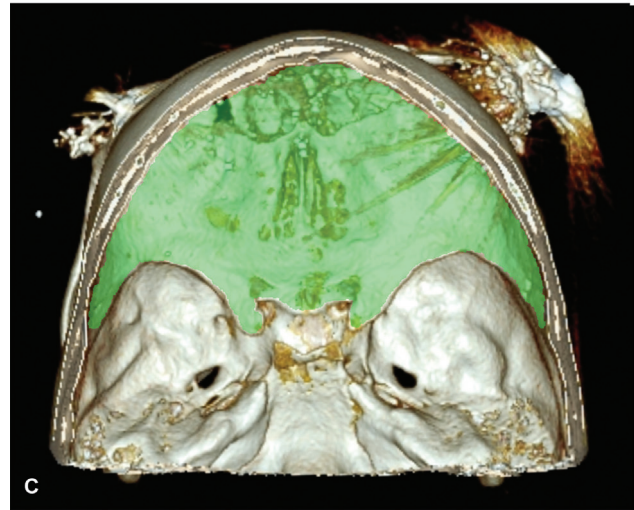
Anatomy and Classification

The anterior cranial fossa (ACF) contains the frontal lobes of the cerebral cortex and is comprised of the orbital portion of the frontal bone, the cribriform plate of the ethmoid bone, and the anterior portion of the body and lesser wing of the sphenoid bone (→Fig. 1A–C).^{7,8} The frontal bone separates the intracranial contents from the frontal sinus and orbital roof, while the cribriform plate separates the intracranial contents from the ethmoid sinus. Open approaches to the ACF often traverse the middle cranial fossa, which includes the sella turcica, tuberculum sellae, and clivus, among other associated structures.⁴

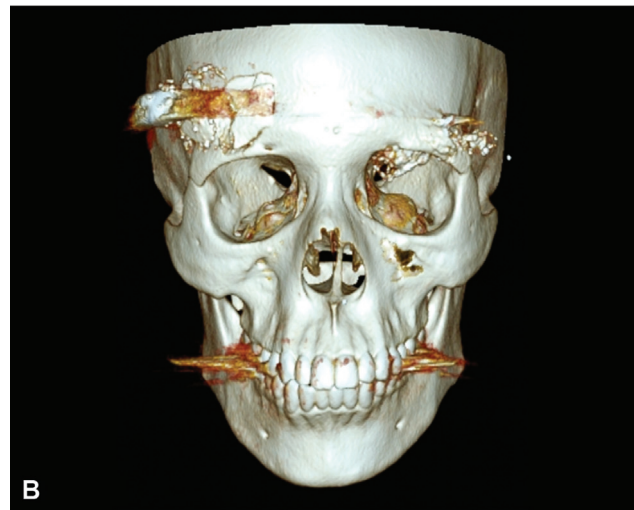
Multiple neurovascular structures course within and through the ACF. The median ridge of the cribriform plate—termed the crista galli—forms the anterior attachment of the falx cerebri, which contains the superior sagittal sinus. The cribriform plate contains the olfactory groove supporting the olfactory bulb, as well as multiple neural perforations through the bony structure which transmit olfactory nerves (CN I) into the sinonasal cavity. The anterior and posterior ethmoidal foramina transmit the anterior and posterior ethmoidal neurovascular structures. At the articulation of the ethmoid and frontal bones, the foramen cecum transmits the nasal emissary vein to the superior sagittal sinus. Bounded laterally by the lesser wings of the sphenoid, the optic canal carries the optic nerve (CN II), the ophthalmic artery, and associated sympathetic fibers into the orbital cavity. The sphenoid also forms the borders to the superior and inferior orbital fissures, which transmit the oculomotor (CN III), trochlear (CN VI), ophthalmic division of trigeminal (CN V1), and



A



C



B

Fig. 1 Anatomic representation of the anterior cranial fossa (ACF). (A) Cross-sectional three-dimensional representation of ACF anatomy. (B, C) 3D computed tomography head of a patient with a gunshot wound to the R temple resulting in injury to the ACF (green).

abducens (CN VI) cranial nerves in addition to the superior and inferior divisions of the ophthalmic vein.

Trauma from anteriorly or laterally directed forces may cause bony fracture of the ACF. A classification schema proposed by Archer et al characterized fractures of the ACF according to extension of the defect past the frontal

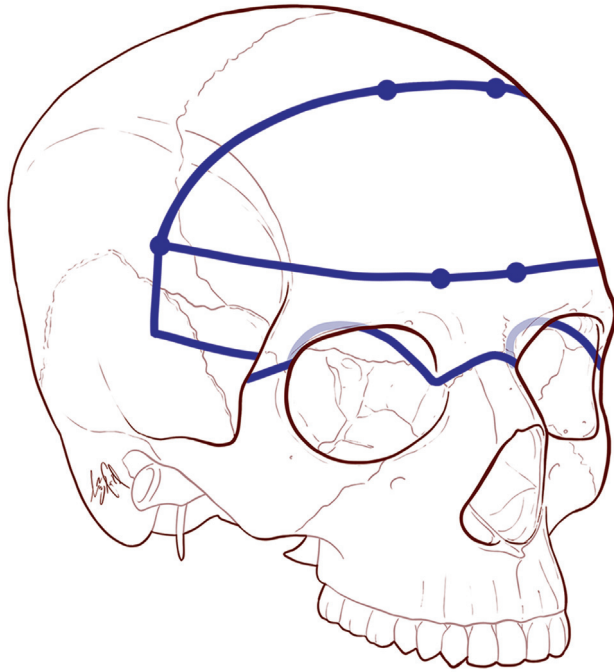


Fig. 2 Surgical approach to the anterior cranial fossa. Schematic representation of frontal craniotomy and frontal bandeau (blue) used to access the anterior cranial fossa after standard bicoronal scalp incision.

sinus: Class I fractures are limited to the anterior and posterior tables of the frontal sinus; Class II fractures extend through the ethmoid; and Class III fractures further extend through the frontal bone, orbits, orbital roof, and sphenoid.⁹ Alternatively, Yano et al proposed a classification of ACF defects based on anterior and/or middle cranial fossa involvement with further subclassification as either (1) localized, (2) horizontal extension, or (3) vertical extension.¹⁰ Greater traumatic extension of the ACF defect (i.e., higher classification) is increasingly associated with CSF leak. Orbitocranial involvement and extension of the defect horizontally into the orbital roof or vertically into the sinonasal cavity are also associated with higher morbidity and mortality.^{9,10}

Surgical Approaches

In the management of traumatic ACF fracture, an open bicoronal approach is the most commonly used technique for craniofacial disassembly of the bifrontal region, with evacuation of intracranial hemorrhage and dural repair performed prior to reconstruction.^{3,8,11} The bicoronal transfrontal technique employs an anterior approach, with elevation of a subgaleal or subperiosteal scalp flap to the periorbital rims. This is followed by frontal craniotomy, exposing the sinonasal cavity, epidural space, and intracranial anterior fossa compartment (►Fig. 2).^{11–13} Bicoronal scalp incision must be planned to preserve and maximize the use of local flaps (e.g., pericranial, galeal), while preserving adjacent vasculature for potential free

flap recipient anastomosis.¹⁴ As a modification to the classically described straight-line pretrichial bicoronal incision, we advocate for a modified zigzag incision beginning immediately above the helical root and veering posterior to avoid injury to the superficial temporal vessels. This approach maximizes exposure of the frontal bone and preserves local vascularized pedicled flap options, such as the pericranial and galeal flaps.¹² Transfrontal exposure, however, offers limited access to the sphenoid bone and requires extensive frontal lobe retraction, which may result in brain contusion and increased risk of meningitis. Various modified approaches have consequently been developed.

The basal subfrontal approach combines additional osteotomies with the frontal craniotomy to mediate removal of the supraorbital bar, thereby mitigating some of the limitations associated with the transfrontal approach.^{11,15} The planned craniotomy extends through the anterior and posterior tables of the frontal sinus. In defects involving the orbits or cribriform plate, additional nasal osteotomies may be performed along the nasolacrimal suture lines. The roof and lateral walls of the orbits may be removed with dural dissection and orbital osteotomy.^{15,16} The basal subfrontal approach to the ACF offers minimal brain retraction by providing wider floor exposure, but may result in worse structural outcomes due to extensive skeletal involvement, which may increase the risk for osteomyelitis.^{15,16}

Based on Paul Tessier's description of the frontal bandeau, the subcranial (i.e., Raveh) approach allows for removal of the frontal bone and supraorbital bar in continuity while avoiding transfrontal incisions.¹⁷ Raveh's approach involves subgaleal elevation of a pretrichial bicoronal scalp flap beyond the supraorbital ridges anteriorly and to the temporalis fascia laterally.^{8,11,15,16} Osteotomies are made through the anterior and posterior walls of the frontal sinus, the proximal segment of the nasal bone, and the medial wall of the orbit. The fronto-naso-orbital segment is extracted en bloc, followed by bilateral sphenoidotomy and ethmoidectomy, providing ACF exposure.^{15,16} Hemicoronal, supraorbital, and temporal incisions have also been described in the literature, but are less frequently used.^{11,13,16} Additional access incisions may include existing scars, lacerations from large scalp wounds, and neurosurgical incisions from concurrent hematoma evacuation.

Reconstructive Options

Prerequisites for successful ACF reconstruction include (1) separation of the intracranial contents from the nasopharynx, the paranasal sinuses, and the orbit, (2) watertight dural reconstruction, and (3) support of the brain tissue.¹⁸ Reconstruction of bony and soft tissue defects requires highly vascularized tissue that will achieve these reconstructive goals. Historic neurosurgical reconstruction of skull base defects has involved various nonvascularized tissues including fascia lata, muscle, and fat, and synthetic materials including cellulose or dura allograft—all of which may lead to tissue

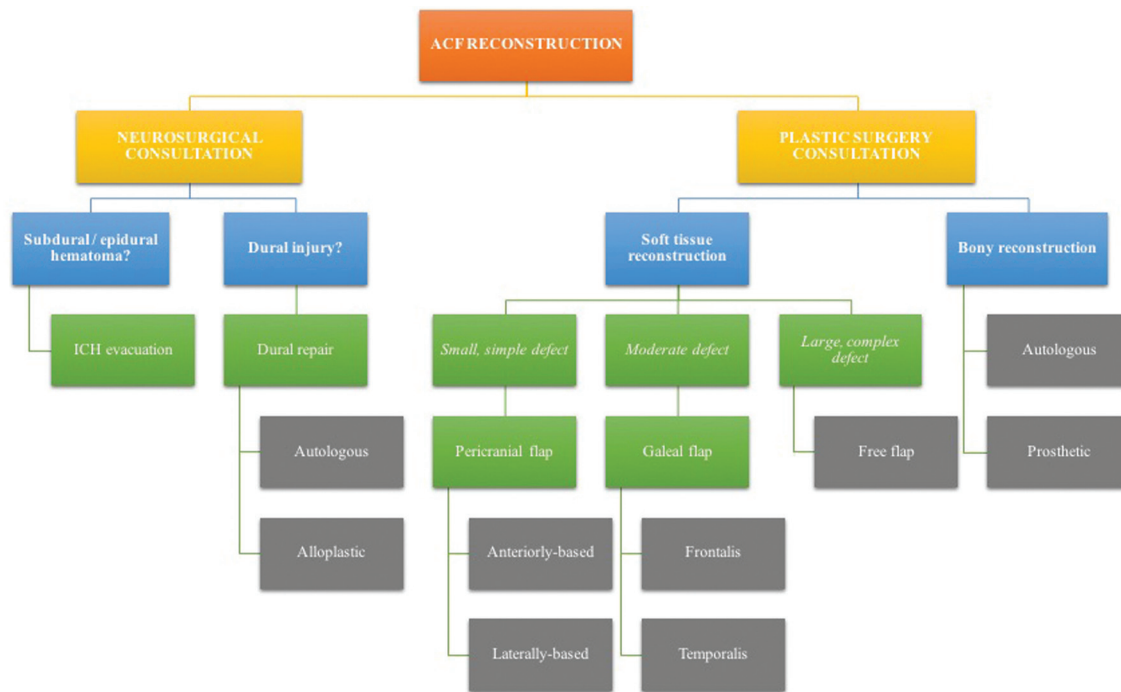


Fig. 3 Algorithmic approach to anterior cranial fossa (ACF) reconstruction. Initial patient presentation requires emergent evaluation by neurosurgery to determine acute need for evacuation of intracranial hemorrhage and/or subsequent dural repair. Subsequent reconstruction of the ACF defect depends on the specific soft tissue and bony deficit. To hermetically seal defects of small to moderate sizes, a pericranial or galeal flap may be utilized. Larger defects or complex defects requiring multiple tissue types may require sophisticated free tissue transfer including chimeric flap options. Bony reconstruction of ACF defects may be performed using autologous sources such as split cranial bone graft (preferred) or prosthetic materials including titanium mesh. Together, the ACF reconstruction aims to provide structural support to the brain while separating the intracranial and extracranial contents to prevent ascending infection.

necrosis, CSF leak, and infection.¹⁴ The introduction of local and free vascularized tissues has dramatically reduced the resultant morbidity and mortality previously associated with these defects.^{19–22}

We generally adhere to the simplified algorithm for ACF reconstruction proposed by Georgantopoulou et al, in which defect size and patient factors dictate reconstructive options (→**Fig. 3**).¹⁴ The central tenet to this approach is that patients presenting with communication of intra- and extracranial contents undergo some form of vascularized tissue reconstruction. Mitigating factors include previous radiotherapy which may require reconstruction with distant vascularized free tissue transfer, or previous cranial surgery which may preclude pericranial-based reconstruction. Secondary options include galeal or thin free flaps to reconstruct moderately sized defects, while free tissue transfer is indicated for reconstruction of larger defects.

Bony Reconstruction

Bony reconstruction of ACF defects remains somewhat controversial. For small to moderate defects up to 30 cm², Yamamoto et al argued against vascularized or nonvascularized bony reconstruction, as they observed increased postoperative infectious complications in their 10 patient case series likely related to dead space creation.¹⁸ Instead, they advocated for

vascularized soft tissue reconstruction with a flap of sufficient volume to mitigate CSF leak, infectious, and brain herniation concerns. Snyderman et al further substantiated these claims by suggesting bone grafts may delay healing by hindering coaptation of the dura to the overlying vascularized soft tissue reconstruction.²³ Nevertheless, large bony defects of the cranial base with comminuted fractures require reconstruction with rigid materials to prevent brain herniation (i.e., meningoencephalocoele) and/or pulsatile exophthalmos. Bone grafts, most commonly split-thickness cranial bone, is advocated; however, harvesting and fixating split-thickness cranial bone requires familiarity with technique and may be time-consuming.^{24,25} Allografts, bioengineered implants including porous polyethylene, and titanium mesh are alternative options and offer availability, easy contouring, and stability. These may be useful adjuncts if viable autograft options are limited or in situations where the defect is too large to fill with autograft alone.^{6,20,26–30} These avascular tissues may pose a higher risk of postoperative infection, but concomitant use of vascularized soft tissue augmentation with a pericranial flap, for example, may lessen these complications.³⁰ For complex defects requiring vascularized soft tissue and bone, there may be an indication for chimeric free flaps using rib, scapula, both rib and scapula, or ilium.^{31,32} In these high-risk situations, bone may be used for separation, muscle for fill, and skin for coverage. Additionally, vascularized duraplasty may be performed using serratus anterior fascia, for example, as a

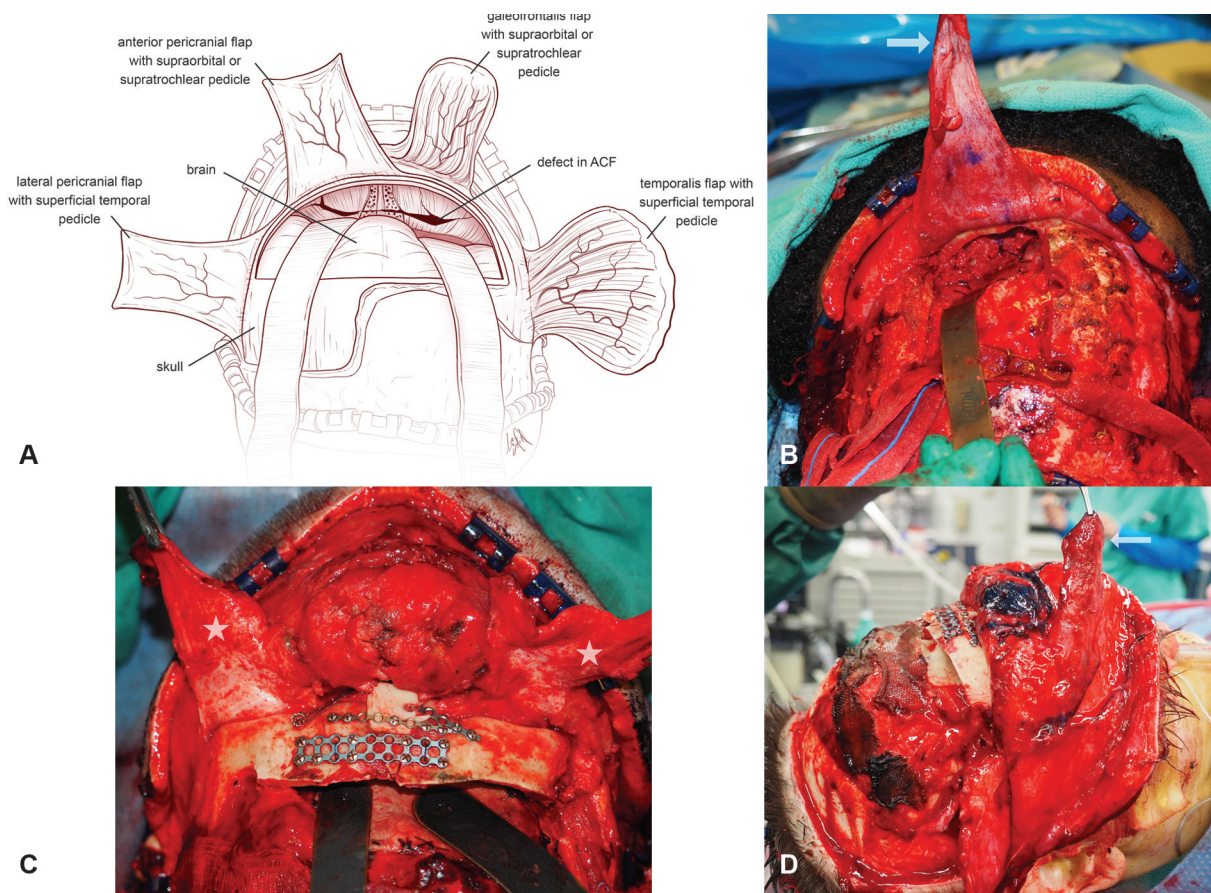


Fig. 4 Pericranial and galeal-based muscle flaps. (A) Schematic representation of local flap options for anterior cranial fossa (ACF) reconstruction. (B) A conventional anteriorly based pericranial flap elevation (arrow). (C) Given the zone of injury to the central forehead, laterally based pericranial flap were elevated (arrows) in this specific case. (D) Elevation (arrow) and inset of a right-sided galeal-frontalis flap.

component of the chimeric flap. It is essential to ensure that direct communication with nonvascular allografts or implants and sinuses be prevented to mitigate infectious risk. To further separate the intra- and extracranial contents and risk for ascending infection, the frontal sinuses are typically cranialized, nasofrontal ducts plugged with bone graft or autologous fat, and sinuses covered with a pericranial flap. Rigid fixation using plates and screws further stabilizes the skeleton in its normal position.

Local Vascularized Options

The vast majority of traumatic ACF injuries resulting in smaller defects of the cranial base itself can be successfully reconstructed using local pedicled pericranial or galeal flaps. These local pedicled options may obviate the need for distal pedicled or free tissue flaps in the absence of significant skin defects.^{6,29} Typically based anteriorly on the deep supraorbital and supratrochlear vessels, the pericranial flap can be used for soft tissue reconstruction of the entire ACF and can be readily accessed during bicoronal transfrontal exposure.³³ When anterior vascularity has been compromised, wide temporally based pericranial flaps supplied by the superficial temporal artery may also be used. We prefer the pericranial flap for its easy

access, wide surface area, significant length, and reliable vascularity. The pliability of the pericranial flap offers excellent reconstruction of dural defects, as well (► Fig. 4).^{6,15} The galeal flap, which is thicker yet equally pliable, may be anteriorly based (galeofrontalis), posteriorly based (galeo-occipitalis), or laterally based (galeotemporalis) off the superficial temporal vessels (► Fig. 4). The posteriorly based galeal flap cannot reliably reach the ACF, but anteriorly or laterally based flaps serve as durable, pedicled options for reconstruction. Some authors have advocated for the use of bipedicled galeal flaps based on bilateral superficial temporal vessels to avoid the inherent midline watershed zone of unipedicled flaps.¹⁴ Variations of the galeal flap, which include the galeotemporalis muscle flap, may augment defects that require greater bulk to fill dead space. Supplied by branches of the external carotid, the galeotemporalis muscle flap may be harvested with an osseous component to provide vascularized autologous bony reconstruction. Similar to the galeal flap, however, it has limited mobility and cannot adequately reconstruct midline or paramedian defects.^{15,29,34} Harvest of the galeofrontalis or galeotemporalis flaps may lead to poor cosmesis with donor site concavity. With all local pedicled flaps, we utilize fibrin glue to provide a watertight seal of the reconstructed cranial base.

Free Tissue Transfer

In cases with extensive skin and soft tissue involvement, most commonly in the setting of cancer resection rather than trauma, distant pedicled or free flaps may be utilized.^{6,27,29,31} Distal pedicled flap options include pectoral, trapezius, latissimus dorsi, and sternocleidomastoid flaps. Free flap reconstruction provides reliable, robust soft tissue to seal the dura, obliterate dead space, cover exposed cranial bone, and provide cutaneous coverage for skin or mucosa.⁶ Commonly utilized free flaps include the rectus abdominis, latissimus dorsi, anterolateral thigh, and the radial forearm flaps. When harvested as a chimeric flap for complex wounds requiring multiple tissue types, these flaps may be utilized for bony separation, soft tissue bulk, coverage, and lining. In general, free flaps are less restricted than distant pedicled flaps in which the distal most aspect is the least reliable portion, yet where viability is the most vital.³⁵ However, their use necessitates careful dissection and preservation of adjacent vasculature to serve as recipient vessels for anastomosis, which may be challenging in the traumatic setting.

Complications and Postoperative Management

Compared with historical nonvascularized ACF reconstructive options, vascularized reconstruction using pericranial and/or galeal flaps has decreased the rate of CSF leak from 25 to 6.5%.³⁶ Predictors of CNS complications include prior radiotherapy and dural/brain invasion.⁶ The most common early postoperative complications (< 4 weeks) include CSF leak (7.1%), flap loss (4.3%), and facial nerve weakness (1.4%), while later complications include fistula (4.3%), intracranial abscess (1.4%), and other infections (1.4%).³⁷ Neligan et al argue that free tissue transfer for large defects of the ACF further reduce CNS complications.²⁸

Postoperatively, patients are managed in the neurosurgical intensive care unit (NICU) and monitored for changes in mental status, hemodynamic concerns, and infection. Antibiotics are continued for approximately 5 to 7 days and typically consist of intravenous ampicillin/sulbactam or oral amoxicillin/clavulanic acid. Postoperative management often contrasts from conventional free flap management of reconstructive patients. Perioperative care provided in the NICU avoids vasodilation and liberal fluid resuscitation, avoids opioids to prevent hypercapnic-induced cerebral vasodilation, and utilizes diuretics and corticosteroids—factors that are essentially at the opposite end of postreconstructive care spectrum.¹⁴ Regardless, free tissue transfer outcomes are largely unaffected.¹⁴

Functional Outcomes

Overall, the prognosis of skull base fractures remains guarded and generally varies according to presenting symp-

tomatology. A range of injuries can be associated with high impact trauma to the cranial base often stemming from motor vehicle accidents (MVs), blunt trauma, or ballistic projectiles. Initial impact invariably leads to TBI and may additionally result in facial paralysis, cranial nerve pathology, paresthesia, CSF fistula, anosmia, and vestibulocochlear or ocular complications. Depending on the severity of the injury, the potential for recovery to the preinjury state is limited. For example, fracture through the cribriform plate may disrupt olfaction, as anosmia is one of the most common complications of ACF trauma. Once lost, the prognosis for return varies from 10 to 30%.³ In our experience, however, for patients who incur isolated ACF injury without concurrent brain or cranial nerve injury, quality of life following reconstruction has been excellent with most patients returning to their vocations.

Case Series

As outlined, there are many clinical decision points in ACF reconstruction, and consequently there are few consensus statements regarding surgical technique and flap options to guide management. ▶ **Table 1** presents a review of the existing literature related to traumatic reconstruction of the anterior cranial base.^{11,14,20,26,28–30} The PubMed, MEDLINE, EMBASE, Scopus, Cochrane Central Register of Controlled Trials, and clinicaltrials.org were searched systematically for all English studies published in any time frame reporting operative outcomes following primary or secondary traumatic anterior cranial base reconstruction. Additionally, we present our case series of $n = 6$ patients undergoing traumatic reconstruction of the ACF at an urban Level 1 trauma center from 2016 to 2018. Surgical technique, treatment outcomes, and complications are reviewed (▶ **Fig. 5**). Females comprised 50% of the study population with patient age ranging from 23 to 79 years (▶ **Table 2**). Etiology of traumatic injury to the ACF included self-inflicted gunshot wound (2/6), MVA (2/6), assault (1/6), and other (1/6). Presenting Glasgow Coma Scale was 6/15 (range 3–14) (▶ **Table 3**). Intraoperatively, all patients were noted to have dural injury with 1/6 actively leaking CSF. Dural reconstruction, which was performed by the neurosurgical team, utilized dural allograft in all cases. Bony reconstruction was performed in all cases using split cranial bone graft with rigid fixation to the surrounding craniofacial skeleton. Soft tissue reconstruction was performed using local pericranial flaps (1/6 anteriorly based, 1/6 laterally based). All exposures occurred through a standard bicoronal zigzag scalp incision at the level of the ears. The mean length of follow-up was 12.4 months, during which time 1/6 patients developed an intracranial abscess with pulsatile exophthalmos successfully salvaged with a galeal-frontalis flap and 1/6 patients represented with a persistent bony defect without brain herniation that was successfully managed with a polymethylmethacrylate cranioplasty at the 12-month postoperative time point (▶ **Table 4**). There were no postoperative CSF leaks, mucoceles, episodes of meningitis, or deaths during the study follow-up period.

Table 1 Study characteristics

Study	Year	Location	Study design	N	Population	Age; male (%)	Intervention(s)	Analysis	Clinical exam time point(s)	Mean follow-up (mo)
Piccirilli et al	2012	Italy	Retrospective	223	Patients with fractures of the anterior cranial fossa	Conservative treatment: 41 years; 78% Surgery: 31.8 years; 84.7%	Observation versus surgical management	CT and clinical signs correlating with cerebral involvement necessitating surgery	2 weeks, 1 month, 6 months, and yearly for 3 years	–
Vargo et al	2018	US	Retrospective	11	Patients with low, middle, and high anterior cranial fossa (ACF) defects requiring primary or secondary microvascular reconstruction due to trauma, malignancy, and/or infection	53 years; 70%	Osteocutaneous, myocutaneous, or myofascial free flap reconstruction of the ACF	Flap-related outcomes	Perioperative	–
Neligan et al	1996	Canada	Retrospective	90	Patients with cranial base defects following tumor ablation involving the anterior, middle, and/or posterior cranial fossae	–	Local, pedicled, and/or free tissue transfer for cranial base reconstruction	Incidence of flap success versus failure (e.g., flap death, CSF leak, fistula, abscess, wound dehiscence, wound infection)	–	–
Georgantopoulou et al	2003	UK	Retrospective	28	Reconstruction of the anterior and middle cranial fossa due to tumor, trauma, or congenital pathology	1–68 years	Pericranial, galeal, and free flap reconstruction of at least the ACF	Incidence of flap complications and death	–	4–24
Aksu et al	2017	Turkey	Retrospective	27	Midfacial defects requiring free flap reconstruction due to tumor or trauma.	53.1 years; 66.7%	Free flap reconstruction of Cordeiro type I-VI maxillectomy defects	Functional and aesthetic outcomes of midface reconstruction involving the midface and/or anterior cranial base	> 12 months	> 12
Janecka and Sekhar	1989	US	Retrospective	100	Patients with skull base defects due to tumor or trauma	7–75 years	Titanium mesh or porous polyethylene three-dimensional implant reconstruction of skeletal and soft tissue defects of the skull base	Rates of complications and degree of functional and aesthetic reconstruction	–	60
Badie et al	2000	US	Retrospective	13	Patients with large anterior cranial base defects due to malignancy, trauma, or craniofacial pathology	45.8 years	Reconstruction using titanium mesh and vascularized pericranium	Rates of perioperative and postoperative complications including CSF leakage, infection, meningocele, and death	–	22

Abbreviations: CSF, cerebrospinal fluid; CT, computed tomography.

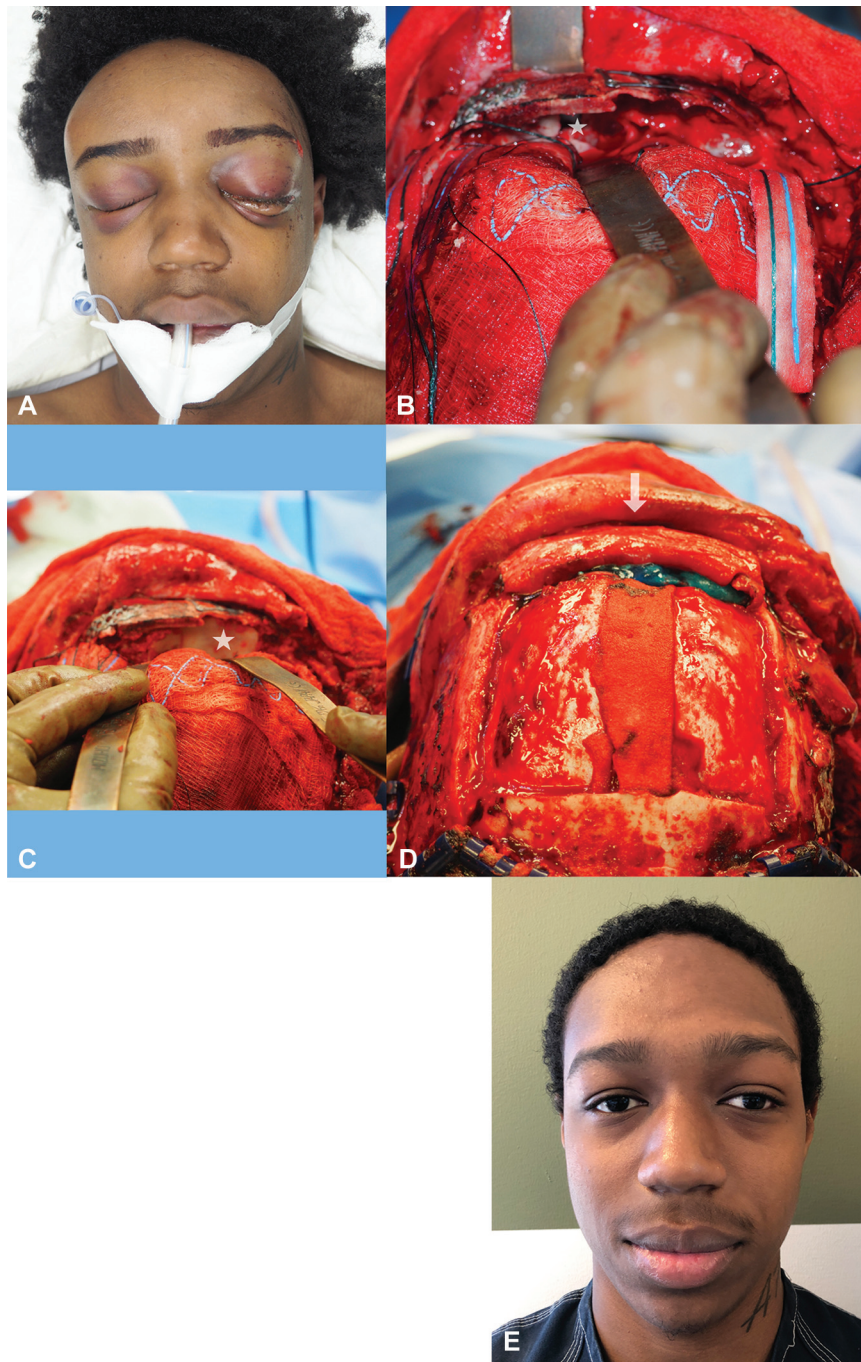


Fig. 5 Complex anterior cranial fossa (ACF) reconstruction following gunshot wound (GSW). (A) An 18-year-old male presenting after GSW to the right temple resulting in blast injury to the ACF. (B) Exposure of the ACF defect after frontal craniotomy (star). (C) The resultant small bony defect was reconstructed using splint cranial bone graft (star). (D) Bone “slurry,” an anteriorly based pericranial flap, and a polymer-based sealant (blue) provided a hermetic seal, separating the intracranial and intranasal contents. (E) The patient is shown 5 months postoperatively, recovering well.

Conclusion

Traumatic ACF reconstruction requires a team approach to provide dural reconstruction, separation of the intracranial contents from the aerodigestive tract, and prevent brain herniation. Depending on the defect size and underlying

patient and operative factors, reconstruction may involve bony reconstruction using autografts, allografts, or prosthetics in addition to soft tissue reconstruction using vascularized local or distant tissues. Use of pericranial, galeal, and free flaps, as indicated, can provide reliable and durable reconstruction of a wide variety of injuries.

Table 2 Demographics

Demographic characteristics	
	n (%)
Sex	
Male	3 (50)
Female	3 (50)
Age (y)	
Mean	38.1
Range	23–79
Mechanism of injury	
Gunshot	2 (40)
Motor vehicle accident	2 (40)
Assault	1 (17)
Heavy machinery accident	1 (17)

Table 3 Perioperative characteristics

Perioperative characteristics	
	n (%)
Preoperative GCS	
Median	6
Range	3–14
Dural injury (%)	6 (100)
Pericranial flap (%)	
Anteriorly based	5 (83)
Laterally based	1 (17)
Bone graft (%)	
Split thickness cranial graft	6 (100)
Allograft/implant	-

Abbreviation: GCS, Glasgow Coma Scale.

Author Contributions

Each of the authors has met the following criteria for authorships:

- (1) Substantial contributions to conception and design, acquisition of data, and analysis and interpretation of data.
- (2) Drafting the article or revising it critically for important intellectual content.
- (3) Final approval of the version to be published.
- (4) Agreement to be accountable for all aspects of the work in ensuring that questions related to the accuracy or integrity of any part of the work are appropriately investigated and resolved.

Patient Consent

The patients provided written informed consent for the publication and the use of their images.

Table 4 Postoperative outcomes

Postoperative outcomes	
	n (%)
Length of follow-up	
Mean (mo)	7.7
Range	2.8–12.4
CSF leak (%)	-
Infection (%)	1 (17) ^a
Mucocele (%)	-
Bony defect (%)	1 (17) ^b
Death (%)	1 (17) ^c

Abbreviation: CSF, cerebrospinal fluid.

^aIntracranial abscess successfully managed with R-sided galeal frontalis muscle flap.

^bMethylmethacrylate cranioplasty 1 year postoperatively.

^cWithdrawal by family secondary to other injuries.

Conflict of Interest

None declared.

References

- 1 CDC. Traumatic Brain Injury & Concussion. Published 2017. Accessed February 3, 2022 at: <http://www.cdc.gov/traumaticbraininjury/>
- 2 Michael LMB. Retrospective study of skull base fracture: a study of incidents, complications, management, and outcome overview from trauma-one-level institute over 5 years. *J Neurol Surg B Skull Base* 2013;74:239
- 3 Feldman JS, Farnoosh S, Kellman RM, Tatum SA III. Skull base trauma: clinical considerations in evaluation and diagnosis and review of management techniques and surgical approaches. *Semin Plast Surg* 2017;31(04):177–188
- 4 Kwon D, Iloreta A, Miles B, Inman J. Open anterior skull base reconstruction: a contemporary review. *Semin Plast Surg* 2017; 31(04):189–196
- 5 Ganly I, Patel SG, Singh B, et al. Complications of craniofacial resection for malignant tumors of the skull base: report of an International Collaborative Study. *Head Neck* 2005;27(06): 445–451
- 6 Pusic AL, Chen CM, Patel S, Cordeiro PG, Shah JP. Microvascular reconstruction of the skull base: a clinical approach to surgical defect classification and flap selection. *Skull Base* 2007;17(01): 5–15
- 7 Stephens JR, Holmes S, Evans BT. Applied anatomy of the anterior cranial fossa: what can fracture patterns tell us? *Int J Oral Maxillofac Surg* 2016;45(03):275–278
- 8 Lin DT, Lin AC. Surgical treatment of traumatic injuries of the cranial base. *Otolaryngol Clin North Am* 2013;46(05):749–757
- 9 Archer JB, Sun H, Bonney PA, et al. Extensive traumatic anterior skull base fractures with cerebrospinal fluid leak: classification and repair techniques using combined vascularized tissue flaps. *J Neurosurg* 2016;124(03):647–656
- 10 Yano T, Okazaki M, Tanaka K, et al. A new concept for classifying skull base defects for reconstructive surgery. *J Neurol Surg B Skull Base* 2012;73(02):125–131
- 11 Piccirilli M, Anichini G, Cassoni A, Ramieri V, Valentini V, Santoro A. Anterior cranial fossa traumas: clinical value, surgical indications, and results—a retrospective study on a series of 223 patients. *J Neurol Surg B Skull Base* 2012;73(04):265–272

- 12 Albonette-Felicio T, Rangel GG, Martínéz-Pérez R, Hardesty DA, Carrau RL, Prevedello DM. Surgical management of anterior skull-base malignancies (endoscopic vs. craniofacial resection). *J Neurooncol* 2020;150(03):429–436
- 13 Ein L, Sargi Z, Nicoli EA. Update on anterior skull base reconstruction. *Curr Opin Otolaryngol Head Neck Surg* 2019;27(05):426–430
- 14 Georgantopoulou A, Hodgkinson PD, Gerber CJ. Cranial-base surgery: a reconstructive algorithm. *Br J Plast Surg* 2003;56(01):10–13
- 15 Wasserzug O, DeRowe A, Ringel B, Fishman G, Fliss DM. Open approaches to the anterior skull base in children: review of the literature. *J Neurol Surg B Skull Base* 2018;79(01):42–46
- 16 Fliss DM, Abergel A, Cavel O, Margalit N, Gil Z. Combined subcranial approaches for excision of complex anterior skull base tumors. *Arch Otolaryngol Head Neck Surg* 2007;133(09):888–896
- 17 Raveh J, Laedrach K, Speiser M, et al. The subcranial approach for fronto-orbital and anteroposterior skull-base tumors. *Arch Otolaryngol Head Neck Surg* 1993;119(04):385–393
- 18 Yamamoto Y, Minakawa H, Yoshida T, et al. Role of bone graft in reconstruction of skull base defect: is a bone graft necessary. *Skull Base Surg* 1993;3(04):223–229
- 19 Jackson IT, Marsh WR, Bite U, Hide TA. Craniofacial osteotomies to facilitate skull base tumour resection. *Br J Plast Surg* 1986;39(02):153–160
- 20 Janecka IP, Sekhar LN. Surgical management of cranial base tumors: a report on 91 patients. *Oncology (Williston Park)* 1989;3(03):69–74
- 21 Jones NF, Schramm VL, Sekhar LN. Reconstruction of the cranial base following tumour resection. *Br J Plast Surg* 1987;40(02):155–162
- 22 Spinelli HM, Persing JA, Walser B. Reconstruction of the cranial base. *Clin Plast Surg* 1995;22(03):555–561
- 23 Snyderman CH, Janecka IP, Sekhar LN, Sen CN, Eibling DE. Anterior cranial base reconstruction: role of galeal and pericranial flaps. *Laryngoscope* 1990;100(06):607–614
- 24 Clyde BL, Stechison MT. Repair of temporosphenoidal encephalocele with a vascularized split calvarial cranioplasty: technical case report. *Neurosurgery* 1995;36(01):202–206
- 25 Goel A. Vascularized osteomyoplastic flaps for skull base reconstruction. *Br J Neurosurg* 1994;8(01):79–82
- 26 Aksu AE, Uzun H, Bitik O, Tunçbilek G, Şafak T. Microvascular tissue transfers for midfacial and anterior cranial base reconstruction. *J Craniofac Surg* 2017;28(03):659–663
- 27 Ioannides C, Fossion E, McGrouther AD. Reconstruction for large defects of the scalp and cranium. *J Craniomaxillofac Surg* 1999;27(03):145–152
- 28 Neligan PC, Mulholland S, Irish J, et al. Flap selection in cranial base reconstruction. *Plast Reconstr Surg* 1996;98(07):1159–1166
- 29 Vargo JD, Przylecki W, Camarata PJ, Andrews BT. Classification and microvascular flap selection for anterior cranial fossa reconstruction. *J Reconstr Microsurg* 2018;34(08):590–600
- 30 Badie B, Preston JK, Hartig GK. Use of titanium mesh for reconstruction of large anterior cranial base defects. *J Neurosurg* 2000;93(04):711–714
- 31 Lee JC, Kleiber GM, Pelletier AT, Reid RR, Gottlieb LJ. Autologous immediate cranioplasty with vascularized bone in high-risk composite cranial defects. *Plast Reconstr Surg* 2013;132(04):967–975
- 32 Cherubino M, Turri-Zanoni M, Battaglia P, et al. Chimeric antero-lateral thigh free flap for reconstruction of complex cranio-orbitofacial defects after skull base cancers resection. *J Craniomaxillofac Surg* 2017;45(01):87–92
- 33 Argenta LC, Friedman RJ, Dingman RO, Duus EC. The versatility of pericranial flaps. *Plast Reconstr Surg* 1985;76(05):695–702
- 34 Smith JE, Ducic Y, Adelson RT. Temporalis muscle flap for reconstruction of skull base defects. *Head Neck* 2010;32(02):199–203
- 35 Neligan PC, Boyd JB. Reconstruction of the cranial base defect. *Clin Plast Surg* 1995;22(01):71–77
- 36 Jackson IT, Adham MN, Marsh WR. Use of the galeal frontalis myofascial flap in craniofacial surgery. *Plast Reconstr Surg* 1986;77(06):905–910
- 37 Chiu ES, Kraus D, Bui DT, et al. Anterior and middle cranial fossa skull base reconstruction using microvascular free tissue techniques: surgical complications and functional outcomes. *Ann Plast Surg* 2008;60(05):514–520