




Modified Tunneling (Capsule Modification Technique) for Subcutaneous Placement of Ventriculo-Peritoneal Shunt in Patients with Hydrocephalus: Technical Note

Wajid Nazir Wani¹  Heena Samad² Shaam Bodeliwala¹ Anita Jagetia¹ Daljit Singh¹

¹Department of Neurosurgery, Govind Ballabh Pant Institute of Post Graduate Medical Education and Research, Delhi, India

²Department of Neuro-Anaesthesia, Institute of Human Behaviour and Allied Sciences, Delhi, India

Address for correspondence Wajid Nazir Wani, DNB, Department of Neurosurgery, Govind Ballabh Pant Institute of Post Graduate Medical Education and Research, Room No: 518, 5th Floor, Academic Block, J. L.N. Marg, 110002, Delhi, India
(e-mail: dr_wajidnazir@rediffmail.com).

Indian J Neurosurg 2022;11:280–283.

Abstract

One of the first procedures that a neurosurgical resident/trainee assists and performs is the placement of a ventriculoperitoneal shunt, the commonest being the Chhabra shunt system. However, no modification has been done or proposed in performing this procedure keeping in mind the position of the chamber of the Chhabra shunt system. As the tunneller has to pass through the subcutaneous plane having tight adhesions, it is essential to have a proper and adequate space for the chamber. Utilization of instruments such as artery forceps or Penfield dissectors for the same results in the creation of inappropriate or a roughly estimated space, which is either inadequate, causing kinking of tubing, or too roomy that results in the peri-catheter collection of cerebrospinal fluid with the risk of infection.

Keywords

- ▶ traditional technique
- ▶ capsule modification technique
- ▶ hydrocephalus

We propose a novel method of utilizing a modified tunneller with a distal “Capsule” that provides just enough space both, at the appropriate distance and for adequate length, for the chamber to fit snugly and thus avoid procedure-related risks and complications as well as reduce the total duration of surgery, thereby decreasing the chances of infection.

Capsule Modification Technique

The capsule modification technique (CMT) has been developed for the placement of ventriculoperitoneal shunt after evaluating the inherent difficulties encountered with the traditional technique (TT). It is basically a capsule-like attachment [▶ Fig. 1A] that connects at the distal end of the traditional tunneller [▶ Fig. 1B], resulting in a modified tunneller [▶ Fig. 1C]. The CMT is started similar to TT with openings made at cranial and abdominal ends [▶ Fig. 2A]; however, once the distal end of the tunneller (cranial end) is

out of the subcutaneous plane, a capsule-shaped attachment is attached to it [▶ Fig. 2B]. It fits into the tunneller like a cap of a pen. Once attached, the tunneller is partially withdrawn from the abdominal end gradually [▶ Fig. 2C] for 8 cm beyond the cranial opening of the subcutaneous plane (10 cm in neonates where the length of the peritoneal end is shortened to provide additional widened space for the connector). Once the capsule has reached the destined site, the tunneller is pushed out again, and the attachment along with stylet is removed [▶ Fig. 2D]. The peritoneal end of the catheter is passed and the tunneller is removed [▶ Fig. 2E]. Finally, the

DOI <https://doi.org/10.1055/s-0042-1744252>.
ISSN 2277-954X.

© 2022. Neurological Surgeons' Society of India. All rights reserved.
This is an open access article published by Thieme under the terms of the Creative Commons Attribution-NonDerivative-NonCommercial-License, permitting copying and reproduction so long as the original work is given appropriate credit. Contents may not be used for commercial purposes, or adapted, remixed, transformed or built upon. (<https://creativecommons.org/licenses/by-nc-nd/4.0/>)
Thieme Medical and Scientific Publishers Pvt. Ltd., A-12, 2nd Floor, Sector 2, Noida-201301 UP, India

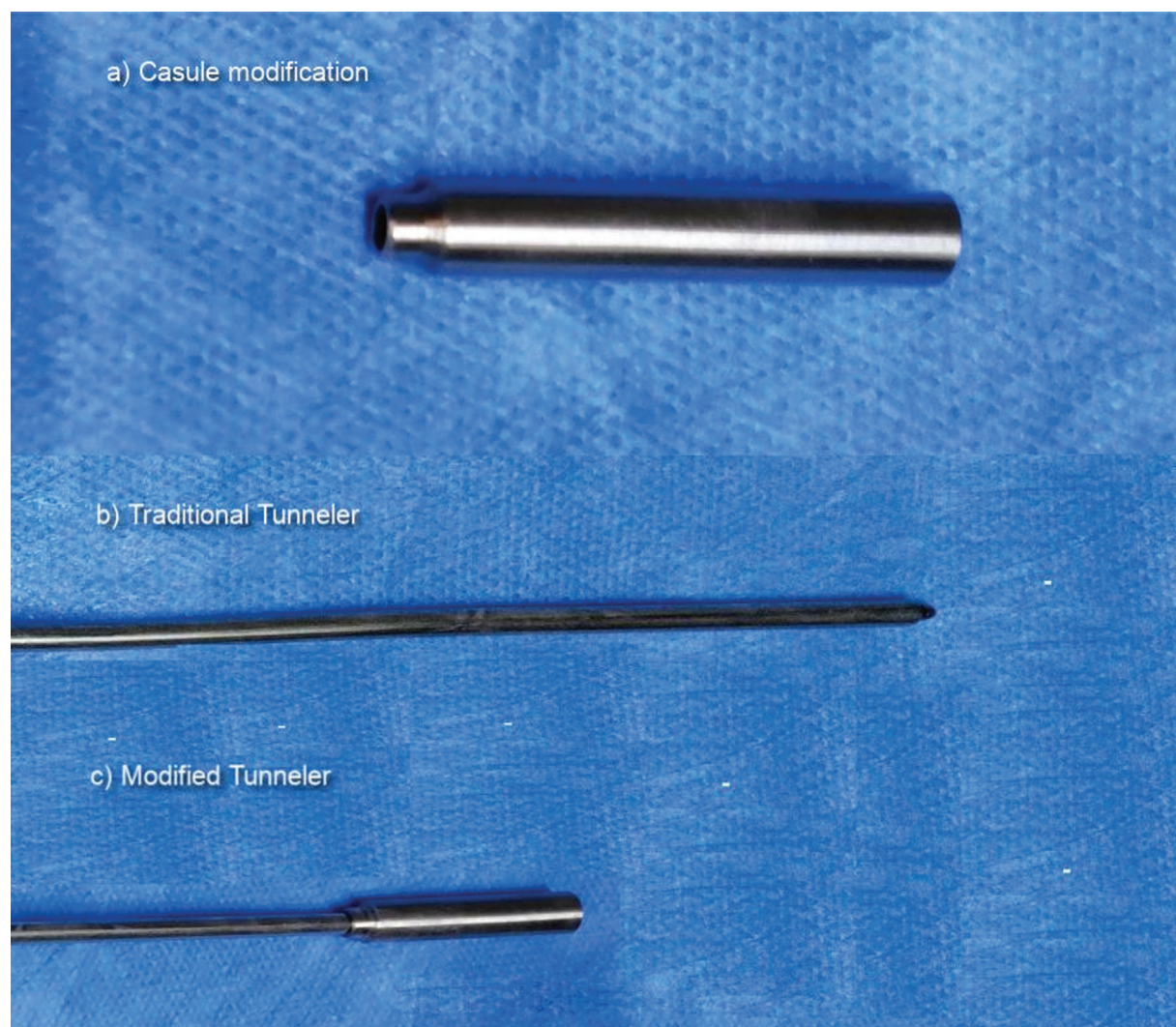


Fig. 1 Parts of tunneller system.

ventricular end is connected to the peritoneal end and skin is closed in layers (→ **Fig. 2F**). The CMT is extremely simple and basic and its benefits are considerable.

The space so created ensures the chamber fits snugly and perfectly, thereby eliminating any dead space, which is usual and common in cases where dilatation is done using instruments such as artery forceps or Penfield dissector. The space for proper placement of chamber is made at the exact place so that there is no need for manipulation while placing the catheter and any kinking is avoided. It further eliminates the need to re-position the chamber as well as avoid contact of blood with the opening in the chamber, thus minimizing the risk of blockage. Excessive dilatation of the subcutaneous plane is avoided, thereby decreasing the chances of peri-catheter collection of cerebrospinal fluid and subsequent risk of infection.

Discussion

Ventriculoperitoneal shunting is one of the most common neurosurgical procedures performed. However, not much attention has been given to the technique involved in the

procedure. It tends to play a crucial role in ensuring proper placement of the tubing in the subcutaneous plane free of any kinking. Several techniques and modifications have been suggested;¹⁻⁵ however, no modification has been done or proposed in performing this procedure keeping in mind the position of the chamber of the shunt tubing. There are several studies on the management of shunt failure due to migration and infection.^{6,7} Skin of pediatric patients, especially post tubercular, is very fragile; hence, transient redness of the skin is seen in many cases, suggesting the need for careful and gentle tunneling. The space created by various instruments such as artery forceps results in a lot of dead space where CSF gets collected and is prone to infection. There is adequate evidence that duration of surgery, minimizing contact of shunt tubing with gloves, and decreased need of manipulation of tubing are associated with less risk of infection and shunt failure.⁸⁻¹¹ The duration of surgery has a direct impact on the outcome and complications. Revisions are associated with increased morbidity. Our CMT showed reduced overall duration of surgery with not a single case of kinking in the chamber/tubing and absence of entry of any amount of

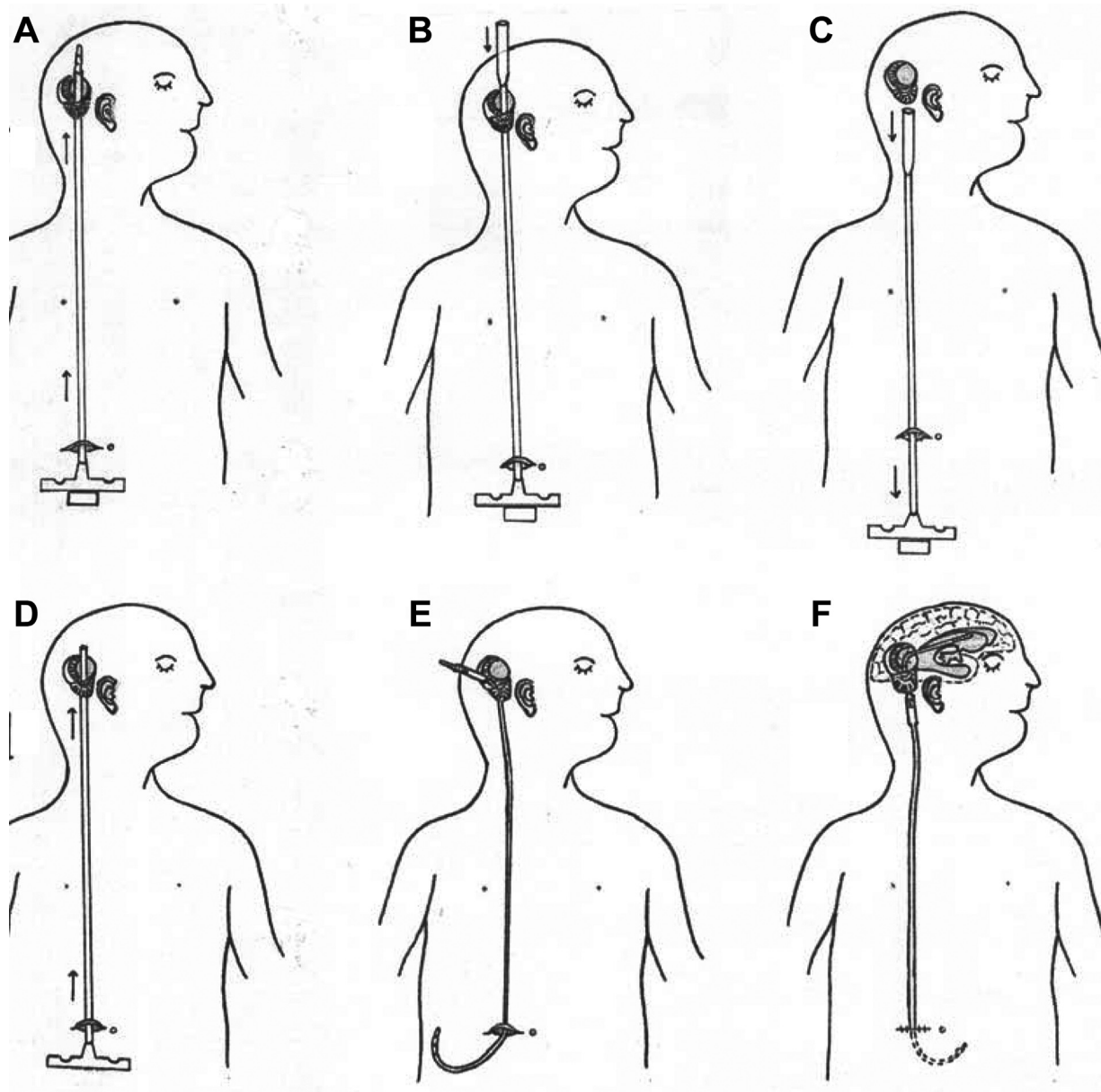


Fig. 2 Schematic representation of modified capsule tunneling for the placement of the ventriculoperitoneal shunt system. (A) Subcutaneous placement of the tunneller after making openings at the cranial and abdominal ends. (B) Attachment of the distal (capsule attachment) at the cranial end of the tunneller. (C) Retraction (pulling down) of the entire assembly caudally until capsule reaches the mastoid area, where the chamber of catheter needs to be placed. (D) Pushing up the entire assembly from the cranial opening with the removal of capsule attachment and style. (E) Passing of the peritoneal end of the catheter and the removal of the tunneller. (F) Placement of the ventricular end of the catheter and connecting entire system followed by closure in layers.

blood through the opening of the chamber as no manipulation was required at the time of fixing the ventricular to peritoneal end of the shunt. There was no need to revise the position of the chamber with a reduced need for shunt revision.

Conclusion

This new technique appears to be superior to the traditional one. It was found to reduce operative time with no kinking of the catheter and no contact of the catheter with the skin and other tissue. This technique has been suggested to simplify the procedure and minimize other shunt-related risks and

complications. However, a dedicated study incorporating the role of etiology and associated factors on the outcome is needed for effective statistical analysis.

Conflict of Interest
None declared.

References

- 1 Vitali AM, le Roux AA. Modification of shunt introducer. *J Pediatr Neurosci* 2007;2:67-68
- 2 Tubbs RS, Goodrich D, Tubbs I, Loukas M, Cohen-Gadol AA. A novel method for passing cerebrospinal fluid shunt tubing: a proof of principle study. *Childs Nerv Syst* 2014;30(12):2115-2117

- 3 Downes AE, Vandergrift WA, Beckman JM, Truong D, Tuite GF. Bucket and straw technique to facilitate passage of a ventriculoperitoneal shunt through the distal tunneling sheath. *J Neurosurg Pediatr* 2014;14(06):662–664
- 4 Sandquist MA, Selden NR. A single-pass tunneling technique for CSF shunting procedures. *Pediatr Neurosurg* 2003;39(05):254–257
- 5 Oi S, Matsumoto S. A shape-corrective shunt-passer using a titanium-nickel alloy. *Neurosurgery* 1991;28(05):725–726
- 6 Wong JM, Ziewacz JE, Ho AL, et al. Patterns in neurosurgical adverse events: cerebrospinal fluid shunt surgery. *Neurosurg Focus* 2012;33(05):E13
- 7 Kumar V, Shah AS, Singh D, Loomba PS, Singh H, Jagetia A. Ventriculoperitoneal shunt tube infection and changing pattern of antibiotic sensitivity in neurosurgery practice: alarming trends. *Neurol India* 2016;64(04):671–676
- 8 Cochrane DD, Kestle JRW. The influence of surgical operative experience on the duration of first ventriculoperitoneal shunt function and infection. *Pediatr Neurosurg* 2003;38(06):295–301
- 9 Faillace WJ. A no-touch technique protocol to diminish cerebrospinal fluid shunt infection. *Surg Neurol* 1995;43(04):344–350
- 10 Tulipan N, Cleves MA. Effect of an intraoperative double-gloving strategy on the incidence of cerebrospinal fluid shunt infection. *J Neurosurg* 2006;104(1, Suppl):5–8
- 11 Pirotte BJM, Lubansu A, Bruneau M, Loqa C, Van Cutsem N, Brotchi J. Sterile surgical technique for shunt placement reduces the shunt infection rate in children: preliminary analysis of a prospective protocol in 115 consecutive procedures. *Childs Nerv Syst* 2007;23(11):1251–1261