



Fronto-Temporo-Orbito-Zygomatic Approach with Orbital Reconstruction in Lesions causing Unilateral Non-pulsating Proptosis

Mohab Darwish¹ Ahmed Moawad¹

¹Attending of Neurosurgery, Department of Neurosurgery, Minia University Hospital and school of Medicine, Minia, Egypt

Address for correspondence Mohab Darwish, MD, PhD, Attending of Neurosurgery, Department of Neurosurgery, Minia University Hospital and School of Medicine, Minia, Egypt (e-mail: Mohab.darwish@mu.edu.eg).

Indian J Neurosurg 2024;13:11–19.

Abstract

Background Unilateral non-pulsating proptosis can be caused by lesions with intraorbital extensions compressing the globe including sphenoid wing en plaque meningiomas and paranasal sinuses lesions.

Patients and Methods We operated on 20 patients with unilateral non-pulsating proptosis using fronto-temporo-orbito-zygomatic (FTOZ) approach with orbital reconstruction in six patients. Eighteen patients had sphenoid wing en plaque meningioma, 1 patient had paranasal sinuses fungal infection with intraorbital and intracranial extension, and 1 patient had frontal sinus dermoid with intraorbital extension.

Results Proptosis was corrected in 50% of the patients, improved in 25%, and remained stationary in 25%. Vision improved in three patients, remained stationary in three, and deteriorated in one patient. Two patients had temporary oculomotor ophthalmoplegia that resolved within 3 months.

Conclusion Although it is an invasive approach, FTOZ gives excellent exposure of the orbit and anterolateral skull base that allows the excision of intracranial lesions with orbital extension. If needed, the orbit could be reconstructed easily due to excellent exposure.

Keywords

- ▶ proptosis
- ▶ FTOZ
- ▶ en plaque meningioma

Introduction

Proptosis or anterior displacement of one or both globes can occur as a result of orbital lesions such as cellulitis, tumor, and retrobulbar hematoma. It can also occur as a result of extension from a nearby pathology such as frontal mucocele, dermoids,¹ and cranial lesions with orbital extensions, e.g., en plaque meningioma, fibrous dysplasia, metastases, and osteomas.²

Many of patients encountered with proptosis in the neurosurgical field have en plaque meningiomas,³ which account for 2 to 9% of all meningiomas^{2,4,5} and cause

progressive proptosis that is influenced mainly by the degree of bone invasion rather than intradural involvement.^{6,7}

In addition to proptosis, visual impairment and oculomotor paresis may result from the involvement of the optic canal and superior orbital fissure (SOF). In such cases, extensive drilling of the optic canal and SOF decompression are required to preserve visual function and ocular motility.^{4,5,7}

Proptosis may occur secondary to nasal and paranasal sinuses pathologies such as squamous cell carcinomas,

article published online
October 7, 2022

DOI <https://doi.org/10.1055/s-0042-1744249>.
ISSN 2277-954X.

© 2022. The Author(s).

This is an open access article published by Thieme under the terms of the Creative Commons Attribution License, permitting unrestricted use, distribution, and reproduction so long as the original work is properly cited. (<https://creativecommons.org/licenses/by/4.0/>)
Thieme Medical and Scientific Publishers Pvt. Ltd., A-12, 2nd Floor, Sector 2, Noida-201301 UP, India

frontoethmoidal mucocele, and fungal sinusitis. It can be even their initial presentation.^{8,9}

Surgical management of proptosis cannot be the same in all patients. It has to be tailored to each patient according to his clinical and cosmetic presentation.² However, the standard approach is mostly frontotemporal with orbital decompression by extensive drilling of the involved bone and extensive resection of involved dura.^{2,4,5} Cavernous sinus involvement is common and is considered a surgical limit.³ Extensive bone resection should be followed by orbitocranial reconstruction with autografts or allografts to ensure good cosmesis and prevent enophthalmos.^{4,7}

We here aimed at evaluation of the FTOZ approach in correcting non-pulsating proptosis due to intracranial lesion with orbital extension, especially when there is a need for orbital reconstruction.

Patients and Methods

After obtaining the local ethics committee approval, we retrospectively studied the patients operated upon for proptosis between January 2016 and June 2020 at Neurosurgery Department, Minia University Hospital, Egypt.

This study was conducted on 20 patients (14 females and 6 males). Their ages ranged between 15 and 53 years with a mean/standard deviation (SD) of 37.4 ± 6.5 years. Eighteen patients had sphenoid wing en plaque meningiomas (13 females and 5 males). One male patient had frontoethmoidal fungal sinusitis with subfrontal and orbital extension. The last patient was a female having frontal sinus dermoid expanding the sinus floor, outer and inner tables.

The degree of proptosis was clinically evaluated in all patients using Hertel's exophthalmometer at the ophthalmology outpatient clinic. Radiologically, we used computed tomography (CT) scans to assess proptosis. In CT scans, we measured the distance between the corneal apex and the interzygomatic line (which is drawn between the most anterior portions of the zygomatic bones at the lateral orbital walls) (→ Fig. 1). All patients were also examined for visual acuity and motility of extraocular muscles.

We first used the one-piece "FTOZ1" approach described by Aziz et al.¹⁰ They emphasized the value of MacCarty keyhole and inferior orbital fissure, which acts as a naturally existing burr hole connecting the orbit to the temporal fossa. However, in this approach, pathological involvement of the greater wing of the sphenoid bone in some patients with en plaque meningiomas prevented "controlled fracture" of the bone flap and led to "uncontrolled fracture" and/or excessive bleeding. So, with extensive involvement of the sphenoid greater wing at the floor of the middle cranial fossa, we used the 2-piece-FOTZ approach starting with classic pterional approach, followed by orbito-zygomatic osteotomy removing the orbital rim, superior, and lateral orbital walls.

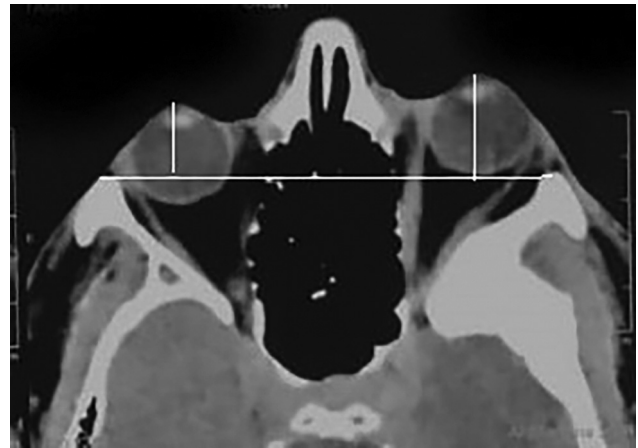


Fig. 1 Preoperative radiological assessment of proptosis. A line is drawn from the corneal apex to the interzygomatic line.

After removing the bone flap, the pathological bone was drilled out in the elevated bone flap, floor of the middle cranial base, and orbital walls as well. The endpoint of drilling removed the pathological bone in the elevated FTOZ bone flap, satisfactory decompression of SOF and optic nerve, orbital contents, and restoration of the orbital cavity (→ Fig. 2A–C). After dural grafting, one essential step is to maintain the restored orbital cavity and prevent overcorrection and enophthalmos on the other hand. So, cranioplasty is done in patients with extensive orbital osteotomies that compromise the orbital rim before repositioning and fixation of the bone flap.

Day 0 postoperative CT scans with three-dimensional (3D) reconstruction were obtained in all patients. Patients were followed up for an average period of 20 months (6–36) with postoperative CTs done at 3, 6, 12, 24, and 36 months intervals.

Results

Based on the preoperative assessment, we had 8 patients with ≤ 2 mm proptosis, 11 with 2–4 mm proptosis, and 1 patient with >4 mm proptosis. We graded them as mild, moderate, and severe, respectively. Visual acuity was diminished preoperatively in seven patients. Ocular motility was preserved in all patients.

We used FTOZ1 in 5 patients and 2-piece FTOZ in 15 patients. All patients had temporary postoperative eyelid edema that resolved within maximally 1 week with cold fomentation and anti-edematous measures. Five patients with en plaque meningioma had postoperative CSF collection that resolved spontaneously, except in two patients who needed lumbar drain for 2 days.

Visual acuity improved in three patients out of seven, in whom it was diminished preoperatively, remained stationary in three patients, and deteriorated in one patient (→ Table 1). Two patients with en plaque sphenoid wing meningioma had oculomotor ophthalmoplegia that

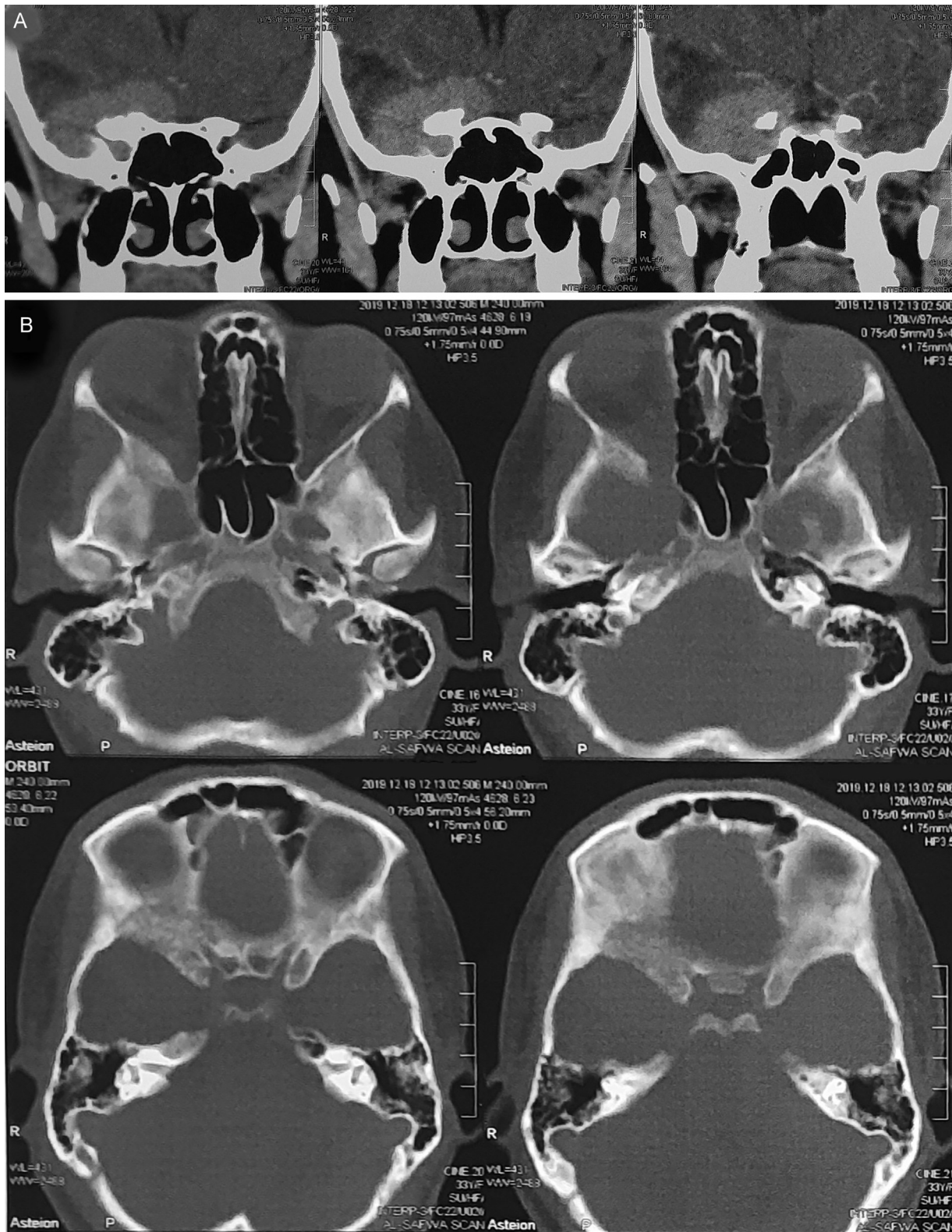

Fig. 2 A 32-year-old female patient with right sphenoidal meningioma, (A) causing mild proptosis due to hyperostosis of the lateral wall and posterior part of the orbital roof with diminution of vision due to optic nerve compression. (B) Six-month-follow-up orbital CT shows the correction of proptosis after the FTOZ approach with drilling of the involved bone of the orbital roof, lateral wall, anterior clinoidectomy, and deroofing of the optic canal (C). Orbital rim was not compromised and orbital reconstruction was not necessary (D, E).

resolved within 3 months postoperatively. None of our patients had permanent postoperative ophthalmoplegia. We did orbital reconstruction with bone cement in six patients with sphenoid wing meningiomas.

With follow-up, proptosis was completely corrected in the patient with fungal infection (mild degree) and the patient with frontal sinus dermoid (moderate). In 18 patients, with en plaque wing meningiomas, proptosis was corrected in 8 patients (5 mild and 3 moderate), improved by one degree in 5 patients, and still stationary in the remaining 5 patients (– Table 2).

Discussion

Proptosis is a common manifestation of a wide variety of lesions that could originate in the orbit or extend to it from intracranial or paranasal spaces.^{1,2,6,8,9} Diagnosis and management are usually the combined efforts of radiologists, ophthalmologists, ENT surgeons, and neurosurgeons. It occurs frequently with sphenoid wing en plaque meningioma due to extensive bone invasion and hyperostosis, which is the primary cause of clinical presentation in such patients rather than intradural involvement.^{3,6,7}

Treatment is directed primarily toward the offending lesion and should ensure adequate decompression of orbital structures and restoration of the orbital cavity. Pterional craniotomy is classically used to approach the orbital wall and frontal and middle cranial bases. This is followed by extradural resection of involved bone and orbital wall drilling to decompress the orbital cavity, SOF, and, if needed, the optic canal.^{3,11–14} Frontolateral and FTOZ approaches are also recommended.^{11,12,15} The latter is a modification of the classic pterional approach that increases surgical exposure to the orbit and decreases the need for brain retraction.¹¹

Based on our surgical experience and aiming at restoring the cosmetic and functional abilities of the patients, we preferred to use FTOZ in all patients. We used the one-piece “FTOZ1” described by Aziz et al¹⁰ in the patients with fungal sinusitis, frontal dermoid, and in three patients with en plaque meningiomas. We used the 2-piece FTOZ approach in patients with extensive bony involvement to avoid “uncontrolled fracture” of the bone flap. Extradural drilling of the involved bone is then done with the decompression of SOF, deroofing of the optic canal, and anterior clinoidectomy when needed with the excision of the intradural lesion and dural grafting using pericranial grafts.

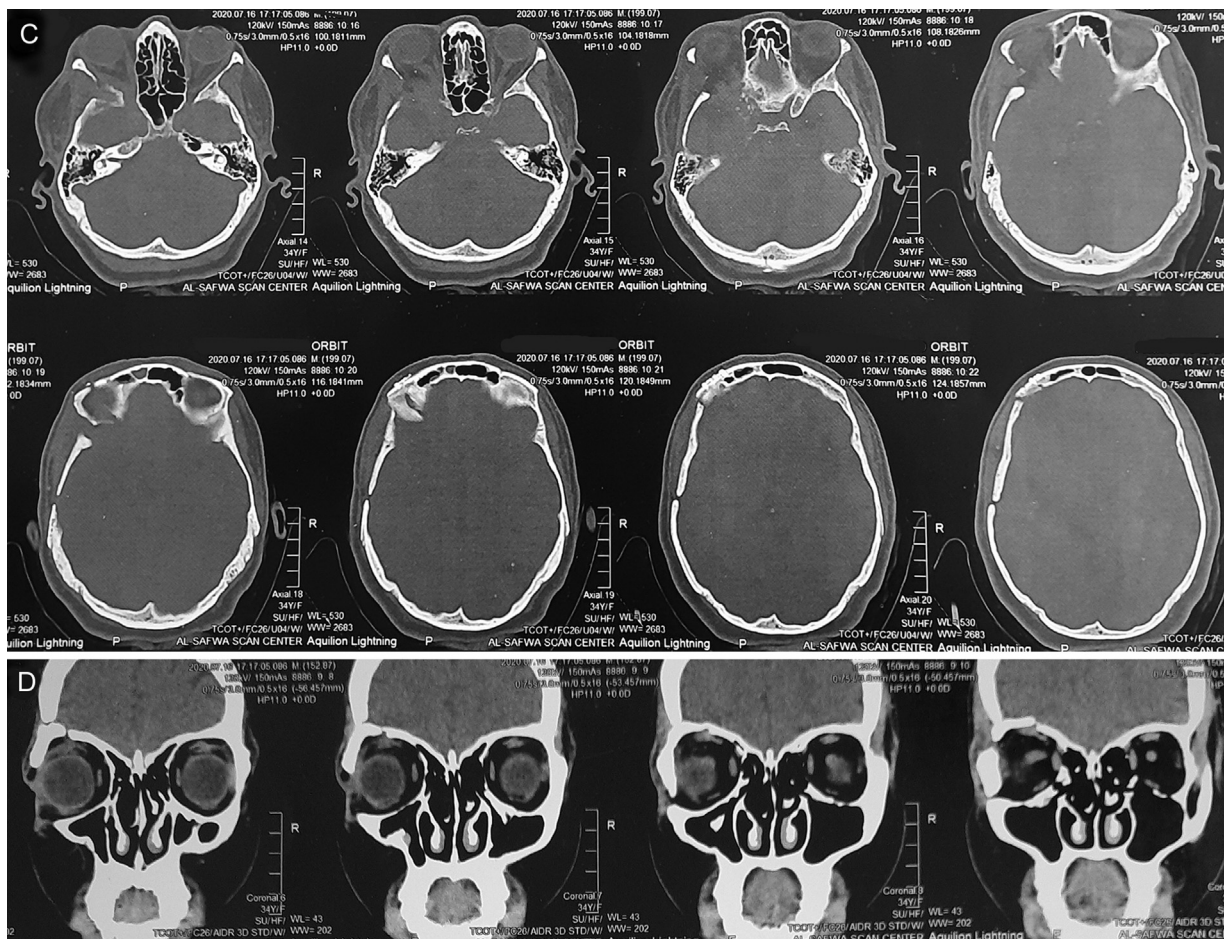


Fig. 2 (Continued)

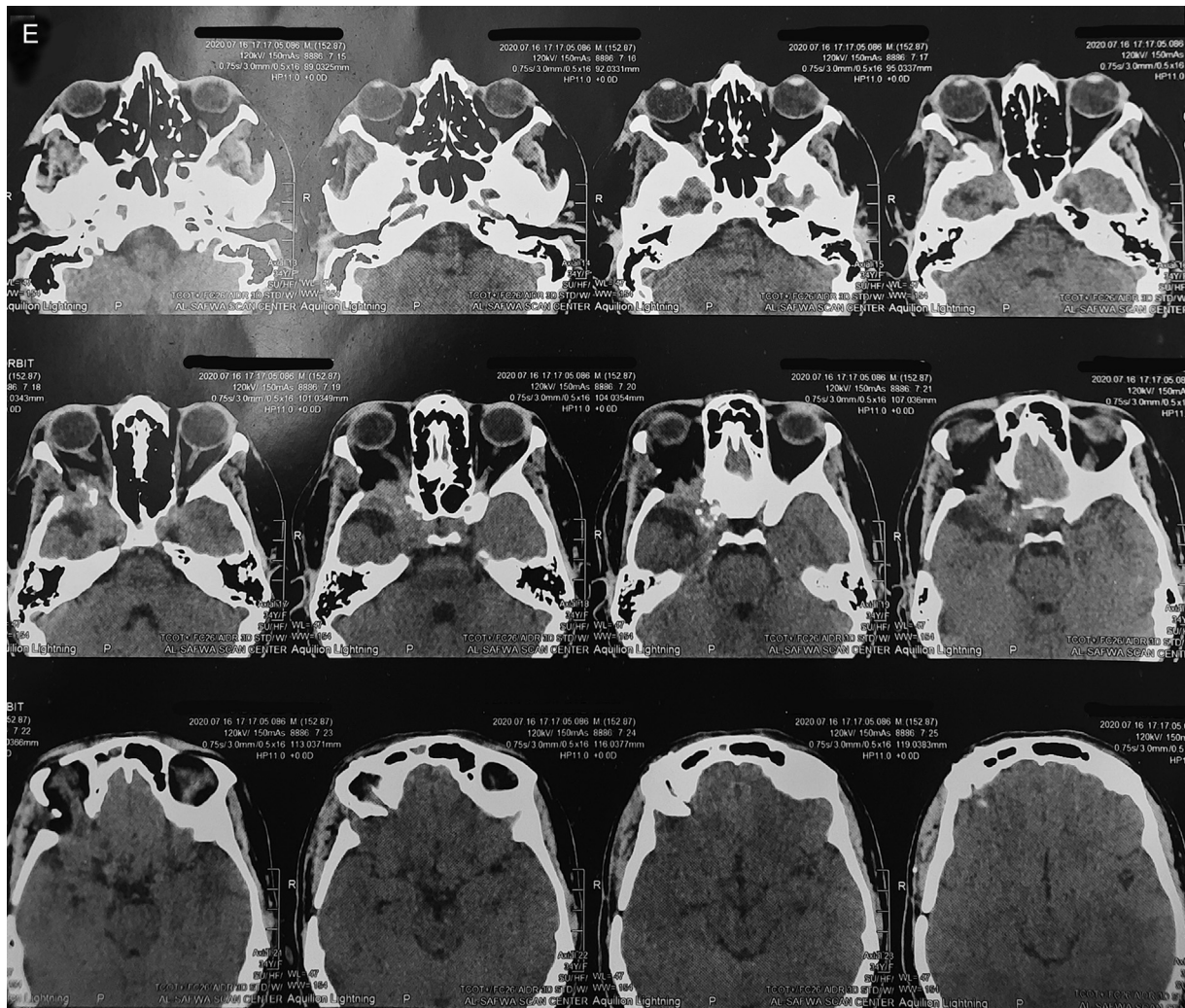


Fig. 2 (Continued)

Table 1 List of visual acuity changes pre- and postoperatively in patients having preoperative visual deterioration

Visual acuity changes	Preoperative	Postoperative
Pt. no. 1 (improved)	Counting fingers at 2 m	6/60
Pt. no. 2 (stationary)	Counting fingers at 2 m	Counting fingers at 2 m
Pt. no. 3 (improved)	Counting fingers at 3 m	6/60
Pt. no. 4 (stationary)	Hand movement	Hand movement
Pt. no. 5 (stationary)	Counting fingers at 4 m	Counting fingers at 4 m
Pt. no. 6 (deteriorated)	Counting fingers at 3 m	No PL
Pt. no. 7 (improved)	6/60	6/36

Table 2 Number of patients with preoperative and postoperative corrected proptosis

	Mild	Moderate	severe
Preoperative degree of proptosis	8	11	1
Corrected proptosis	6	4	0
Improved proptosis	0	4	1
Stationary proptosis	2	3	0

Because the main complaint of the patients in this study was proptosis with and without diminution of vision, the essential step in our procedure was to restore the volume of the orbital cavity to correct the proptosis. Optic canal deroofting was done in patients with diminished visual acuity.

Orbital reconstruction in patients with sphenoid-orbital meningiomas is still a matter of debate regarding the techniques, materials, and even the necessity of reconstruction itself. Some authors reported the increased risk of pulsatile enophthalmos, meningoceles, diplopia, and extraocular muscle fibrosis leading to

ophthalmoplegia without reconstruction.^{4,7,16,17} However, some groups reported that above-mentioned complications may not necessarily result after no orbital reconstruction even with long-term follow-up.^{3,13,16-18} Heller et al suggested “rebuilding the orbit at slightly larger than anatomical volume” with extensive bone involvement and removal.¹⁸

As the most important parts in reconstructing the orbit are the floor and orbital rim,¹⁹ we did not reconstruct the orbit unless the orbital rim is compromised with extensive osteotomies leaving only around 2 cm of bone from the superior and lateral orbital rim backward (►Fig. 2D, 2E, ►Fig. 3, ►Fig. 4). Thus, we only reconstructed the orbit in six patients. In these patients, we only “rebuilt” the orbital roof mainly to avoid pulsating enophthalmos. In addition, rebuilding the orbit at larger than anatomical volume adds a more decompressive effect. We simply used a sheet of bone cement as it is cheaper, more malleable, and easily shaped to conform to the orbital roof than titanium mesh.

This additive effect of orbitocranial osteotomy, extensive drilling, and orbital reconstruction, if needed, allowed complete correction of proptosis in 50% of the patients, downgrading in 25%, while the remaining 25% had stationary course.

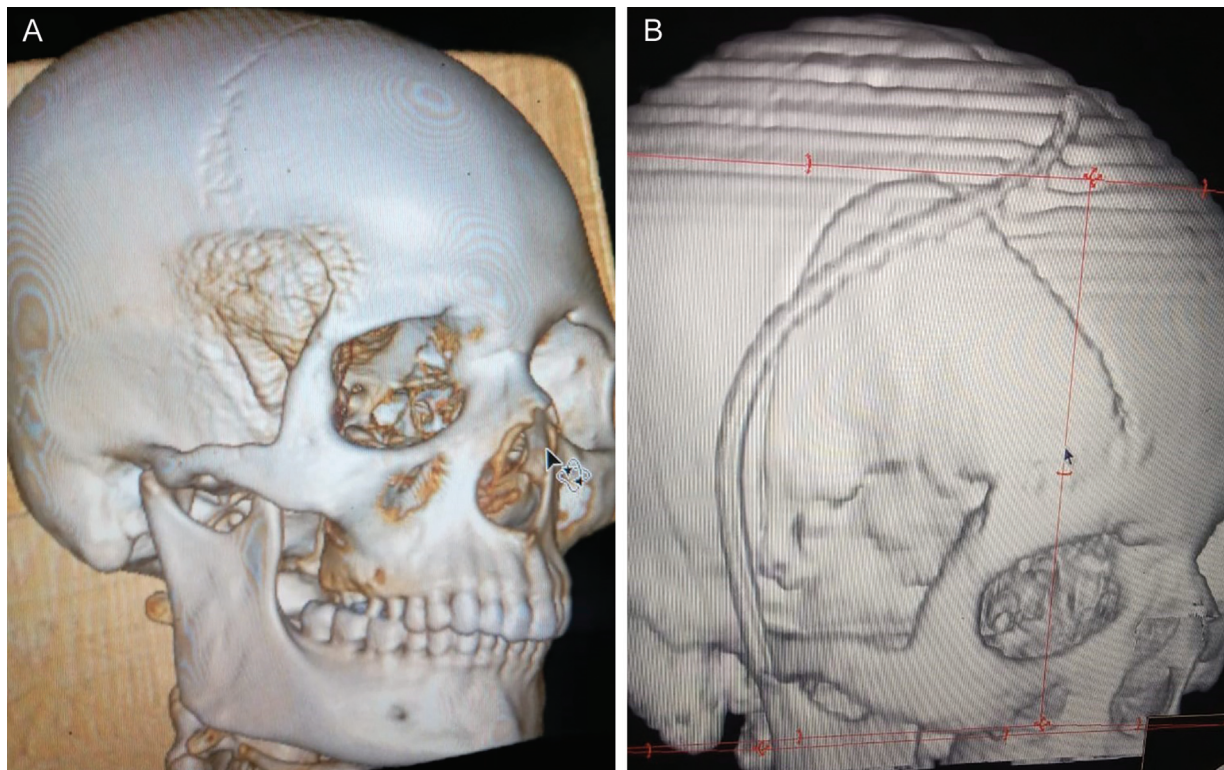


Fig. 3 A 35-year-old female patient with an plaque meningioma of the right sphenoid wing causing proptosis due to the involvement of the lateral orbital wall and orbital roof. (A) Orbital rim was not compromised. The orbit was reconstructed and bone cement was used only to cover the large defect in the periorbital bone flap (B).

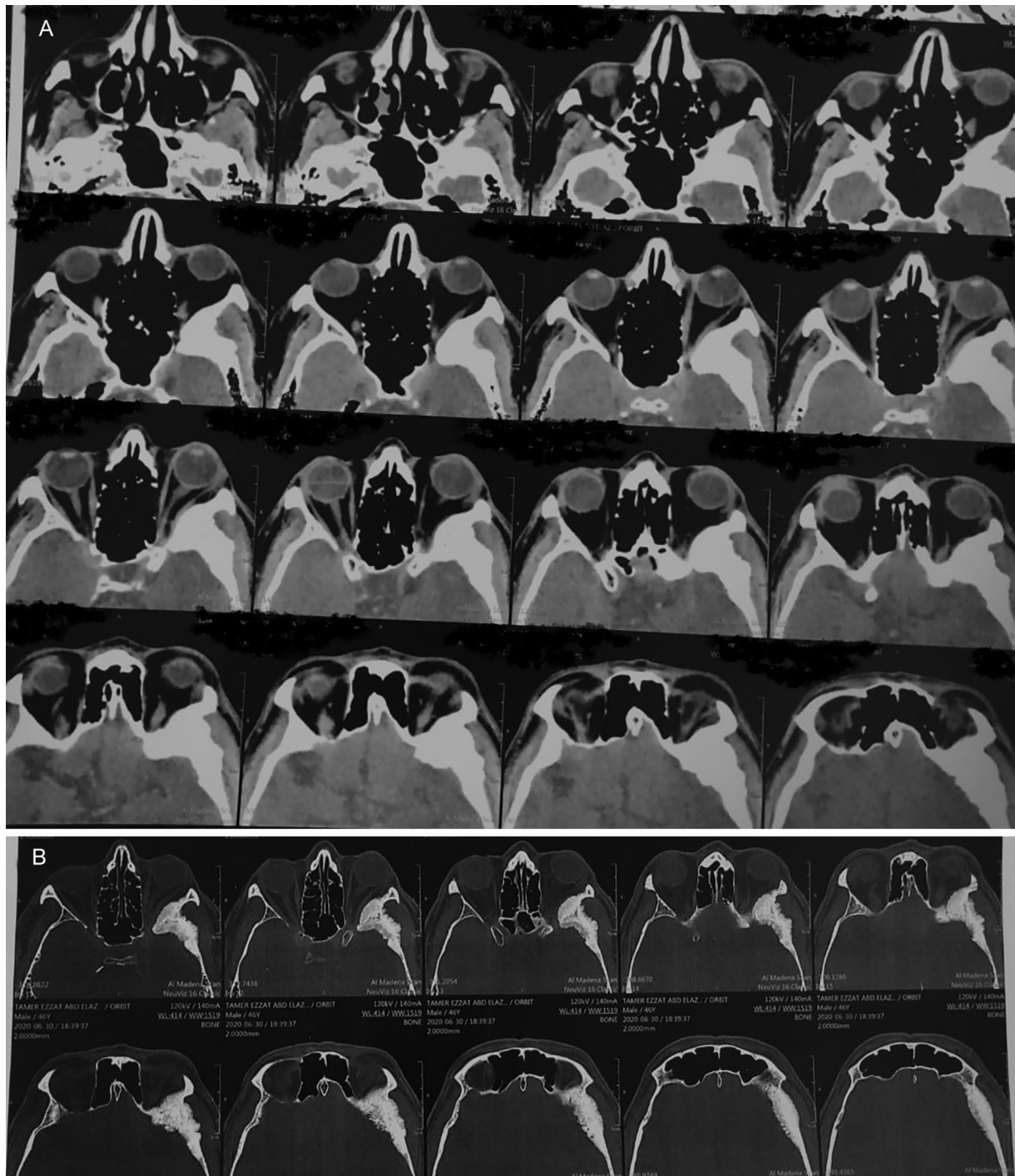

Fig. 4 A 40-year-old-male patient with moderate proptosis due to the left sphenoid wing meningioma with hyperostosis of lateral orbital wall and greater wing of the zygomatic bone (A, B). Postoperative computed tomography (CT) shows partial improvement of proptosis after orbital decompression and the removal of the lateral orbital wall and anterior clinoid (C). Bone defect in the greater wing of sphenoid bone in the pterional flap was repaired with bone cement (D, E). Preoperative and 7-days postoperative images of patient's eyes (F, G).

Conclusion

In dealing with proptotic lesions, the FTOZ approach allows wide exposure of the orbital contents and anterolateral skull base and minimizes the need for brain retraction. A 2-piece

FTOZ is preferred with extensive bone involvement. Orbital reconstruction should be larger than anatomical volume and is preferably done when only the orbital rim is compromised and is directed mainly toward the orbital roof to protect against pulsatile exo/enophthalmos.

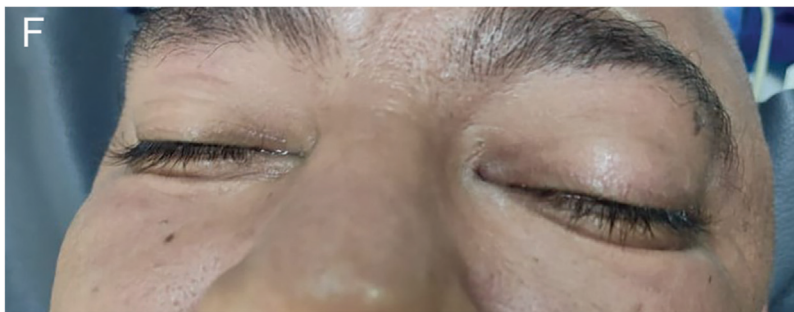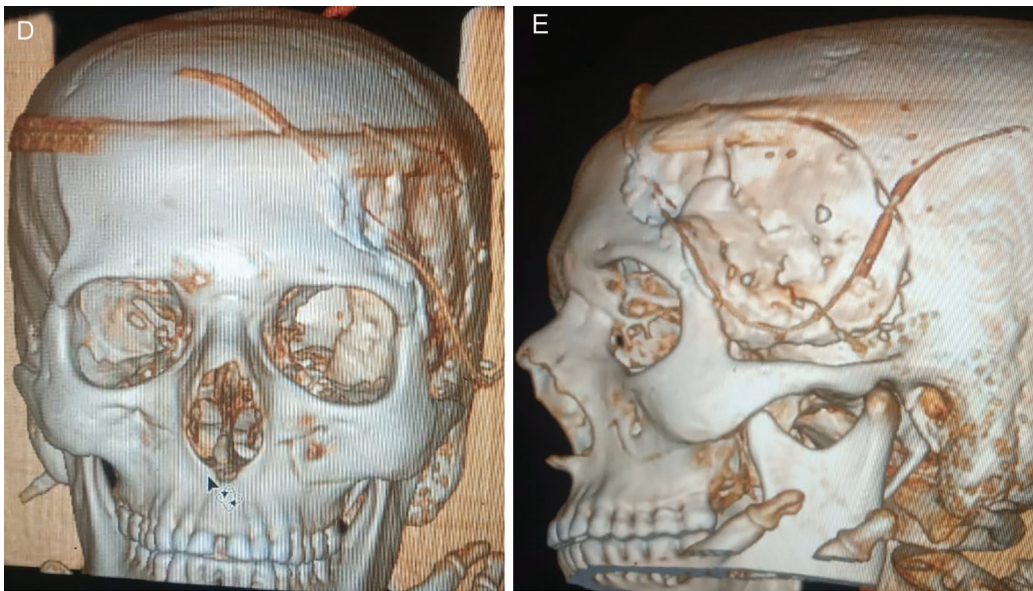
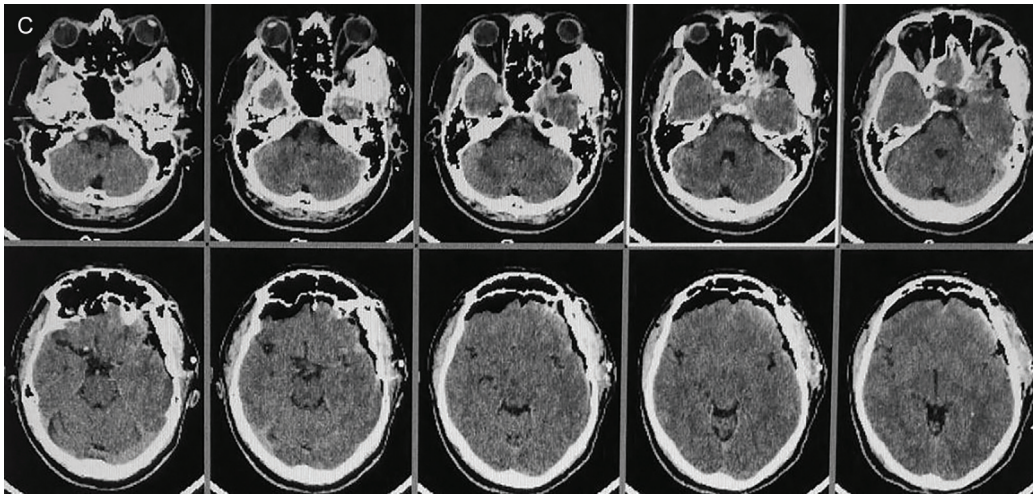


Fig. 4 (Continued)

Conflict of Interest

None declared.

References

- 1 Dsouza S, Kandula P, Kamath G, Kamath M. Clinical profile of unilateral proptosis in a tertiary care centre. *J Ophthalmol* 2017; 2017:8546458
- 2 De Jesús O, Toledo MM. Surgical management of meningioma en plaque of the sphenoid ridge. *Surg Neurol* 2001;55(05):265–269
- 3 Simas NM, Farias JP. Sphenoid wing en plaque meningiomas: surgical results and recurrence rates. *Surg Neurol Int* 2013;4:86
- 4 Shrivastava RK, Sen C, Costantino PD, Della Rocca R. Sphenoorbital meningiomas: surgical limitations and lessons learned in their long-term management. *J Neurosurg* 2005;103(03):491–497
- 5 Mirone G, Chibbaro S, Schiabello L, Tola S, George B. En plaque sphenoid wing meningiomas: recurrence factors and surgical strategy in a series of 71 patients. *Neurosurgery* 2009;65(6, Suppl):100–108, discussion 108–109
- 6 Maroon JC, Kennerdell JS, Vidovich DV, Abla A, Sternau L. Recurrent sphenoid-orbital meningioma. *J Neurosurg* 1994;80(02):202–208
- 7 Bikmaz K, Mrak R, Al-Mefty O. Management of bone-invasive, hyperostotic sphenoid wing meningiomas. *J Neurosurg* 2007;107(05):905–912
- 8 Venugopal M, Sagesh M. Proptosis: the ENT surgeon's perspective. *Indian J Otolaryngol Head Neck Surg* 2013;65(Suppl 2):247–250
- 9 Heier JS, Gardner TA, Hawes MJ, McGuire KA, Walton WT, Stock J. Proptosis as the initial presentation of fungal sinusitis in immunocompetent patients. *Ophthalmology* 1995;102(05):713–717
- 10 Aziz KM, Froelich SC, Cohen PL, Sanan A, Keller JT, van Loveren HR. The one-piece orbitozygomatic approach: the MacCarty burr hole and the inferior orbital fissure as keys to technique and application. *Acta Neurochir (Wien)* 2002;144(01):15–24
- 11 Elborady MA, Nazim WM. Spheno-orbital meningiomas: surgical techniques and results. *Egypt J Neurol Psychiat Neurosurg* 2021; 57(01):18
- 12 Schneider M, Potthoff AL, Borger V, et al. Outcome of tumor-associated proptosis in patients with spheno-orbital meningioma: single-center experience and systematic review of the literature. *Front Oncol* 2020;10:574074
- 13 Bowers CA, Sorour M, Patel BC, Couldwell WT. Outcomes after surgical treatment of meningioma-associated proptosis. *J Neurosurg* 2016;125(03):544–550
- 14 Fisher FL, Zamanipoor Najafabadi AH, Schoones JW, Genders SW, van Furth WR. Surgery as a safe and effective treatment option for spheno-orbital meningioma: a systematic review and meta-analysis of surgical techniques and outcomes. *Acta Ophthalmol* 2021;99(01):26–36
- 15 Idowu OO, Ashraf DC, Magill ST, Kersten RC, McDermott MW, Vagefi MR. Multidisciplinary frontotemporal orbitozygomatic craniotomy for spheno-orbital meningiomas: ophthalmic and orbital outcomes. *Ophthal Plast Reconstr Surg* 2021;37(01):18–26
- 16 Freeman JL, Davern MS, Oushy S, et al. Spheno-orbital meningiomas: a 16-year surgical experience. *World Neurosurg* 2017;99:369–380
- 17 Oya S, Kim SH, Sade B, Lee JH. The natural history of intracranial meningiomas. *J Neurosurg* 2011;114(05):1250–1256
- 18 Heller RS, David CA, Heilman CB. Orbital reconstruction for tumor-associated proptosis: quantitative analysis of postoperative orbital volume and final eye position. *J Neurosurg* 2019;132(03):927–932
- 19 Schick U, Bleyen J, Bani A, Hassler W. Management of meningiomas en plaque of the sphenoid wing. *J Neurosurg* 2006;104(02):208–214