



# Trans-Disc Aspiration of Anterior Cervical Cysts

Zahier Ebrahim<sup>1</sup> Armin Gretschel<sup>2</sup> Alex van der Horst<sup>1</sup> Adriaan J. Vlok<sup>1,3</sup>

<sup>1</sup>Department of Neurosurgery, Tygerberg Academic Hospital, Stellenbosch University, Cape Town, South Africa

<sup>2</sup>Department of Neurosurgery, Tygerberg Academic Hospital, Stellenbosch University, Cape Town, South Africa

<sup>3</sup>Department of Orthopaedic Surgery, Windhoek Central Hospital, Windhoek, Namibia

**Address for correspondence** Adriaan J. Vlok, Mmed Neurosurgery (SU), FC Neurosurgery (SA), PhD, Department Neurosurgery, Tygerberg Hospital, Stellenbosch University, Francie Van Zijl Drive, Parow, Cape Town, South Africa (e-mail: ianvlok@sun.ac.za).

Indian J Neurosurg

## Abstract

**Background** Spinal arachnoid cysts are rare entities occurring mainly in the cervical and thoracic spine. The majority of these lesions are treated through posterior approaches with laminectomy or laminotomy. We present trans-disc and trans-vertebral aspiration of anterior cervical arachnoid cysts as an alternative therapeutic approach.

**Methods** We present three cases and four procedures where anterior cervical arachnoid cysts were treated through an anterior trans-discal or trans-vertebral approach. A standard Smith–Robertson approach was used to expose the appropriate level in the cervical spine. A 22-gauge spinal needle is passed through the intervertebral disc or a 3-mm channel created in the midline of the vertebral body. This is performed under fluoroscopic guidance.

**Results** Three out of the four procedures resulted in complete clinical resolution at a 6-month follow-up. One patient required a repeat aspiration for a recurrent cyst at a level lower than the previous procedure. One patient had an initial improvement post-procedure followed by a functional decline within the first 5 postoperative days. Our assessment was that the cyst was re-filled and this was confirmed on magnetic resonance imaging (MRI). A standard posterior approach was used to excise the cyst with a good clinical result. Overall, no morbidity was suffered from the anterior approach.

**Conclusion** We believe this approach is a safe alternative to posterior intradural approaches. MRI scanning is advised at 6 months or earlier if clinical improvement is not demonstrated.

## Keywords

- ▶ cervical
- ▶ arachnoid cysts
- ▶ trans-disc

## Introduction

Spinal arachnoid cysts are rare entities occurring mainly in the thoracic or cervical spine.<sup>1</sup> Their etiology is linked to defects in the dura mater that may be congenital, traumatic, or iatrogenic. As a result, the arachnoid may protrude through these defects, thereby resulting in cyst formation.<sup>1,2</sup> Neurenteric cysts however are rare lesions that arise due to inappropriate partitioning of the

embryonic notochord plate and presumptive endoderm during the third week of development.<sup>1</sup> Often, these cysts may cause compression of the spinal cord resulting in clinical features of myelopathy.<sup>2,3</sup>

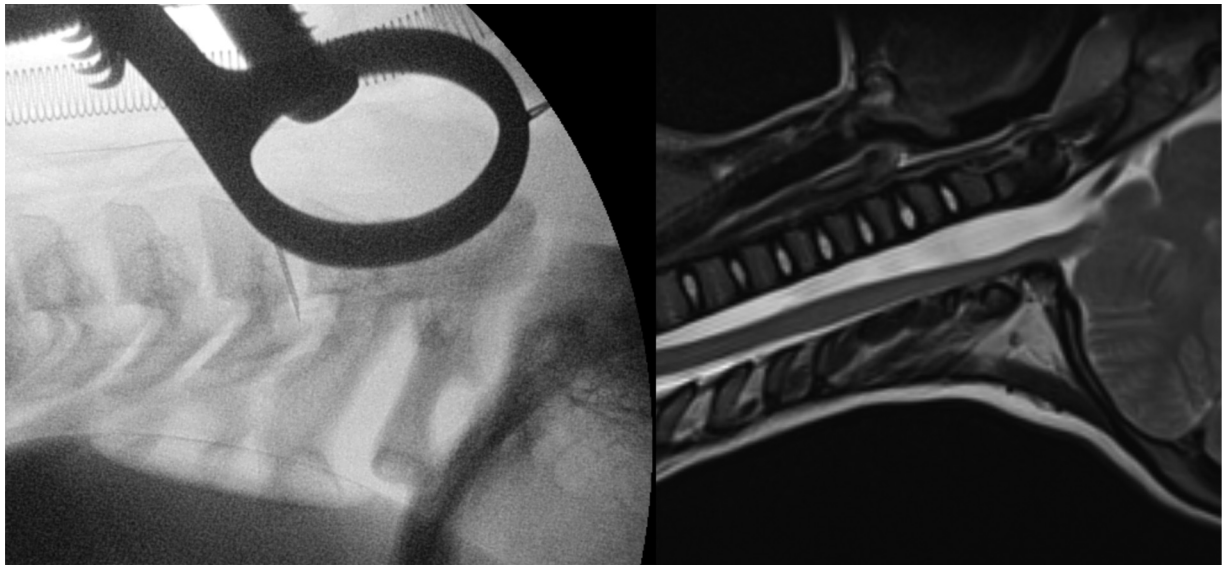
A review of the literature suggests that the majority of authors treat these lesions by posterior laminectomy or laminotomy.<sup>4–8</sup> Associated complications with this approach include progressive kyphotic deformities, especially in

DOI <https://doi.org/10.1055/s-0042-1744248>.  
ISSN 2277-954X.

© 2024. The Author(s).

This is an open access article published by Thieme under the terms of the Creative Commons Attribution License, permitting unrestricted use, distribution, and reproduction so long as the original work is properly cited. (<https://creativecommons.org/licenses/by/4.0/>)

Thieme Medical and Scientific Publishers Pvt. Ltd., A-12, 2nd Floor, Sector 2, Noida-201301 UP, India



**Fig. 1** Lateral X-ray of cervical spine showing position of spinal needle and sagittal T2 MRI of anterior cervical arachnoid cyst with mass effect on spinal cord.

children.<sup>9</sup> Some authors aim to minimize this by performing laminoplasties yet extensive soft-tissue dissection is still required. A few reports utilize decompression by anterior approaches via corpectomy as the long-term effect on mobility generally is significant considering a potential multilevel fusion. In addition, the technical challenges and risks of anterior cervical intradural work have to be considered. We describe a series of four procedures, whereby trans-disc and trans-vertebral aspiration of arachnoid cysts have been performed in the cervical spine.<sup>8-12</sup>

## Operative Technique

A standard Smith–Robinson approach was utilized to expose the appropriate level, supported by fluoroscopy. Once the level was identified and adequately exposed, a 22-gauge spinal needle with its stylet is passed through the disc (→**Fig. 1**) supported by continuous fluoroscopy. If the cyst is best accessed through the vertebral body as opposed to the disc, a small 3 mm channel is drilled up to the posterior longitudinal ligament in the midline. The spinal needle is then passed to drain the cyst. The cervical canal can accurately be measured preoperatively and correlated with fluoroscopy measurements making accurate needle (and specifically the bevel of the needle) placement possible. The bevel must be passed completely into the cyst at least 1 mm past the posterior vertebral body line or posterior margin of the disc. When the placement of the needle is confirmed, the stylet is removed and the cyst aspirated. Volume calculation of the cyst preoperatively guides the total volume aspirated safely.

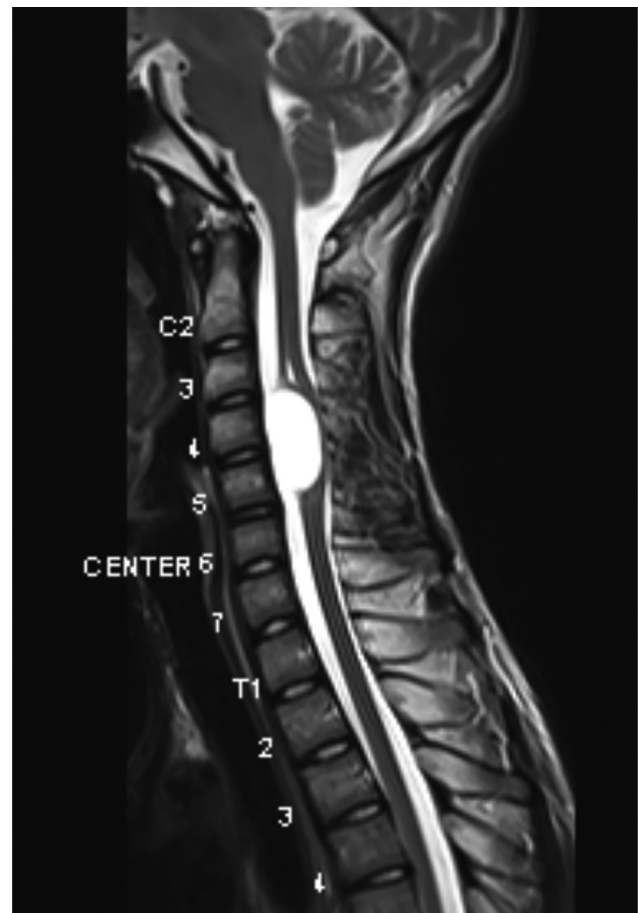
## Case Series

### Case 1

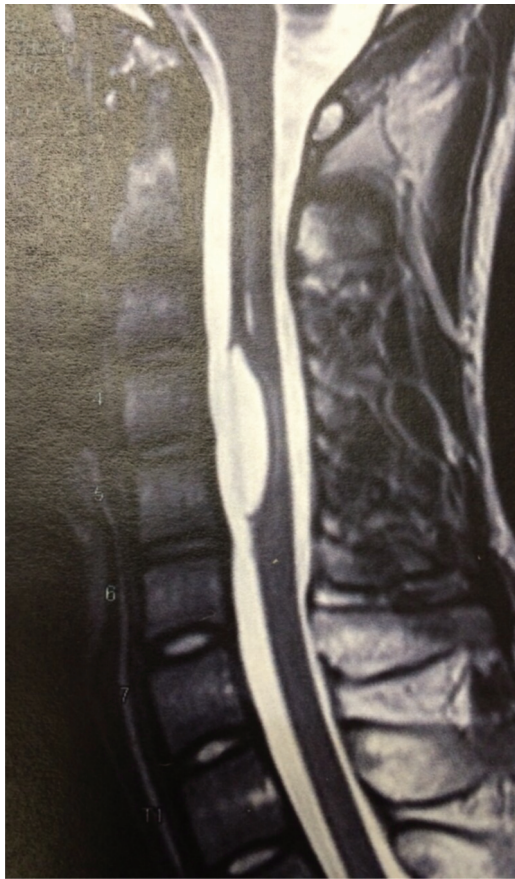A 23-year-old man, a builder by profession, presented with an extended history and clinical features suggestive of cervical myelopathy, rendering him bed-bound. Progressive

deterioration included loss of fine motor function, difficulty ambulating, and urinary incontinence.

A magnetic resonance imaging (MRI) scan demonstrated a large anterior cervical cyst dorsal to the C4 and C5 vertebral bodies (→**Fig. 2**).



**Fig. 2** T2-weighted image demonstrating an anterior cervical cyst.



**Fig. 3** Postoperative T2-weighted image demonstrating collapse of the cyst.

He was managed in an outreach facility with limited equipment. This prompted the senior author and his orthopedic colleague to attempt this procedure.

A trans-disc aspiration was performed as described in the operative technique above.

Postoperatively, the patient's symptoms resolved and he returned to his occupation unhindered. When reviewed at the 6-month outpatient clinic follow-up, he was noted to be asymptomatic with an unremarkable neurological examination. Repeat MRI showed a significantly smaller cyst remnant with a cerebrospinal fluid (CSF) flow void suggesting containment of the residual cyst (►Fig. 3).

The patient remained asymptomatic at subsequent outpatient clinic follow-up appointments.

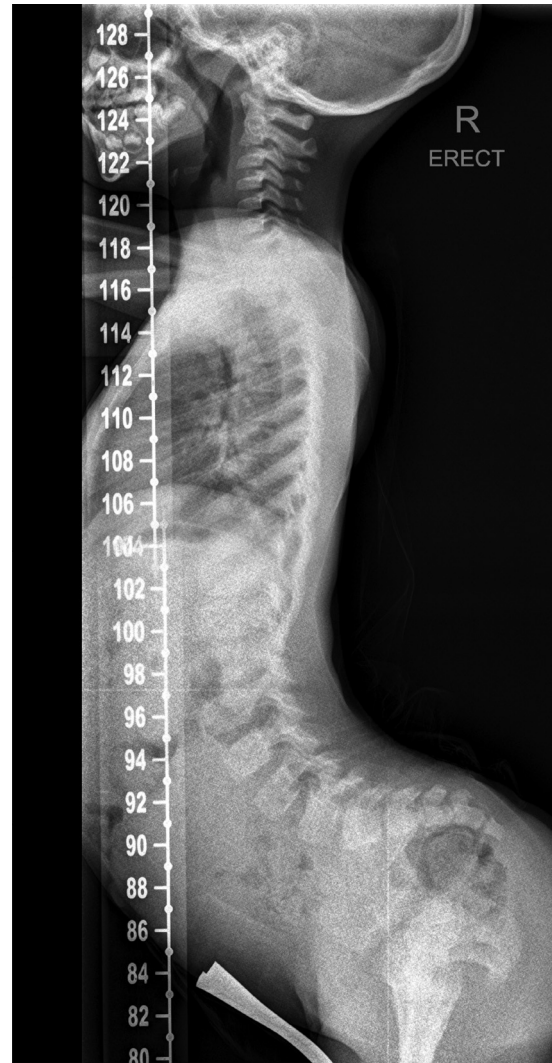### Case 2

A 6-year-old boy presented to the deformity clinic with a 3-month history of progressive difficulty to walk and at the time of presentation had an opisthotonic posture and was unable to ambulate.

With the exception of abnormal posture, his examination findings revealed a normal motor and sensory examination.

Plain film X-rays demonstrated an exaggerated lumbar lordosis but no scoliosis or bony defects (►Fig. 4).

MRI revealed a  $15 \times 10 \times 16$  mm cystic lesion with CSF signal characteristics and a thin hypointense rim on T2-



**Fig. 4** X-ray demonstrating opisthotonus.

weighted imaging, situated just inferior to the craniocervical junction (C1–C3). Significant pressure on the spinal cord was demonstrated with posterior compression (►Fig. 5).

The patient subsequently came forward for trans-disc aspiration of this cyst as per the operative technique described above.

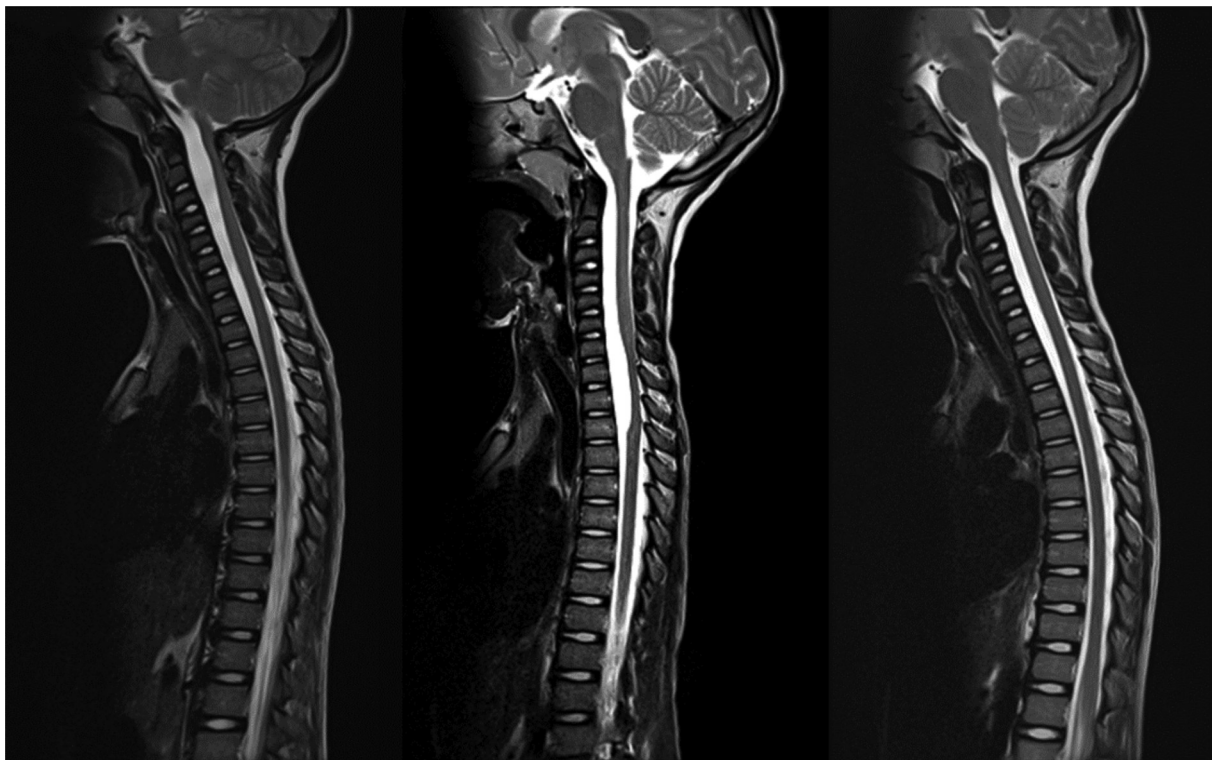
The patient's symptoms improved dramatically in the immediate postoperative period. His gait returned to normal and his opisthotonus resolved. He was discharged home on the third postoperative day, able to run already.

Nine months later, the patient re-presented with acute onset neck and back pain and opisthotonus. Once again, his clinical examination was unremarkable. He was symptom-free since the previous procedure.

An urgent MRI scan demonstrated no evidence of recurrence of the previously documented arachnoid cyst, but a new cystic lesion was noted from the C7 level to the T3 level with a mass effect on the spinal cord. No myelopathic changes were appreciated on this imaging (►Fig. 5).

A trans-disc aspiration was performed at the level in question (C7/T1). The procedure was uneventful and





**Fig. 5** Arachnoid cyst pre-aspiration, the second cyst demonstrated after initial cyst aspirated, follow-up at 3 months.

the patient regained complete function immediately postoperatively.

A 3-month follow-up MRI scan revealed complete decompression of the spinal cord with no evidence of the arachnoid cysts (→ **Fig. 5**). In hindsight, the second cyst can be appreciated in the first MRI yet was overshadowed by the large upper cervical cyst. There was no evidence of any changes to the intervertebral discs through which the needle was passed.

### Case 3

A 57-year-old male patient presented to our department with a 2-month history of neck pain and progressive quadriparesis. Examination revealed globally brisk reflexes, increased bilateral limb tone, 2/5 power in all limbs, and a sensory level at C3. MRI findings were consistent with an anterior cervical arachnoid cyst and spinal cord compression at the C2 level.

The patient came forward for a transoral trans-dens cyst aspiration.

The level was confirmed fluoroscopically and a 3 mm burr was used to create midline trans-oral access to the posterior cortex. A spinal needle was then used to enter the cyst and the contents aspirated.

The patient initially improved to power 4/5 in all limbs, but within 5 days returned to pre-surgical levels. A repeat MRI showed recurrence of the cyst, yet access to it was demonstrated. A repeat aspiration was performed and a similar postoperative course of initial improvement followed by deterioration back to the baseline was again observed. This led to an open posterior procedure with cyst

excision and subsequent clinical resolution of symptoms. At 3 months, the myelopathy resolved and a follow-up MRI demonstrated no cyst recurrence.

Histological analysis confirmed an arachnoid cyst.

### Discussion

There are only 24 previously reported cases of anterior cervical arachnoid cysts in the English literature.<sup>13,14</sup> Our series contributes an additional four to the existing body of knowledge but describes a novel method in the management thereof, which can be considered minimally invasive.

Surgical approaches to these cysts usually involve a laminectomy or laminoplasty with access to the cyst from a dorsolateral trajectory. Anterior cervical corpectomy is the alternative if posterior approaches cannot be used. These procedures are invasive and have associated morbidity. These include hemorrhage, possible CSF leaks due to challenging dural closures, and multilevel fusions after corpectomy with its associated restricted motion and complications over time.<sup>15</sup> It would be preferential to avoid these procedures when a safe alternative is available. Posterior approaches involving laminectomy or laminoplasty are associated with postoperative pain, wound sepsis risks, and potential kyphotic deformity over time.<sup>16</sup> Risk to neural structures is equally important in both approaches.

Three of the four procedures resulted in complete clinical resolution at the 6-month follow-up with excellent radiological results. No degeneration of the intervertebral disc through which the needle was passed could be

demonstrated on postoperative MRI scans. One patient initially improved and then slowly deteriorated within the first 5 postoperative days. The conclusion was that it re-filled and a standard posterior approach was utilized to excise the cyst after MRI confirmation with a good clinical result. No morbidity was suffered from the anterior approach.

We believe this approach is minimally invasive and should it fail, pose no ill effect to the patient nor the tissues involved with the benefit of potentially avoiding extensive procedures. MRI scanning is advised at 6 months or earlier if clinical improvement is not demonstrated.

#### Funding

No support (financial or other) was provided by any third party involved in this study.

#### Conflict of Interests

None declared.

#### References

- Muthukumar N. Anterior cervical arachnoid cyst presenting with traumatic quadriplegia. *Childs Nerv Syst* 2004;20(10):757–760
- Chan RC, Thompson GB, Bratty PJ. Symptomatic anterior spinal arachnoid diverticulum. *Neurosurgery* 1985;16(05):663–665
- Wenger M, Zobor N, Markwalder R, Vogt E, Markwalder TM. Intradural extramedullary arachnoid cyst of the thoracic spine associated with cord compression. *J Clin Neurosci* 2007;14(07):693–696
- Srinivasan US, Bangaari A, Senthilkumar G. Partial median corpectomy for C2–C3 intradural arachnoid cyst: case report and review of the literature. *Neurol India* 2009;57(06):803–805
- Chen HJ, Chen L. Traumatic interdural arachnoid cyst in the upper cervical spine. Case report. *J Neurosurg* 1996;85(02):351–353
- Silbergleit R, Brunberg JA, Patel SC, Mehta BA, Aravapalli SR. Imaging of spinal intradural arachnoid cysts: MRI, myelography and CT. *Neuroradiology* 1998;40(10):664–668
- Rao ZX, Li J, Hang SQ, You C. Congenital spinal intradural arachnoid cyst associated with intrathoracic meningocele in a child. *J Zhejiang Univ Sci B* 2010;11(06):429–432
- Fountas KN, Kapsalaki EZ, Nikolakakos LG, et al. Anterior cervical discectomy and fusion associated complications. *Spine* 2007;32(21):2310–2317
- Banczerowski P, Lipóth L, Vajda J, Veres R. Surgery of ventral intradural midline cervical spinal pathologies via anterior cervical approach: our experience. *Ideggyogy Sz* 2003;56(3–4):115–118
- Palmer JJ. Spinal arachnoid cysts. Report of six cases. *J Neurosurg* 1974;41(06):728–735
- Campos WK, Linhares MN, Brodbeck IM, Ruhland I. Anterior cervical arachnoid cyst with spinal cord compression. *Arq Neuropsiquiatr* 2008;66(2A):272–273
- Agnoli AL, Schönmayr R, Laun A. Intraspinal arachnoid cysts. *Acta Neurochir (Wien)* 1982;61(04):291–302
- Engelhardt J, Vignes JR. Anterior cervical intradural arachnoid cyst, a rare cause of spinal cord compression: a case report with video systematic literature review. *Eur Spine J* 2016;25(Suppl 1):19–26
- Rahimizadeh A, Sharifi G. Anterior cervical arachnoid cyst. *Asian Spine J* 2013;7(02):119–125
- Sarkar S, Nair BR, Rajshekhar V. Complications following central corpectomy in 468 consecutive patients with degenerative cervical spine disease. *Neurosurg Focus* 2016;40(06):E10
- Rashid M, Syed A, Ahmad I, Ekramullah. Giant thoracolumbar extradural arachnoid cyst: a case report. *Acta Orthop Belg* 2008;74(05):709–713