The Use of Robotic-Arm Assistance in Complex Primary Total Hip Arthroplasty: A Report of Three Challenging Cases

Ahmed Siddiqi, DO, MBA[1,2] Nicolas S. Piuzzi, MD[3] Paul Jacob, DO[4] Robert M. Molloy, MD[3] Michael Bloomfield, MD[3]

[1] Department of Orthopaedic Surgery, Hackensack Meridian Health, Edison, New Jersey
[2] Department of Orthopedic Surgery, Orthopaedic Institute Brielle Orthopaedics, Manasquan, New Jersey
[3] Department of Orthopaedic Surgery, Cleveland Clinic Foundation, Cleveland, Ohio
[4] Department of Orthopedic Surgery, Oklahoma Joint Reconstruction Institute, Oklahoma City, Oklahoma

Address for correspondence Ahmed Siddiqi, DO, MBA, Department of Orthopaedic Surgery, Hackensack Meridian Health, Edison, NJ 08820 (e-mail: asiddiqi89@gmail.com).

J Hip Surg 2022;6:80–90.

Abstract

The purpose of this case report was to demonstrate the utility, versatility, and efficacy of robotic-arm technology in complex primary total hip arthroplasty (THA) cases for acetabular bone loss, hip dysplasia, and post-traumatic arthritis with hardware. Preoperative computer templating allows precise and accurate acetabular and femoral stem positioning in cases that presented with significant native deformity and bone loss. Robotic-arm THA may be a viable option for complex primary cases to optimize implant positioning and mitigate postoperative instability and complications.

Keywords
- total hip arthroplasty
- robotic arm
- robotic-arm technology

Total hip arthroplasty (THA) is the most effective procedure for end-stage hip pathology in improving function and overall quality of life.[1–3] Despite overall THA success, there is still the potential for complications related to component malpositioning, leg-length discrepancy, dislocations, and early implant failures.[4] Robotic-assisted THA (RA-THA) has gained momentum to reduce surgical error by improving implant positioning accuracy and greater precision in restoring hip biomechanics.[5,6] Some studies have also proposed RA-THA to be associated with superior patient-reported outcome measures (PROMs), decreased instability rates, and higher forgotten joint scores.[6–9] However, the majority of the current literature has focused on the efficacy of RA-THA on cohorts of patients with primary hip osteoarthritis (OA).

THA for secondary hip OA including conditions with distorted anatomy presents surgeons with unique challenges such as variable hip centers, lack of bone stock, heterotopic ossification (HO), acetabular protrusion, abductor deficiency, prior infection, and retained hardware that hinder reconstruction. THA for secondary arthritis has been reported to be associated with longer operative duration, transfusion rates, hospital length of stay, intraoperative, and postoperative complications.[10–13] Meticulous planning and surgical technique may be enhanced by technology assistance to improve accuracy and mitigate complications. Therefore, the purpose of this case report was to demonstrate the utility and efficacy of robotic-arm technology in complex primary THA.

Case Report 1

History

A 67-year-old female with a history of tobacco abuse presented with severe right hip pain, inability to ambulate, and 2.5 cm shortening of the leg. She had received a

received
June 6, 2021
accepted after revision
January 4, 2022
published online
March 9, 2022

Thieme Medical Publishers, Inc., 333 Seventh Avenue, 18th Floor, New York, NY 10001, USA

DOI https://doi.org/10.1055/s-0042-1744132.
ISSN 2472-8446.

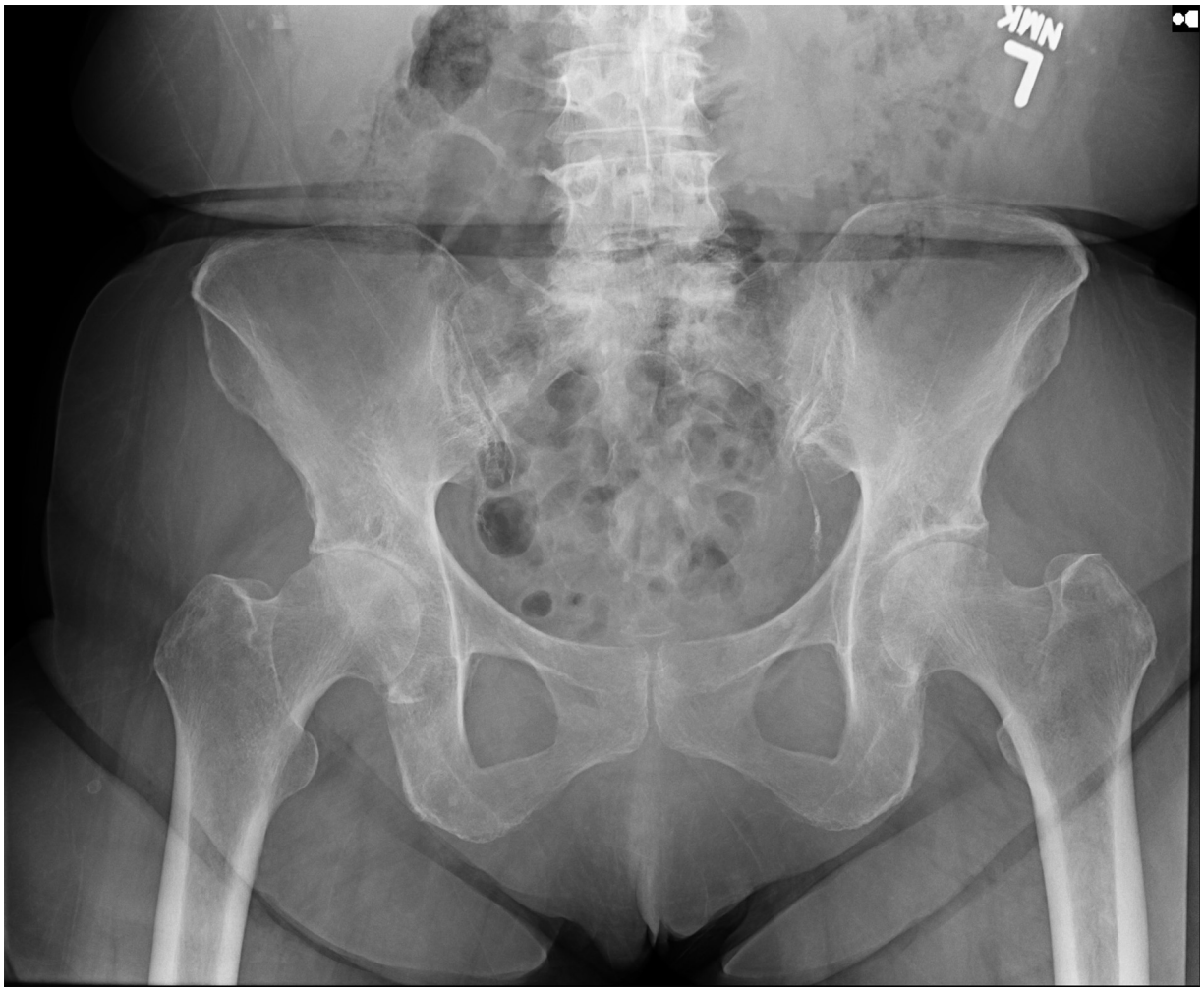

Fig. 1 Anteroposterior (AP) pelvis demonstrating end-stage osteoarthritis of the right hip.

corticosteroid injection 3 months prior (►**Fig. 1**) with subsequent rapid joint destruction and severe acetabular and femoral bone loss (►**Fig. 2**). After ruling out infectious etiology, the patient opted for RA-THA to allow for accurate bone preparation and implant placement.

Preoperative Planning and Intraoperative Implementation

The preoperative CT scan was obtained for reconstruction templating and planning. The acetabular component was sized and placed in the coronal, sagittal, and axial planes relative to host bone. The reconstruction was planned near the native hip center which allowed for fit between the remaining anterior and posterior walls (►**Fig. 3**). The acetabular component was planned to a more medialized and superior position to bolster the press fit into host bone. However, a superior acetabular augment was planned for the large segmental superior dome Paprosky type-IIB defect (►**Fig. 4**). After planning the femoral reconstruction, the approximate leg-length and offset restoration were planned for intraoperative execution.

The acetabular bone was registered with the optical navigation, and the registration was verified to ensure accuracy (►**Fig. 5**). The robotic arm was used to ream and impact the acetabulum according to the preoperative plan. Although the cup was significantly uncovered superiorly, a modest press fit between the anterior and posterior walls was provisionally achieved and augmented with four superior dome screws with dual mobility articulation. A superior acetabular augment was fixed to the ilium with three additional screws and unitized to the cup with cement. Due to the large segmental superior, the femur was broached, and after the placement of the final implants, the restoration of equal leg length and offset was verified using the robotic computer software.

Follow-Up

The patient recovered appropriately with functional improvement in pain, function, and radiographic osseointegration at short-term follow-up (►**Fig. 6**). Hip pain and function were assessed by hip-disability-and-osteoarthritis-outcome (HOOS) pain (0–100 points) and HOOS-physical-function short form (PS) (0–100 points), respectively, with higher scores indicating less pain and better function with a minimally clinically important difference of 10-points.[14–16] HOOS pain/HOOS–PS improved from 22.5/32.1 to 85/91.1 from

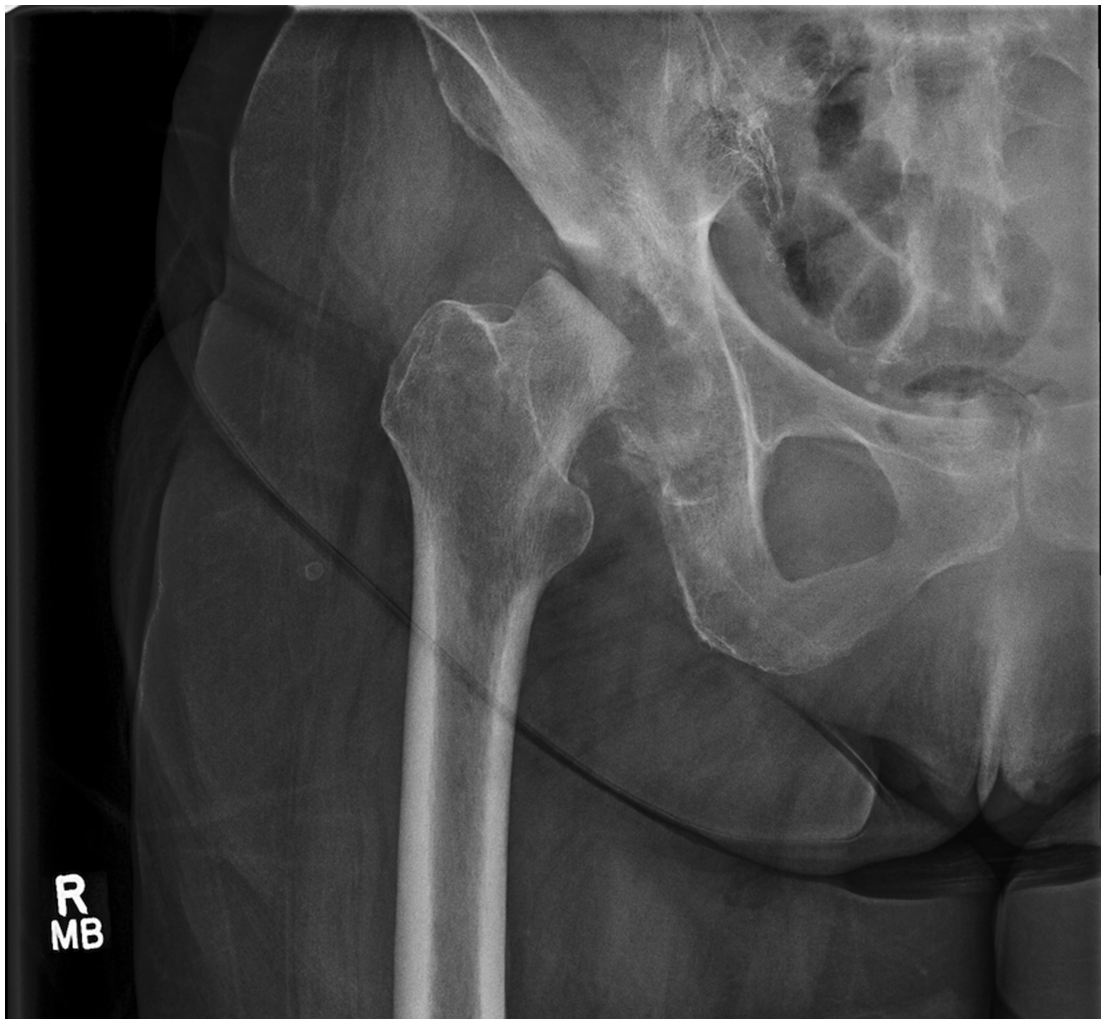

Fig. 2 Anteroposterior (AP) right hip plain radiograph demonstrating complete femoral head collapse with posterior, superior femoral head subluxation, and large superior acetabular defect (Paprosky IIB).

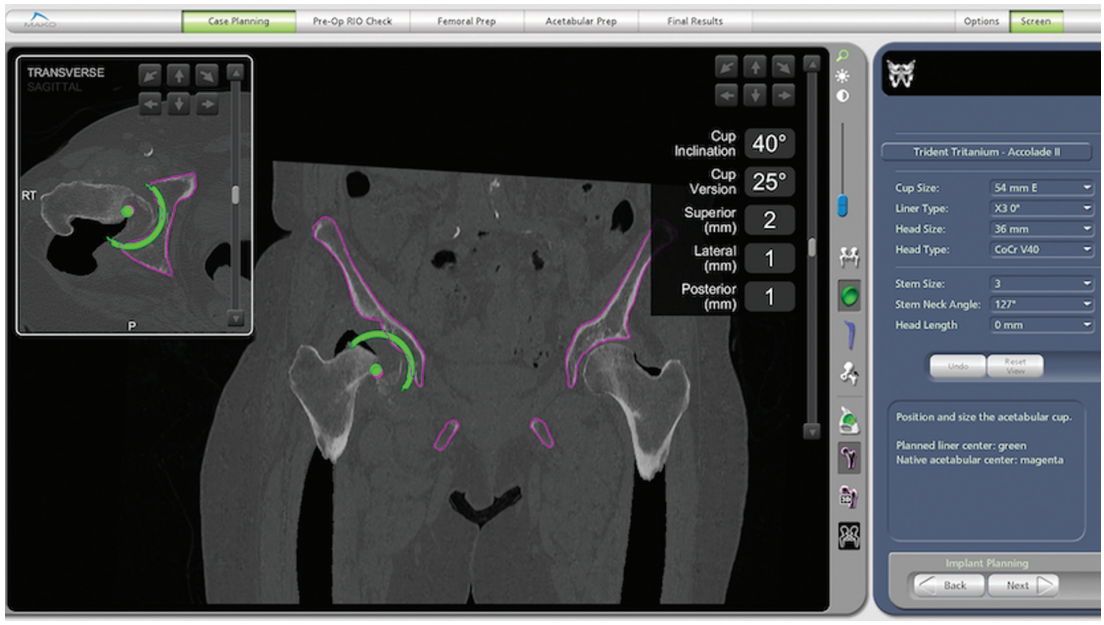

Fig. 3 Preoperative planning based on the CT scan. Acetabular positioning is fine tuned in the coronal, sagittal, and axial planes with the ability of positional adjustment within millimeters.

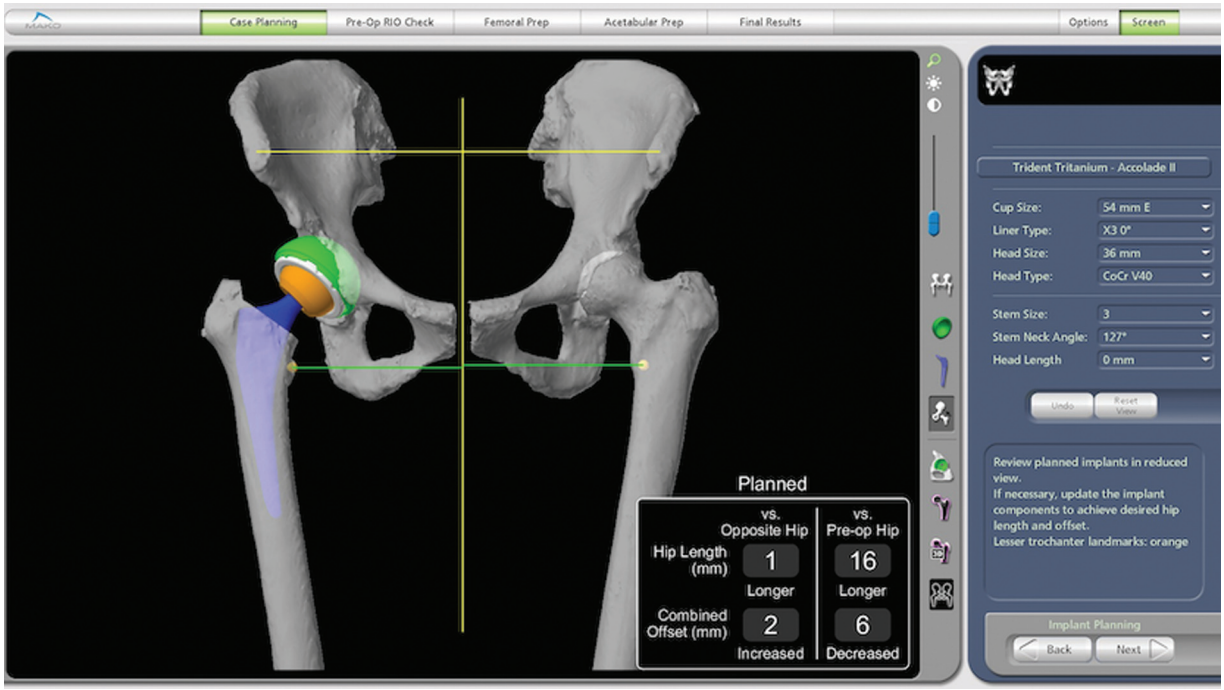

Fig. 4 Virtual 3D image of planned acetabular and femoral components with anticipated postoperative leg lengths and global offset.

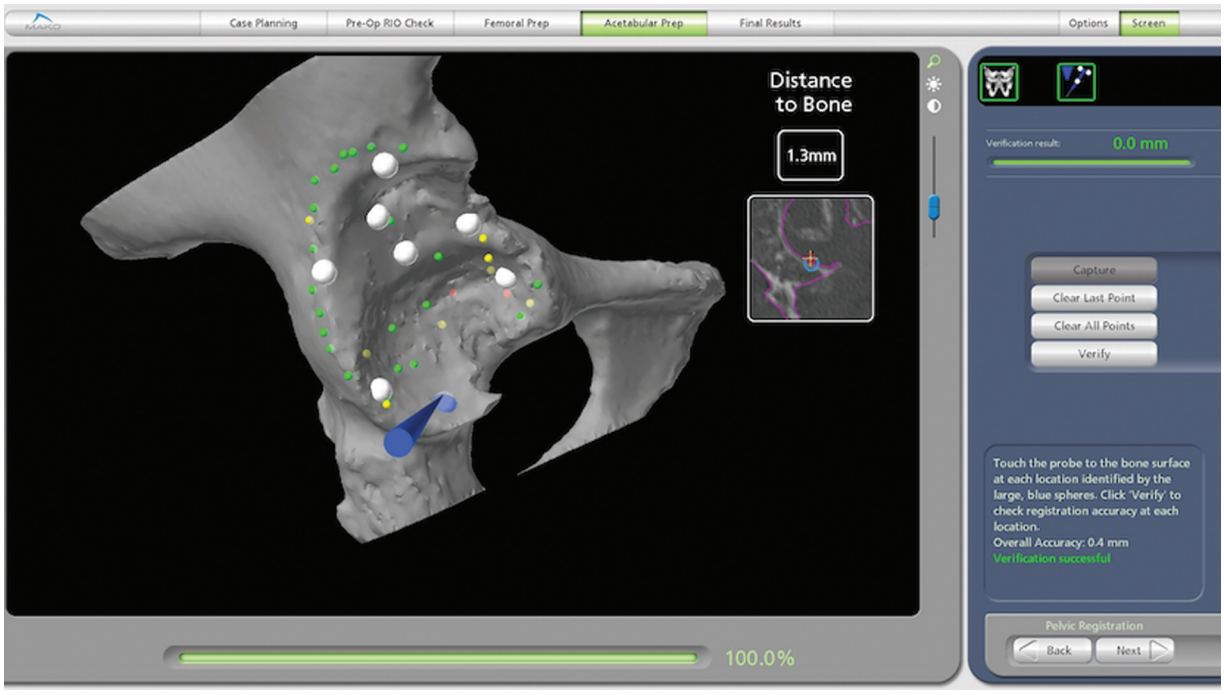

Fig. 5 Acetabular bony registration.

baseline to 1-year postoperatively, respectively. The University of California, Los Angeles (UCLA), Veterans-Rand-12 (VR-12) physical-component-score (PCS), and mental-component-scores (MCS) also improved from baseline to 1-year follow-up (2/16.8/36.9 to 4/29.1/56, respectively).

Case Report 2

History

A 35-year old female with a history of prior acetabular and femoral osteotomies as a child for hip dysplasia with

Fig. 6 One-year postoperative radiographs demonstrating acetabular component, superior augment, and femoral stem in stable alignment without signs of loosening or failure.

subsequent hardware removal presented with severe degenerative hip disease (►**Figs. 7** and **8**). Multiple conservative measures to relieve the symptoms were attempted without success. The patient opted for THA with the utilization of robotic-assisted technology for preoperative and intraoperative planning.

Preoperative Planning and Intraoperative Implementation

The preoperative CT scan helped define the native acetabulum with relative retroversion and a shallow medial wall. The robotic computer software helped place the acetabular component in the desired inclination and version to optimize positioning and stability (►**Fig. 9**). After acetabular bone registration, the robotic-arm assisted in reaming and final shell impaction to maintain proper abduction and anteversion. One screw was placed to augment initial stability.

With a prior femoral osteotomy and significant deformity, a proximally modular cementless femoral stem with distal splines was planned for femoral reconstruction. However, a cortical breach was identified distal to the calcar prior to inserting the trial sleeve. A prophylactic cerclage cable was placed to prevent any fracture propagation. A modular diaphyseal-engaging stem was used to bypass the defect. An intraoperative plain radiograph was taken to verify component position without evidence of fracture propagation (►**Fig. 10**). Final implants were placed, and there was no bone implant, bone–bone impingement, or instability throughout the range of motion. The leg length remained equal and unchanged from the initial robotic preoperative plan.

Follow-Up

The patient recovered without any complications immediately postoperatively to short-term follow-up. She remained toe-touch partial weight bearing for 4 weeks and progressively advanced to weight bearing as tolerated over the subsequent 6 weeks. HOOS-pain/HOOS-PS improved from 50/66.1 to 97/99 from baseline to 1-year follow-up, respectively. UCLA, VR-12 PCS and MCS also improved from baseline to 1-year follow-up (3/33.1/31.4 to 4/65.3/71.1, respectively). One-year follow-up radiographs demonstrated appropriately positioned implants without signs of implant subsidence, loosening, or failure (►**Fig. 11**).

Fig. 7 Preoperative AP pelvis demonstrating right hip coxa vara deformity with end-stage osteoarthritis.

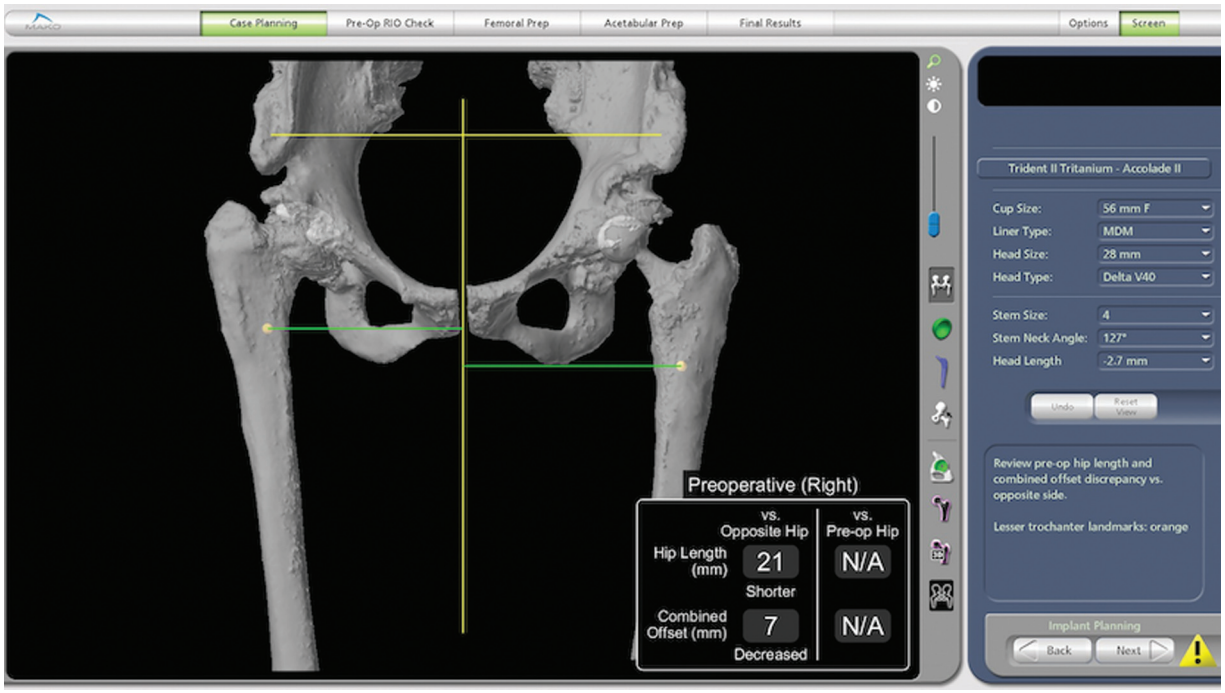

Fig. 8 Virtual 3D model demonstrating significant acetabular and femoral deformity.

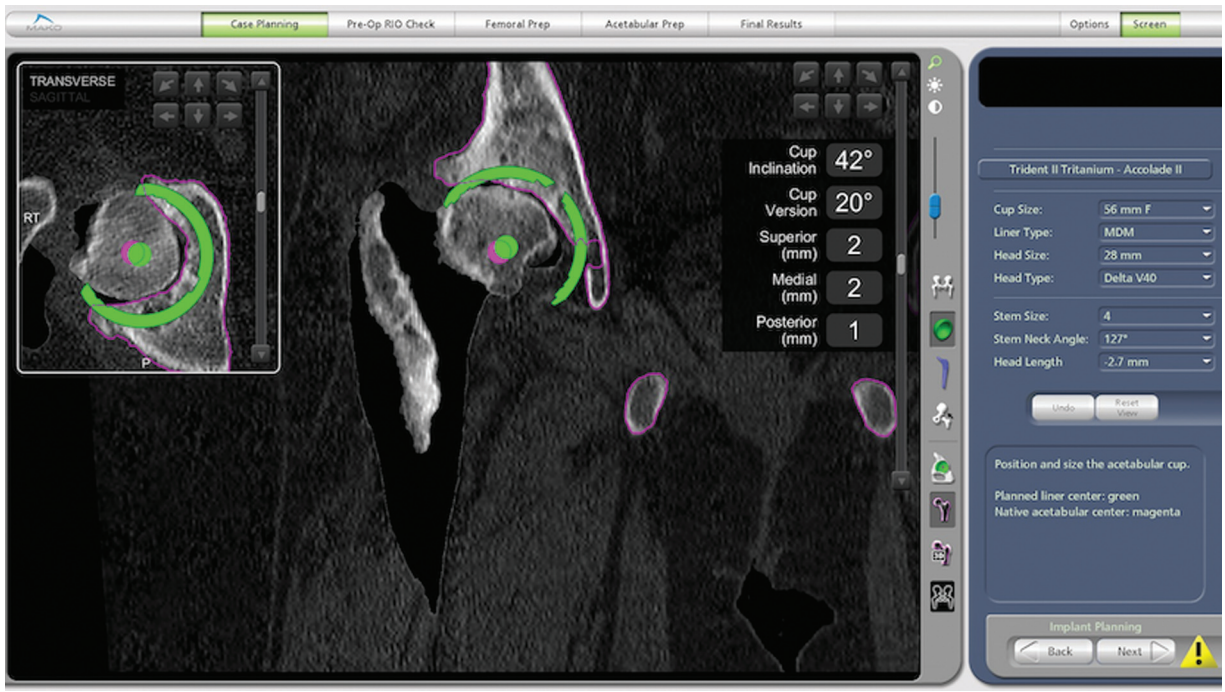

Fig. 9 Preoperative 3D acetabular component position planning. The implant was placed 2 mm superior and medial to allow maximal bone contact and implant coverage.

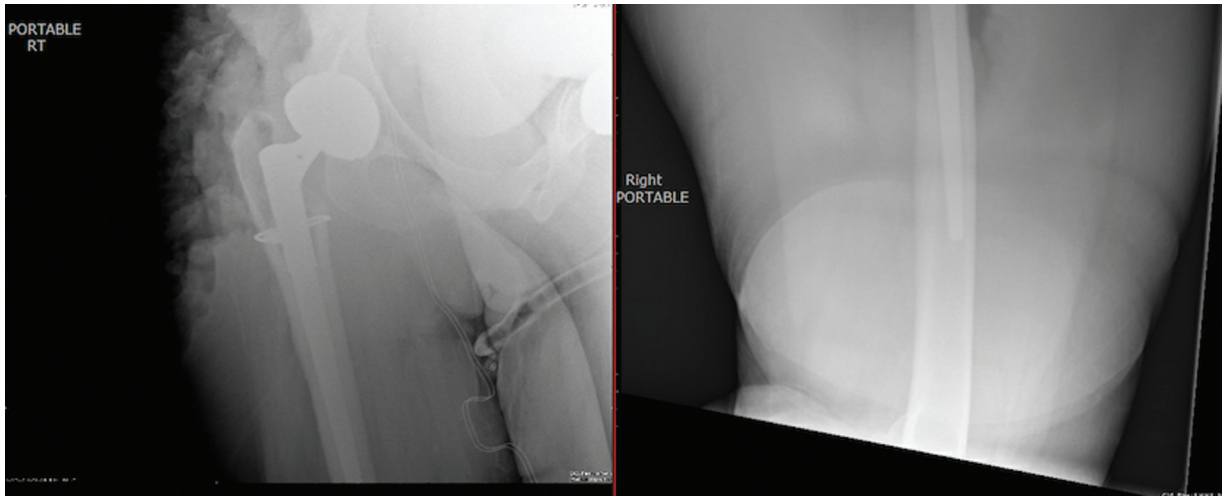

Fig. 10 Intraoperative flat-plate plain radiograph demonstrating stable implants without fracture propagation.

Case Report 3

History

A 67-year-old male with a history of pelvic fracture and posterior wall acetabular operative fixation 7-years prior presented with right hip pain. The patient had end-stage femoral head avascular necrosis with complete superior margin collapse (►**Figs. 12** and **13**). His clinical exam demonstrated right leg to be shorter than left (5 mm), and complete loss of range of motion. After unsuccessful conservative treatment, the patient opted for THA with the utilization of a robotic arm for preoperative and intraoperative planning given his prior acetabular hardware and deformity.

Preoperative Planning and Intraoperative Implementation

The robotic-system software allowed for accurate implant placements based on the anatomic boundaries for accurate intraoperative execution (►**Fig. 14**). The preoperative CT scan was critical in implant positioning planning to avoid the posterior wall hardware by allowing positional adjustments within a few millimeters. To circumvent the pre-existing hardware, the acetabulum preparation was planned 2 mm more superiorly and 1 mm posteriorly relative to the native center.

The robotic arm assisted with acetabulum reaming and component implantation (►**Fig. 13**). The femoral stem was then impacted, and trial reduction was performed. Once

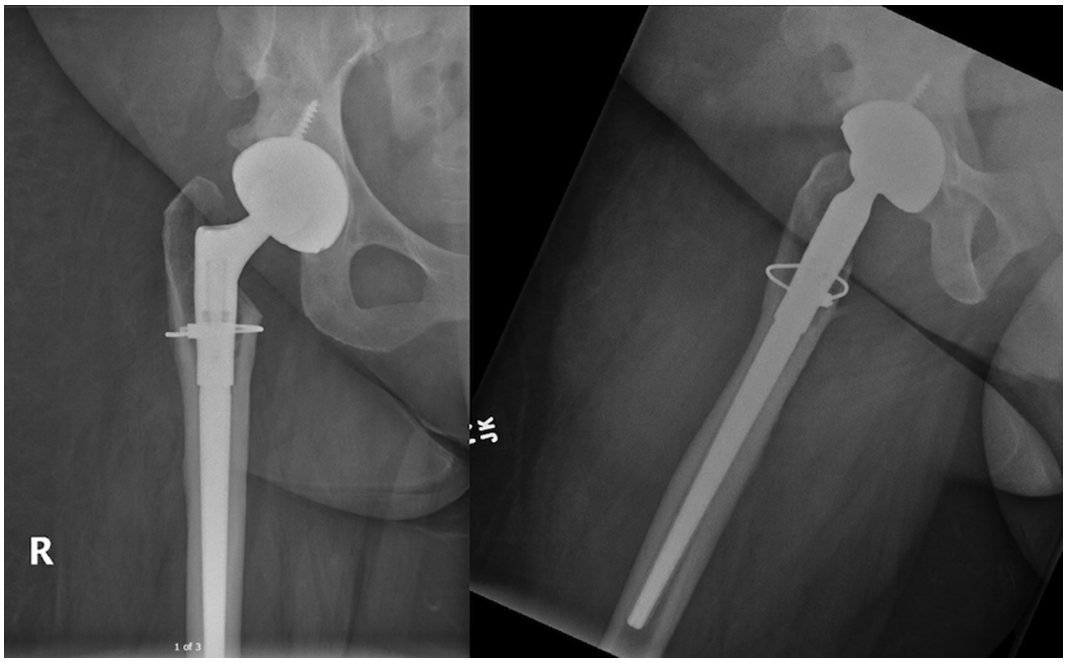

Fig. 11 One-year follow-up radiographs demonstrated appropriately positioned implants without signs of implant subsidence, loosening, or failure.

Fig. 12 Preoperative plain radiographs demonstrating right hip acetabular hardware.

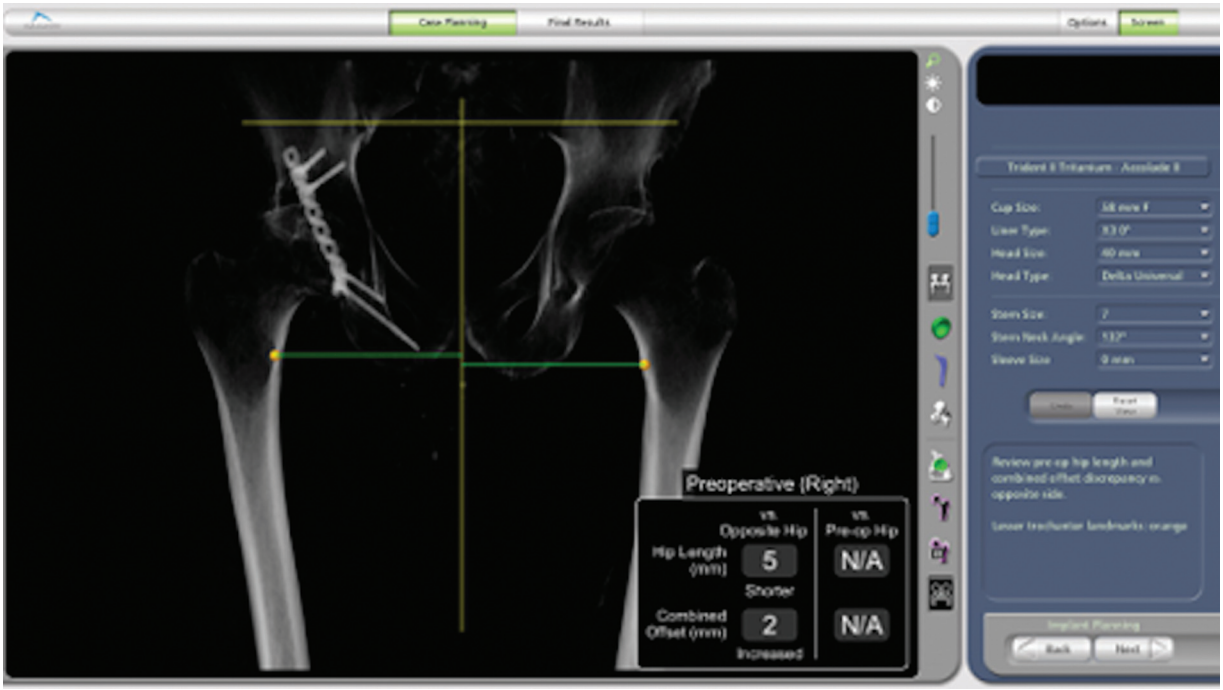

Fig. 13 Preoperative plain radiographs demonstrating acetabular hardware with the robotic computer software.

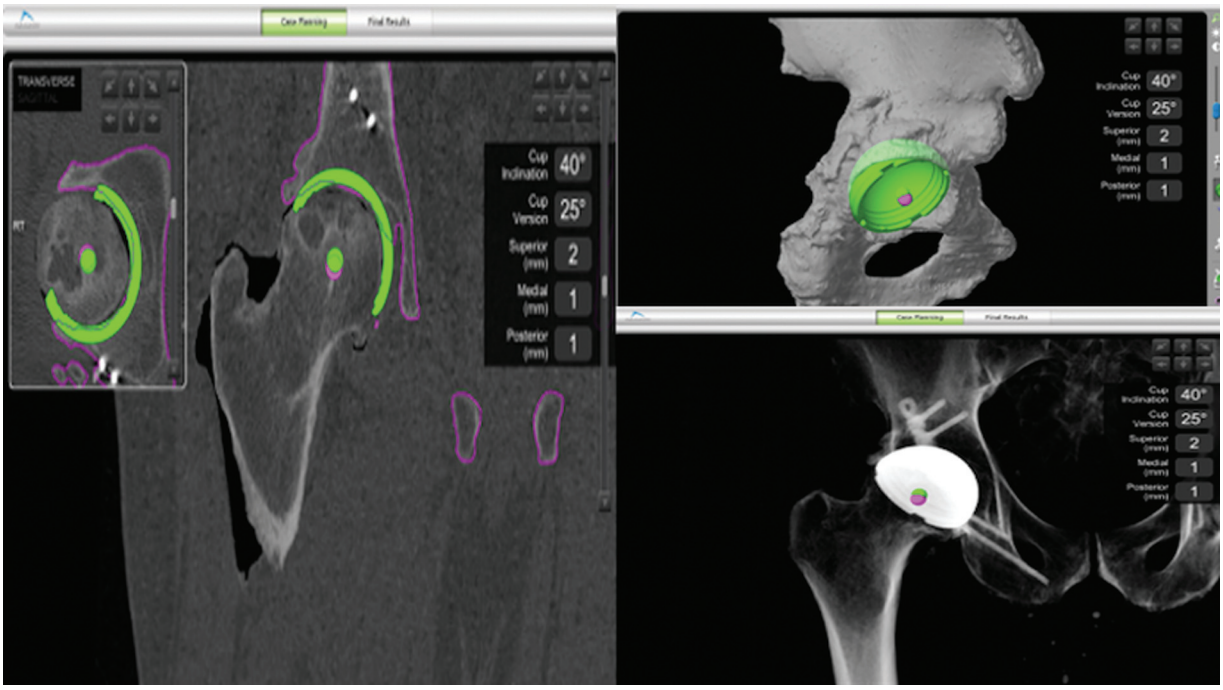

Fig. 14 Preoperative 3D acetabular component position planning.

stability and limb length were confirmed, final implants were placed and verified using the robotic computer software (►**Fig. 15**).

Follow-Up

The patient had an uncomplicated postoperative course without any complications at 6-week routine evaluation. He achieved all his physical therapy goals and was off all pain medications. One-year follow-up radiographs demonstrated appropriately positioned implants without signs of implant subsidence, loosening, osteolysis, or failure. HOOS-pain/function scores improved from 20/30 preoperatively to 92/100 at 1-year follow-up.

Discussion

Acetabular bone loss, hip dysplasia with prior osteotomies, and post-traumatic arthritis with hardware are challenging

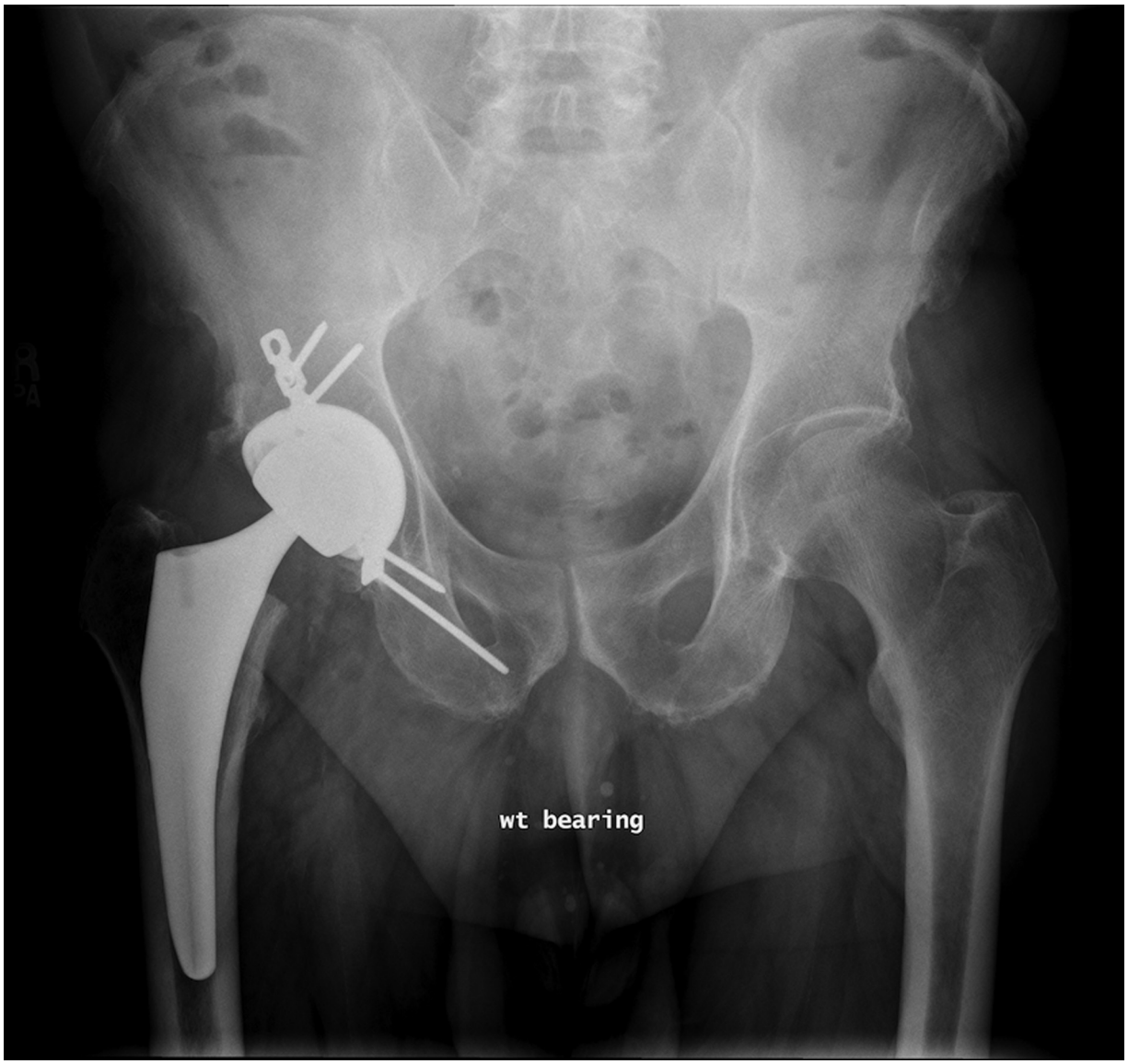

Fig. 15 Planned postoperative radiographs with leg-length and offset restoration.

situations when performing primary THA. RA-THA offers surgeons a unique ability to anticipate and prevent potential technical pitfalls and allows preoperative three-dimensional templating of implants according to a patient's individual anatomy. RA-THA has been generally reserved for simpler primary OA and avascular necrosis cases with normal anatomy for landmark registration. However, as technology continues to evolve and become increasingly prevalent in arthroplasty, the value of robotics and its versatility will continue to increase, especially in more challenging THA procedures as presented in our case reports.

Bukowski et al[17] compared estimated blood loss, complications, and PROMs between 100 RA-THA and 100 conventional THA patients. The estimated intraoperative blood loss was significantly reduced for RA-THA compared with manual THA (374 ± 133 vs. 423 ± 186 mL, respectively, $p = 0.035$). RA-THA reported significantly higher mean postoperative Harris Hip Scores (HHS) (92.1 ± 10.5 vs. 86.1 ± 16.2, $p = 0.002$) and UCLA scores (6.3 ± 1.8 vs. 5.8 ± 1.7, $p = 0.033$) compared with conventional THA at 1-year follow-up. More recently, Domb et al[18] reported 5-year midterm outcomes of 66 RA-THA that were propensity matched with 66 conventional THA. The RA-THA cohort reported higher HHS ($p < 0.001$), forgotten joint scores ($p = 0.002$), VR-12 PCS ($p = 0.002$), and 12-item short-form survey physical ($p = 0.001$). RA-THA acetabular cup placement had a nine-fold reduced risk of placement outside the Lewinnek safe zone[19] ($p = 0.002$), fewer discrepancies in leg length ($p = 0.091$), and overall offset ($p = 0.001$).

Most studies comparing RA-THA and conventional-THA have involved small patient cohorts. However, in a recent systematic review and meta-analysis, Chen et al.[4] compared 522 RA-THA and 994 conventional-THA. RA-THA was associated with lower intraoperative complication rates, more accurate cup placement within the safe zone, stem placement, and overall offset with no differences in leg-length discrepancy and revision rates. Pooled analysis of functional outcome scores found no significant differences between RA-

THA and conventional THA, with significant heterogeneities both preoperatively ($p = 0.27$, $I^2 = 87\%$) and 24 months postoperatively ($p = 0.38$, $I^2 = 68\%$). The rate of HO was significantly higher in RA-THA patients, which the authors potentially attributed to pin site placement. Further investigation is warranted to determine if RA-THA is linked with greater HO regardless of the surgical approach.

Conclusion

We reported three, complex primary THA cases that were performed with robotic-arm technology. Acetabular and femoral stem placement was planned preoperatively using the computer software with CT-scan integration. Preoperative templating allowed precise and accurate acetabular and femoral stem positioning in cases that presented with significant native deformity and bone loss. RA-THA may be a viable option for complex primary cases to optimize implant positioning and mitigate postoperative instability and complications. Future studies are needed to determine long-term improvement in PROMs, implant longevity, and revision rates with the utilization of robotic-arm technology.

Informed Consent

Each patient consented to have their THA data submitted for publication.

Conflict of Interest

None declared.

References

1 Ethgen O, Bruyère O, Richy F, Dardennes C, Reginster JY. Health-related quality of life in total hip and total knee arthroplasty. A qualitative and systematic review of the literature. J Bone Joint Surg Am 2004;86(05):963–974

2 Singh JA, Lewallen DG. Increasing obesity and comorbidity in patients undergoing primary total hip arthroplasty in the U.S.: a 13-year study of time trends. BMC Musculoskelet Disord 2014; 15:441

3 Yang EI, Hong G, Gonzalez Della Valle A, et al. Trends in inpatient resource utilization and complications among total joint arthroplasty recipients: a retrospective cohort study. J Am Acad Orthop Surg Glob Res Rev 2018;2(10):e058

4 Chen X, Xiong J, Wang P, et al. Robotic-assisted compared with conventional total hip arthroplasty: systematic review and meta-analysis. Postgrad Med J 2018;94(1112):335–341

5 Nodzo SR, Chang CC, Carroll KM, et al. Intraoperative placement of total hip arthroplasty components with robotic-arm assisted technology correlates with postoperative implant position: a CT-based study. Bone Joint J 2018;100-B(10):1303–1309

6 Redmond JM, Gupta A, Hammarstedt JE, Petrakos A, Stake CE, Domb BG. Accuracy of component placement in robotic-assisted total hip arthroplasty. Orthopedics 2016;39(03):193–199

7 Tsai TY, Dimitriou D, Li JS, Kwon YM. Does haptic robot-assisted total hip arthroplasty better restore native acetabular and femoral anatomy? Int J Med Robot 2016;12(02):288–295

8 Perets I, Walsh JP, Close MR, Mu BH, Yuen LC, Domb BG. Robot-assisted total hip arthroplasty: clinical outcomes and complication rate. Int J Med Robot 2018;14(04):e1912

9 Chai W, Guo RW, Puah KL, Jerabek S, Chen JY, Tang PF. Use of robotic-arm assisted technique in complex primary total hip arthroplasty. Orthop Surg 2020;12(02):686–691

10 Siddiqi A, White PB, Sloan M, et al. Total hip arthroplasty for developmental dysplasia of hip vs osteoarthritis: a propensity matched pair analysis. Arthroplast Today 2020;6(03):607–611.e1

11 Moya-Angeler J, Lane JM, Rodriguez JA. Metabolic bone diseases and total hip arthroplasty: preventing complications. J Am Acad Orthop Surg 2017;25(11):725–735

12 Stibolt RD Jr, Patel HA, Huntley SR, Lehtonen EJ, Shah AB, Naranje SM. Total hip arthroplasty for posttraumatic osteoarthritis following acetabular fracture: a systematic review of characteristics, outcomes, and complications. Chin J Traumatol 2018;21(03): 176–181

13 Lu M, Phillips D. Total hip arthroplasty for posttraumatic conditions. J Am Acad Orthop Surg 2019;27(08):275–285

14 Nilsdotter AK, Lohmander LS, Klässbo M, Roos EM. Hip disability and osteoarthritis outcome score (HOOS)—validity and responsiveness in total hip replacement. BMC Musculoskelet Disord 2003;4:10

15 Davis AM, Perruccio AV, Canizares M, et al. The development of a short measure of physical function for hip OA HOOS-physical function shortform (HOOS-PS): an OARSI/OMERACT initiative. Osteoarthritis Cartilage 2008;16(05):551–559

16 Paulsen A, Roos EM, Pedersen AB, Overgaard S. Minimal clinically important improvement (MCII) and patient-acceptable symptom state (PASS) in total hip arthroplasty (THA) patients 1 year postoperatively. Acta Orthop 2014;85(01):39–48

17 Bukowski BR, Anderson P, Khlopas A, Chughtai M, Mont MA, Illgen RL II. Improved functional outcomes with robotic compared with manual total hip arthroplasty. Surg Technol Int 2016;29:303–308

18 Domb BG, Chen JW, Lall AC, Perets I, Maldonado DR. Minimum 5-year outcomes of robotic-assisted primary total hip arthroplasty with a nested comparison against manual primary total hip arthroplasty: a propensity score-matched study. J Am Acad Orthop Surg 2020;28(20):847–856

19 Lewinnek GE, Lewis JL, Tarr R, Compere CL, Zimmerman JR. Dislocations after total hip-replacement arthroplasties. J Bone Joint Surg Am 1978;60(02):217–220

