


# Nasal Septal Perforation Reconstruction with Polydioxanone Plate: A Systematic Review

Marc Levin, MD<sup>1</sup> Hedyeh Ziai, MD<sup>1</sup> Justin Shapiro, MSc<sup>2</sup> Michael G. Roskies, MD, MSc, FRCSC<sup>3,4</sup>

<sup>1</sup>Department of Otolaryngology—Head and Neck Surgery, University of Toronto, Toronto, Ontario, Canada

<sup>2</sup>Temerty Faculty of Medicine, University of Toronto Temerty, Toronto, Ontario, Canada

<sup>3</sup>Department of Otolaryngology—Head and Neck Surgery, University of Toronto Faculty of Medicine, Mount Sinai Hospital, Toronto, Ontario, Canada

<sup>4</sup>Division of Facial Plastic and Reconstructive Surgery, Sinai Health System, Toronto, Ontario, Canada

Address for correspondence Justin Shapiro, MSc, Temerty Faculty of Medicine, University of Toronto, 1 King's College Circle, Toronto, Ontario M5S 1A8, Canada (e-mail: justin.shapiro@mail.utoronto.ca).

Facial Plast Surg 2022;38:428–433.

## Abstract

Nasal septal perforation is an uncommon pathology that is difficult to surgically repair and may significantly impact patients' quality of life. Existing treatments have high complication and failure rates. The use of polydioxanone (PDS) plates to repair septal perforations is an innovative approach that has demonstrated superior outcomes to the conventional techniques. This study aimed to review the literature on PDS plates for nasal septal perforation reconstruction. PubMed, OVID Medline, and OVID Embase databases were searched for relevant articles in June 2021. Search terms included nasal septal perforation, polydioxanone, septal perforation, septal repair, nasal septum, and PDS plate. The Preferred Reporting Items for Systematic Reviews and Meta-analyses (PRISMA) guidelines were adhered to for this systematic review. Database searches yielded 80 articles. Seven articles were included representing 74 patients. All studies reported the use of PDS plates in addition to other materials. They all reported closure rates of at least 80%. The majority of studies reported no postoperative complications. Nasal septal perforation reconstruction with PDS plates is a promising approach that has demonstrated positive outcomes. Further larger studies are required to evaluate the long-term efficacy of using PDS plates on patients with septal perforations.

## Keywords

- ▶ nasal septal perforation
- ▶ septal reconstruction
- ▶ PDS plate
- ▶ polydioxanone plate

Nasal septal perforations are a relatively uncommon pathology that can occur due to trauma, iatrogenic causes, and inhalation drug use among others.<sup>1,2</sup> Perforations can cause symptoms of chronic epistaxis, nasal crusting, congestion, and whistling when breathing.<sup>2</sup> These symptoms can significantly impact patient quality of life.

Repair of septal perforations poses a challenge for the surgeon. From a conservative perspective, perforations can be managed with a septal button.<sup>3</sup> However, septal buttons can be uncomfortable and hard to fit.<sup>3,4</sup> For larger perforations, a local rotational/advancement/free flap reconstruction approach can be used.<sup>2</sup> These flap reconstructions can be technically challeng-

ing with high complication and failure rates.<sup>2</sup> Hence, innovative techniques have been described aiming at improving reconstruction of septal perforations. In the last decade, there have been a limited number of articles published on the use of a polydioxanone (PDS) plate to aid with reconstruction of septal perforations.<sup>5–11</sup> PDS is a resorbable polymer that is completely metabolized by the body.<sup>12</sup> The PDS plate itself is not actually the material that closes septal perforations. Rather, PDS plates act as the scaffold that supports the recipient's tissue to regenerate over the perforated septum.<sup>12</sup> In a systematic review that evaluated 49 clinical trials and 104 articles, PDS sutures, plates, and mesh were found to have low rates of inflammatory reactions,

Issue Theme Functional Facial Plastic Surgery; Guest Editors: Clinton D. Humphrey, MD, FACS, and J. David Kriet, MD, FACS

© 2022, Thieme. All rights reserved. Thieme Medical Publishers, Inc., 333 Seventh Avenue, 18th Floor, New York, NY 10001, USA

DOI <https://doi.org/10.1055/s-0042-1743251>. ISSN 0736-6825.

foreign body responses, surgical site infections, and postoperative fevers. For example, PDS plates had a surgical site infection rate below 10%.<sup>13</sup> Hence, early research has shown that PDS plates may be a safe and effective way to provide a template for the attachment of tissue grafts to facilitate septal perforation reconstruction without the long-term complications of synthetic grafts.<sup>12</sup> The results of these studies have been promising, showing successful closure of septal perforations with PDS plates.

Despite this aforementioned literature, there is no published collective report on the use of PDS plates in septal reconstruction. Hence, the purpose of this article was to review the literature on PDS plates for nasal septal perforation reconstruction. With such a unified understanding of this technique, surgeons may be able to provide up-to-date, evidence-based care for their patients.

## Materials and Methods

The Preferred Reporting Items for Systematic Reviews and Meta-analyses (PRISMA) guidelines were adhered to for this systematic review.<sup>14</sup>

### Search

PubMed, OVID Medline, and OVID Embase databases were searched on June 20, 2021. Search terms included nasal septal perforation, polydioxanone, septal perforation, septal repair, nasal septum, and PDS plate. These terms were combined with Boolean search terms, AND or OR.

### Inclusion/Exclusion Criteria

Prospective and retrospective articles that met inclusion criteria focused on the use of PDS plate for reconstruction of a nasal septum perforation. Articles that used PDS plates for reconstruction of septal deviations (septoplasty) and/or cosmetic rhinoplasty/septorhinoplasty were excluded. Articles that were not in

English, had not undergone peer-review, and/or those that did not report original data, such as editorials, letters to the editor, review articles and conference abstracts, were excluded.

### Article Selection/Data Extraction and Analysis

Two independent reviewers (M.L. and H.Z.) engaged in article title/abstract screening, and full-text screening according to the inclusion and exclusion criteria. This review was completed using Covidence (Covidence systematic review software; Veritas Health Innovation, Melbourne, Australia). A third reviewer (M.G.R.) was introduced if consensus regarding an article's inclusion could not be agreed upon.

Data were then extracted from the articles that met inclusion criteria. Such data included the following: study demographic information, included patient symptoms, type of repair completed, materials other than PDS used in repair, results, and complications. Pooled analysis was completed across all included studies regarding patient symptoms, perforation etiology, and closure rates.

The data were organized on a Microsoft Excel worksheet and then analyzed using R software. Descriptive statistics was completed.

## Results

### Article Inclusion

From the initial search which yielded 80 articles, 11 were selected after title and abstract screening. Following full-text screening, seven articles were selected for final inclusion and data extraction (►Fig. 1). The majority of the included articles were from the United States of America ( $n=4$ ).<sup>6,8,10,11</sup> Most articles were published in the last decade (six or seven published in or after 2011).<sup>5-8,10,11</sup> A detailed description of the included studies can be found in ►Table 1.

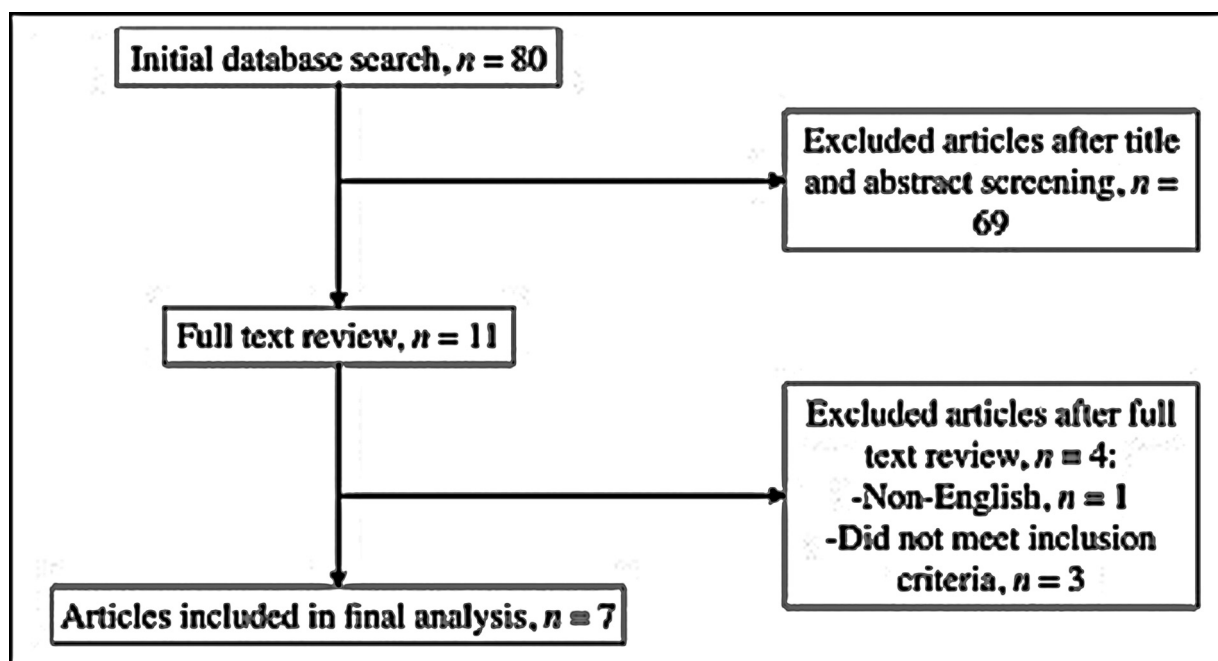


Fig. 1 The Preferred Reporting Items for Systematic Reviews and Meta-analyses (PRISMA) flow diagram.

### Patient Demographics

A total of 74 patients were included in this review. The age of included patients ranged from 3 to 61 years. Overall, ages were reported for 65 of 74 (87.8%) patients across all seven studies. The mean age across all patients was 37 years. The pooled distribution of the included patients' etiologies of septal perforation were as follows: 27 of 74 (36.5%) patients received prior surgery or septoplasty, 12 of 74 (16.2%) patients had trauma-related septal perforation (including one patient from a gunshot wound), 8 of 74 (10.8%) patients had septal perforations related to cocaine use, 7 of 74 (9.5%) patients had a septal infection or abscess, 5 of 74 (6.8%) patients had septal perforations related to nasal decongestant use, 2 of 74 (2.7%) patients had septal perforations secondary to rheumatologic conditions, 1 of 74 (1.4%) patient suffered a perforation due to cauterization of the nasal septum, 10 of 74 (13.5%) patients had an idiopathic cause of septal perforation and no etiology was reported for 7 of 74 (9.5%) patients. Certain patients were reported to have greater than one etiology for their nasal septal perforation.

The presence or absence of symptoms for patients included in this review were pooled and reported for 51 of 74 (68.9%) individual patients in the included studies. Of these, 37 of 51 (72.5%) patients experienced crusting, 33 of 51 (65%) patients experienced obstruction, 18 of 51 (35.3%) patients experienced bleeding or epistaxis, 17 of 51 (33.3%) patients experienced whistling, and 4 of 51 (8%) patients experienced malodor. Some patients included in this review presented with a combination of the aforementioned symptoms.

### Reconstruction Trends

All included studies used a PDS plate for their nasal septum perforation reconstruction. All studies reported using other materials in addition to the PDS plate for their repair. Four of seven studies also used a temporalis fascia graft, 2 of 7 studies used autologous cartilage grafts and 3 of 7 studies used a variety of other reconstruction materials, including acellular dermal matrices with tissue and mucoperichondrial rotation flaps (► **Table 2**). Twenty-two of 74 (29.7%) patients, in three of seven studies, underwent surgery involving both a PDS plate and local rotation flaps. One study reported the use of nasal septal flaps on five patients.<sup>11</sup> Another two studies involved a technique that used mucoperichondrial flaps over PDS plates on a total of 17 patients.<sup>5,10</sup>

### Patient Outcomes

The majority of patients were followed-up around the 4 to 6 months postoperatively. The maximum time for follow-up was 5 years and 8 months postoperatively.<sup>5</sup> All included studies reported septal perforation closure rates greater than 80% with the PDS plate repair. Three of seven studies reported 100% septal perforation closure rates.<sup>5,8,11</sup> Pooled analysis of the reconstruction trends across all included patients demonstrating closure rates of 91% (48/53) for temporalis fascia and PDS, 88% (14/16) for autologous cartilage grafts and PDS, 100% (6/6) for acellular dermal matrix

with tissue (via inferior turbinate flap or temporalis fascia) and PDS, and 86% (6/7) for mucoperichondrial rotation flaps with tissue (via temporalis fascia) and PDS. Four of seven studies reported that no patients had any complications following surgery.<sup>5,8-10</sup> Three of seven studies reported complications, including temporal scalp seroma, temporal pain, and local infection.<sup>6,7,11</sup>

### Discussion

All studies in this review reported septal perforation closure rates of at least 80%. The different materials used in conjunction with PDS plates in the included studies, all contributed to high rates of successful nasal septum perforation closure. The majority (four of seven) of studies did not report any complications following nasal septal repair with PDS plate.<sup>5,8-10</sup> In total, 67 of 74 (90.5%) patients in the included studies reported closure of their septal perforation. As an innovative technique for repairing nasal septal perforations, these results are promising. However, due to the sparse literature on the role of PDS plates in nasal septal perforation reconstruction, further research is needed to demonstrate its utility and to suggest its routine use.

In most reconstructive surgeries, the use of autologous tissue is preferred. However, due to factors, such as the limited amount of suitable, high-quality cartilage available at donor sites, synthetic materials are often used in septal reconstructive surgeries.<sup>15</sup> As has been shown, PDS plates appear to be a useful material for reconstructing nasal septal perforations. From a physiologic perspective, PDS plates aid septal perforation closure by acting as a scaffold to support other human tissue (cartilage, fascia, etc.) which encourages structural stability and remucosalization of the nasal septum.<sup>15</sup> Hence, PDS plates may act as an important cartilage replacement in the context of nasal septum perforations. They degrade spontaneously without impacting the surrounding tissue, and they serve to guide regenerating chondrocytes over the perforation to avoid the formation of deviated cartilage.<sup>16,17</sup> Furthermore, when cartilage and PDS plate are used simultaneously, the regenerated tissue has been shown to be stronger than had the perforation been repaired solely with cartilage.<sup>18</sup>

Notably, three studies included the use of temporoparietal fascia (TPF) grafting in addition to PDS plates for reconstruction of the nasal septum.<sup>6,8,10</sup> TPF grafts have demonstrated a high success rate for other reconstructive procedures.<sup>6,19</sup> The histological properties of the TPF are thought to contribute to the successful use of PDS plates as a scaffold/cartilage replacement to enhance cellular regeneration, migration, and mucosalization.<sup>6,20</sup>

Other techniques of nasal septal reconstruction have been shown to have significantly more complications than the use of PDS plates.<sup>2</sup> For example, while rotational and advancement flaps have been shown to be efficacious in nasal septal repair, the pooled data on PDS plates presented in this review report lower complication rates compared with similar studies pertaining to rotational or advancement flaps.<sup>21,22</sup> Further, using free flaps for nasal septal reconstruction have also been shown

**Table 1** Included studies' demographics

Study	Year published	Country published	Number of patients	Number of females n (%)	Number of males n (%)	Age of patients (y)	Number of centers	Number of surgeons	Type of injury	Patient symptoms
Morse et al <sup>6</sup>	2019	The United States	17	12 (70.59)	5 (29.41)	45	1	1	Unknown/idiopathic (35%), rheumatologic (12%), prior septoplasty (53%)	Nasal crusting, whistling, nasal obstruction, epistaxis
Epprecht et al <sup>7</sup>	2017	Switzerland	20	13 (65)	7 (35)	33	1	N/R	Previous operation (45%), posttraumatic (25%), cocaine (10%), infection (5%), idiopathic (15%)	Nasal crusting, obstruction, bleeding, whistling
Hughes and Paun <sup>5</sup>	2012	The United Kingdom	10	1 (10)	9 (90)	27–58	1	1	Cocaine (50%), postseptoplasty (30%), cauterization (10%), idiopathic (10%)	N/R
Sand et al <sup>10</sup>	2015	The United States	7	15 (60)	10 (40)	21–61	1	1	N/R	N/R
Mirzai et al <sup>11</sup>	2021	The United States	5	3 (60)	2 (40)	22–56	1	1	Previous septoplasty (80%), nasal decongestant use (60%), Nasal trauma (60%)	Nasal obstruction, whistling, epistaxis, crusting, malodor
Menger et al <sup>9</sup>	2008	The Netherlands	6	1 (16.67)	5 (83.33)	3–11	1	1	Septal abscess (100%)	Obstruction
Flavill and Gilmore <sup>8</sup>	2014	The United States	9	N/A	N/A	N/A	1	1	Trauma (33%), surgery (23%), cocaine (11%), oxymetazoline (22%), gunshot wound (11%)	Nasal crusting, discomfort, obstruction, epistaxis, whistling

Abbreviations: N/A, not available; N/R, not reported.

**Table 2** Included studies' reconstruction techniques and outcomes

Study	Year published	Perforation size range (mm)	Plate sizes used	Other materials for reconstruction	Follow-up time (mo)	Outcome (% of closures)	Outcome (no. of closures)	Complications
Mirzai et al <sup>11</sup>	2021	10 × 25–20 × 25	1-cm larger than nasal septal perforation	Inferior turbinate flap, acellular dermal matrix	6	100	5	None
Morse et al <sup>6</sup>	2019	2 × 2–14 × 30	0.15-mm thick	Temporoparietal fascia graft	8.7	88	15	Temporal pain (6%), scalp seroma (6%)
Epprecht et al <sup>7</sup>	2017	5 × 5–40 × 30	0.25-mm thick	Plate enveloped by temporoparietal fascia	12	90	18	Temporal pain (5%), infection (5%)
Sand et al <sup>10</sup>	2015	5 × 20–> 20	0.15, 0.25, and 0.55 mm	Temporalis fascia, mucoperichondrial rotation flaps	6.6	86	6	N/R
Flavill and Gilmore <sup>8</sup>	2014	8 × 10–20 × 25	0.25-mm thick	Deep temporal fascia, temporoparietal fascia, acellular dermal matrix	6–50	100	9	None
Hughes and Paun <sup>5</sup>	2012	7–16	0.15-, 0.25-, and 0.5-mm thick	Autologous cartilage interpositional grafts	10–68	80	8	Mild postoperative inflammation (10%)
Menger et al <sup>9</sup>	2008	15 × 23–25 × 36	0.15 mm × 50 mm × 40 mm plates	Autologous cartilage graft of auricle or rib	4–17	100	6	None

Abbreviation: N/R, not reported.

to have a higher failure rate than alternative techniques.<sup>2,23</sup> This reconstructive method can also cause morbidity at the donor site. One study reported a successful closure rate of 78% which is lower than all PDS studies included in this review.<sup>24</sup> Another study using interpositional auricular cartilage grafting via a mucosal regeneration technique to repair nasal septal perforations demonstrated symptom relief in 83.3% of patients, notably lower than the pooled results for our included studies.<sup>25</sup> Septal buttons have also been used to treat nasal septal perforations. However, they are only suitable for small perforations.<sup>3</sup> Patients who received treatment with buttons have reported that they do not fit well and can be painful.<sup>3</sup> Further, 50% of patients reported that they poorly tolerate septal buttons.<sup>4</sup> However, PDS products are not without their own risks. Despite the efficacy of PDS plates, mesh, and screws, PDS clips and staples have higher rates of migration from site of injury and related adverse reactions.<sup>13</sup> Furthermore, when PDS plates have sharp cutting edges, particularly at the nasal tip and anterior columella, they can become palpable or exposed.<sup>15</sup> Care should be taken to ensure PDS plates have rounded-off edges before being used in septal reconstruction.

### Limitations and Future Directions

There are several limitations associated with this review. First, the scant number of studies on the topic negates a meta-analysis or the ability to draw definitive conclusions on the usefulness of PDS plates for repairing nasal septum perforations. The included studies involved cohorts with a relatively small number of patients. Further, each study evaluated participants from a single site, and six studies reported that all operations were performed by a single surgeon, weakening the external validity of the results. Only one study contained patient-reported outcomes, which reduces the understanding of how patients perceive the benefit of reconstruction with PDS plates.<sup>6</sup>

Future research could incorporate larger cohorts of patients from various centers. Further, longitudinal studies that evaluate the long-term safety and outcomes for patients receiving nasal septal perforation reconstruction with PDS plates is warranted. Future studies could also investigate what types of perforations, in terms of characteristics, such as etiology or size, are most suitable to be reconstructed with PDS plates. Patient-reported outcomes should also be included in future studies.<sup>26</sup> Given that PDS plates and materials required for alternative procedures have varying associated costs, future studies could also include cost-benefit analyses or cost-utility analyses of using PDS plates compared with other strategies for individuals with nasal septum perforations.<sup>27</sup> PDS plates are reported to cost \$299 per sheet.<sup>12</sup> Finally, future research should also focus on innovations to improve PDS plates with the use of other biomaterials.

### Conclusion

This systematic review ultimately included seven studies representing 74 patients who received nasal septal perforation reconstruction with a PDS plate. All included studies



reported closure rates of at least 80%. The use of PDS plates is an innovative and promising approach to repairing septal perforations that has demonstrated positive outcomes. Future studies should continue to evaluate the long-term safety and outcomes of using PDS plates on larger cohorts of patients with nasal septum perforations.

#### Funding

None.

#### Conflict of Interest

None declared.

#### References

- Boynuegri S, Cayonu M, Tuna EU, et al. The effect of nasal septal perforation and its treatment on objective sleep and breathing parameters. *Med Sci Monit* 2016;22:501–507
- Kim SW, Rhee CS. Nasal septal perforation repair: predictive factors and systematic review of the literature. *Curr Opin Otolaryngol Head Neck Surg* 2012;20(01):58–65
- Mullace M, Gorini E, Sbrocca M, Artesi L, Mevio N. Management of nasal septal perforation using silicone nasal septal button. *Acta Otorhinolaryngol Ital* 2006;26(04):216–218
- Luff DA, Kam A, Bruce IA, Willatt DJ. Nasal septum buttons: symptom scores and satisfaction. *J Laryngol Otol* 2002;116(12):1001–1004
- Hughes J, Paun S. Repair of nasal septal perforations using conjugate polydioxanone plate and autologous cartilage interpositional grafts. *Otolaryngol Head Neck Surg* 2012;146(02):323–325
- Morse J, Harris J, Owen S, Sowder J, Stephan S. Outcomes of nasal septal perforation repair using combined temporoparietal fascia graft and polydioxanone plate construct. *JAMA Facial Plast Surg* 2019;21(04):319–326
- Epprecht L, Schlegel C, Holzmann D, Soyka M, Kaufmann T. Closure of nasal septal perforations with a polydioxanone plate and temporoparietal fascia in a closed approach. *Am J Rhinol Allergy* 2017;31(03):190–195
- Flavill E, Gilmore JE. Septal perforation repair without intraoperative mucosal closure. *Laryngoscope* 2014;124(05):1112–1117
- Menger DJ, Tabink IC, Trenité GJ. Nasal septal abscess in children: reconstruction with autologous cartilage grafts on polydioxanone plate. *Arch Otolaryngol Head Neck Surg* 2008;134(08):842–847
- Sand JP, Desai SC, Branham GH. Septal perforation repair using polydioxanone plates: a 10-year comparative study. *Plast Reconstr Surg* 2015;136(04):700–703
- Mirzai S, Lee AH, Chi JJ. Nasal septal perforation repair with an inferior turbinate flap and acellular dermal matrix. *Surg J (N Y)* 2021;7(01):e26–e29
- Rimmer J, Ferguson LM, Saleh HA. Versatile applications of the polydioxanone plate in rhinoplasty and septal surgery. *Arch Facial Plast Surg* 2012;14(05):323–330
- Martins JA, Lach AA, Morris HL, Carr AJ, Mouthuy PA. Polydioxanone implants: a systematic review on safety and performance in patients. *J Biomater Appl* 2020;34(07):902–916
- Page MJ, McKenzie JE, Bossuyt PM, et al. The PRISMA 2020 statement: an updated guideline for reporting systematic reviews. *BMJ* 2021;372:n71
- Oh GJ, Choi J, Kim TK, et al. Feasibility of a polydioxanone plate as an adjuvant material in rhinoplasty in Asians. *Arch Plast Surg* 2019;46(02):152–159
- Boenisch M, Tamás H, Nolst Trenité GJ. Influence of polydioxanone foil on growing septal cartilage after surgery in an animal model: new aspects of cartilage healing and regeneration (preliminary results). *Arch Facial Plast Surg* 2003;5(04):316–319
- Boenisch M, Mink A. Clinical and histological results of septoplasty with a resorbable implant. *Arch Otolaryngol Head Neck Surg* 2000;126(11):1373–1377
- Conderman C, Kinzinger M, Manuel C, Protsenko D, Wong BJ. Mechanical analysis of cartilage graft reinforced with PDS plate. *Laryngoscope* 2013;123(02):339–343
- Patel MR, Taylor RJ, Hackman TG, et al. Beyond the nasoseptal flap: outcomes and pearls with secondary flaps in endoscopic endonasal skull base reconstruction. *Laryngoscope* 2014;124(04):846–852
- Tellioglu AT, Tekdemir I, Erdemli EA, Tuccar E, Ulusoy G. Temporoparietal fascia: an anatomic and histologic reinvestigation with new potential clinical applications. *Plast Reconstr Surg* 2000;105(01):40–45
- Park JH, Kim Dw, Jin HR. Nasal septal perforation repair using intranasal rotation and advancement flaps. *Am J Rhinol Allergy* 2013;27(02):e42–e47
- Wang W, Vincent A, Shokri T, Hilger P, Ducic Y. Septal perforation repair using bilateral rotational flaps with interposed mastoid periosteal graft. *Laryngoscope* 2021;131(07):1497–1500
- Vuyk HD, Versluis RJJ. The inferior turbinate flap for closure of septal perforations. *Clin Otolaryngol Allied Sci* 1988;13(01):53–57
- Virkkula P, Mäkitie AA, Vento SI. Surgical outcome and complications of nasal septal perforation repair with temporal fascia and periosteal grafts. *Clin Med Insights Ear Nose Throat* 2015;8:7–11
- Ozturan O, Yenigun A, Senturk E, Eren SB, Aksoy F. Endoscopic endonasal repair of septal perforation with interpositional auricular cartilage grafting via a mucosal regeneration technique. *Otolaryngol Head Neck Surg* 2016;155(04):714–717
- Taylor CM, Bansberg SF, Marino MJ. Assessing patient symptoms due to nasal septal perforation: development and validation of the NOSE-Perf scale. *Otolaryngol Head Neck Surg* 2021;165(05):739–744
- Fuller JC, Levesque PA, Lindsay RW. Polydioxanone plates are safe and effective for L-strut support in functional septorhinoplasty. *Laryngoscope* 2017;127(12):2725–2730