



Type II Monteggia Lesion with Complete Elbow Dislocation in a Cat

Kevin Schreiber¹ Thomas Rousseau¹ Olivier Gauthier¹

¹Department of Small Animal Surgery, Oniris Nantes – Atlantic College of Veterinary Medicine, Food Science and Engineering, Nantes, France

Address for correspondence Kevin Schreiber, DVM, Department of Small Animal Surgery, Oniris Nantes – Atlantic College of Veterinary Medicine, Food Science and Engineering, 101, Route de Gachet, 44307 Nantes, France (e-mail: k.schreiber1@outlook.fr).

VCOT Open 2022;5:e30–e35.

Abstract

A 2-year-old neutered male cat was presented for right forelimb non-weight-bearing lameness. A fracture of the proximal third of the ulna (associated with a caudal radio-humeral and humero-ulnar dislocations and a radio-ulnar dislocation) was radiographically identified, leading to a diagnosis of type II Monteggia lesion with complete elbow joint dislocation. The ulnar fracture was reduced and stabilized using an intramedullary pin. During surgery, the lateral collateral ligament and the annular ligament appeared disrupted. The radio-ulnar dislocation was reduced and stabilized, using a double-loop suture prosthesis passing through the metaphysis of the ulna and around the radial head. The radio-humeral dislocation was reduced and stabilized using a lateral collateral suture prosthesis. No postoperative complications were observed and the patient regained good elbow joint range of motion, with no significant lameness at 8 postoperative months.

Keywords

- ▶ Monteggia fracture
- ▶ elbow joint dislocation
- ▶ cat
- ▶ prosthesis

Introduction

Radio-ulnar fractures are the fourth most common fractures in the cat, with a prevalence between 3 and 13.8%, after femoral, mandibular and pelvic fractures.^{1–3} They are mostly observed after a road accident or falling trauma in young male cats, aged under 2 years in more than 75% of cases.^{1,2} Fracture of the radius and ulna is generally observed in around 75% of cases, where the fracture site most frequently observed is the distal third of the ulnar diaphysis.²

A Monteggia lesion^{4–6} (also called Monteggia fracture)^{7–12} is a fracture of the proximal third of the ulnar diaphysis associated with luxation of the radial head.⁴ Four types of Monteggia fracture have been observed, but concurrent humero-ulnar and radio-ulnar luxation is a rare presentation that has not yet been reported in detail.¹³ The present case report describes the treatment of an atypical type II Monteggia fracture with total elbow joint luxation in an adult cat, and its long-term outcome.

Main Text

A 2-year-old neutered male European cat weighing 4 kg was presented for right forelimb non-weight-bearing lameness 6 days after a fall-from-a-height trauma. On admission, clinical examination revealed an absence of any signs of cardiovascular or respiratory distress confirmed by an abdominal Point-Of-Care Ultrasound and thoracic radiographs. Examination of the right forelimb after intravenous (IV) morphine hydrochloride (0.1 mg/kg) administration revealed bones cracking, abnormal motion of the elbow joint, swelling of the antebrachium and medial displacement of the olecranon. Neurological abnormality was not noted on clinical examination.

Radiographic examination revealed a fracture of the proximal third of the ulnar diaphysis, with a butterfly fragment. Radiographs also showed radio-ulnar, humero-ulnar and radio-humeral joints dislocations with caudo-medial luxation of the radial head (–Figs. 1A and 1B). According to both Bado and Jupiter classifications,^{4,5} this injury was a type II-C Monteggia

received
December 17, 2020
accepted after revision
November 7, 2021

DOI <https://doi.org/10.1055/s-0042-1742470>.
ISSN 2625-2325.

© 2022. The Author(s).
This is an open access article published by Thieme under the terms of the Creative Commons Attribution License, permitting unrestricted use, distribution, and reproduction so long as the original work is properly cited. (<https://creativecommons.org/licenses/by/4.0/>)
Georg Thieme Verlag KG, Rüdigerstraße 14, 70469 Stuttgart, Germany

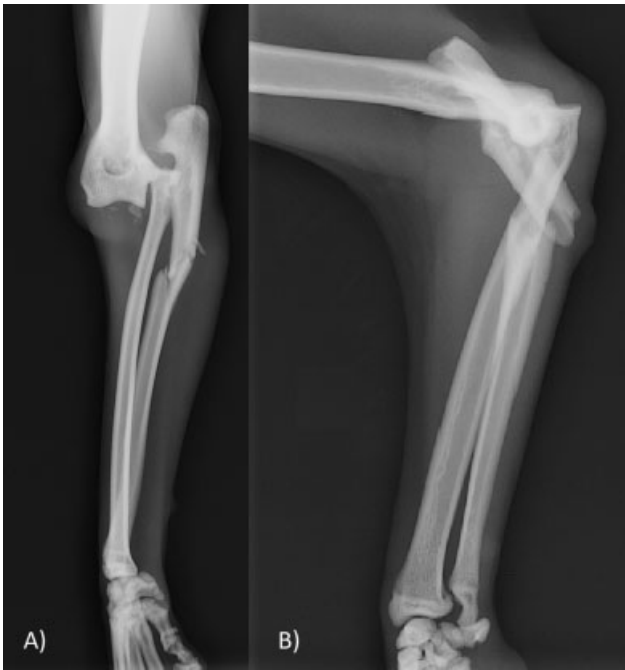

Fig. 1 (A) Craniocaudal and (B) lateral radiographs of the right antebrachium showed an ulnar diaphyseal fracture with a butterfly fragment and a complete elbow joint dislocation. Bone fragments are visible on the craniomedial edge of the elbow joint.

fracture, with concurrent humero-ulnar joint luxation. Cranio-medial bone fragments were also visible on the antero-posterior radiographic view.

Surgical stabilization of the fracture was decided upon, with the owner's consent. After premedication with medetomidine (10 µg/kg, IV), ketamine (1 mg/kg, IV) and morphine hydrochloride (0.1 mg/kg, IV), anaesthesia was induced with propofol and maintained with isoflurane in oxygen. Treatment with amoxicillin (20 mg/kg, IV) was initiated. Ringer lactate was administered IV at a rate of 5 mL/kg/hour during surgery. The cat was positioned in left lateral recumbency. The right forelimb was prepared for aseptic surgery.

The radius and ulna were exposed through a lateral surgical approach extending from the humeral lateral epicondyle to the proximal third of the ulnar diaphysis. Subcutaneous tissues and superficial antebrachial fascia were incised on the same line. After retraction of the skin margins, the fracture line of the ulna could be seen between the extensor digitorum communis muscle and the extensor digitorum lateralis muscle. The radial head could be seen through the deep antebrachial fascia on the cranial part of the incision, between the extensor carpi radialis muscle and the extensor digitorum communis muscle. Elbow joint was explored and flushed; no intra-articular bone fragment was observed. The elbow joint dislocation was manually reduced with the forelimb in flexion, combining external taxis and bone segments manipulation with bone holding forceps. A 1.2 mm Kirschner wire was placed retrograde into the medullary cavity of the proximal ulnar fragment. After ulnar fracture reduction, the Kirschner wire was inserted into the medullary cavity of the distal fragment.

The injured annular ligament and radial portion of the lateral collateral ligament were identified by dorsally

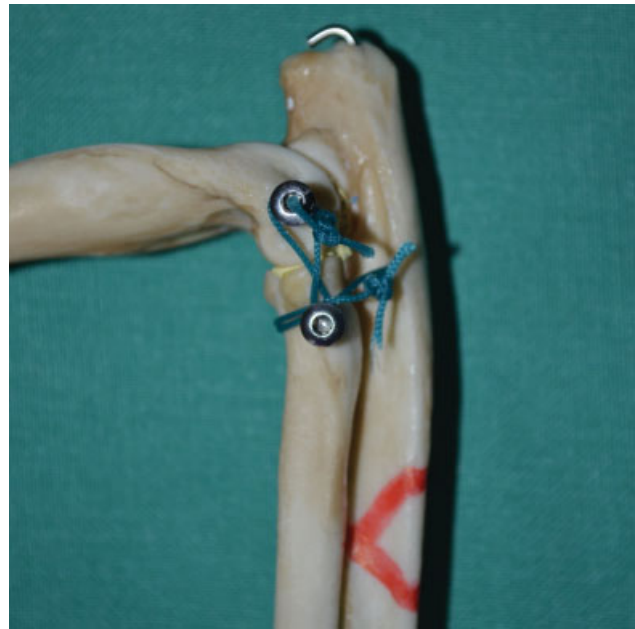


Fig. 2 Reconstitution of the construct composed of an intramedullary Kirschner wire in the ulna and two sutures prostheses mimicking the annular ligament and the radial part of the lateral collateral ligament respectively. A red mark represents the fracture line on the ulnar diaphysis.

retracting the anconeus muscle. Two 2 mm cortical screws with washers were positioned in the humeral lateral epicondyle and the lateral aspect of the radial head respectively. A single suture prosthesis was placed in a figure-of-eight around those screws using a 4 metric polyester (MERSUTURES, Ethicon, Issy-les-Moulineaux, France). A double-loop suture prosthesis was placed through a predrilled 1.5 mm hole in the proximal part of the ulnar metaphysis. The prosthesis (4 metric polyester) was placed around the radial head and under the extensor muscles, proximally to the radial screw (→ Fig. 2). The elbow joint was then mobilized in flexion, extension and internal and external rotations, exhibiting a good stability of the radial head and ulna in all these positions. The surgical site was generously flushed, and the surgical wound was closed routinely.

Postoperative radiographs showed good reduction of both the ulnar fracture and the elbow joint dislocation. Cranio-medial bone fragments coming from the primary trauma observed on preoperative radiographs, not visible perioperatively, were also observed on postoperative radiographs (→ Figs. 3A and B). Bone fragment of fracture avulsion of the annular ligament or the medial collateral ligament can be considered.

The cat was released with instruction for administration of amoxicillin with acid clavulanic and meloxicam. The cat's activity was restricted until the first postoperative recheck. Clinical and radiographic re-evaluations were performed at 4, 8, and 16 weeks postoperatively. The cat showed full weight-bearing on his operated forelimb without significant lameness at 4 weeks. Elbow joint range of motion was slightly reduced in extension (165 degrees) and flexion (20 degrees) compared with the contralateral elbow

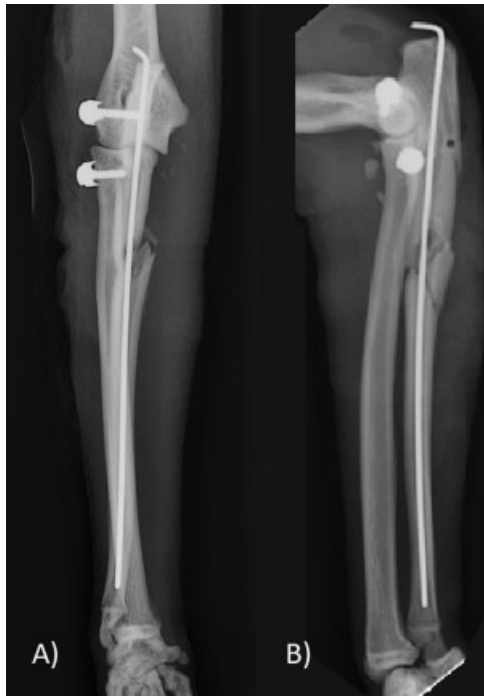

Fig. 3 Postoperative (A) craniocaudal and (B) lateral radiographs reveal a reduction in the ulnar fracture with a good bone alignment. Anatomic relationships between the radius, ulna and humerus have been restored. Bone fragments are still visible on the craniomedial edge of the elbow joint.

(175 degrees in extension and 10 degrees in flexion), without any associated pain. Normal range of motion of the elbow joint was observed in pronation and supination movements. Thanks to the owners' compliance, the cat presented at 8 postoperative months and 2 postoperative years without any significant elbow joint X-ray changes in comparison with the 16-week visit (►Figs. 4A and 4B). Perfect stability of the elbow joint was confirmed with Campbell's tests and flexion and extension movements. Only slight, non-persistent lameness was reported by the owners (a video was transmitted by the owners showing the gait described).

Discussion

Giovanni Batista Monteggia first described Monteggia lesion in 1814 as fractures of the proximal third of ulnar diaphysis and luxation of the radial head. These are very uncommon presentations for ulna fractures, and little information about their frequency has been reported in veterinary medicine. Out of 25 radio-ulnar fractures, a single case is cited in the study by Phillips, representing 3% of cases. In human medicine, Monteggia fractures represent 7% of radio-ulnar fractures—though only 0.7% when elbow joint dislocation is considered.⁷ In 1967, José Luis Bado presented four Monteggia lesion types, according to radial head displacement and ulnar fracture angulation (►Fig. 5).⁴ Type I is the most frequent presentation in both humans and animals, and is defined as a cranial radial head luxation and cranio-proximal angulation of the ulnar fracture. Type II is the least frequent presentation and combines a caudal radial head displacement with caudal ulnar fracture angula-

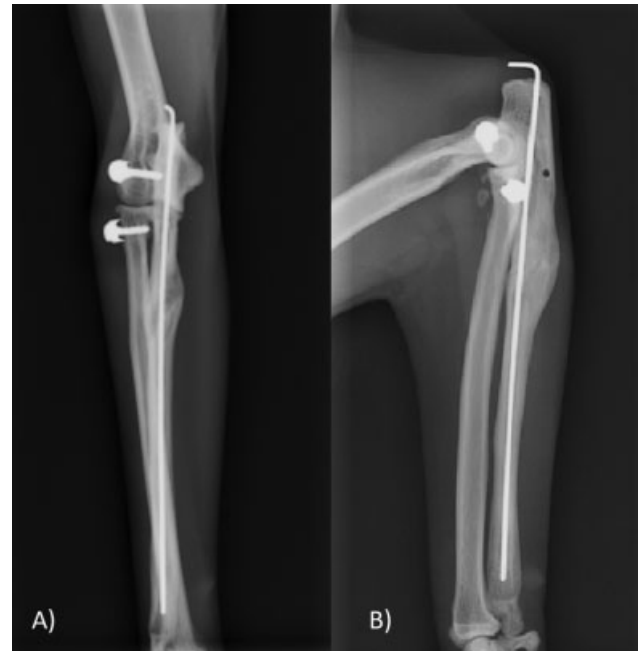

Fig. 4 Sixteen-week postoperative (A) craniocaudal and (B) lateral radiographs revealed a complete healing of the fracture with all the implants in place. No sign of osteoarthritis was noted.

tion. Type III corresponds to a lateral or cranio-lateral radial head luxation. Type IV combines fractures of the ulna and radius with cranial radial head luxation. For type II fractures, a classification into four groups (by the fracture line position relative to the medial coronoid process) has been described in human medicine.⁵ It has been shown that type II-A Monteggia fractures with fracture of the radial head or of the coronoid process are negative prognostic factors.⁸ Similar conclusions have not yet been established in veterinary medicine, though it is admitted that articular damage with complex presentation has a poorer prognosis.

These fracture presentations are rare in veterinary patients, usually resulting from motor vehicle trauma in dogs, and falling trauma in cats. In cats, few case reports of type IV fractures^{9,10} and two cases series of Monteggia fractures^{6,7} have been described. Type II Monteggia fracture is the most infrequent presentation,^{6,7} with associated complete elbow joint dislocation a very unusual condition. A type II Monteggia fracture with humero-ulnar joint luxation has been described but with another type of ulnar stabilization construct (plate-screw construct) and no radio-ulnar dislocation.¹⁴

In the present case, the ulnar fracture resulted from a falling trauma and showed a caudal angulation and caudo-medial radial head luxation. According to Bado classification, then, the present fracture was a type II Monteggia fracture. Moreover, the elbow joint was completely dislocated with a medial ulnar and radial luxation. Annular ligament and collateral ligament disruptions were surgically confirmed. The humero-ulnar joint luxation associated with the radio-ulnar dislocation could be explained with two anatomic differences in the cat. First, the annular ligament has an attachment to the lateral humeral condyle together with the

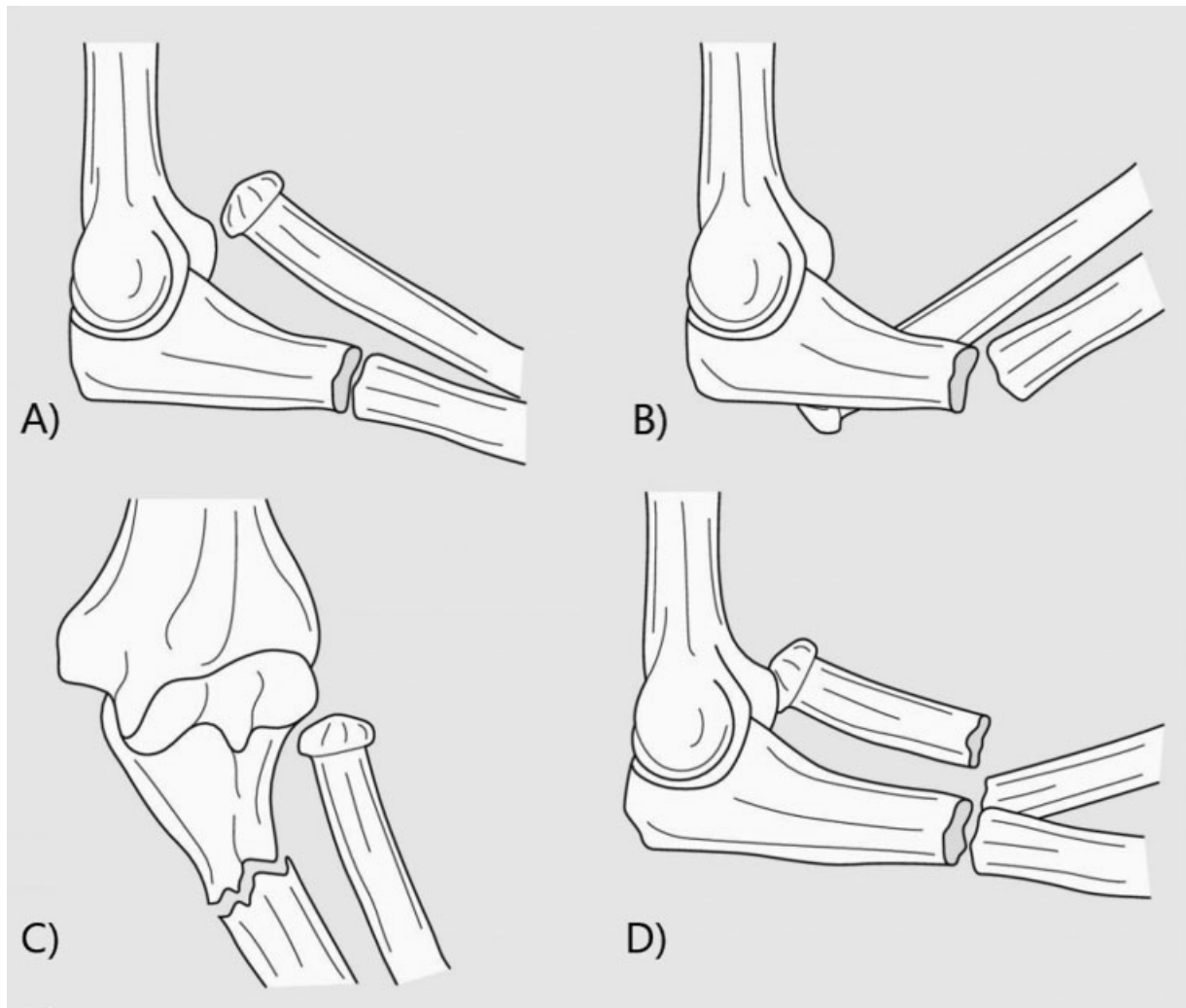


Fig. 5 Representation of the Bado classification of the Monteggia fractures. (A) Type I, (B) type II, (C) type III, and (D) type IV.

lateral collateral ligament, which may result in simultaneous damage. Second, cats lack the strong interosseus ligament between the radius and ulna.¹³

Most of the implants used to reduce and stabilize Monteggia fractures are plate-screw constructs, to counteract compression and rotation forces.^{7,9,10} Plate-screw construct is very interesting alone to stabilize ulnar diaphysis fracture including comminuted fracture.¹⁰ Intramedullary Kirschner wire could be used alone under certain conditions such as intact annular and collateral ligaments, integrity of the radius and articular congruence of the elbow.^{11,15}

In the present case, an intramedullary Kirschner wire alone was used to reduce and stabilize the ulnar fracture, in combination with the placement of annular and lateral collateral ligament prostheses, thanks to the integrity of the radius. Moreover, the Kirschner wire implant was well-suited to the bone size. Such a construct provided excellent ulnar alignment and good bone congruence, without any complications. Plating of the ulnar diaphysis could also be an option.^{10,14} Plate-screw construct offers better stabilization against compression and rotation strains, but in this case intramedullary Kirschner wire is sufficient to

counteract mainly bending and shearing strains applied on the ulnar diaphysis. Moreover, intramedullary positioning of the Kirschner wire provides an excellent alignment of the neutral axis of the bone.

The annular ligament encircles the radial head and allows pronation and supination movements of the antebrachium during weight-bearing. It is attached to the lateral and medial extremities of the radial incisure of the ulna and to the humeral epicondyle on the lateral side. Currently reported surgical methods of reducing radial head luxation in dogs and cats include repair of the torn annular ligament, transfixation to the ulna using a pin or screw and substitution of the annular ligament. When primary repair of the annular ligament has been attempted, approximately one-third of joints re-luxated.^{6,16,17} For this reason, supplementing the annular ligament repair by transfixation of the radius to the ulna using cortical screws is recommended. Removal of radio-ulnar implants has been recommended at approximately 4 weeks, to avoid complications and to maintain pronation and supination movements of the antebrachium.^{11,15,17} Alternatively, a synthetic radio-ulnar Tight-Rope prosthesis has been proposed, to favour pronation and supination movements during weight-bearing.¹²

In the present case, the annular ligament was disrupted, with a complete radio-ulnar dislocation. The prosthesis was passed around the radial head and through an ulnar bone tunnel proximal to a more distal radial screw (limit sliding of the prostheses), mimicking the annular ligament position. A good postoperative outcome with stability of the elbow joint in flexion, extension and Campbell's tests movements and no pain was noted. An excellent elbow joint congruency, no radio-ulnar synostosis and no osteoarthritis were observed radiographically.

Traumatic elbow joint dislocation is a rare condition in dogs and cats because of intrinsic bone congruency and contribution of collateral ligaments.¹⁸ Lateral luxation of the radial head and olecranon is more common than medial, occurring in more than 90% of elbow joint dislocation cases^{19–22} due to the anatomical conformation of the distal medial humerus, which presents a large medial epicondyle and a sloped medial condylar ridge.^{18,23} Several open reduction techniques have been described for the treatment of elbow joint dislocation—such as primary suture of the torn ligament using a locking loop suture, or ligament prosthesis secured by screws and washers, or placed through bone tunnels.^{19,22,24} Good results have been obtained using prostheses that replace both the radial and the ulnar parts of the collateral ligament through transcondylar, transradial, and transulnar bone tunnels in cats.²³ After reduction, immobilization of the elbow joint is preconised. After open reduction, immobilization is maintained for 3 weeks before beginning physical therapy.²⁴

In the present case, only a lateral prosthesis was performed, because the conformation of the medial humeral epicondyle limits medial movement of the radial head together with the presence of the annular prosthesis, and medial elbow joint stability was good in Campbell's test. The lateral collateral ligament appeared disrupted, and was reconstructed using a figure-of-eight suture around screw and washer implants placed at the origin and at the distal insertion of the lateral collateral ligament. Moreover, the surgical approach was then limited to a caudo-lateral approach, minimizing iatrogenic damage. Elbow joint stability as assessed by Campbell's test was good immediately after surgery and throughout follow-up. No sign of osteoarthritis was observed radiographically at 8 months postoperatively.

Osteoarthritis, diminution of the range of motion of the elbow joint and radial head re-luxation are the most common postoperative complications associated with Monteggia fracture treatment.^{6,7,11} Implant failure also is a major complication, particularly with monofilament suture ligament prostheses. Braided suture prosthesis (such as MER-SUTURE or Arthrex TightRope) is more resistant to rupture²⁵ but aseptic technique should be strictly adhered to prevent infection.¹²

In the present case, both ligamentoplasty and fracture fixation were efficient in stabilizing the elbow joint dislocation, with neither further luxation nor the development of osteoarthritis in the course of the 8-month postoperative period. Only a slight diminution (10–20 degrees) of the elbow joint range of motion, in rotation and extension

positions, was noted without any pain. Only slight intermittent lameness was reported, with no worsening effects along the postoperative period.

Conclusion

The association of a type II Monteggia fracture with complete elbow joint dislocation (humero-ulnar and radio-ulnar) was treated using an innovative stabilization method of annular ligamentoplasty with an ulnar bone tunnel and locking with a radial screw, which restored long-term elbow joint function. The main advantage of the present treatment was that it reduced both the size and number of implants, limiting implant-related complications (in particular, radio-ulnar screw loosening).

Animal Care

Client consent obtained.

Funding

None declared.

Conflict of Interest

None declared.

References

- Hill FWG. A survey of bone fractures in the cat. *J Small Anim Pract* 1977;18(07):457–463
- Phillips IR. A survey of bone fractures in the dog and cat. *J Small Anim Pract* 1979;20(11):661–674
- Nolte DM, Fusco JV, Peterson ME. Incidence of and predisposing factors for nonunion of fractures involving the appendicular skeleton in cats: 18 cases (1998–2002). *J Am Vet Med Assoc* 2005;226(01):77–82
- Bado JL. The Monteggia lesion. *Clin Orthop Relat Res* 1967;50(50):71–86
- Jupiter JB, Leibovic SJ, Ribbans W, Wilk RM. The posterior Monteggia lesion. *J Orthop Trauma* 1991;5(04):395–402
- Schwarz PD, Schrader SC. Ulnar fracture and dislocation of the proximal radial epiphysis (Monteggia lesion) in the dog and cat: a review of 28 cases. *J Am Vet Med Assoc* 1984;185(02):190–194
- Blieux V. Des fractures de Monteggia chez le chien et le chat: études anatomique, clinique et rétrospective de 59 cas de fractures de l'ulna avec luxation de la tête radiale [Monteggia fractures in dogs and cats: Anatomical, clinical and retrospective study of 59 cases of ulnar fractures with radial head dislocation]. 2005. Available at: <http://hdl.handle.net/10068/765467>
- Konrad GG, Kundel K, Kreuz PC, Oberst M, Sudkamp NP. Monteggia fractures in adults: long-term results and prognostic factors. *J Bone Joint Surg Br* 2007;89(03):354–360
- Bush M, Owen M. Type-IV variant Monteggia fracture with concurrent proximal radial physeal fracture in a Domestic Short-haired Cat. *Vet Comp Orthop Traumatol* 2009;22(03):225–228
- Irbetagoyna I, Lopez T, Autefage A. Type IV Monteggia fracture in a cat. *Vet Comp Orthop Traumatol* 2011;24(06):483–486
- Fox D. Radius and ulna. In: Johnston SA, Tobias KM, eds. *Veterinary Surgery Small Animal*. 2nd edition. Saint Louis: Elsevier GmbH.; 2018:918–919
- Vallone L, Schulz K. Repair of Monteggia fractures using an Arthrex Tightrope system and ulnar plating. *Vet Surg* 2011;40(06):734–737

- 13 Voss K, Langley-Hobbs S, Montavon P. Elbow joint. In: Montavon P, Voss K, Langley-Hobbs S, eds. *Feline Orthopaedic Surgery and Musculoskeletal Disease*. 1st ed. Philadelphia: Elsevier; 2009:354–356
- 14 Fernandez-Sanchez A, Calvo I, Farrell M. Articular type II Monteggia fracture with concurrent humeroulnar luxation in a Bengal cat. *Vet Rec Case Rep* 2019;7(01):7–10
- 15 DeCamp CE, Johnston SA, Déjardin LM, Schaefer SL. Type A1, ulnar fracture. In: Brinker WO, Piermattei D, Flo G, eds. *Small Animal Orthopedics and Fracture Repair*. 5th edition Saint Louis: Elsevier GmbH; 2016:372–378
- 16 Autefage A. Fracture of the ulna. In: Johnson A, Houlton J, Vannini R, eds. *AO Principles of Fracture Management in the Dog and Cat*. New York: Thieme; 2005:260–272
- 17 Boudrieau R. Fractures of the radius and ulna. In: Slatter D, ed. *Textbook of Small Animal Surgery*. 3rd edition Philadelphia: W.B. Saunders; 2003:1955–1973
- 18 Campbell JR. Luxation and ligamentous injuries of the elbow of the dog. *Vet Clin North Am* 1971;1(03):429–440
- 19 Mitchell KE. Traumatic elbow luxation in 14 dogs and 11 cats. *Aust Vet J* 2011;89(06):213–216
- 20 Billings L, Vasseur P, Todoroff R, Johnson W. Clinical results after reduction of traumatic elbow luxations in nine dogs and one cat. *J Am Anim Hosp Assoc* 1992;28:137–142
- 21 O'Brien MG, Boudrieau RJ, Clark GN. Traumatic luxation of the cubital joint (elbow) in dogs: 44 cases (1978–1988). *J Am Vet Med Assoc* 1992;201(11):1760–1765
- 22 Williams H, Calvo I, Gaines A, et al. Multi-centre retrospective study of the long-term outcome following suspected traumatic elbow luxation in 32 cats. *J Small Anim Pract* 2020;61(06):354–362
- 23 Farrell M, Thomson DG, Carmichael S. Surgical management of traumatic elbow luxation in two cats using circumferential suture prostheses. *Vet Comp Orthop Traumatol* 2009;22(01):66–69
- 24 Bordelon JT, Reaugh HF, RoCHAT MC. Traumatic luxations of the appendicular skeleton. *Vet Clin North Am Small Anim Pract* 2005;35(05):1169–1194
- 25 Schmiedt CW. Suture material, tissue staplers, ligation devices, and closure methods. In: Johnston SA, Tobias KM, eds. *Veterinary Surgery Small Animal*. 2nd ed Saint Louis: Elsevier GmbH; 2018:214–218