




# Fixation of Intertrochanteric Fractures with Dynamic Hip Screws: Randomized Controlled Trial Comparing Hardinge and Minimally Invasive Approaches\*

## *Fraturas intertrocantéricas fixadas com parafuso dinâmico de quadril: Ensaio clínico randomizado comparando a via lateral de Hardinge e o acesso minimamente invasivo*

Eduardo Lima de Abreu<sup>1</sup>  Jonas Byk<sup>2</sup> Fernando Westphal<sup>2</sup>

<sup>1</sup>Escola Superior de Ciências da Saúde, Universidade do Estado do Amazonas (UEA), Boca do Acre, AM, Brazil

<sup>2</sup>Programa de Pós-Graduação em Cirurgia, Universidade Federal do Amazonas (PPGRACI-UFAM), Manaus, AM, Brazil

Address for correspondence Eduardo Abreu, MSc, Escola Superior de Ciências da Saúde, Universidade do Estado do Amazonas, Avenida Carvalho Leal, 1.777, Cachoeirinha, Manaus, Amazonas, 69065001, Brazil (e-mail: ed\_manauas@yahoo.com.br).

Rev Bras Ortop 2022;57(1):150–158.

### Abstract

#### Keywords

- ▶ intertrochanteric fracture
- ▶ minimally-invasive surgical procedures
- ▶ osteosynthesis
- ▶ pain, postoperative
- ▶ clinical trial

**Objective** To compare the techniques for the osteosynthesis of intertrochanteric fractures with dynamic hip screws (DHSs) through the Hardinge and minimally-invasive access routes of the hip, evaluating the operative time, the degree of pain in the immediate postoperative period, the hematimetric loss, and the functional aspects of active mobility.

**Methods** A randomized, double-blinded clinical trial in which 66 patients with intertrochanteric fractures were submitted to osteosynthesis by DHS. The patients were divided into a test group, submitted to the minimally-invasive access, and a control group, in whom the surgery was performed through the Hardinge route.

**Results** Patients submitted to the minimally-invasive treatment presented a lower degree of postoperative pain compared to the group treated by the Hardinge lateral route ( $p < 0.001$ ), as well as lower hematimetric loss ( $p < 0.001$ ), shorter operative time ( $p < 0.001$ ), and improvement in immediate postoperative active mobility tests ( $p < 0.05$ ).

\* Work developed at Universidade do Estado do Amazonas (UEA), Boca do Acre, AM, Brazil.

received  
May 7, 2020  
accepted  
October 14, 2021

DOI <https://doi.org/10.1055/s-0042-1742348>.  
ISSN 0102-3616.

© 2022. Sociedade Brasileira de Ortopedia e Traumatologia. All rights reserved.

This is an open access article published by Thieme under the terms of the Creative Commons Attribution-NonDerivative-NonCommercial-License, permitting copying and reproduction so long as the original work is given appropriate credit. Contents may not be used for commercial purposes, or adapted, remixed, transformed or built upon. (<https://creativecommons.org/licenses/by-nc-nd/4.0/>)

Thieme Revinter Publicações Ltda., Rua do Matoso 170, Rio de Janeiro, RJ, CEP 20270-135, Brazil

**Conclusion** The study demonstrated the clinical superiority of the minimally-invasive access route parameters analyzed in relation to the Hardinge access for the fixation of intertrochanteric fractures when DHS is the choice osteosynthesis method.  
Level of evidence I.

## Resumo

**Objetivo** Comparar as técnicas de osteossíntese de fraturas intertrocantéricas com o parafuso dinâmico de quadril (*dynamic hip screw*, DHS, em inglês) pelas vias de acesso de Hardinge e minimamente invasiva do quadril, avaliando o tempo cirúrgico, o grau de dor no pós-operatório imediato, a perda hematimétrica, e os aspectos funcionais de mobilidade ativa.

**Métodos** Estudo clínico randomizado e duplo-cego, em que 66 pacientes com fratura intertrocantérica foram submetidos a osteossíntese com DHS. Os pacientes foram divididos em um grupo teste, submetidos ao acesso minimamente invasivo, e um controle, em que a cirurgia foi realizada pela via de Hardinge.

**Resultados** Os pacientes submetidos ao tratamento pela via minimamente invasiva apresentaram um grau de dor pós-operatória inferior em comparação ao grupo tratado pela via lateral de Hardinge ( $p < 0,001$ ), assim como menor perda hematimétrica ( $p < 0,001$ ), menor tempo operatório ( $p < 0,001$ ), e melhora nos testes de mobilidade ativa pós-operatória imediata ( $p < 0,05$ ).

**Conclusão** O estudo demonstrou a superioridade clínica nos parâmetros analisados da via de acesso minimamente invasiva em relação ao acesso de Hardinge para a fixação de fraturas intertrocantéricas, quando o DHS for a opção de osteossíntese escolhida.  
Nível de evidência I.

## Palavras-chave

- ▶ fratura intertrocantérica
- ▶ procedimentos cirúrgicos minimamente invasivos
- ▶ osteossíntese
- ▶ dor pós-operatória
- ▶ ensaio clínico

## Introduction

Ideally, intertrochanteric fracture is a surgical nosological entity, common in elderly patients, and its prevalence is increasing thanks to the worldwide increase in life expectancy of the population. The important loss of bone mass density proper to this population favors the occurrence of these fractures caused by low-impact traumas, such as falls from their own height.<sup>1</sup>

Throughout history, several implants have been developed for the fixation of intertrochanteric fractures, which are divided into two groups: intramedullary fixation and extramedullary stabilization, among which the dynamic hip screw (DHS) stands out. Currently, the fixation of these fractures with cephalomedullary nails, despite having a higher cost, has been the choice of most authors due to their low aggressiveness to soft tissues, since minimally-invasive access routes are used for their installation, and mainly because they provide better stability.<sup>2</sup> The DHS, however, remains an excellent option for the fixation of intertrochanteric fractures.<sup>3-5</sup>

When the implant chosen is the DHS, the classic access route is that described in 1982 by Hardinge,<sup>6</sup> which consists of an approach 15 to 20 cm on the lateral face of the thigh, with a longitudinal section of the fascia lata and dissection of the posterior third of the lateral vastus. In 2011,<sup>7</sup> however, a minimally-invasive access route was proposed to make the intertrochanteric fracture fixation procedure less aggressive.

The main benefit of the minimally-invasive technique in relation to the traditional surgery is the reduction in opera-

tive time and the lower rate of bleeding, but there is no consensus on the superiority of the technique in terms of the postoperative recovery of the patients.<sup>8-10</sup>

The main objective of the present study is to analyze intertrochanteric fractures fixed with the DHS system by comparing minimally-invasive plate osteosynthesis (MIPO) and the traditional Hardinge access route regarding the postoperative pain index. The secondary goal is to assess whether there is a superiority of the former approach in terms of operative time, blood loss indexes, and the degree of active mobility in the immediate postoperative period (IPOP).

## Methods

The present is a double-blinded randomized clinical trial – registered in the Brazilian Registry of Clinical Trials under protocol 238492489–with elderly patients who suffered low-energy trauma in the hip, with intertrochanteric fracture, without other associated injuries, and who were submitted to fixation with the DHS between March and December 2018.

We included Brazilian patients aged  $\geq 60$  years, of both genders, with intertrochanteric fractures under clinical conditions appropriate to the proposed surgical treatment, who authorized their participation by signing the Free and Informed Consent Form. The exclusion criteria were: patients who declared themselves indigenous, patients with intertrochanteric fractures with reverse trait obliqueness, whose treatment with DHS is not recommended, patients with

pathological intertrochanteric fractures due to malignant or benign tumors, cases in which the anesthesia team refused to perform the intraoperative analgesia protocol chosen for the study, patients who required transfusion or immediate postoperative blood transfusion, those considered with low cognitive level to understand the questions of the research, and patients who died in the IPOP.

The sample size was estimated in terms of the proportion of elderly people affected by intertrochanteric fractures found in a study conducted by Martini et al.,<sup>11</sup> which was of 22.7%, and the approximate annual total of these surgeries performed in patients with this disease in the service where the study was developed, which is of 80 surgeries. A 95% confidence interval and an accuracy of 4.95% (margin of error) were established, with a minimum sample size of 62 elderly individuals.

The sample was initially composed of 70 patients, 66 of whom were randomly distributed into 2 groups: 33 in group I, composed of patients submitted to surgery by the classic Hardinge route, and 33 in group II, composed of patients submitted to surgery by MIPO. A total of 4 patients were excluded from the study: 2 from group I (no. 14, who died in the IPOP, and no. 28, who required intraoperative blood transfusion) and 2 from group II (no. 17 and no. 25, both with low cognitive capacity in the first postoperative day, which hindered the accurate assessment of the degree of pain and the evaluation of the mobility tests) (► **Table 1**, supplementary material, available online only).

The study was submitted to the institutional Ethics in Research Committee and received the Certificate of Presentation for Ethical Appreciation (CAAE: 68335517.1.0000.0007), and it followed the Consolidated Standard of Reporting Trials (CONSORT) from the selection of patients to its final analysis, as shown in ► **Figure 1**.

The groups were randomized using the electronic tool found in the [randomization.com](http://randomization.com) website.

A questionnaire was developed with the variables researched in this study, composed of the degree of pain before and after surgery (using the Wong–Baker Faces Pain Rating Scale), the degree of active mobility in the IPOP, with a request for active elevation of the operated limb and an assessment of the patient's ability to sit in bed with assistance. The protocol also presented the variables to comparatively quantify the hematimetric loss in routine preoperative collections and on the first postoperative day (hemoglobin and hematocrit). We also measured the time required, in each of the methods, for the implantation of the DHS system and for the suture of the surgical wound (► **Figure 2**).

Upon admission, patients were asked to assess pain on the Wong–Baker scale by an independent examiner (the same examiner chosen to perform the postoperative evaluation), always at eight o'clock in the morning of the first day of hospitalization. This evaluation was made with the examiner showing the Wong–Baker scale to the patient, which has scores 0 zero to 10 points. The preoperative prescription of analgesia was standard, with dipyrone, at a systematic dose of 1 g every 6 hours, and 100 mg of tramadol hydrochloride as rescue.

All patients evaluated were operated on by the same surgeon, and the anesthesiology team followed the same anesthesia protocol, with spinal anesthetic block with 0.5% of hyperbaric bupivacaine hydrochloride, at an approximate dose of 10 mg, associated with 100 mg tramadol hydrochloride, administered intravenously, diluted in serum during the perioperative period. The operative time was measured in two moments: the first one began with the access route and finished with the end of the osteosynthesis, and in the second one, synthesis of the surgical wound was performed.

The surgical dressing was the same for the patients in both groups, with 20 × 5-cm roller gauze with 16 layers fixed with 25 × 10-cm adhesive band, covering the entire length of the access routes, in order to blind the examiner and the patient. This dressing was changed on the first postoperative day, after the patient's anamnesis, using the research protocol.

The prescription of postoperative analgesia was maintained, with 100 mg of tramadol hydrochloride injected subcutaneously as rescue, and with 1g of systemic intravenous dipirone every 6 hours. On the first postoperative day, the patients were reassessed with the Wong–Baker scale, and asked about the request for opioids. After the new pain assessment, the patients were submitted to two evaluations to determine the degree of active hip mobility. Initially, they had help to sit on the bed and remain in this position for up to 10 seconds and were subsequently instructed to raise the operated limb, with an extended knee, to an angle of approximately 45°.

A new blood collection was performed on the first postoperative day to evaluate the hematimetric alteration and compared with the preoperative collection.

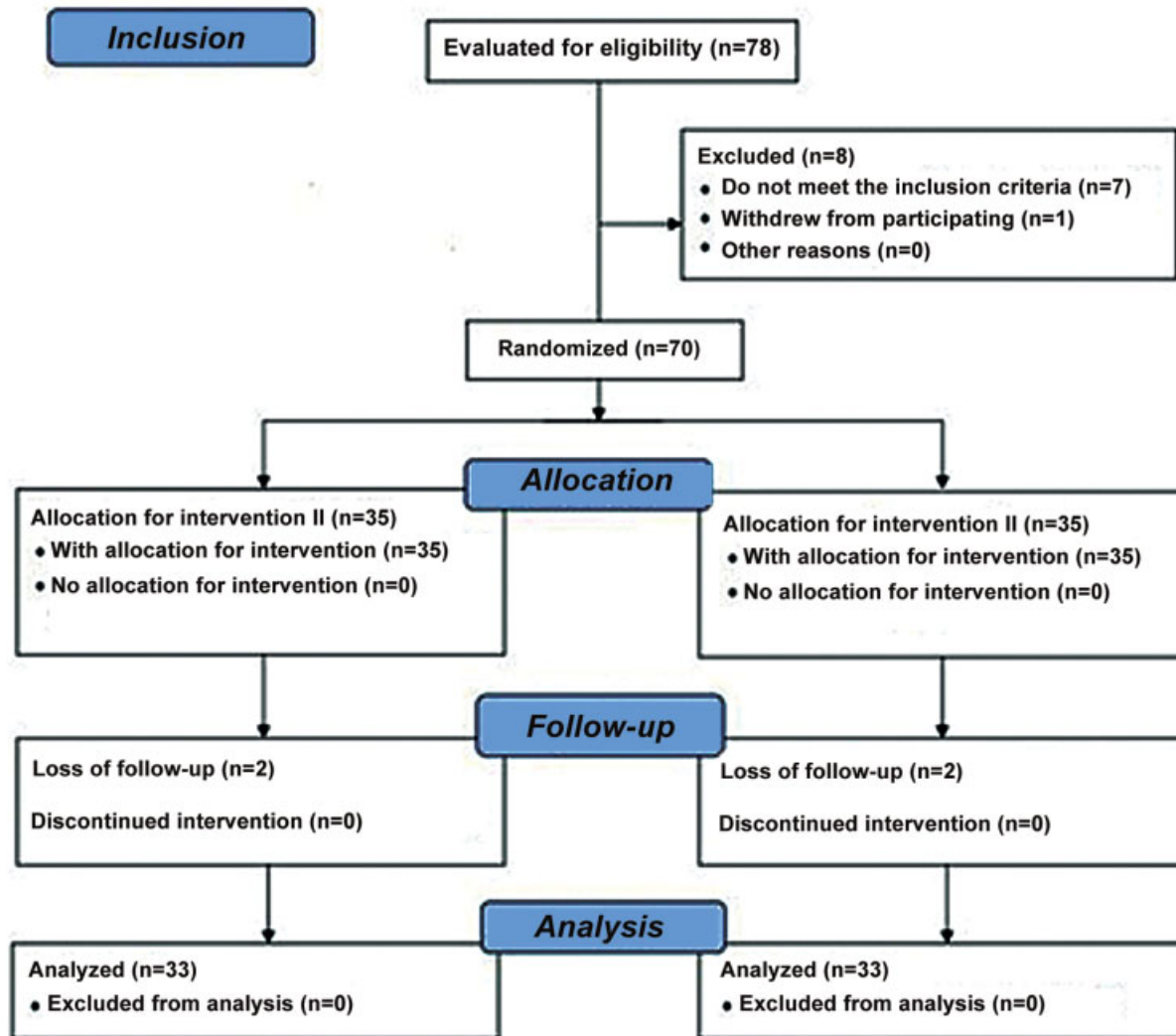
The primary outcome of the present study was the evaluation of the degree of postoperative pain according to the Wong–Baker scale, and the secondary outcome was the evaluation of the degree of postoperative hip mobility.

**Table 1** Analysis of the degree of pre- and postoperative pain in patients using the Wong–Baker Visual Scale

Group	N	Preoperative pain		Postoperative pain		p*
		Average	Standard deviation	Average	Standard deviation	
Hardinge	33	5.15	2.15	7.03	1.90	0.001
MIPO	33	6.30	1.38	3.33	2.31	< 0.0001

Abbreviation: MIPO, minimally-invasive plate osteosynthesis.

Notes: \*Values of  $p < 0.05$  (5%) were considered statistically significant. Student t-test.



**Fig. 1** Flowchart of the stages of the clinical trial with elderly patients with intertrochanteric fractures submitted to DHS fixation. Intervention I: fixation by the Hardinge access; intervention II: by the minimally-invasive route.

## Results

Out of the 33 elderly individuals in group I, 15 (45.5%) were male and 18 (54.5%) female. In Group II, 19 (57.6%) were male and 14 (42.4%), female. The mean age of group I was of  $80.42 \pm 8.26$  years, and that of group II was of  $78.58 \pm 8.78$  years, with approximate statistical variation between the groups ( $p = 0.191$ ). The distribution of fractures according to the Tronzo classification is shown in ► **Figure 3**.

Regarding the pain assessment, group I presented a significant increase in the mean degree of pain, when compared to the pre- and postoperative evaluations (from  $5.15 \pm 2.15$  to  $7.03 \pm 1.90$ ). As for group II, the mean degree of pain in the preoperative period was of  $6.30 \pm 1.38$ , and, in the postoperative period, it was of  $3.33 \pm 2.31$ , which shows a significant reduction ( $p < 0.0001$ ) (► **Table 2**, supplementary material, available online only). When the postoperative degrees of pain were compared between the groups, the score of group II was significantly lower than that of group I ( $p < 0.0001$ ), as shown in ► **Table 1**.

When comparing the mean preoperative levels of hemoglobin and hematocrit of the patients, no statistically signifi-

cant difference was found between groups I and II ( $p = 0.643$  and  $p = 0.536$  respectively). In the postoperative period, the hematimetric loss was significantly lower in group II (► **Table 2**) ( $p < 0.001$ ).

The operative time was measured in two stages: the time for the performance of the osteosynthesis, calculated from the beginning of the access route to the placement of the last plate screw, and the time required for the closure of the surgical wound. The time required to perform the MIPO was significantly shorter in both stages ( $p > 0.001$ ), as shown in ► **Table 2**.

After the evaluation of the postoperative pain, the operated hips were submitted to two mobility tests. In the first one, the patient was asked to sit in bed and remain in this position for 10 seconds. In the second test, the patient was asked to flex the operated hip with the knee in extension. Group II had a better performance in both tests ( $p = 0.031$  and  $p = 0.001$  respectively), as shown in ► **Figure 4**.

As for the position of the tip of the sliding screw in relation to the quadrants of the femoral head, which were proposed by the Cleveland Femoral Head Division, in 12 cases, the screw was in quadrant 4: 6 (50.0%) in group I, and 6 (50.0%) in group

### Research Protocol

**Comparative study between Hardinge's lateral pathway and minimally invasive access for the treatment of intertrochanteric fractures with the Dynamic Hip Screw system.**



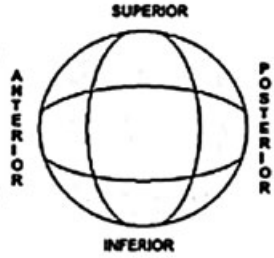
M.I.P.O. Group	Hardinge Group		
Name: _____ Age: _____ Gender: <input type="radio"/> Mas <input type="radio"/> Fem Tronzo: <input type="radio"/> I <input type="radio"/> II <input type="radio"/> III/IV <input type="radio"/> IV Phones: _____	Pre-op hematimetry: Hb: _____ HTC: _____ Post-op hematimetry: Hb: _____ HTC: _____		
<b>Wong &amp; Baker Preoperative Scale</b> 			
<b>Wong &amp; Baker Preoperative Scale</b> 			
<b>Sat on the bed</b> <input type="radio"/> Able <input type="radio"/> Unable	<b>Opioid requests (1° PO)</b> <input type="radio"/> Yes _____ DOSES <input type="radio"/> No	<b>Hip flexion</b> <input type="radio"/> Able <input type="radio"/> Unable	
Osteosynthesis time _____ Suture time _____			

Fig. 2 Form for data collection of the research protocol.

II; in 37 cases it was in quadrant 5, 20 (54.1%) in group I, and 17 (45.9%) in group II; in 12 cases, it was in quadrant 6, 6 (50.0%) in group I, and 6 (50.0%) in group II; in 1 case in group II, it was in quadrant 7; and in 4 cases, it was in quadrant 8, 1 (25.0%) in group I, and 3 (75.0%) in Group II, as shown in ► **Figure 5**.

### Discussion

The MIPO procedure in intertrochanteric fractures was superior when compared to the treatment by the traditional

Hardinge route. In procedures in which the access route was lower, the degree of postoperative pain and the rate of blood loss were lower, and active mobilization on the first day of surgery was better.

Hip fractures comprise an extremely broad spectrum, and knowledge of their approach is essential not only for the orthopedist or hip surgeon but also for physicians in general. Intertrochanteric fractures, when treated by MIPO, showed a lower rate of blood loss, shorter operative time, and resulted in better functional recovery in the IPOP. Since they are a

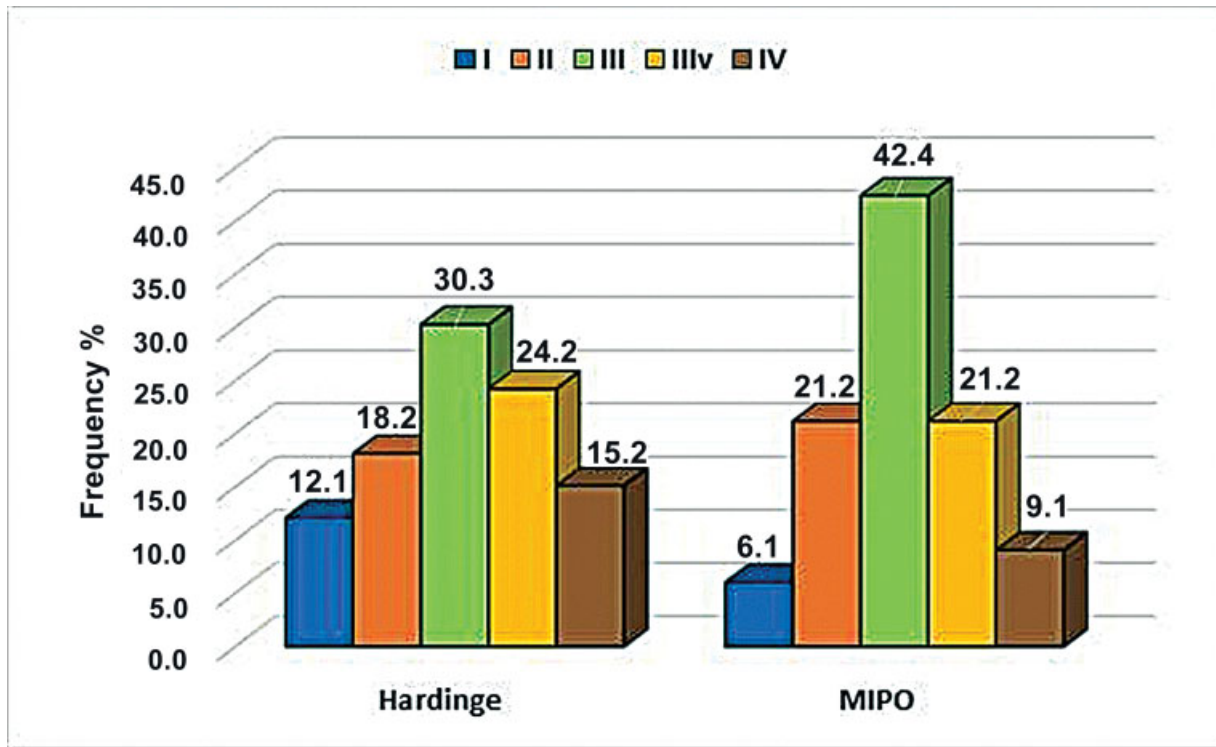


Fig. 3 Distribution of patients regarding the type of fracture according to the Tronzo classification.

Table 2 Comparison of hematimetric loss and operative time between groups

EXAMS	HARDINGE		MIPO		p*
	Average	Standard deviation	Average	Standard deviation	
Preoperative hemoglobin (mg/dL)	12.62	0.85	12.52	0.90	0.643
Preoperative hematocrit (mg/dL)	37.32	2.71	36.90	2.74	0.536
Postoperative hemoglobin (mg/dL)	9.55	0.84	10.80	1.17	< 0.0001
Preoperative hematocrit (mg/dL)	28.05	2.61	31.64	3.49	< 0.0001
Fixation time (minutes)	46.55	5.92	21.03	5.09	< 0.0001
Suture time (minutes)	14.27	3.56	6.15	1.48	< 0.0001

Abbreviation: MIPO, minimally-invasive plate osteosynthesis.

Notes: \*Values of  $p < 0.05$  (5%) were considered statistically significant. Student *t*-test.

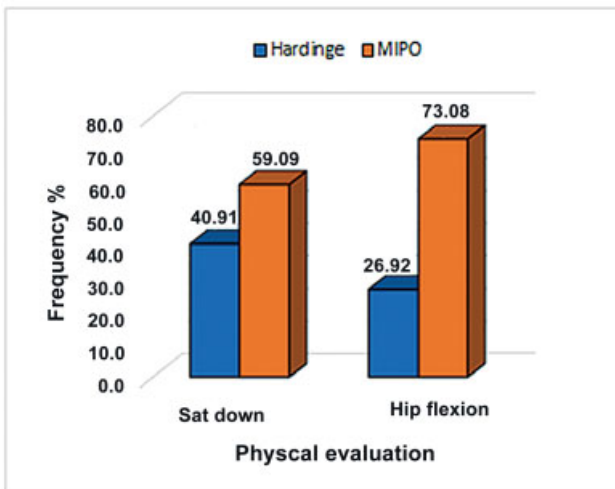


Fig. 4 Evaluation of postoperative active mobility by group.

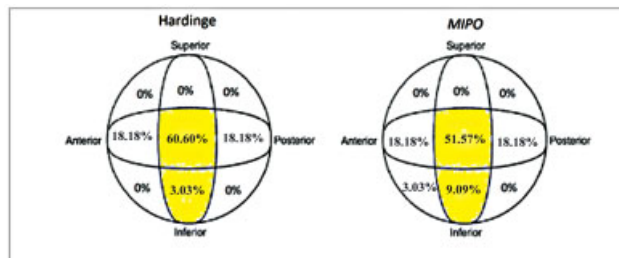


Fig. 5 Distribution of the position of the tip of the sliding screw regarding the femoral head according to the quadrants proposed by the Cleveland Femoral Head Division. In group I, the position was considered adequate in approximately 63% of the cases, and, in group II, in approximately 60%.

peculiar condition in elderly patients whose ideal treatment is surgical, these fractures present high morbidity and mortality rates.<sup>4,5,9,12,13</sup>

In general, orthopedic trauma surgeries have evolved from an era in which anatomical reduction with rigid fixation was recommended. The issue with this principle of osteosynthesis was the noted direct approach to the fracture, with important aggression to the soft tissues and, invariably, great deperiostization of the fragments involved, raising the degree of surgical aggression. The evolution of surgical techniques and the advent of fluoroscopy showed that a less aggressive approach, often without any contact with the fracture focus, had a very satisfactory index of consolidation, and with a lower degree of surgical aggressiveness. Thus began the trend towards minimally-invasive techniques, with indirect reduction of fractures and fixation with the maximum possible preservation of soft tissue adjacent to the focus, preserving the blood supply required for bone healing.<sup>14</sup>

Following the worldwide trend, the surgical treatment of intertrochanteric fractures also underwent important changes. In 1982, the Hardinge access,<sup>6</sup> which had been ideally described for the performance hip arthroplasties, eventually became popular in the treatment of intertrochanteric fractures. However, this broad approach had adverse consequences for the patient, especially regarding blood loss and the degree of postoperative pain.<sup>7</sup> The change in the management of these fractures with the DHS began with a study<sup>7</sup> with 40 patients, in which the authors concluded that a minimally-invasive approach (MIPO) was safe, effective, reduced operative blood loss and the degree of pain, in addition to achieving reduction alignment and proper positioning of the screw, which are predictive factors of good results.

The extramedullary implants for the stabilization of intertrochanteric fractures also underwent an important revolution, from the models that did not allow their impaction, and consequently presented high rates of mechanical failure, to the system developed by Richard with the sliding screw, the precursor of the DHS, which revolutionized the treatment of these patients.<sup>14</sup>

In a technical note published in 2012,<sup>15</sup> the authors proposed the use of the MINUS system, which was an adaptation of the traditional DHS, which used its own instruments to perform the minimally-invasive surgery. The technique consisted of inserting the implants through a mini-incision, and the fixation of the plate to the femoral cortical bone mass performed percutaneously, aided by a template adapted to the system to guide the blockade.<sup>15</sup>

In the present study, all of the surgeries were performed with the same instruments, and for the MIPOs, some operative times were readapted, showing that no special instrument is necessary for the proper and safe performance of this procedure through the minor route.

The choice of fixation of intertrochanteric fractures by an intra- or extramedullary system, such as the DHS, is a historical controversy. The vast majority of studies<sup>1,3-5,16</sup> support the intramedullary method for the most unstable

intertrochanteric fractures. In a prospective study with more than 4 thousand patients in the United States, the superiority of intramedullary implants compared to the traditional DHS was demonstrated in terms of the length of hospitalization after surgery. According to the authors, the shorter hospital stay of patients submitted to the procedure with stems minimizes the costs involved with this type of implant, which is more expensive than the DHS.

In a case series conducted in Brazil,<sup>14</sup> the DHS – through the minimally-invasive access – was the method used for the treatment of intertrochanteric fractures. The authors<sup>14</sup> observed consolidation in all 140 cases, with a death rate of only 1.4% until the sixth month of follow-up, which shows the efficacy of the method as a way of stabilizing the fracture and of the less aggressive access to improve the survival rate of patients.<sup>14</sup>

Mahmood et al.<sup>9</sup> compared the Hardinge access and MIPO in the treatment of intertrochanteric fractures, and they concluded that both techniques are safe, but the implantation of the DHS through MIPO required a shorter operative time, and resulted in a lower volume of bleeding and shorter mean length of hospital stay.

The present study evaluated only the technique of extramedullary fixation with the DHS in the treatment of intertrochanteric fractures. However, the results obtained show that the use of this implant through MIPO provides the short-term benefits observed in the fixation with stems: in theory, it is faster and with less aggressive execution and a lower volume of bleeding. In the present study, the mean time for both fracture fixation and surgical wound closure was significantly lower in patients undergoing MIPO.

In a study conducted in 2016,<sup>4</sup> the volume of bleeding was compared between fixation with proximal femoral nail antirotation (PFNA) and the DHS. The authors<sup>4</sup> concluded that visible bleeding was higher in the group treated with the DHS (in which the surgical access for implantation is larger), and, in contrast, the occult bleeding was more voluminous in patients treated with the nail (in which there is intrasosseous bleeding due to lesions to the endosteum caused by the implantation). The sum of the losses totaled an average of 320 mL in patients treated with the DHS, and of 368 mL in those treated with the PFNA.<sup>4</sup> In a systematic review with meta-analysis, Huang et al.<sup>17</sup> demonstrated that there was no statistically significant difference in bleeding between such methods.

In the present study, the hematimetric loss was measured by measuring the weight hemoglobin per deciliter (mg/dL) on the first postoperative day. The findings revealed that group I presented a higher hematimetric loss than group II, proving the greater aggressiveness to soft tissues of the Hardinge access.

The evaluation of postoperative pain is a trend in all medical specialties. In orthopedic trauma surgery in particular, pain measurement and quality of life assessment gained ground in the same proportion in which less aggressive surgeries started to become a reality. In the present study, the evaluation of pain scores before and after surgery was performed using the Wong-Baker scale. We demonstrated

that group II presented significantly-lower pain scores than those of group I.

In a study to evaluate postoperative pain in different surgical procedures of the hip, several surgeries were compared for the treatment of fractures in this region. The authors observed that the intertrochanteric fractures treated with the DHS and cephalomedullary nails were the procedures with the highest pain index, and they suggested that, for these fractures, new pain control alternatives and new rehabilitation protocols be created.

In another study, conducted in Belgium, Heinrich et al. (2002) compared the degree of postoperative pain in patients with intertrochanteric fractures fixed with the DHS (by the traditional route) and with a percutaneous compression plate. In this study, the researchers concluded that percutaneous surgeries with compression plates evolved with less pain and confirmed the importance of the minimal access to hip surgeries. In addition to the lower degree of pain, less-invasive surgeries required shorter transoperative times. These results coincide with those of the present study, in which patients submitted to MIPO showed lower pain indices.

The present study also demonstrated that the degree of active movement of patients on the first postoperative day was satisfactory, which was assessed by means of two tests. In the first one, in which the patient was instructed to sit in bed with little help from the examiner and remain in this position for up to 10 seconds, as well as in the second one, in which the patient was asked to flex the operated hip with knee extension up to approximately 45° of elevation, group II had a better performance.

As for the position of the sliding screw on the femoral head, Cleveland et al.<sup>20</sup> described a system in which the femoral head was divided into 9 zones, with zones 1 (anterosuperior), 2 (upper central), and 3 (posterosuperior) being the ones with the highest risk of synthesis failure, and zones 5 (central) and 8 (lower central) being the most recommended for the placement of the screw. The surgical technique with minimally-invasive access – despite limiting access to the lateral face of the proximal femur and, consequently, hindering the manipulation of the instruments of the fixation system – did not seem an obstacle to place the sliding screw in its most ideal location. Zones 5 and 8 were affected in more than 60% of the cases both in patients submitted to fixation by the traditional method and by the minimally-invasive route. This fact, associated with the shorter surgical time achieved in the less-invasive surgery group, proves that this access provides benefits to the patient and does not cause technical difficulties regarding the procedure.

Among the limitations of the present study, we highlight the fact that the follow-up was very short, only on the first postoperative day. Therefore, the main complications of hip fixation surgeries in elderly patients, such as systemic and surgical site infections, venous thrombosis with or without thromboembolic events, synthesis failures, and death at any stage of the follow-up other than in the IPOP, were not investigated.

## Conclusion

In conclusion, the minimally-aggressive access route for the treatment of intertrochanteric fractures presented better clinical and functional outcomes than the Hardinge route in terms of operative time, blood loss and degree of immediate postoperative pain.

### Sources of Funding

The present research did not receive any specific grants from funding agencies in the public, commercial or non-profit sectors.

### Conflict of Interests

The authors have no conflict of interests to declare.

## References

- 1 de Abreu EL, de Oliveira MH. Avaliação da qualidade de vida dos pacientes submetidos à hemiartroplastia do quadril. *Rev Bras Ortop* 2015;50(05):530–536
- 2 Sahin S, Ertürer E, Öztürk I, Toker S, Seçkin F, Akman S. Radiographic and functional results of osteosynthesis using the proximal femoral nail antirotation (PFNA) in the treatment of unstable intertrochanteric femoral fractures. *Acta Orthop Traumatol Turc* 2010;44(02):127–134
- 3 Sambandam SN, Chandrasekharan J, Mounasamy V, Mauffrey C. Intertrochanteric fractures: a review of fixation methods. *Eur J Orthop Surg Traumatol* 2016;26(04):339–353
- 4 Yu W, Zhang X, Zhu X, et al. Proximal femoral nails anti-rotation versus dynamic hip screws for treatment of stable intertrochanteric femur fractures: an outcome analyses with a minimum 4 years of follow-up. *BMC Musculoskelet Disord* 2016;17:222
- 5 Egol K. Intertrochanteric hip fractures: the sliding hip screw. In: *Wiss D. Master techniques in orthopaedic surgery: fractures*. Philadelphia: Lippincott Williams & Wilkins; 2013:331–341
- 6 Hardinge K. The direct lateral approach to the hip. *J Bone Joint Surg Br* 1982;64(01):17–19
- 7 Agrawal M, Yuvarajan P, Maini L. Modified minimally invasive approach for dynamic hip screw fixation. *Eur J Orthop Surg Traumatol* 2011;21(05):375–379
- 8 Vidyarthi K, Paluvadi S, Sinha A. Minimally invasive dynamic hip screw for intertrochanteric fractures: comparison with conventional method and surgical tips. *Int J Res Orthop* 2017;3(04):712–717
- 9 Mahmood A, Kalra M, Patralekh MK. Comparison between Conventional and Minimally Invasive Dynamic Hip Screws for Fixation of Intertrochanteric Fractures of the Femur. *ISRN Orthop* 2013;2013:484289
- 10 Ropars M, Mitton D, Skalli W. Minimally invasive screw plates for surgery of unstable intertrochanteric femoral fractures: a biomechanical comparative study. *Clin Biomech (Bristol, Avon)* 2008;23(08):1012–1017
- 11 Martini LA, Moura EC, Santos LC, Malta DC, Pinheiro MdeM. Prevalence of self-reported diagnosis of osteoporosis in Brazil, 2006. *Rev Saude Publica* 2009;43(Suppl 2):107–116
- 12 Ho M, Garau G, Walley G, et al. Minimally invasive dynamic hip screw for fixation of hip fractures. *Int Orthop* 2009;33(02):555–560
- 13 Kammerlander C, Neuerburg C, Verlaan JJ, Schmoelz W, Miclau T, Larsson S. The use of augmentation techniques in osteoporotic fracture fixation. *Injury* 2016;47(Suppl 2):S36–S43
- 14 de Abreu EL, Sena CB, Saldanha Rodrigues Filho SA. Effectiveness of treatment of transtrochanteric fractures with Dynamic Hip



- Screws using minimally invasive access. *Rev Bras Ortop* 2016;51(02):138–142
- 15 Sawaia RN, Belangero WD. THE MINUS® System Minimally Invasive Technique For The Treatment Of Trantrochanteric Fractures. *Rev Bras Ortop* 2012;47(01):113–117
  - 16 Zhang K, Zhang S, Yang J, et al. Proximal femoral nail vs. dynamic hip screw in treatment of intertrochanteric fractures: a meta-analysis. *Med Sci Monit* 2014;20:1628–1633
  - 17 Huang X, Leung F, Xiang Z, et al. Proximal femoral nail versus dynamic hip screw fixation for trochanteric fractures: a meta-analysis of randomized controlled trials. *ScientificWorldJournal* 2013;2013:805805
  - 18 Foss NB, Kristensen MT, Jensen PS, Palm H, Krashennikoff M, Kehlet H. The effects of liberal versus restrictive transfusion thresholds on ambulation after hip fracture surgery. *Transfusion* 2009;49(02):227–234
  - 19 Janzing HM, Houben BJ, Brandt SE, et al. The Gotfried PerCutaneous Compression Plate versus the Dynamic Hip Screw in the treatment of pertrochanteric hip fractures: minimal invasive treatment reduces operative time and postoperative pain. *J Trauma* 2002;52(02):293–298
  - 20 Cleveland M, Bosworth DM, Thompson FR, Wilson HJ Jr, Ishizuka T. A ten-year analysis of intertrochanteric fractures of the femur. *J Bone Joint Surg Am* 1959;41-A:1399–1408