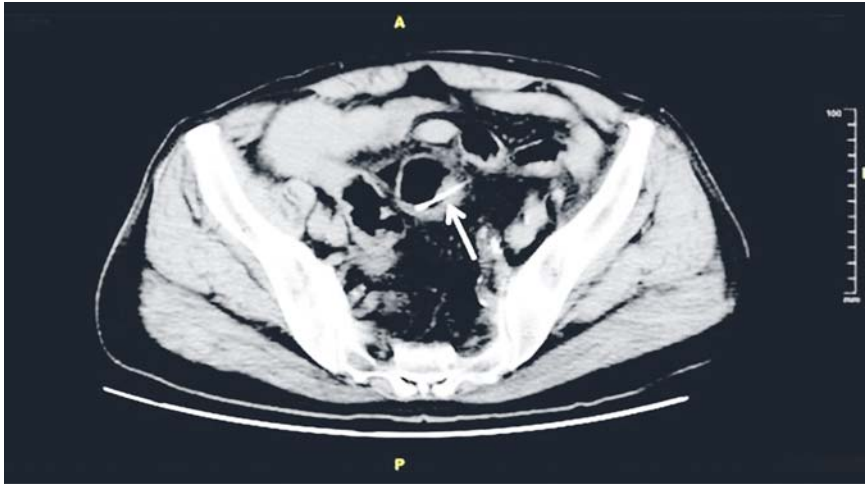
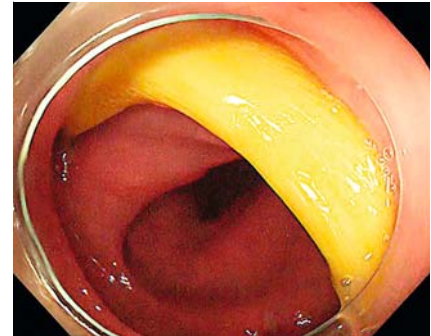


Endoscopic treatment of a sigmoid perforation caused by an ingested fish bone



► **Fig. 1** Computed tomography (CT) scan showing a radiodense linear foreign body (arrow) extending transmurally through the wall of the sigmoid colon.



► **Fig. 2** Colonoscopy view showing a fish bone stuck in the wall of the sigmoid colon.

A 68-year-old man was admitted with severe abdominal pain since the previous day. His physical examination was unremarkable, except for mild lower abdominal tenderness without rebound tenderness. Laboratory tests showed he had an elevated white blood cell count (11 800 cells/ μ L) and increased C-reactive protein (CRP) level (105 mg/L). A computed tomography (CT) scan revealed a radiodense linear foreign body that was extending transmurally through the wall of the sigmoid colon (► **Fig. 1**). Colonoscopy demonstrated a fish bone stuck in the sigmoid colon wall (► **Fig. 2**).

The fish bone was carefully removed using foreign body forceps, leaving an approximately 0.5×0.5-cm perforation in the sigmoid colon wall. The perforation was closed by an over-the-scope clip (OTSC; Ovesco Endoscopy Ag, Germany) (► **Video 1**). After this endoscopic procedure, the patient's lower abdominal discomfort immediately disappeared. He was treated with antibiotics for 3 days and was discharged from hospital without any early complications.

Ingestion of foreign bodies, such as poultry bones, fish bones, coins, and dentures, is a common occurrence among elderly patients, children, alcoholics, patients with psychiatric disorders, and fast eaters [1]. Most foreign bodies are able to pass through the gastrointestinal tract without consequence, while some may

lead to perforation, fistula, hemorrhage, or obstruction of the gastrointestinal tract [2]. Perforation of the sigmoid colon caused by an ingested fish bone is rare. Surgical treatment is usually inevitable if foreign bodies cannot be extracted endoscopically [3]; however, a case where a fish bone-induced sigmoid colonic perforation was successfully treated by conservative management had previously been reported [4]. In our case, the fish bone that had stuck in the wall of the sigmoid colon was successful-

► **VIDEO 1**

► **Video 1:** Colonoscopy demonstrating a fish bone stuck in the wall of the sigmoid colon, which was carefully removed using foreign body forceps, leaving an approximately 0.5×0.5-cm perforation, which was closed by an over-the-scope clip (OTSC). The length of the fish bone was about 5.0 cm.

ly removed with foreign body forceps and the resulting perforation was completely closed by an OTSC, which thereby avoided an aggressive surgical strategy.

Endoscopy_UCTN_Code_CCL_1AD_2AH

Competing interests

None

The Authors

Congcheng Fang, Liping Ye, Xinli Mao, Jinshun Zhang

Department of Gastroenterology, Taizhou Hospital of Zhejiang Province, Linhai, Zhejiang Province, China

Corresponding author

Jinshun Zhang, MD

Department of Gastroenterology, Taizhou Hospital of Zhejiang Province, Taizhou Enze Medical Center(Group), 150 Ximen Street, Linhai 317000, Zhejiang Province, China
Fax: +86-576-85115140
tzzjs@qq.com

References

- [1] Kornprat P, Langner C, Mohadjer D et al. Chicken-bone perforation of a sigmoid colon diverticulum into the right groin and subsequent phlegmomonous inflammation of the abdominal wall. *Wien Klin Wochenschr* 2009; 121: 1 – 2

- [2] Sarsu SB, Karakus SC, Erdem AU. Colon perforation caused by a foreign body in Hirschsprung disease. *J Pediatr Surg* 2012; 47: e15 – e17
- [3] Cho MK, Lee MS, Han HY et al. Fish bone migration to the urinary bladder after resectosigmoid colon perforation. *World J Gastroenterol* 2014; 20: 7075 – 7078
- [4] Watanable M, Kou T, Nishikawa Y et al. Perforation of the sigmoid colon by an ingested fish bone. *Inter Med* 2010; 49: 1041 – 1042

Bibliography

DOI <http://dx.doi.org/10.1055/s-0042-124500>
Endoscopy 2017; 49: E82–E83
© Georg Thieme Verlag KG
Stuttgart · New York
ISSN 0013-726X