

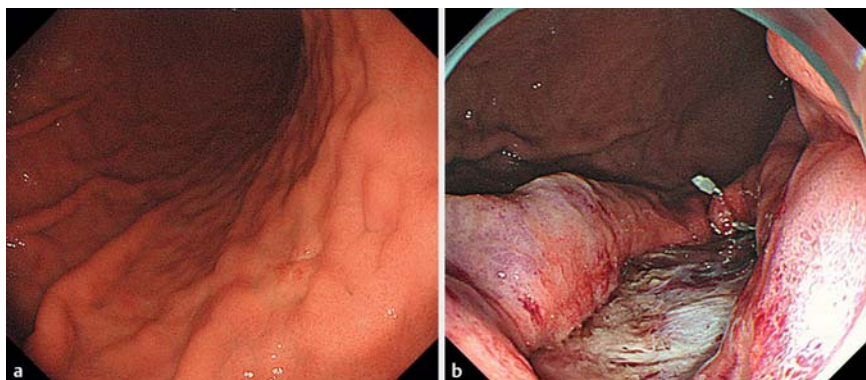
Successful endoscopic closure using over-the-scope clip for delayed stomach perforation caused by nasogastric tube after endoscopic submucosal dissection

A 55-year-old woman was found to have a depressed lesion on the posterior part of the lower gastric body (► **Fig. 1 a**). The patient underwent endoscopic submucosal dissection (ESD) and en bloc resection without intraoperative perforation. Prophylactic endoscopic coagulation using Coagrasper (Olympus Medical, Tokyo, Japan) was performed for visible vessels, and endoclips were applied prophylactically to close tiny injuries to the muscularis propria (► **Fig. 1 b**). As significant bile juice reflux was noticed during endoscopy, a 14-Fr soft nasogastric tube was inserted. Smooth drainage of gastric fluid was observed.

During the night following the procedure, the patient developed severe upper abdominal pain and nausea, and both radiography and computed tomography revealed free air, with a migrated nasogastric tube outside the stomach (► **Fig. 2 a**). Emergency esophagogastroduodenoscopy (EGD) after removal of the tube identified a cylindrical perforation, which was probably caused by mechanical penetration of the nasogastric tube (► **Fig. 2 a, b**, ► **Video 1**).

After interdisciplinary discussion with surgeons it was decided to close the perforation endoscopically. The whole wall defect was closed using an over-the-scope clip (OTSC, 12/6t; Ovesco, Tübingen, Germany). A Twin grasper (Ovesco) was necessary to grasp and appose the two edges of the perforation site. After careful retraction of the edges into the cap, the OTSC device was directed towards the perforation, the clip was released, and the wound was closed successfully (► **Fig. 2 c**). Follow-up EGD demonstrated sustained closure of the perforation, and gastric series confirmed no leakage of contrast (► **Fig. 2 d**, ► **Video 1**). The patient was discharged home 12 days after ESD.

The resected specimen revealed a completely resected, depressed mucosal adenocarcinoma, 18 mm in size with moder-

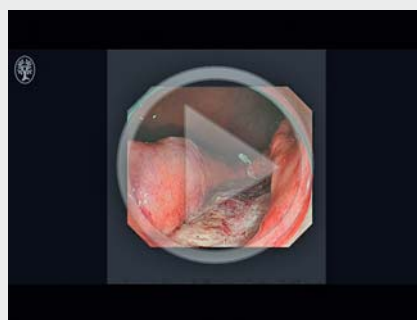


► **Fig. 1** Endoscopic submucosal dissection (ESD) for a gastric lesion. **a** The depressed lesion on the greater curvature of the lower gastric body. **b** The patient underwent ESD and en bloc resection, without intraoperative perforation.

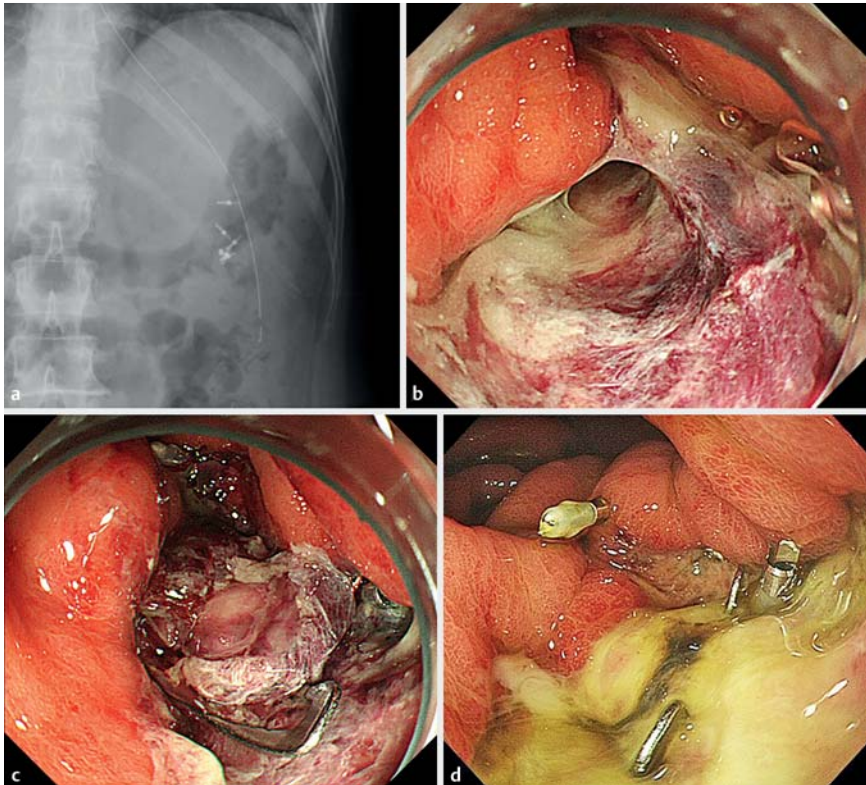
ate to poor differentiation, but without lymphovascular invasion or ulceration. Some experts recommend nasogastric tube intubation for diversion of gastrointestinal fluids such as bile, which may induce delayed perforation after gastric ESD [1,2]. This case highlights the utility of large size OTSCs with Twin grasper to close a rare but complex delayed perforation, which was probably caused by a

post-ESD nasogastric tube. Although endoclips can be used, this perforation was complex and large, and thus it would have been impossible or technically much more challenging to close the hole. The opposition forces of OTSCs are much stronger and may result in a more secure closure, thus avoiding emergency surgery [3,4].

► VIDEO 1



► **Video 1:** Endoscopic submucosal dissection of a gastric lesion, and closure of a subsequent perforation. A Twin grasper (Ovesco, Tübingen, Germany) was used to grasp and appose the two mucosal edges. Then, suction was applied to pull the mucosal edges into the cap. The over-the-scope clip device was directed towards the perforation, the clip was released, and the wound was closed successfully. The perforation was probably caused by the nasogastric tube that was placed after gastric endoscopic submucosal dissection.



► **Fig. 2** The nasogastric tube caused perforation following endoscopic submucosal dissection. **a** Radiography and computed tomography revealed a migrated nasogastric tube outside the stomach. **b** A cylindrical delayed perforation caused by mechanical penetration of the nasogastric tube. **c** The over-the-scope clip (OTSC) device was directed towards the perforation, the clip was released, and the wound was closed successfully. **d** Follow-up esophago-gastroduodenoscopy 4 days after OTSC application demonstrated sustained closure of the perforation.

Endoscopy_UCTN_Code_CPL_1AH_2AZ

Competing interests

None

The Authors

Seiichiro Abe¹, Takeyoshi Minagawa^{1,2}, Hirohito Tanaka^{1,3}, Ichiro Oda¹, Yutaka Saito¹

1 Endoscopy Division, National Cancer Center Hospital, Tokyo, Japan

2 Department of Gastroenterology, Tonan Hospital, Sapporo, Japan

3 Department of Gastroenterology and Hepatology, Gunma University, Gunma, Japan

Corresponding author

Seiichiro Abe, MD

Endoscopy Division, National Cancer Center Hospital, 5-1-1 Tsukiji, Chuo-ku, Tokyo 104-0045, Japan

Fax: +81-3-35423815

seabe@ncc.go.jp

Acknowledgments

The authors are grateful to Satoru Nonaka, MD, PhD, Haruhisa Suzuki, MD, Shigetaka Yoshinaga, MD, PhD (Endoscopy Division, National Cancer Center Hospital), and Ayyakannu Kumar, MD (Barking Havering and Redbridge University Hospitals NHS Trust, Romford, London, UK) for their kind support relating to this report.

References

- [1] Minami S, Gotoda T, Ono H et al. Complete endoscopic closure of gastric perforation induced by endoscopic resection of early gastric cancer using endoclips can prevent surgery (with video). *Gastrointest Endosc* 2006; 63: 596–601
- [2] Paspatis GA, Dumonceau JM, Barthet M et al. Diagnosis and management of iatrogenic endoscopic perforations: European Society of Gastrointestinal Endoscopy (ESGE) position statement. *Endoscopy* 2014; 46: 693–711
- [3] Mönkemüller K, Peter S, Toshniwal J et al. Multipurpose use of the 'bear claw' (over-the-scope-clip system) to treat endoluminal gastrointestinal disorders. *Dig Endosc* 2014; 26: 350–357
- [4] Abe S, Council L, Cui X et al. Endoscopic resection and enucleation of gastric submucosal tumor facilitated by subsequent closure of incision using over-the-scope clip. *Endoscopy* 2015; 47 (Suppl. 01): E153–154

Bibliography

DOI <http://dx.doi.org/10.1055/s-0042-123696>

Endoscopy 2017; 49: E56–E57

© Georg Thieme Verlag KG

Stuttgart · New York

ISSN 0013-726X