

# Iodinated Contrast Media and the Alleged “Iodine Allergy”: An Inexact Diagnosis Leading to Inferior Radiologic Management and Adverse Drug Reactions

## Jodierte Kontrastmittel und die sogenannte „Jodallergie“: eine unexakte Diagnose führt zu ineffizientem radiologischen Management und unerwünschten Arzneimittelwirkungen

### Authors

Ingrid Böhm<sup>1,2</sup>, Knud Nairz<sup>1</sup>, John N. Morelli<sup>3</sup>, Patricia Silva Hasembank Keller<sup>1</sup>, Johannes T. Heverhagen<sup>1,2</sup>

### Affiliations

- 1 Department of Diagnostic, Interventional and Pediatric Radiology, Inselspital, Bern University Hospital, University of Bern, Bern, Switzerland
- 2 Department of Clinical Research (DCR), University of Bern, Switzerland
- 3 Radiology, St. John's Medical Center Tulsa, United States

### Key words

CT, contrast agents, drugs/reactions, safety

received 11.7.2016

accepted 18.11.2016

### Bibliography

DOI <http://dx.doi.org/10.1055/s-0042-122148>

Published online: 1.3.2017 | Fortschr Röntgenstr 2017; 189: 326–332

© Georg Thieme Verlag KG Stuttgart · New York

ISSN 1438-9029

### Correspondence

Dr. Ingrid Böhm  
Dept. of Diagnostic, Interventional and Pediatric Radiology,  
University of Bern  
Freiburgstrasse  
3010 Bern  
Switzerland  
Tel.: +41/31/6 32 24 35  
Fax: +41/31/6 32 48 74  
[ingrid.boehm@insel.ch](mailto:ingrid.boehm@insel.ch)

### ZUSAMMENFASSUNG

**Ziel** Ziel dieser Studie war die Überprüfung der Hypothese, dass die ungenaue Diagnose „Jodallergie“ für Patienten unter radiologischen Routinebedingungen möglicherweise gefährlich ist.

**Material und Methode** 300 Patienten mit einer anamnestischen sogenannten „Jodallergie“ wurden retrospektiv im Sinn einer Fall-Kontroll-Studie (Gruppenvergleich mit Übereinstimmung von Alter, Geschlecht und radiologischer Untersuchung) analysiert. Es gab 2 Kontrollgruppen mit der Diagnose „Kontrastmittelallergie“, und zwar ohne und mit bekanntem Auslöser. In allen Gruppen wurden die klinischen Symptome der letzten unerwünschten Arzneimittelreaktion

(UAW) auf jodiertes Kontrastmittel (JKM), die prophylaktischen Maßnahmen vor einer JKM-Gabe sowie mögliche UAWs nach erfolgter JKM-Prophylaxe erfasst und analysiert.

**Ergebnisse** Die Diagnose „Jodallergie“ war bei 84,3 % Patienten nicht spezifiziert. In dieser Gruppe waren bei den meisten Fällen die Symptome vormals durchgemachter UAWs nicht dokumentiert. Im Gegensatz dazu waren die klinischen Symptome in den anderen beiden Gruppen in den meisten Fällen vorhanden. Der höchste Prozentsatz nativer CTs fand sich in der Gruppe der „Jodallergiker“ (36,7 % vs. 28,7 %/18,6 %). UAWs nach prophylaktischen Maßnahmen gab es ausschließlich in der Gruppe mit der „Jodallergie“ (OR 9,24; 95 %CI 1,16 – 73,45;  $p < 0,04$ ).

**Schlussfolgerungen** Die Daten bestätigen die Hypothese, dass die Diagnose „Jodallergie“ zur Unsicherheit im Rahmen des klinischen prophylaktischen Managements führt und sogar mit einem potentiellen Risiko für KM-Reaktionen verbunden ist. Folglich sollte der Ausdruck „Jodallergie“ durch exakte Begriffe wie JKM-Allergie oder, besser, durch Nennung des jeweiligen Auslösers ersetzt werden.

### Kernaussagen

- Der Begriff „Jodallergie“ ist ungenau, weil er Allergien gegen unterschiedliche Substanzklassen, wie Desinfektionsmittel mit komplexiertem Jod und Kontrastmittel mit kovalent-gebundenem Jod, beinhaltet.
- Es findet sich eine eindeutige Korrelation zwischen der Genauigkeit der Diagnose – von der sogenannten „Jodallergie“ zur „Kontrastmittelallergie“ und zur exakten Bezeichnung des auslösenden Kontrastmittels – und der Qualität der Dokumentation der Symptome.
- Das Patientenmanagement bei der Diagnose „Jodallergie“ war mit einer Unsicherheit verbunden. Dies führte dazu, dass native Bildgebung sowie in einigen Fällen unnötige prophylaktische Maßnahmen ergriffen wurden.
- Der Begriff „Jodallergie“ sollte vermieden werden, weil er potentiell gefährlich ist und möglicherweise die Qualität radiologischer Untersuchungen negativ beeinflussen kann.

### ABSTRACT

**Purpose** To test the hypothesis that the incomplete diagnosis “iodine allergy” is a possibly dangerous concept for patients under routine radiologic conditions.

**Materials and Methods** 300 patients with a history of an “iodine allergy” were retrospectively screened and compared with two age-, sex-, and procedure-matched groups of patients either diagnosed with a nonspecific “iodine contrast medium (ICM) allergy” or an allergy to a specific ICM agent. For all groups, the clinical symptoms of the

most recent past adverse drug reaction (ADR), prophylactic actions taken for subsequent imaging, and ultimate outcome were recorded and analyzed.

**Results** The diagnosis “iodine allergy” was not otherwise specified in 84.3% patients. For this group, in most cases, the symptoms of the previous ADRs were not documented. In contrast, the type of ADR was undocumented in only a minority of patients in the comparison groups. In the group of patients with an “iodine allergy” the percentage of unenhanced CT scans was greater than within the other two groups (36.7% vs. 28.7%/18.6%). ADRs following prophylactic measures were only observed in the “iodine allergy” group (OR of 9.24 95% CI 1.16–73.45;  $p < 0.04$ ).

**Conclusion** This data confirms the hypothesis that the diagnosis “iodine allergy” is potentially dangerous and results in uncertainty in clinical management and sometimes even ineffective prophylactic measures.

#### Key points

- The term “iodine allergy” is imprecise, because it designates allergies against different substance classes, such as disinfectants with

complexed iodine and contrast media containing covalently bound iodine.

- There is a clear correlation between the exactness of the diagnosis – from the alleged “iodine allergy” to “contrast media allergy” to naming the exact culprit CM – and the quality of documentation of the symptoms.
- Management of patients diagnosed with “iodine allergy” was associated with uncertainty leading to unenhanced scans and sometimes unnecessary prophylactic actions.
- The term “iodine allergy” should be omitted, because it is potentially dangerous and can decrease the quality of radiology exams.

#### Citation Format

- Böhm Ingrid, Nairz Knud, Morelli John N et al. Iodinated Contrast Media and the Alleged “Iodine Allergy”: An Inexact Diagnosis Leading to Inferior Radiologic Management and Adverse Drug Reactions. *Fortschr Röntgenstr* 2017; 189: 326–332

## Introduction

Iodinated contrast media (ICM) are the most frequently utilized contrast agents worldwide. More than 70 million CT scans were performed in the United States alone in 2007 [1] with a clear trend toward increased future utilization [2]. Based on this, it is estimated that the administration of ICM is performed at least 100 million times each year worldwide. Although low-osmolality ICM agents have an excellent safety/risk profile, adverse drug reactions (ADRs) in general or hypersensitivity reactions (HSRs) in particular occur in approximately 3–30% and 1–3%, respectively [3, 4]. HSRs are per definitionem so-called type B reactions [5] and therefore are not predictable. Despite this fact, several authors have identified risks predisposing patients to HSRs [6], in particular a history of previous CM-related hypersensitivities [6]. In other words, adequate screening of patients prior to contrast administration remains an important prerequisite for the safe performance of contrast-enhanced CT (CECT).

Safe ICM administration is dependent on several preconditions, one of which is the use of precise nomenclature. Imprecise or incorrect terminology potentially places the patient at risk. One of the most important nonspecific terms within the context of ICM-related ADRs is the concept of an “iodine allergy”. Indeed a true “iodine allergy”, meaning an allergy against elemental iodine, would be lethal [7]. We hypothesize that this nomenclature is more problematic than helpful and poses a potential safety risk. A thorough search of the available literature did not identify a formal evaluation of patients with an “iodine allergy” undergoing contrast-enhanced radiologic procedures. To verify the aforementioned hypothesis, patients with an alleged “iodine allergy” listed in the medical record were analyzed. The goal of the present paper is threefold: 1) to identify the possible clinical meaning of individual “iodine allergies”, 2) to analyze the resulting clinical consequences/prophylactic actions arising from alleged “iodine allergies” including possible ADRs that occurred after prophylaxis, and finally 3) to recommend a practical method to ensure the safe

administration of ICM in future contrast-enhanced procedures for patients diagnosed with an “iodine allergy”.

## Patients and Methods

### Investigated population and study design

The radiologic information system (RIS database) at a radiology department within an academic medical center was searched to identify patients with a history of an “iodine allergy” (group 1) for whom imaging had been subsequently ordered. Either a full-text search of all relevant dates (1997–2015) or a screening by individual timeframes (01/2014–03/2014 and 01/2015–12/2015) was performed. Two age-, sex-, and procedure-matched control groups were identified within the RIS database consisting of patients with ADRs related to ICM who subsequently underwent imaging. These were divided into patients for whom a non-specific “iodine contrast medium (ICM) allergy” was documented but the exact culprit ICM was unknown (group 2) and those for whom a specific culprit agent for ICM allergy was known (group 3 or substance allergy group). The institutional review board (IRB) approved this study. Informed signed consent was waived because of the retrospective nature of the study.

The inclusion criteria were adult patients (> 18 years old) with a history of a so-called “iodine allergy” for whom contrast-enhanced CT imaging was ordered between January 1997 and December 2015. All documented explanations or descriptions of the term “iodine allergy” were explored in the medical record. Epidemiologic baseline data were collected including age, sex, medical history, history of allergic disorders, any available details about previous reactions to ICM, the administered contrast materials, the type of radiological procedure, prophylactic actions (e. g. premedication or change of procedure), and finally the outcome (i. e., whether a reaction ultimately occurred after CM administration). The severity of both historical reactions in the patients with an “iodine allergy” and of any subsequent reactions to the administration contrast material was classified according to

the previously published grading system (see ► **Table 1**) [8]. We also screened the data for AEs or HRSs that occurred in spite of different prophylactic actions. Evidence of a CM-related AE was analyzed using the Naranjo adverse drug reaction probability scale [9].

**Statistics**

Continuous variables were expressed as mean ± standard deviation (SD). Categorical variables were expressed by frequencies and percentages. The Chi-square test (Pearson) and Fisher’s exact test were used to compare qualitative (categorical) variables and the Student’s t-test or the Mann-Whitney U-test to compare quantitative (continuous) variables.

Multiple logistic regression analysis was used to identify the risk factors related to AEs in patients in groups 1 and 2. The magnitude of risk was calculated with the odds ratio (OR). 95% two-sided Cornfield’s confidence intervals (CI) were constructed according to Clopper-Pearson.

P-values (two-tailed tests) <0.05 were considered statistically significant. Statistical analysis was performed with Stata version 12 software for Windows (StataCorp LP, Lakeway Drive, College Station, Texas, USA).

**Results**

**Patient profiles**

Group 1 consisted of 300 patients (men n = 108/36.0%) with a documented history of the alleged “iodine allergy”. The mean age of the study population was 63.3 ± 13.3 years. The mean age of men and women was identical (63.3 ± 12.5 years vs. 63.3 ± 13.7 years; p = 0.95).

Group 2 consisted of age-, sex-, and procedure-matched patients (n = 230) diagnosed with an “ICM allergy” to an unknown culprit agent. The proportion of men was 39.1% and the mean age was 61.5 ± 13.6 years, does not statistically significantly different from group 1 (p = 0.94).

Group 3 consisted of age-, sex-, and procedure-matched patients (n = 70) with a clear and specifically documented ICM allergy (e. g., “iopromide allergy”). 15.7% of the patients were men and the mean age in the group was 59.3 ± 14.0 years, again this was not statistically significantly different from the other groups (p = 0.96).

**Diagnostic explanation of the term “iodine allergy”**

275 out of the 300 patients of group 1 were clearly diagnosed as having an “iodine allergy” and 25 (8.3%) were documented as having a “suspected iodine allergy”. For the analysis, these two subgroups were grouped together and defined as “iodine allergy” patients.

In 253 (84.3%) of the group 1 patients the term “iodine allergy” was not further explained. In 47 (15.7%) patients the diagnosis was further specified in reports as: 24 (8.0%) cases with CM allergy, 20 (6.7%) antiseptic allergies, and 4 (1.3%) seafood allergies. In one case, both CM allergy and antiseptic allergy were documented. No instances of an amiodarone drug allergy, sometimes referred to as an “iodine allergy” as well [10], were found in our sample.

**Disease spectrum, prophylaxis, and subsequent adverse reactions**

Generally, the more specific the diagnosis, the more information was available. Only 11.7% of patients in group 1 had documented symptoms pertaining to the previous hypersensitivity reaction, while in 88.3% both the clinical features and the severity of the so-called “iodine allergy” remained unknown (► **Table 2, 3**). However, in patients either with a nonspecific ICM allergy (group 2) or a specific ICM allergy (group 3), previous clinical symptoms and severity were documented in 65.2% and 90% of cases, respectively (see ► **Fig. 1a**, ► **Table 2, 3** for details).

A spectrum of different prophylactic actions was performed in the three groups prior to subsequent diagnostic imaging. In the majority of procedures, some prophylaxis was documented, but up to 10% of the examinations were performed without any

► **Table 1** Clinical features and severity grading of CM-induced reactions from the literature [8].

► **Tab. 1** Klinische Symptome und Schweregrade der KM-induzierter Reaktionen nach Literatur [8].

severity grade	features	actions
1 – mild	heat/cold feeling, nausea, vomiting, flushing, mild urticaria or other anatomically limited skin disease (e. g. fixed drug eruption), itching	no treatment necessary
2 – moderate	angioedema, generalized urticaria or other skin disease (e. g. maculopapular exanthema), bronchospasm, dyspnea, stridor, wheeze, moderate hypotension, tachycardia, chest or throat tightness, dizziness	anti-allergy drug treatment (e. g. with corticosteroids and H1-antihistamines) can be performed in the radiology department patient can be discharged after remission of symptoms
3 – severe	prolonged hypotension, ventricular fibrillation, angina, myocardial infarction, cardiac arrest, severe bronchospasm, pulmonary edema, respiratory arrest, cardiovascular collapse, confusion, loss of consciousness, convulsion, Stevens–Johnson syndrome, toxic epidermal necrolysis, contrast-induced nephropathy, nephrogenic systemic fibrosis	hospitalization necessary

► **Table 2** Severity of symptoms and their frequency of occurrence within the three analyzed groups for past ADRs described in the medical record. Of note, the majority of patients in group 1 did not have sufficient documented information to enable the classification of symptoms.

► **Tab. 2** Schwere der Symptome und ihre Häufigkeit in der letzten dokumentierten UAWs in den drei analysierten Gruppen. Es ist bemerkenswert, dass bei den meisten Patienten der Gruppe 1 keine ausreichende Information vorhanden war.

severity grade	group 1 "Iodine allergy"	group 2 "ICM allergy"	group 3 specific allergy
1 – mild	37.1 %	61.3 %	76.2 %
2 – moderate	22.9 %	20.7 %	14.3 %
3 – severe	40.0 %	18.0 %	9.5 %
absolute numbers	35	150	63

► **Table 3** Frequency (absolute numbers and percentages) of past symptoms in groups 1 – 3 (n.s. = not significant).

► **Tab. 3** Häufigkeit (absolute Anzahl und prozentual) der klinischen Symptome der letzten KM-UAW der Gruppen 1 – 3 (n.s. = nicht signifikant).

clinical features and symptoms	group 1 "Iodine allergy"	group 2 "ICM allergy"	group 3 Specific allergy	p-value		
				group 1 vs. 2	group 1 vs. 3	group 2 vs. 3
unknown	88.3 %	34.8 %	10.0 %	<0.0001	<0.0001	<0.0003
known	11.7 %	65.2 %	90.0 %	<0.0001	<0.0001	<0.0003
cutaneous symptoms	4.0 %	34.8 %	48.6 %	<0.0001	<0.0001	<0.04
shivering/fatigue	0.0 %	1.3 %	0.0 %	n.s.	n.s.	n.s.
delayed reaction	0.3 %	3.5 %	4.3 %	<0.03	n.s.	n.s.
cardiopulmonary symptoms	3.0 %	10.9 %	11.4 %	<0.0007	<0.005	n.s.
rhinitis/sneezing	0.0 %	0.4 %	7.1 %	n.s.	n.s.	n.s.
gastrointestinal symptoms	0.3 %	12.2 %	24.3 %	<0.0004	<0.0001	<0.02
neurological/ophthalmological	0.0 %	4.8 %	1.4 %	n.s.	n.s.	n.s.
anaphylaxis	4.7 %	7.8 %	7.1 %	n.s.	n.s.	n.s.
absolute numbers	300	230	70			

prophylactic measures (► **Table 4**). The prophylactic actions varied throughout the studied groups. For instance, non-contrast CT imaging was performed more often in group 1 than in group 2 ( $p < 0.02$ ) and group 3 ( $p < 0.003$ ). Moreover, in the control groups (2 and 3), the culprit ICM was often omitted and another ICM was injected, while in group 1 the chemical class of contrast agents was changed to barium or gadolinium (see ► **Fig. 1b**, ► **Table 4** for details). In general, the more accurate the diagnosis, the higher the likelihood that the originally ordered examination and modality was performed (► **Fig. 1b**).

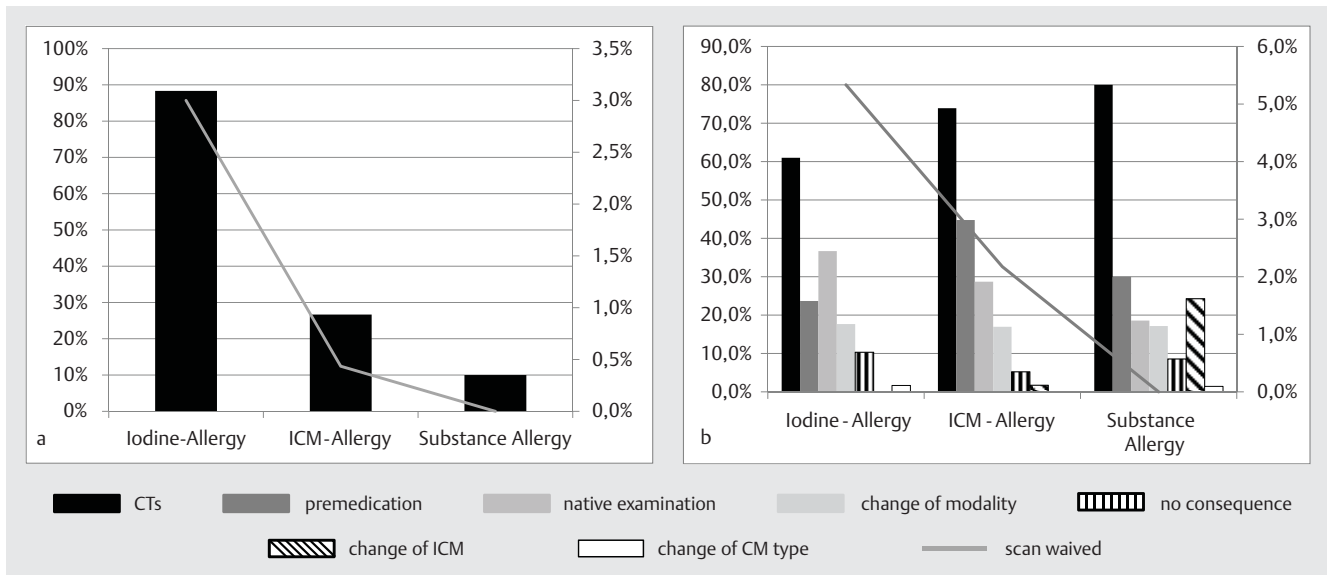
The less specific the terminology utilized to describe previous ADRs, the greater the prevalence of AEs/ADRs in the three patient groups ( $r = 0.981$ ;  $p < 0.00001$ ). In fact, no group 3 patients experienced an AE/ADR, whereas 9 (3.0%) patients in group 1 experienced a reaction. A reaction occurred in one group 2 patient (0.4%) (see ► **Fig. 1a**, ► **Table 5** for details).

All reactions in group 1 were ADRs: eight reactions could be related to the CM administration, and one reaction occurred due to the application of polyvidone (PVP) iodine. In group 2, only one

woman who had refused premedication had a reaction. No patients in group 3 experienced an ADR following the prophylactic action. An OR of 9.24 for an ADR (95% CI 1.1642 to 73.4541;  $p < 0.04$ ) was calculated for group 1 as compared to the two other groups.

## Discussion

Previous papers dealing with "iodine allergy" and ICM application either focused on implying that this kind of allergy does not exist or on questionnaire results [6, 11 – 16]. This study examines for the first time the incidence of subsequent ADRs in patients referred to as having a history of "iodine allergy" versus the ADR rate in cases where a specific or nonspecific history of ICM allergy is documented. 9 of 10 ADRs occurred in the "iodine allergy" group. A clear correlation between the precision of diagnosis and propensity to have a subsequent reaction was found.



**Fig. 1** a Correlation between the prevalence of ADRs (black bars – left y-axis) and the prevalence of nonspecific clinical features (grey line – right y-axis) (top). b Correlation between the frequencies of prophylactic management/frequencies of CT examinations (bars – left y-axis) in the three groups and the frequency of cancelled scans (grey line – right y-axis) (bottom).

### The diagnosis “iodine allergy” is inexact and associated with insufficient documentation

The first issue to be addressed in this study was the analysis of the term “iodine allergy”, which remained unexplained in the majority (84.3 %) of the patient cohort. Only in a remaining 15.7 % patients were further annotations such as CM allergy, antiseptic allergy, and fish/seafood allergy documented. As expected, the definition of an “iodine allergy” was heterogeneous. According to the literature, the term “iodine allergy” describes four different conditions: ICM allergy, disinfectant allergy, amiodarone allergy and/or seafood (shellfish or fish) allergy [10, 12, 16, 17].

Because of its vagueness, we recommend that the term “iodine allergy” should be omitted in the future and replaced with the offending agent when possible and the associated reaction. Patients with an allergy to iodinated antiseptics, amiodarone, or seafood, for example, can safely receive all ICMs without premedication (except in the case of a concurrent ICM allergy).

Antiseptics based on PVP iodine may induce local irritation or in a minority of cases an allergic reaction such as a so-called type IV allergy or contact dermatitis [18]. Immediate type (type I allergy) reactions with allergen-specific IgE have been rarely described [19]. All reactions should be diagnosed by adequate test procedures (patch tests for delayed reactions and prick/intradermal tests for immediate reactions). One should be aware that polyvidone iodine is broadly used as an antiseptic compound not only in disinfectants but also in different drugs and sometimes even in ICM solutions [20]. Unfortunately, current package labeling for available ICM solutions does not mention polyvidone iodine content. Patients with PVP hypersensitivity should receive an alternative antiseptic material (e. g. chlorhexidine, alcohol). In this study, one patient in group 1 was treated with PVP iodine for an interventional radiological procedure and subsequently developed an allergic reaction.

Seafood allergies were also initially assumed to be an “iodine allergy” [12, 13, 16, 21]. Now it is clear that tropomyosin, a muscle protein of crustaceans, or parvalbumin, a muscle protein of fish, contribute to immediate type allergies in patients with seafood allergy [13]. Therefore, patients with hypersensitivity (allergic or non-allergic) to seafood should omit these in their diet, but can receive all iodinated CM.

### Prophylactic actions

Patients truly at an increased risk for iodinated CM ADR (i. e. history of a CM-induced hypersensitivity reaction) should undergo a special prophylactic management program. In this study, clinical management was altered in all patient groups; only in a minority of patients was no special prophylaxis task performed (▶ **Table 4**). However, the nonspecific term “iodine allergy” and the often associated lack of clinical documentation about the ADR led to uncertainty in the management of these cases.

In approximately 20 % of patients in group 1, an anti-allergic premedication was applied before an ICM was subsequently given (▶ **Table 4**). Premedication as a prophylactic procedure has both advantages and disadvantages. If the patient has a true allergy to ICM, it may be helpful. However, premedication protocols lack standardization, and even drugs utilized for premedication can induce ADRs. Finally, breakthrough reactions can occur even with premedication [22]. In special cases, premedication may be indicated; however, it is far from a universal solution.

In most patients with an “iodine allergy”, the modality was changed to an MRI examination. This is in line with several papers that recommend MRI, GBCA application for CT, or, to a lesser extent, ultrasound in patients with an ICM allergy or “iodine allergy” [23 – 26]. However, GBCA can induce both AEs and hypersensitivity reactions. Moreover, even initial contact with a GBCA can lead to an allergic reaction as reported previously [27] and also

► **Table 4** Comparison of prophylaxis/clinical consequences of previous ADRs in groups 1–3 (n.s. = not significant).

► **Tab. 4** Vergleich der Prophylaxe / klinischen Konsequenzen bei vorausgegangenem UAWs der Gruppen 1–3 (n.s. = nicht signifikant).

clinical consequences	group 1 “iodine allergy“	group 2 “ICM allergy“	group 3 Specific allergy	p-value		
				group 1 vs. 2	group 1 vs. 3	group 2 vs. 3
no consequence	10.3 %	5.2 %	8.6 %	<0.04	n.s.	n.s.
altered examination:						
▪ non-contrast CT	36.7 %	29.1 %	18.6 %	n.s.	<0.005	n.s.
▪ premedication prior to contrast CT	23.7 %	44.8 %	30.0 %	<0.0001	n.s.	<0.03
▪ change of modality	17.7 %	17.0 %	17.1 %	n.s.	n.s.	n.s.
▪ imaging not performed	5.7 %	2.6 %	0.0 %	n.s.	–	n.s.
▪ gastrointestinal ICM application	2.3 %	0.0 %	0.0 %	–	–	–
▪ anesthesia stand-by/anesthesia	1.7 %	0.0 %	0.0 %	–	–	–
▪ change of CM type	1.7 %	1.7 %	25.7 %	n.s.	<0.0001	<0.0001
▪ lower ICM volume	0.0 %	0.4 %	0.0 %	–	–	–
▪ non-iodine disinfection	0.7 %	0.0 %	0.0 %	–	–	–
absolute numbers	300	230	70			

► **Table 5** Overview of individual patients with ADRs despite prophylactic action.

► **Tab. 5** Überblick einzelne Patienten mit UAWs trotz prophylaktischer Maßnahmen.

severity grade	classification	patient age, sex	prophylactic management	adverse event
1 – mild	group 1	41, female	none	vomiting
	group 2	60, female	none (premedication refused)	cutaneous symptoms (neck)
	group 1	68, female	none	local reaction by PVP iodine
	group 1	61, male	premedication <sup>1</sup>	conjunctivitis
	group 1	47, female	change of modality (MRI)	cutaneous symptoms
2 – moderate	group 1	62, female	premedication <sup>1</sup>	larynx edema, cutaneous symptoms
	group 1	76, male	premedication <sup>1</sup>	breathing difficulties, nausea
	group 1	49, female	change of modality (MRI)	tachycardia
	group 1	64, female	change of modality (MRI)	erythema, palpitations, arrhythmias, hypertension
3 – severe	group 1	75, male	change of CM type (barium)	aspiration

<sup>1</sup> Intravenous injection of 2 mg clemastine and 125 mg methylprednisolone.

found in the unpublished observations of the authors. In fact, the change to MR examinations in our study group was accompanied by AEs as well (► **Table 5**). In 4 out of 51 examinations when the modality was changed, ADRs were observed. A change of the CM class was performed rarely: twice barium was used instead of ICM for CT, once GBCA, and once CO<sub>2</sub>. Unfortunately, one patient received per os barium in lieu of ICM resulting in the aspiration of barium. As this case demonstrates, changing of the CM class is not necessarily a safe alternative. A change of the contrast medium within the group of iodinated CMs was performed in

groups 2 and 3 (► **Table 4**). This prophylactic task was not accompanied by adverse reactions, and can be recommended as described previously [28].

Some patients received gastrointestinal CM application as prophylaxis. However, it should be noted that there is still some risk related to this application route [29].

In 16 cases the examinations were cancelled because the patients had a positive history of an “iodine allergy” (► **Table 4**, ► **Fig. 1a**). The cancellation rate of radiological examinations declined with the quality of information concerning the allergy from



5.3 % in the reference group to 2.2 % in group 2. In group 3, no examinations were cancelled.

## Adverse events

Despite a prophylactic management program, 9 patients in group 1 ultimately experienced ADRs (► **Table 5**). One ADR occurred in group 2, and none in group 3. Therefore, the uncertainty of the diagnosis associated with term “iodine allergy” is associated with an increased risk for AEs/ADRs. For safety, it is thus recommended to eliminate the term “iodine allergy” from the medical lexicon.

## Limitations of this study

One limitation of our study is its retrospective nature. Very likely, the detected number of patients with “iodine allergy” is incomplete, because the diagnosis “iodine allergy” is mentioned in variable sections of the RIS database. Moreover, due to different spelling styles (e. g. “iodine-allergy”, “iodine allergy”, “iodineallergy”, “iodine”), it is difficult or impossible to identify all patients with this diagnosis. Therefore, the current analysis was limited to 300 cases.

## Conclusion

Taken together our data show, not unexpectedly, that the term “iodine allergy” covers different medical entities. We agree with Dewachter et al. [13] who stated that “asking a patient if he/she is ‘allergic to iodine’ is a question that should be avoided because its significance is null.” To this, it can now be added that the diagnosis of “iodine allergy” is associated both with missing information about the clinical symptoms of previous adverse reactions and an increased risk for ADRs even after special prophylactic management. Therefore, to better understand a patient’s risk and to start an effective prophylactic program, an ICM-allergy work-out, the exact name of the culprit compound, and the clinical symptoms of the last ADR must be determined and possibly supplemented with the results of in vivo and in vitro allergy tests.

## Conflict of Interest

The authors declare that they have no conflict of interest.

## References

- [1] Berrington De Gonzalez A, Mahesh M, Kim KP et al. Projected cancer risks from computed tomographic scans performed in the United States in 2007. *Arch Intern Med* 2009; 169: 2071–2077
- [2] Katzberg RW. “Acute reactions to urographic contrast medium: incidence, clinical characteristics, and relationship to history of hypersensitivity states”—a commentary. *Am J Roentgenol* 2008; 190: 1431–1432
- [3] Schild HH, Kuhl CK, Hubner-Steiner U et al. Adverse events after unenhanced and monomeric and dimeric contrast-enhanced CT: a prospective randomized controlled trial. *Radiology* 2006; 240: 56–64
- [4] Katayama H, Yamaguchi K, Kozuka T et al. Adverse reactions to ionic and nonionic contrast media. A report from the Japanese Committee on the Safety of Contrast Media. *Radiology* 1990; 175: 621–628
- [5] Rawlins MTW. Mechanisms of adverse drug reactions. In: DD, (ed) *Textbook of adverse drug reaction*. New York: Oxford University Press; 1991: 18–45
- [6] Pradubpongsa P, Dhana N, Jongjarearnprasert K et al. Adverse reactions to iodinated contrast media: prevalence, risk factors and outcome—the results of a 3-year period. *Asian Pac J Allergy Immunol* 2013; 31: 299–306
- [7] Dewachter P, Mouton-Faivre C. Allergy to iodinated drugs and to foods rich in iodine: Iodine is not the allergenic determinant. *Presse Med* 2015; 44: 1136–1145 pii: S0755-4982(0715)00125-00126
- [8] Böhm I, Heverhagen JT, Klose KJ. Classification of acute and delayed contrast media-induced reactions: proposal of a three-step system. *Contrast Media Mol Imaging* 2012; 7: 537–541
- [9] Naranjo CA, Shear NH, Lanctôt KL. Advances in the diagnosis of adverse drug reactions. *J Clin Pharmacol* 1992; 32: 897–904
- [10] Brouse SD, Phillips SM. Amiodarone use in patients with documented allergy to iodine-containing compounds. *Pharmacotherapy* 2005; 25: 429–434
- [11] Westermann-Clark E, Pepper AN, Talreja N et al. Debunking myths about “allergy” to radiocontrast media in an academic institution. *Postgrad Med* 2015; 127: 295–300
- [12] Beaty AD, Lieberman PL, Slavin RG. Seafood allergy and radiocontrast media: are physicians propagating a myth? *Am J Med* 2008; 121: 158 e151–158 e154
- [13] Dewachter P, Tréchet P, Mouton-Faivre C. “Iodine allergy”: point of view. *Ann Fr Anesth Reanim* 2005; 24: 40–52
- [14] Greenfield MF. Shellfish-iodine nexus is a myth. *J Fam Pract* 2010; 59: 314
- [15] Lovenstein SBR, Dweck E. Intravenous contrast and iodine allergy myth. *Skinmed* 2014; 12: 207–208
- [16] Baig M, Farag A, Sajid J et al. Shellfish allergy and relation to iodinated contrast media: United Kingdom survey. *World J Cardiol* 2014; 6: 107–111
- [17] Lakshmanadoss U, Lindsley J, Glick D et al. Incidence of amiodarone hypersensitivity in patients with previous allergy to iodine or iodinated contrast agents. *Pharmacotherapy* 2012; 32: 618–622
- [18] Lachapelle JM. A comparison of the irritant and allergenic properties of antiseptics. *Eur J Dermatol* 2014; 24: 3–9
- [19] Gray PE, Katelaris CH, Lipson D. Recurrent anaphylaxis caused by topical povidone-iodine (Betadine). *J Paediatr Child Health* 2013; 49: 506–507
- [20] Moneret-Vautrin DA, Mata E, Gerard H et al. Probable allergy to polyvidon, responsible for a reaction to iodinated contrast medium: a case of asthma after hysterosalpingography. *Allerg Immunol (Paris)* 1989; 21: 198–199
- [21] Coakley FV, Panicek DM. Iodine allergy: an oyster without a pearl? *Am J Roentgenol* 1997; 169: 951–952
- [22] Tramer MR, von Elm E, Loubeyre P et al. Pharmacological prevention of serious anaphylactic reactions due to iodinated contrast media: systematic review. *BMJ* 2006; 333: 675
- [23] Nakamura T, Ogo T, Tsuji A et al. Successful balloon pulmonary angioplasty with gadolinium contrast media for a patient with chronic thromboembolic pulmonary hypertension and iodine allergy. *Respir Med Case Rep* 2016; 17: 75–82
- [24] Kusuyama T, Iida H, Mitsui H. Intravascular ultrasound complements the diagnostic capability of carbon dioxide digital subtraction angiography for patients with allergies to iodinated contrast medium. *Catheter Cardiovasc Interv* 2012; 80: E82–E86
- [25] Lawrence C, Cotton PB. Gadolinium as an alternative contrast agent for therapeutic ERCP in the iodine-allergic patient. *Endoscopy* 2009; 41: 564–567
- [26] Safriel Y, Ali M, Hayt M et al. Gadolinium use in spine procedures for patients with allergy to iodinated contrast—experience of 127 procedures. *AJNR Am J Neuroradiol* 2006; 27: 1194–1197
- [27] Hasdenteufel F, Luyasu S, Renaudin JM et al. Anaphylactic shock after first exposure to gadoterate meglumine: two case reports documented by positive allergy assessment. *J Allergy Clin Immunol* 2008; 121: 527–528
- [28] Abe S, Fukuda H, Tobe K et al. Protective effect against repeat adverse reactions to iodinated contrast medium: Premedication vs. changing the contrast medium. *Eur Radiol* 2016; 26: 2148–2154
- [29] Seymour CW, Pryor JP, Gupta R et al. Anaphylactoid reaction to oral contrast for computed tomography. *J Trauma* 2004; 57: 1105–1107