

Memory Effect of the Median Nerve: Can Ultrasound Reliably Depict Carpal Tunnel Release Success?

Memory Effect des Nervus medianus: Kann man ein erfolgreiches Outcome der Karpaltunnelchirurgie bildgebend darstellen?

Authors

Fabian Steinkohl¹, Leonhard Gruber¹, Hannes Gruber¹, Wolfgang Löscher², Bernhard Glodny¹, Petra Püzl³, Eva-Maria Baur³, Alexander Loizides¹

Affiliations

- 1 Department of Radiology, Medical University Innsbruck, Austria
- 2 Department of Neurology, Medical University Innsbruck, Austria
- 3 Department of Plastic and Reconstructive Surgery, Medical University Innsbruck, Austria

Key words

ultrasound, carpal tunnel syndrome, median nerve, carpal tunnel release, wrist-to-forearm ratio

received 11.5.2016

accepted 19.8.2016

Bibliography

DOI <http://dx.doi.org/10.1055/s-0042-116241>

Published online: 19.09.2016 | Fortschr Röntgenstr 2017; 189: 57–62

© Georg Thieme Verlag KG Stuttgart · New York

ISSN 1438-9029

Correspondence

Dr. Leonhard Gruber

Radiology, Medical University Innsbruck

Anichstraße 35

6020 Innsbruck

Austria

Tel.: ++43/5 12/50 48 23 07

Fax: ++43/5 12/2 27 58

leonhard.gruber@i-med.ac.at

ZUSAMMENFASSUNG

Ziel Evaluierung der postoperativen Ultraschalluntersuchung der Querschnittsfläche und Wrist-to-Forearm-Ratio des Nervus medianus zur Prognoseabschätzung nach Karpaltunnelspaltung bei Karpaltunnelsyndrom.

Material und Methoden 21 Hände von 20 Patienten mit klinisch diagnostiziertem Karpaltunnelsyndrom wurden in Bezug auf subjektive Schmerzen, Querschnittsfläche und Wrist-Forearm-Ratio des N. medianus, postoperatives Narbengewebe kurz vor der Karpaltunnelspaltung und 6 Monate danach untersucht. Gruppenunterschiede wurden mittels eines zweiseitigen ratio-paired t-Tests und one-way ANOVA, Korrelationen mittels eines linearen Regressionsmodells untersucht.

Ergebnisse Es kam zu keiner signifikanten Änderung zwischen präoperativer und postoperativer Querschnittsfläche des Nervus medianus ($p = 0,293$, 95% CI 0,826 – 1,063) oder WFR ($p = 0,230$, 95% CI 0,757 – 1,074). Die Nervenleitgeschwindigkeit besserte sich nach der Karpaltunnelspaltung signifikant ($p < 0,0001$, 95% CI 0,753 – 0,886), ebenso das subjektive Schmerzempfinden

in Ruhe ($p = 0,001$, 95% CI 1,615 – 5,797) und bei Bewegung ($p = 0,008$, 95% CI 0,760 – 4,888). Es bestand keine statistische Korrelation zwischen Änderung der Medianus-Querschnittsfläche und Nervenleitgeschwindigkeit ($p = 0,357$, $r = 0,217$, $R^2 = 0,047$) oder karpaltunneltypischer Beschwerden ($p = 0,441$, $r = 0,200$, $R^2 = 0,040$).

Schlussfolgerungen Anders als oft angegeben, kommt es nach einer erfolgreichen Karpaltunnelspaltung nicht zu einer signifikanten Reduktion der Querschnittsfläche der Nervus medianus. Ein einmal geschädigter Nervus medianus bleibt auch längere Zeit nach Behebung der Ursache der Kompression verdickt. Aufgrund dieses „Memory Effects“ ist die Annahme, dass ein postoperativ verdickter Nervus medianus mit einer erfolglosen Karpaltunnelspaltung einhergeht, nicht korrekt.

Kernaussagen

- Die CSA des Nervus medianus ändert sich nicht signifikant nach erfolgreicher Karpaltunnelchirurgie.
- Morphologische Veränderungen des N. medianus können ungeachtet des funktionellen Outcomes persistieren („Memory Effect“).
- Aus diesem Grund eignet sich die Ultraschalluntersuchung nicht, um ein erfolgreiches funktionelles Outcome nach operativer Entlastung des Nervus medianus zu beurteilen.

ABSTRACT

Purpose To evaluate whether ultrasound findings of the median nerve cross-section area (CSA) and wrist-to-forearm ratio (WFR) correlate with neurophysiological and patient-reported outcome after surgery for carpal tunnel syndrome (CTS).

Materials and Methods Subjective pain, CSA, WFR, postoperative scar tissue formation and nerve conduction velocity in 21 hands of 20 patients with clinically confirmed CTS were examined before and after carpal tunnel release surgery. Group differences were compared via a 2-sided ratio paired t-test or one-way ANOVA, and correlations were calculated using a linear regression model.

Results There were no significant pre- and postoperative changes of the CSA of the median nerve ($p = 0,293$, 95% CI 0.826 – 1.063) or WFR ($p = 0,230$, 95% CI 0.757 – 1.074). The nerve conduction velocity ($p < 0,0001$, 95% CI 0.753 – 0.886) and subjective pain during rest ($p = 0,001$, 95% CI 1.615 – 5.797) and exercise ($p = 0,008$, 95% CI 0.760 – 4.888) improved significantly, though. There was no correlation between changes in the median nerve CSA and nerve conduction velocity ($p = 0,357$, $r = 0,217$, $R^2 = 0,047$) or reported pain intensity ($p = 0,441$, $r = 0,200$, $R^2 = 0,040$).

Conclusion Contrary to common assumptions, there is no significant reduction of the CSA of the median nerve after successful carpal tunnel release. Morphologic median nerve changes may persist for a longer period regardless of successful surgery and clinical improvement. Accordingly, ultrasound appears unsuitable as the primary means of assessing surgical success due to this “memory effect”.

Key Points

- CSA of the median nerve does not change significantly after successful carpal tunnel release.
- Morphologic median nerve alterations may persist regardless of functional outcome (“memory effect”).
- Therefore, ultrasound imaging is not ideally suited to assess the outcome after carpal tunnel release.

Citation Format

- Steinkohl Fabian, Gruber Leonhard, Gruber Hannes et al. Memory Effect of the Median Nerve: Can Ultrasound Reliably Depict Carpal Tunnel Release Success?. *Fortschr Röntgenstr* 2017; 189: 57–62

Introduction

The carpal tunnel is an anatomic space of the wrist formed by the transverse carpal ligament on the volar side and the carpal bones dorsally. The median nerve and the tendons of the flexor muscles travel through this channel. Overall, this is the most frequent site of entrapment neuropathy. Carpal tunnel syndrome (CTS) accounts for over 90 % of all entrapment neuropathies [1–3]; it typically develops in individuals of 45 to 60 years of age and is more frequent in women than men. CTS is predominantly diagnosed based on its quite characteristic clinical presentation such as nocturnal tingling, numbness, or burning sensations from the 1st to the 3rd finger including the radial half of the 4th finger, as well as nerve conduction studies (NCS). The role of ultrasound (US) is focused on the differentiation between idiopathic CTS from secondary forms caused by swelling of the flexor tendons in tenosynovitis, ganglia or tumors, vascular anomalies, accessory muscle tissue or other anatomic variations. In recent years several studies have shifted focus to primary CTS with generally favorable diagnostic and prognostic results and comparable values for sensitivity and specificity to NCS [3].

It is commonly assumed that compression at the carpal tunnel expressed by flattening and proximal swelling of the median nerve is related to the symptoms of CTS, but the underlying pathophysiology is not fully understood. However, it is thought that edematous swelling due to inner flow restrictions of blood and lymph as well as axonal flow causes a progressive increase of pressure within the carpal tunnel in a vicious circle. Sustained over a longer period, these changes can cause demyelination of the nerve and irreversible function loss [4].

Features of a swollen median nerve due to CTS can be visualized by US [5]. During the last years several different methods of measurement have been developed to optimize qualification and quantification: the most common ones include measurements of the cross-sectional area (CSA) of the median nerve (► **Fig. 1**). Others

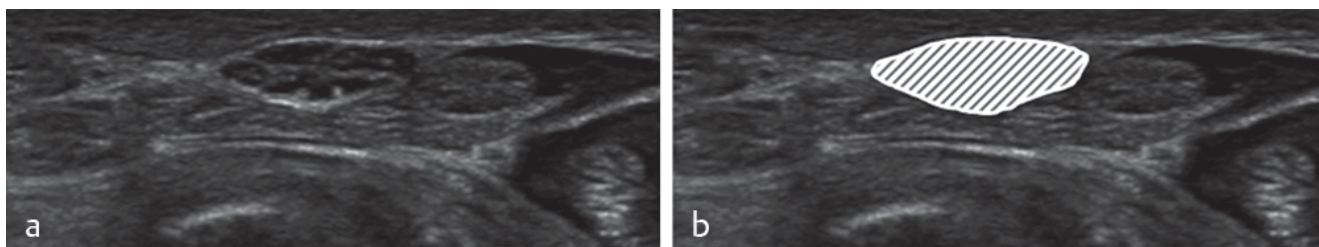
have employed CSA ratios: depending on how the measurements are performed threshold values range from 7 to 15 mm² differentiating normal from abnormal [6–9]. It has become a popular and evaluated method to calculate a ratio – the so-called wrist-to-forearm ratio (WFR) – between the greatest CSA at the carpal tunnel and at the level of the pronator quadratus muscle to exclude focal measurement bias.

Whereas the role of US in the diagnosis of CTS is clearly defined, the role of US in postoperative follow-up remains unclear. Some authors found that the CSA of the median nerve decreased markedly after a carpal tunnel release operation (CTR) and thus should be used for evidence of success. Other authors found contradictory results [10, 11].

The aim of this study was to verify whether US morphological features of the median nerve correlate with a successful CTR.

Materials and Methods

Management of personal data was in accordance with the World Medical Association Declaration of Helsinki (64th WMA General Assembly, Fortaleza, Brazil, October 2013). Institutional review board approval (Number AN4444–304/4.2 Ethikkommission, Medizinische Universität Innsbruck, 2009-02-20) was obtained. Written consent of the usage of anonymized patient data was given. For this prospective pilot study, we included 21 datasets of 20 consecutive patients suffering from idiopathic CTS: 15 female and 5 male patients. The average age at CTR was 58.7 ± 13.8 years. The included patients had been referred from the Department of Plastic Surgery with clinically and electrophysiologically diagnosed CTS. The individual pain was rated on a visual analog scale (VAS) ranging from 0–10 (0 being no pain, 10 the worst pain imaginable) for a “use” and a “rest” situation directly preoperatively and 255 (± 73.25) days postoperatively. Additionally directly before and after standard CTR (standard paramedian-ulnar approach for open median nerve decompression), NCS were per-



► **Fig. 1** a normal median nerve; b the hatched area is the cross-sectional area of the median nerve.

► **Abb. 1** a unauffälliger Nervus medianus; b die schraffierte Fläche ist die „cross sectional area“ des Nervus medianus, gemessen in cm².

formed. We measured the distal motor latency from the wrist to the abductor pollicis brevis muscle (APB). This value should not exceed 4.2 msec. Any other form or cause of CTS than idiopathic had been ruled out neurographically and sonographically.

All available pre- and postoperative sonographic studies were performed by a radiologist with more than 8 years of experience in US of the peripheral nervous system in the following manner: each patient was seated, the affected arm and hand supine on the examination table, the fingers were held extended without force. The maximum CSA of the median nerve was measured at the entry of the carpal tunnel and additionally at the level of the pronator quadratus muscle, and the WFR was calculated. The maximum CSA was measured using the freehand tracing tool on the ultrasound machine. The measurement included the epineurium. The presence of scar tissue was recorded and its extent was measured. The following data was examined: CSA (mm²) at the carpal tunnel pre-OP and about 7 months post-OP, CSA (mm²) at the level of the pronator quadratus muscle pre- and about 7 months post-OP, corresponding WFRs pre- and about 7 months post-OP, maximum sagittal thickness of the scar at the carpal tunnel.

To compare these results to normal values, a control group was established. It consisted of 13 healthy volunteers (26 wrists) and routinely scanned but unaffected wrists in 18 patients with CTS (mean age 53.2 ± 13.0 years, male:female ratio of 1.14:1), resulting in a total of 44 control wrists. In those patients the CSA of the median nerve and WFR were measured as described above.

Technical equipment and image acquisition

A Philips iU22[®] (Philips, Bothell, Washington, USA) ultrasound machine with a 17 – 5 MHz broadband linear array probe was used for all examinations. All measurements were performed using integrated caliper tools on the respective images during image hold. All acquired images were stored in the institution's Agfa[®] PACS.

Statistics

All data were collected in an Excel file (Microsoft; Redmond, WA, USA) for further statistical workup. Statistical analysis was performed in GraphPad Prism[®] (Version 6.05, GraphPad Software Inc.; CA, USA).

Data is given as mean ± SD. To compare changes between pre- and postoperative nerve conduction velocity (NCV) and pain (assessed through VAS) in patients, a 2-sided ratio paired t-test was used, as data sets were distributed in a Gaussian fashion after log₂-transformation (assessed through a D'Agostino-Pearson omnibus test for normality). Differences in WFR and CSA between

patients prior to and after surgery and controls were assessed through a one-way ANOVA with a Bonferroni correction for multiple comparisons. The same method was used to compare changes in pre- and postoperative subjective pain in patients during rest and use. Corresponding box plots were built consisting of the median, interquartile range, 95 % percentiles, outliers (o) and mean (+). The correlation between the change of NCV (Δ Latency) vs. the CSA at the carpal tunnel (Δ CSA at the carpal tunnel), WFR (Δ WFR) and individual pain as assessed with VAS (Δ VAS) as well as between changes of CSA at the carpal tunnel (Δ CSA at the carpal tunnel) and subjective pain (Δ VAS) was calculated using a linear regression model. Correlation is expressed as Pearson's correlation coefficient *r*. The weighted size of effect is given as Cohen's *d* (*d*). Goodness of fit is given as *R*². Corresponding scatter plots were built including interpolated slopes and 95 % confidence bands. A *p* < 0.05 (*) was considered to be significant.

Results

The relevant mean values and the corresponding standard deviations are given in ► **Table 1**.

There was no significant difference in age between patients who had a mean age of 59.2 ± 14.0 years (range 35.2 – 82.2 years, 28.6 % male) and controls who had a mean age of 53.2 ± 13.0 years (range 36.2 – 95.3 years) (*p* = 0.096).

Most patients reported a decrease in subjective pain, while one patient described a minor increase in pain during rest (2 to 4 VAS), but an improvement during exercise (7 to 4 VAS), and one patient reported an increase in symptoms during exercise (3 to 6 VAS), but a relief during rest (7 to 4 VAS). The rest reported stable (20 %) or improved symptoms (60 %).

The mean decrease in VAS was 3.5 ± 3.2 points during rest (*p* = 0.001, 95 % CI 1.615 – 5.797) and 2.67 ± 3.48 points during exercise (*p* = 0.008, 95 % CI 0.760 – 4.888).

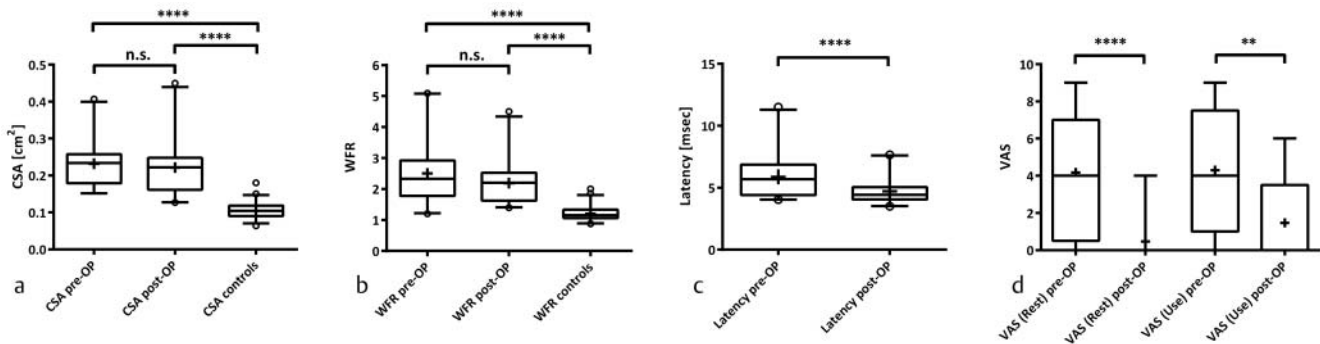
We found no significant difference between the proximal pre- and postoperative CSA over the pronator quadratus muscle in patients (10.0 ± 3.0 mm² vs. 10.4 ± 3.0 mm², *p* > 0.999) or between controls (9.0 ± 2.1 mm²) and preoperative (*p* > 0.259) or postoperative findings (*p* = 0.082) in patients.

Furthermore, no significant changes were found between the pre- and postoperative CSA at the carpal tunnel (*p* = 0.293, 95 % CI 0.826 – 1.063, *d* = -0.151) or in the WFR (*p* = 0.230, 95 % CI 0.757 – 1.074, *d* = -0.361) in patients, but highly significant findings were seen between the control CSA at the carpal tunnel (10.4 ± 2.3 mm², *p* < 0.0001 for both comparisons) and the con-

► **Table 1** Data on median nerve measurements and calculations in patients.

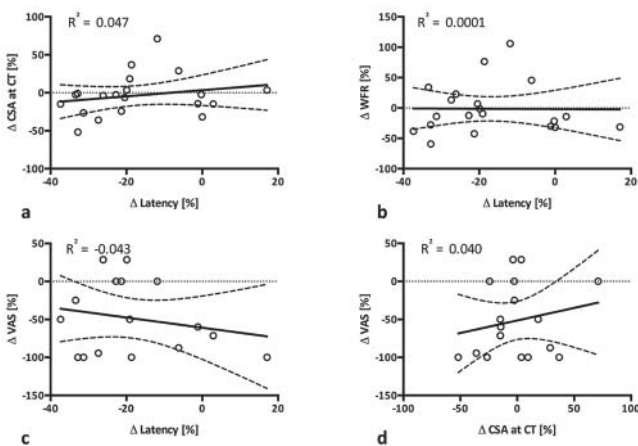
► **Tab. 1** Messergebnisse der Querschnittsflächen des N. medianus bei Patienten vor und nach Operation.

	preOP CSA CT [cm ²]	postOP CSA CT [cm ²]	preOP WFR	postOP WFR	scar dimension [mm]
mean [dimension]	0.23	0.22	2.53	2.18	2.08
standard deviation (±)	0.06	0.08	1.02	0.69	0.86



► **Fig. 2** Pre- and postoperative measurements of CSA **a**, WFR **b**, latency in NCV **c** and individual pain assessed by VAS **d**. A significant postoperative improvement could only be shown for latency and subjective pain.

► **Abb. 2** Prä- und postoperative Messungen des CSA **a**; prä- und postoperativer WFR **b**; prä- und postoperative Nervenleitgeschwindigkeit des Nervus medianus **c**; prä- und postoperativer Schmerz anhand der Visual Analogue Scale **d**. Nur für die Nervenleitgeschwindigkeit und die subjektiven Schmerzen konnte postoperativ eine signifikante Veränderung festgestellt werden.



► **Fig. 3** Correlation between changes in latency in NCV (Δ Latency) vs. CSA at the carpal tunnel (Δ CSA at CT) **a**; wrist-to-forearm ratio (Δ WFR) and latency (Δ Latency) **b**; subjective pain (Δ VAS) and latency (Δ Latency) **c**. Furthermore, the correlation between the change in individual pain (Δ VAS) and CSA at the carpal tunnel (Δ CSA at CT) is given **d**. The interpolated slope and 95% CI bands are given.

► **Abb. 3** Korrelation zwischen Veränderungen in der Nervenleitgeschwindigkeit (Δ Latency) und CSA auf Höhe des Karpaltunnels (Δ CSA at CT) **a**; Korrelation von Veränderungen in der Wrist-to-Forearm-Ratio (Δ WFR) und subjektivem Schmerz (Δ VAS) **b**; Korrelation zwischen Veränderungen in der Visual Analogue Scala (Δ VAS) und der Nervenleitgeschwindigkeit (Δ Latency) **c**; Korrelation zwischen Veränderungen in der subjektiven Schmerzempfindung (Δ VAS) und CSA im Karpaltunnel (Δ CSA at CT) **d** mit interpolierten Kurven und 95%-Konfidenzintervallbänden.

trol WFR (1.20 ± 0.23 , $p < 0.0001$ for both comparisons) (► **Fig. 1a, b, 3b, c**).

In patients there was a significant improvement in postoperative latency in NCV ($p < 0.0001$, 95% CI 0.753–0.886) however with a significant separation ($d = -0.873$). The VAS at rest ($p < 0.0001$) and during use of the hand ($p = 0.0013$) also showed

a significant improvement after surgery with a relevant size of effect ($d = -1.181$ and -1.20 , respectively) (► **Fig. 2c, d**).

There was no significant correlation between the change of NCV and the CSA at the carpal tunnel ($p = 0.357$, $r = 0.217$, $R^2 = 0.047$), the WFR ($p = 0.966$, $r = -0.010$, $R^2 = 0.0001$), and between mean changes of the preoperative and postoperative VAS ($p = 0.439$, $r = -0.208$, $R^2 = 0.043$) (► **Fig. 4a–c**). Furthermore, no significant correlation was observed between subjective pain (assessed by VAS) and the CSA at the CT ($p = 0.441$, $r = 0.200$, $R^2 = 0.040$) (► **Fig. 4d**).

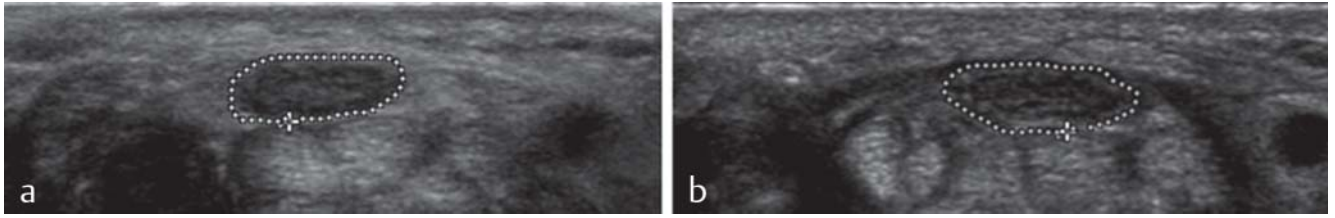
Scar presence and extent were also not correlated to the neurological outcome ($r = 0.05$, $p = 0.85$).

Discussion

CTS is the most common nerve entrapment neuropathy [1–3]. It is known that US is both a sensitive and specific method for the diagnosis of CTS [3], although it is not yet clear whether the severity of the disease can be determined by means of US [12, 13]. The confirmatory value of US after CTR is unknown. Some studies have described that postoperative US follow-up might allow prediction of the surgical outcome by measuring the postoperative CSA of the median nerve [14]. Most authors describe a decrease in the median nerve CSA following CTR, admittedly with great variation [6, 10, 15–18].

Karaby et al. found that the CSA decreased significantly within the first 6 weeks after surgery [19]. In another study Abicalaf et al. found that the CSA of the median nerve decreased within 12 weeks after endoscopic transverse carpal ligament release [16]. However, they noted that there was no correlation between clinical symptoms, ultrasound assessment and postoperative NCS. In another study by Vögelin et al. the CSA decreased slightly 12 weeks after decompression and patients with a smaller postoperative CSA had better clinical outcomes [20].

Yoshii et al. took an even more optimistic stance on the role of postoperative ultrasound after CTR. They reported that the swelling of the median nerve decreased promptly after CTR and that the surrounding structures of the median nerve also recovered.



► **Fig. 4** CSA of the median nerve in a 72-year-old male patient **a**: preoperative, CSA 0.252 cm², VAS 7, **b**: 12 months postoperative CSA 0.276 cm², VAS 0.
 ► **Abb. 4** CSA des Nervus medianus eines 72-jährigen Patienten **a** präoperativ CSA 0,252 cm², VAS 7; **b** 12 Monate postoperativ CSA 0,276 cm², VAS 0.

These findings were used to argue for the value of US-based follow-up examinations and a possible prediction of the outcome after CTR [14]. On the other hand, Lee et al. reported an increase in the CSA in postoperative median nerves [21].

Our results cannot confirm the described significant changes in the CSA after CTR [6, 10, 15–18]. We found no correlation between the preoperative severity of carpal tunnel or CTR outcome and the size of the median nerve, regardless of whether we used the median nerve's CSA proximal to the CT or calculated the WFR. We did not even detect a correlation between the median nerve size and patient symptoms. These findings confirm older results which could not find an association between a reduction of the CSA of the median nerve and clinical improvement [18].

Our findings show that the nerve remains enlarged regardless of CTR success – according to patient symptoms and electrodiagnostic studies, methods of assessment for neural function rather than morphology. US-based follow-up was performed 6 months after CTR, as it is suspected that the CSA of the median nerve changes by inner neural remodeling during the first six postoperative months [20]. We thereby tried to perform measurements after the interval usually considered necessary for restitution of postoperative swelling. Nevertheless, our data shows that a damaged nerve remains enlarged for at least 6 months, even if its function has already been restored. Thus we proposed the term “memory effect”.

Based on our data, the assumption that a postoperatively enlarged median nerve is a sign of an unsuccessful CTR is incorrect. However, ultrasound is useful to rule out postoperative complications such as hematoma formation or infection.

There are some limitations to report: Even though examiners were advised not to question the patients about their symptoms, blinding to the diagnosis and state of disease is difficult in a hands-on US examination. This may be alleviated by the fact that all measurements except for VAS were based on clearly defined imaging or neurophysiological criteria. Patients rated their VAS independently from the US examiners. Furthermore, small changes in CSA and WFR might have been missed due to the limited number of cases. Selection bias should be minimal due to consecutive patient inclusion. Theoretically, persistent swelling of the median nerve may be linked to the surgical technique used – open CTR in this case – and other approaches such as endoscopic CTR may lead to a different morphological outcome. Nonetheless, as func-

tional outcome was favorable in most patients in our study, we do not suspect the choice of technique to have a detrimental effect.

Conclusion

In this study we did not find any evidence to substantiate a decrease in the median nerve CSA as a sign of a successful CTR, while both NCS and subjective patient symptoms demonstrated a clear improvement. The median nerve CSA and the WFR remained virtually unchanged compared to their preoperative state.

We therefore propose that there is a “memory effect”, i. e., a persistence of morphological changes of the median nerve even in the face of (partially) restored function through inner remodeling.

Nonetheless, US should be used in the primary assessment of CTS and for ruling out postoperative complications, such as scar formation, infection and incomplete ligament incision.

References

- [1] Latinovic R, Gulliford MC, Hughes RA. Incidence of common compressive neuropathies in primary care. *Journal of neurology, neurosurgery, and psychiatry* 2006; 77: 263–265
- [2] Aboonq MS. Pathophysiology of carpal tunnel syndrome. *Neurosciences* 2015; 20: 4–9
- [3] Wong SM, Griffith JF, Hui AC et al. Discriminatory sonographic criteria for the diagnosis of carpal tunnel syndrome. *Arthritis and rheumatism* 2002; 46: 1914–1921
- [4] Sugimoto H, Miyaji N, Ohsawa T. Carpal tunnel syndrome: evaluation of median nerve circulation with dynamic contrast-enhanced MR imaging. *Radiology* 1994; 190: 459–466
- [5] Buchberger W, Schon G, Strasser K et al. High-resolution ultrasonography of the carpal tunnel. *Journal of ultrasound in medicine: official journal of the American Institute of Ultrasound in Medicine* 1991; 10: 531–537
- [6] Hammer HB, Hovden IA, Haavardsholm EA et al. Ultrasonography shows increased cross-sectional area of the median nerve in patients with arthritis and carpal tunnel syndrome. *Rheumatology* 2006; 45: 584–588
- [7] Walker FO, Cartwright MS, Wiesler ER et al. Ultrasound of nerve and muscle. *Clinical neurophysiology: official journal of the International Federation of Clinical Neurophysiology* 2004; 115: 495–507
- [8] Werner RA, Jacobson JA, Jamadar DA. Influence of body mass index on median nerve function, carpal canal pressure, and cross-sectional area of the median nerve. *Muscle & nerve* 2004; 30: 481–485
- [9] Beekman R, Visser LH. Sonography in the diagnosis of carpal tunnel syndrome: a critical review of the literature. *Muscle & nerve* 2003; 27: 26–33

- [10] Smidt MH, Visser LH. Carpal tunnel syndrome: clinical and sonographic follow-up after surgery. *Muscle & nerve* 2008; 38: 987–991
- [11] Campagna R, Pessis E, Feydy A et al. MRI assessment of recurrent carpal tunnel syndrome after open surgical release of the median nerve. *American journal of roentgenology* 2009; 193: 644–650
- [12] Mhoon JT, Juel VC, Hobson-Webb LD. Median nerve ultrasound as a screening tool in carpal tunnel syndrome: correlation of cross-sectional area measures with electrodiagnostic abnormality. *Muscle & nerve* 2012; 46: 871–878
- [13] Peer S, Gruber H, Loizides A. Sonography of carpal tunnel syndrome: why, when and how. *Imaging in Medicine* 2012; 4: 287–297
- [14] Yoshii Y, Ishii T, Tung WL. Ultrasound assessment of the effectiveness of carpal tunnel release on median nerve deformation. *Journal of orthopaedic research: official publication of the Orthopaedic Research Society* 2015; 33: 726–730
- [15] Mondelli M, Filippou G, Aretini A et al. Ultrasonography before and after surgery in carpal tunnel syndrome and relationship with clinical and electrophysiological findings. A new outcome predictor?. *Scandinavian journal of rheumatology* 2008; 37: 219–224
- [16] Abicalaf CA, de Barros N, Sernik RA et al. Ultrasound evaluation of patients with carpal tunnel syndrome before and after endoscopic release of the transverse carpal ligament. *Clinical radiology* 2007; 62: 891–894; discussion 895–896
- [17] Colak A, Kutlay M, Pekkaflali Z et al. Use of sonography in carpal tunnel syndrome surgery. A prospective study. *Neurologia medico-chirurgica* 2007; 47: 109–115; discussion 115
- [18] Naranjo A, Ojeda S, Rua-Figueroa I et al. Limited value of ultrasound assessment in patients with poor outcome after carpal tunnel release surgery. *Scandinavian journal of rheumatology* 2010; 39: 409–412
- [19] Karabay N, Kayalar M, Ada S. Sonographic assessment of transverse carpal ligament after open surgical release of the carpal tunnel. *Acta orthopaedica et traumatologica turcica* 2013; 47: 73–78
- [20] Vogelien E, Nuesch E, Juni P et al. Sonographic follow-up of patients with carpal tunnel syndrome undergoing surgical or nonsurgical treatment: prospective cohort study. *The Journal of hand surgery* 2010; 35: 1401–1409
- [21] Lee CH, Kim TK, Yoon ES et al. Postoperative morphologic analysis of carpal tunnel syndrome using high-resolution ultrasonography. *Annals of plastic surgery* 2005; 54: 143–146