

Selective Venous Blood Sampling for Hyperparathyroidism with unclear Localization of the Parathyroid Gland

Selektives Venenblutsampling bei Hyperparathyreoidismus mit unklarer Nebenschilddrüsenlokalisierung

Authors

C. Hader¹, M. Uder¹, R. W. R. Loose², U. Linnemann³, T. Bertsch⁴, R. Adamus²

Affiliations

¹ Institute of Radiology, Friedrich-Alexander-University Erlangen-Nuremberg, University Hospital, Erlangen, Germany

² Institute for Diagnostic and Interventional Radiology, Hospital Nuremberg North, Nuremberg, Germany

³ Department for General, Visceral and Thoracic Surgery, Hospital Nuremberg, Germany

⁴ Institute of Clinical Chemistry, Laboratory Medicine and Transfusion Medicine – Central Laboratory, Hospital Nuremberg, Germany

Key words

- parathyroid
- angiography
- hyperparathyroidism
- selective venous sampling

Abstract



Purpose: Evaluation of the benefit of selective venous blood sampling (SVS) for the pre-operative identification of parathyroid adenomas with unclear localization in non-invasive diagnostics.

Materials and Methods: In a retrospective study, all patients (n=23) with primary (n=21) or tertiary (n=2) hyperparathyroidism were evaluated from 2005 to 2016 at the Hospital Nuremberg-North. These patients all received one (n=20) or more (n=3) SVS. 15 patients had one or more previous unsuccessful surgeries (group A), 8 patients received the SVS primarily before the first surgery (group B). Results of SVS were compared with the results of surgery, non-invasive diagnostic procedures and clinical follow up.

Results: In 24 out of 26 SVS a significant PTH peak was found. 19 patients underwent surgery after SVS. In 16 of these cases (84%) the SVS peak was concordant with the intraoperative localization. Thus, SVS of all operated patients had a sensitivity of 94%. Considering only patients with prior HPT surgery the sensitivity was 89%. In none of the 26 examinations complications occurred.

Conclusion: Our results demonstrate that selective venous blood sampling SVS in cases with unclear imaging of parathyroid adenomas is an effective and low-risk invasive diagnostic method to localize parathyroid adenomas and helps to improve surgical therapy.

Key points:

- ▶ low risk invasive diagnostic procedure to localize parathyroid adenomas
- ▶ additional step if non-invasive diagnostics are negative or inconclusive
- ▶ high sensitivity in the detection of parathyroid adenomas

Citation Format:

- ▶ Hader C, Uder M, Loose RWR et al. Selective Venous Blood Sampling for Hyperparathyroidism with unclear Localization of the Parathyroid Gland. Fortschr Röntgenstr 2016; 188: 1144–1150

Zusammenfassung



Ziel: Bewertung des Nutzens des selektiven Venenblutsamplings (SVS) zur präoperativen Identifikation von Nebenschilddrüsenadenomen bei unklarer Lokalisation in der nichtinvasiven Diagnostik.

Material und Methoden: In einer retrospektiven Studie wurden alle Patienten (n=23) mit primärem (n=21) oder tertiärem (n=2) Hyperparathyreoidismus (HPT) untersucht, die im Zeitraum von 2005 bis 2016 am Klinikum Nürnberg-Nord eine (n=20) oder mehrere (n=3) SVS erhalten haben. 15 Patienten waren bereits ein- oder mehrmals erfolglos operiert worden (Gruppe A), 8 erhielten die SVS primär vor der Erstoperation (Gruppe B). Die Resultate der SVS wurden anhand der Operationsergebnisse, der histologischen Befunde sowie des klinischen Verlaufs evaluiert.

Ergebnisse: 24 der 26 durchgeführten SVS zeigten einen signifikanten PTH-Peak. 19 Patienten wurden nach Durchführung der SVS operiert. Davon war die SVS in 16 Fällen (84%) konkordant zur intraoperativen Lokalisation. Somit hatte die SVS für alle operierten Patienten eine Sensitivität von 94%, bezüglich der Patienten mit HPT-Voroperation allein ergab sich eine Sensitivität von 89%. Bei keiner der 26 Untersuchungen traten Komplikationen auf.

Schlussfolgerung: Unsere Ergebnisse zeigen, dass die SVS bei unklarer nichtinvasiver Bildgebung von Nebenschilddrüsenadenomen ein effektives und risikoarmes invasives diagnostisches Verfah-

received 12.1.2016

accepted 4.7.2016

Bibliography

DOI <http://dx.doi.org/>

10.1055/s-0042-113613

Published online: 19.9.2016

Fortschr Röntgenstr 2016; 188:

1144–1150 © Georg Thieme

Verlag KG Stuttgart · New York ·

ISSN 1438-9029

Correspondence

Christopher Hader

Institute of Radiology, Friedrich-

Alexander-University Erlangen-

Nuremberg, University Hospital

Maximiliansplatz 1

91054 Erlangen

Germany

Tel.: ++49/91 31/8 53 60 65

Christopher_Hader@gmx.de

ren darstellt, um Nebenschilddrüsenadenome zu lokalisieren und so den Erfolg der chirurgischen Therapie des HPT zu verbessern.

Introduction

▼
Hyperthyroidism (HPT) is characterized by an increased production of parathyroid hormone (PTH) by the parathyroid glands. The excess secretion can be caused autonomously (primary or tertiary HPT) or can be regulatory in nature (secondary HPT). With an incidence of 1:1000 to 4:1000, primary HPT is the most common cause of hypercalcemia in the outpatient setting. Twice as many females are affected compared to males [1]. Typical manifestations include generalized bone disease, kidney stones and nephrocalcinosis, gastrointestinal, cardiovascular, neuromuscular and neuropsychiatric symptoms. However, according to frequent screening of laboratory results, up to 80% of patients appear asymptomatic [1]. In 85% of cases, a solitary adenoma is the cause; in 1–15% of cases hyperplasia affects several or all parathyroid glands [2]. The only curative therapy is parathyroidectomy [3]. Although bilateral neck exploration (BNE) is the traditional surgical method and gold standard, due to improved localization diagnostics in recent decades, various minimally-invasive procedures (MIP) have been established. The success rates are similar, >95%; correspondingly the reoperation rate is approx. 5% [4–6]. The role of general preoperative localization diagnostics has been controversially discussed to date [7]. Thus in the case of primary BNE, preoperative localization diagnostics is not mandatory; however, it is obligatory when performing a minimally-invasive parathyroidectomy, in cases of reintervention as well as in cases of suspected ectopic adenomas [7]. The established non-invasive imaging procedures primarily include ultrasound (US) and Tc-99m Sestamibi scintigraphy (Tc99m MIBI SZ). In addition, magnetic resonance imaging (MRI) as well as computed tomography (CT) are used in selected cases. However there are always situations in which non-invasive diagnostics provide no result or contradictory results. This is particularly problematic for patients with previous surgery, since reoperation is accompanied by an increased complication rate and a decreased success rate compared to primary operations [6]. Adequate preoperative localization diagnostics are therefore strongly encouraged in order to allow the surgeon a targeted surgical procedure [8]. In these cases, selective venous sampling (SVS) represents a minimally-invasive diagnostic method that can be indicative when localizing adenomas of the parathyroid glands; however this technique is falling into disuse.

The aim of our study was to investigate the benefit of SVS for patients with indistinct localization of adenomas of the parathyroid glands during non-invasive imaging prior to primary surgery or reoperation and thus assess the value of SVS when localizing parathyroid gland adenomas.

Materials and Methods

▼
A retrospective analysis included all patients of the Nürnberg-Nord Clinic (n=23) who during the period 2005–2016 underwent one (n=21) or more (n=3) selective venous sampling procedures. The mean age was 60 years (26–76 years);

61% of the patients were female and 39% were male. Of the 23 patients, 21 had primary HPT (91%) and 2 had tertiary HPT (9%). The diagnoses were verified chemically in the laboratory. Fifteen patients with persistent or recurrent HPT received SVS prior to reoperation (Group A). Persistence means that raised serum calcium values are measurable within the first 6 months postoperatively. Recurrence is indicated when serum calcium increases again after 6 months of normal postoperative calcemia. Eight patients received SVS for primary diagnosis prior to the first intervention (Group B). Four members of this group had already undergone thyroid surgery. All patients first underwent non-invasive localization diagnostics, initially always a Tc99m Mibi SZ (n=23) and/or an ultrasound (n=17), supplemented by an MRI (n=8) or a CT (n=10) (► Fig. 1). Indication for SVS was supported by at least two non-invasive diagnostic procedures due to missing or ambiguous localization of the parathyroid glands.

The SVS was positive if a significant PTH peak could be shown. This had to lie by a factor of 1.5 above a reference value peripherally obtained during the SVS [9]. The sampling site with the highest peak was then considered the probably location of the hyperactive parathyroid gland. A peak below the confluence of the two brachiocephalic veins indicated an entopic location of the parathyroid gland in the mediastinum.

An operation was considered successful if, in addition to morphological assessment, the PTH value during intraoperative monitoring dropped by 50% of the initial value approx. 10 minutes after removal of the gland.

Intraoperative localization with a corresponding drop in PTH during monitoring, in combination with final histological confirmation was considered the gold standard for verification of the SVS. Correspondingly the results of the SVS were evaluated as follows: True-positive, if a significant PTH peak existed, the anatomical location provided by SVS coincided with the intraoperative location and the diagnosis was histologically confirmed. True-negative, if there was no significant PTH peak, and no mass could be located during the operation. False-positive, if there was a significant PTH peak, but no adenoma could be found during the operation at the relevant location. False-negative, if a mass could be found during the operation, yet no suitably significant PTH peaks could be shown by SVS. The data used for the study were obtained from radiological findings, physician reports, laboratory and histological findings.

SVS Technique

▼
Access is via puncture of the right femoral vein using the Seldinger method and placement of a 5-F sheath. Depending on vessel anatomy, the following catheter configurations can be used: 4-F Cobra (Cordis®, C1, Tempo Aqua), vertebral (MeritMedical®) or straight configuration (Terumo®). The selective catheter is then navigated using a probing wire (Terumo®, Angled 3 cm, normal or stiff) and sectional view of the venous system using contrast fluoroscopy from cranial to caudal for the following sampling positions: internal jugular vein, both sides, each in the upper, middle and lower third of the thyroid gland, subclavian vein, both sides; right brachiocephalic vein; left lateral and medial brachio-

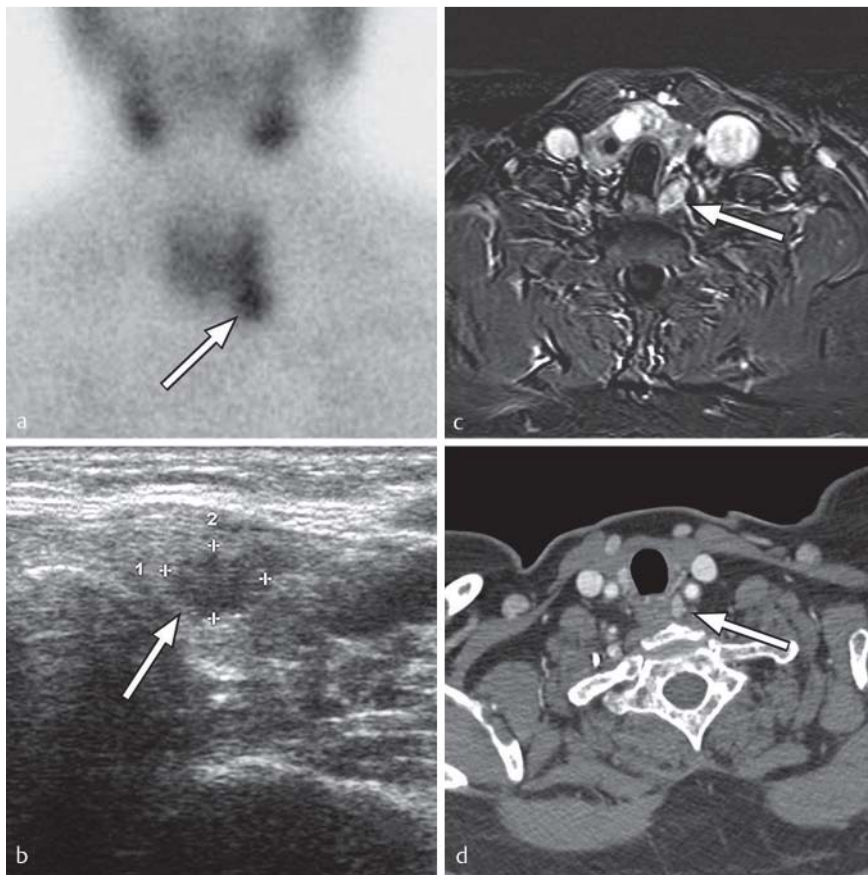


Fig. 1 Positive findings of parathyroid adenomas (arrows) in **a** Scintigraphy, **b** Ultrasound, **c** MRI, **d** CT.

cephalic vein; or in the region of the confluence of the inferior thyroid vein; superior vena cava; azygos vein, right atrium; inferior vena cava; renal vein, both sides. DSA series are needed only in exceptional cases, when the vessel anatomy is complex or if venous valves are difficult to pass through (● Fig. 2).

After each change of position 2 ml of blood are aspirated and discarded in order to ensure absolute separation of PTH values from the various sampling positions. This is followed by a second aspiration of 3 ml blood with a fresh syringe; the blood is sterilely injected into an EDTA tube. Immediately after filling, the tube is labeled and the blood sample is cooled. The individual hormone values are carried over to an anatomical diagram according to PTH determination, allowing association with a location (● Fig. 3). This supports the distinction between location on the left or right side of the neck at various levels and location in the mediastinum. It should be noted that due to the distance between the individual sampling locations and the retrograde blood flow, the location of the target may lie somewhat peripherally to the sampling site. Rare complications include smaller hematomas which may result from perforation of a vein by the guide wire or during an attempt to pass through a venous valve. Furthermore, there are known risks associated with contrast administration (renal insufficiency, thyrotoxic crisis, anaphylactic reaction).

Results



A significant PTH peak could be determined in 24 of the 26 SVS procedures (92%). No complications resulted from any of the 26 procedures. On average, 16 ± 3 samples were taken per examination.

Due to various reasons, 4 of the 23 patients could not undergo an operation (other comorbidities, refusal, etc.). After the SVS was performed, 19 patients were operated on, including 11 from Group A (with previous HPT surgery) and 8 from Group B (no previous HPT surgery). Based on intraoperative localization with a corresponding drop in PTH, in combination with final histological confirmation as the gold standard, the results of SVS could be verified as follows: true-positive 84% (16/19); true-negative 0% (0/19), false-positive 11% (2/19), false-negative 5% (1/19) (● Table 2). On the whole SVS had a positive predictive value (operated patients from Groups A+B) of 89% with a sensitivity of 94%. Considering the group of patients with prior HPT surgery alone, the positive predictive value was 80% with a sensitivity of 89% (● Table 3).

For the sake of completeness, the results of the non-invasive diagnosis of operated patients have been included. The criterion for the accuracy of the results of each method was analogous to the assessment of SVS: the indicated location in reference to the above-defined gold standard. Following are only the true-positive results: Tc99m Mibi SZ 16% (3/19), US 20% (3/15), CT 25% (2/8), MRI 38% (3/8). Targeted surgery was performed wherever a PTH peak was located.

If there was a lateral peak, surgery was performed on one side (9/19); mediastinal surgery (4/19) was performed if a peak

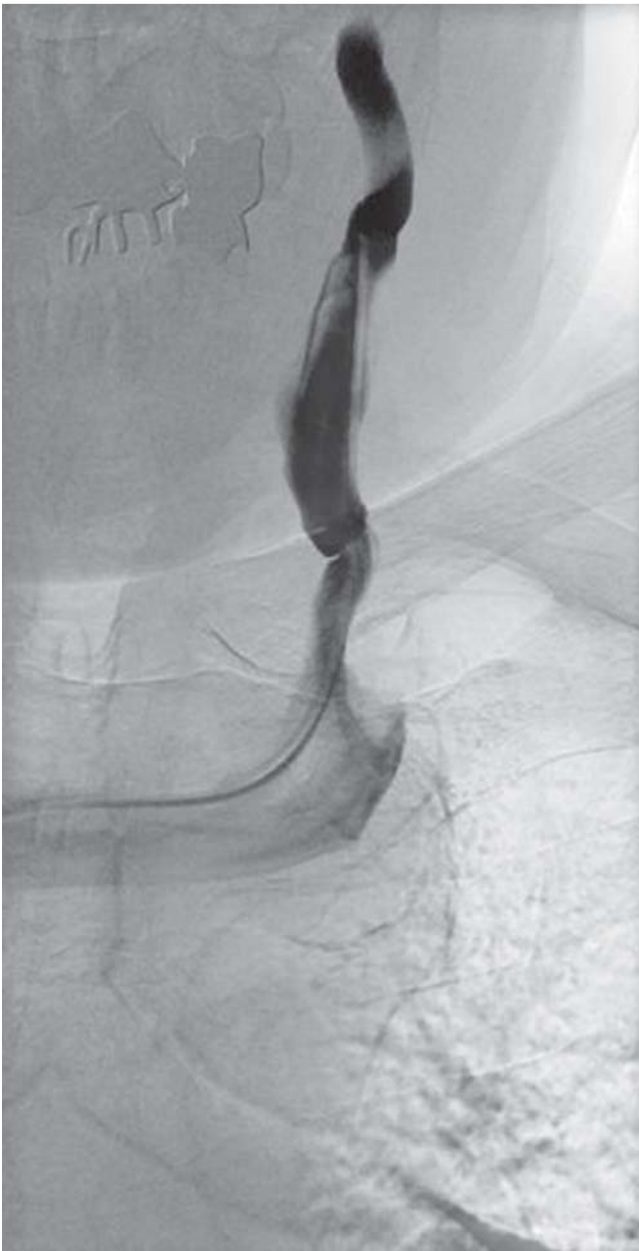

Fig. 2 DSA-image during blood sampling with catheter in left internal jugular vein.

was below the confluence of both brachiocephalic veins. Bilateral exploration was only performed if there was a significant bilateral peak (1/18) or there was a peak in the region of the inferior thyroid vein (3/19). In the latter case, however, only the caudal parathyroid gland was explored. Further exploration occurred if no adenoma could be found after an initial targeted procedure (2/19). In total, 18 of the 19 patients (95%) could be successfully operated on. The following histological results were observed: solitary adenoma (13/18), 2 adenomas (1/18), one or more hyperplasias (3/18), hyperplasia and adenoma (1/18).

• **Table 1** presents the results of SVS and surgery for all patients, with indication of the PTH peak, systemic preoperative PTH and PTH value approx. 10 minutes after excision of the parathyroid adenoma. As expected, the 2 patients with

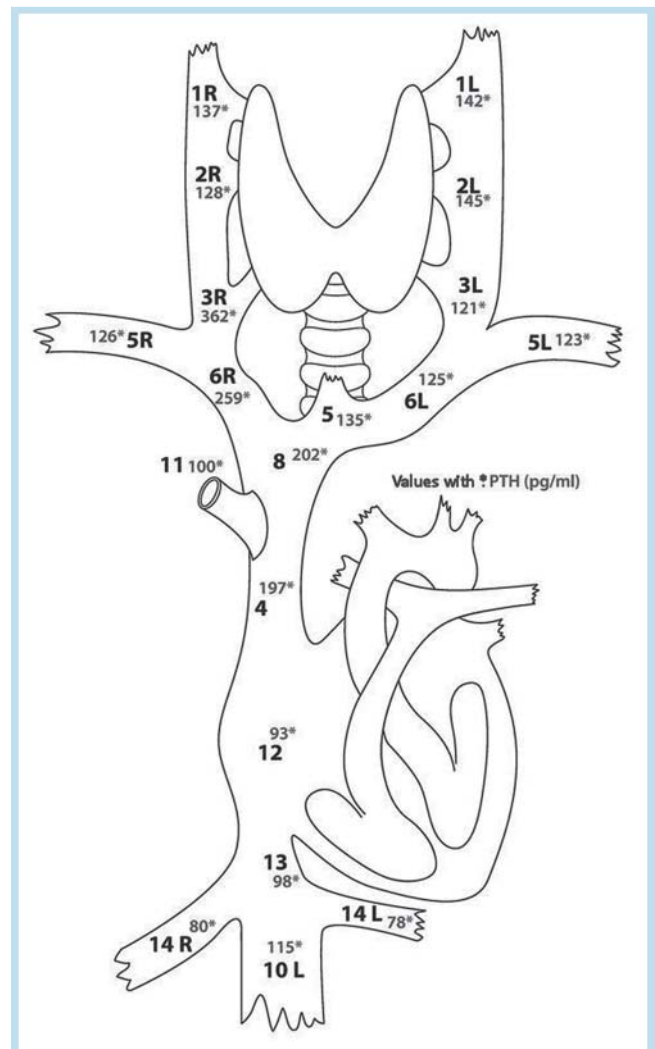


Fig. 3 Anatomic scheme of SVS in a 70 year old patient. A significant PTH peak was found in the lower part of the right internal jugular vein and an adenoma at this site was confirmed by surgery.

tertiary HPT (tHPT) exhibited a higher systemic PTH level compared to the patients with primary HPT (pHPT).

Discussion

The aim of the study was to investigate the benefit of SVS among patients with indistinct parathyroid glands location using non-invasive diagnosis. Of the SVS procedures performed, 92% exhibited a significant PTH peak; in 84% of the operated patients SVS was consistent with the location discovered surgically. Sensitivity of all operated patients was 94%. A sensitivity of 89% was demonstrated for the cohort of patients who had been previously treated surgically with persistent/recurrent HPT.

Several procedures are available to localize parathyroid adenomas; they vary with respect to their value, invasiveness and cost. Ultrasound represents the most widely available and cost-effective examination method but is heavily dependent on the experience of the examiner, the size and position of the parathyroid gland. Depending on the publi-

Table 1 Results of SVS, PTH values and surgical outcome of all patients. Two PTH peak values indicate double SVS.

patient	SVS correct	PTH peak in SVS [pg/ml]	PTH systemic preoperative [pg/ml]	PTH intraoperative approx. 10 min post-excision [pg/ml]	surgery concordant	prior surgery, result of operation
1.	+	1146	134	34	+	thyroid surgery, successful operation
2.	+	278	67	19	+	thyroid OP, successful operation
3.	– +	97 ¹ 1298	84	14	+	pHPT OP, successful reoperation
4.		286			0	pHPT OP, no OP in follow-up
5.	+	350	119	34	+	pHPT OP, successful reoperation
6.	+	648	113	20	+	thyroid OP, successful OP
7.		144			0	pHPT OP, no OP in follow-up
8.	–	866 ¹	900	98	+	tHPT OP, successful reoperation
9.	+	729	147	25	+	pHPT OP, successful reoperation
10.	+	362	169	26	+	thyroid OP, successful OP
11.	+	317	83	44	+	pHPT OP, successful reoperation
12.	– –	982 563			–	multiple pHPT OP unsuccessful
13.	+	399			0	pHPT OP, no OP in follow-up
14.	+	1533	1000	26	+	tHPT OP, successful reoperation
15.	+	282	157	32	+	pHPT OP, successful reoperation
16.		322			0	pHPT OP, no OP in follow-up
17.	– –	197 414	193	34	+	pHPT OP, successful reoperation
18.	+	601	140	24	+	pHPT OP, successful reoperation
19.	+	397	124	48	+	successful OP
20.	+	389	116	49	+	successful OP
21.	+	797	89	17	+	successful OP
22.	+	255	93	18	+	pHPT OP, successful reoperation
23.		240	93	15	+	successful OP

¹ non-significant PTH peaks.**Table 2** Fourfold table of all operated patients.

All operated patients			
	OP +	OP –	
SVS +	16 (84%)	2 (11%)	18
SVS –	1 (5%)	0 (0%)	1
	17	2	19

Table 3 Fourfold table of patients with unsuccessful prior surgery.

Reoperation			
	OP +	OP –	
SVS +	8 (70%)	2 (10%)	10
SVS –	1 (20%)	0 (0%)	1
	9	2	11

cation, the sensitivity of US in detecting a pathological parathyroid gland lies between 70–90% [10]. Among patients with persistent or recurrent HPT, sensitivity is reduced to 36–63% [11]. False-positive diagnoses are often the result of the difficulty in differentiating between parathyroid glands and thyroid nodes, lymph nodes, prominent blood vessels or muscles. False-negative results can be caused by tiny adenomas or ectopic position in sonographically inaccessible (e.g. mediastinal) areas [12]. An additional frequently employed examination method is 99mTc-Sestamibi

scintigraphy. In addition to planar images, using either dual phase or subtraction in combination with a second radionuclide such as Iodine-123, there is also the possibility of 3-dimensional imaging using SPECT (single photon emission computed tomography). Sensitivity of 99mTc-Mibi SZ lies between 54–96%; most studies average around 80% [13]. Analogous to US, thyroid nodes or lymph nodes as well as brown adipose tissue can result in false-positive results; very small adenomas can lead to false-negative diagnoses [14]. Imaging methods such as CT and MRI have a secondary utility in locating pathological parathyroid glands. These methods are primarily used in cases of unclear findings resulting from the above-mentioned established procedures, but with limited success. Compared to SZ and US, computed tomography has a lower sensitivity with values ranging between 40–70% [13]. A new promising development is 4D CT (four-dimensional computed tomography) which, in addition to spatial representation, changes in contrast absorption and release behavior of the parathyroid gland are recorded over time, and thus parathyroid adenomas can be detected based on their characteristic blood flow behavior [13]. Four-dimensional CT has shown good results, but is still in clinical trials and is currently available at only a few centers. Sensitivity of MRI is comparable to that of CT, 43–71% [13]. In both methods (CT + MRI), analogous to US, thyroid nodes or lymph nodes can likewise result in false-positive results; very small adenomas can lead to false-negative diagnoses. The low number of positive findings of non-invasive procedures in our studies, particularly

related to Tc99m-Mibi SZ and US, can be explained by our highly-selective patient cohort, thus requiring the use of SVS, and should not be considered representative for the respective method.

In 16 of 19 cases in our cohort, SVS concurred with intraoperative localization. True-positive results were found in 3 of 4 ectopic parathyroid glands. In the case of the fourth patient with a false-negative SVS, a mediastinal PTH peak was present, which subsequently concurred with intraoperative localization. However, the peak was not significant and was not considered true-positive for the study. In practice, however such results are also included in the decision regarding where to surgically explore. A PTH peak is never interpreted in isolation, but in the context of other PTH values on the anatomical drawing, the non-invasive diagnosis and the patient's history and may provide a clue without particular significance in itself.

The 3 cases with false-positive or false-negative results should be discussed, since a PTH peak does not rule out the presence of an adenoma in the face of absent intraoperative discoverability. On the other hand altered venous drainage resulting from prior surgery can negatively affect interpretation of the SVS. Thus, in a study by Reidel et al., 7 of 8 patients with incorrect SVS results had already had surgery on the thyroid. Other authors see no correlation between prior cervical surgery and non-concurrent SVS results [15–17]. In our cohort, 15 of the 19 patients undergoing surgery had already experienced surgery on the parathyroid gland (11) or the thyroid (4). In 12 of 15 cases with prior surgery, SVS concurred with intraoperative localization. Therefore we cannot likewise confirm a general trend. In individual cases a correlation between prior surgery and incorrect SVS cannot be ruled out with certainty. Thus one patient with a false-positive SVS had prior surgery on both the thyroid and parathyroid glands. After a negative non-invasive diagnosis and two SVS procedures, the adenoma was discovered on the opposite side of where the SVS indicated. This could be explained by altered venous drainage.

Most published studies are devoted exclusively to preoperative diagnosis of persistent/recurrent HPT. Specifically, sensitivities of 91%, 78%, and 83% were achieved [15, 17, 18]. A study by Eloy et al. investigated the primary diagnostic benefit of SVS, reporting a sensitivity of 87% [19]. Compared to other publications, our results are at the same level, confirming the utility of SVS. SVS is certainly not the method for primary diagnosis of parathyroid gland adenomas. Initially, incremental diagnosis should use SZ and/or US, which in most instances is sufficient. If these methods produce contradictory or no results, further diagnosis should be pursued related to the initial situation and desired surgical method. Especially with respect to patients with persistent/recurrent HPT, accurate localization diagnostics are mandatory before reoperation, since due to anatomical changes and scarring of neck soft tissue, difficult operation conditions should be expected [20]. This applies analogously to other previous cervical surgeries. Thus the complication rate for recurrent laryngeal nerve paresis during reoperation is between 4–15%; for hypoparathyroidism with consecutive hypocalcemia the rate is 10–20%, whereas primary intervention shows a complication rate of only 1.45–3.40% [6]. The procedure used (CT, MRI or SVS) depends on availability and expertise of the relevant clinic, in addition to individual preferences, and must be

selected on an individual basis. There is no uniform consensus in the literature, nor is there a guideline. Our experience shows that CT and MRI, as further diagnostic measures, currently offer a limited benefit. This is confirmed by other authors [13, 21]. Therefore in complicated cases, preference should be for SVS. This is an invasive examination method requiring expertise and which involves a risk of complication – however limited. However, SVS can provide the decisive indication for localization of the parathyroid gland in complex cases. A limitation of our study is certainly the low number of patients which reduced the statistical value of our results. However, it is comparable with the number of cases of other studies as well as the limitation to uncertain, non-invasive localization diagnostics and unsuccessful prior surgeries in the context of a seldom-indicated type of examination. In the Nuremberg Clinic, surgery is performed annually on approx. 50 parathyroid glands, but in the 11-year time frame under study, 26 SVS procedures were performed.

This study confirms that SVS continues to be a useful diagnostic method for localizing parathyroid adenomas, and provides an opportunity for successful surgical therapy of HPT in selected cases.

Clinical Relevance of the Study

- ▶ The results of the study demonstrate the high sensitivity of selective venous blood sampling in the localization of a parathyroid hormone peak, and therefore the probable position of a parathyroid adenoma.
- ▶ The procedure is particularly appropriate if the non-invasive diagnosis is negative or ambiguous.
- ▶ Localization of a parathyroid hormone peak can support a second intervention when prior surgery has been unsuccessful, thereby reducing the surgical risk while increasing the chances of success.

Acknowledgements

▼ We thank Günther Bollmann for helping us with the data acquisition, Fabian Klöpfer for the illustrations and Dr. Manuel Schmidt for critical reading. This article was elaborated in fulfillment of the requirements of a medical doctoral thesis.

References

- 1 Pallan S, Rahman MO, Khan AA. Diagnosis and management of primary hyperparathyroidism. *BMJ* 2012; DOI: 10.1136/bmj.e1013
- 2 Gasser RW. Clinical aspects of primary hyperparathyroidism: clinical manifestations, diagnosis, and therapy. *Med Wochenschr* 2013; 163: 397–402. DOI: 10.1007/s10354-013-0235-z
- 3 Suliburk JW, Perrier ND. Primary Hyperparathyroidism. *The Oncologist* 2007; 12: 644–653. DOI: 10.1634/theoncologist.12-6-644
- 4 Karakas E, Schneider R, Rothmund M et al. Initial Surgery for Benign Primary Hyperparathyroidism: An Analysis of 1300 Patients in a Teaching Hospital. *World J Surg* 2014; 38: 2011–2018. DOI: 10.1007/s00268-014-2520-4
- 5 Udelsman R. Six hundred fifty-six consecutive explorations for primary hyperparathyroidism. *Ann Surg* 2002; 235: 665–670
- 6 Kuo LE, Wachtel H, Fraker D et al. Reoperative parathyroidectomy: who is at risk and what is the risk? *J Surg Res* 2014; 191: 256–261. DOI: 10.1016/j.jss.2014.05.073
- 7 Siewert JR, Rothmund M, Schumpelick V. (eds). *Endokrine Chirurgie*. Heidelberg: Springer; 2013: 266

- 8 Karakas E, Müller HH, Schlosshauer T et al. Reoperations for primary hyperparathyroidism – improvement of outcome over two decades. *Langenbecks Arch Surg* 2013; 398: 99–106. DOI: 10.1007/s00423-012-1004-y
- 9 Mauro MA, Murphy KPJ, Thomson KR et al. (eds). *Image-Guided Interventions*. Philadelphia: Saunders Elsevier; 2014: 814
- 10 Huppert BJ, Reading CC. Parathyroid sonography: imaging and intervention. *J Clin Ultrasound* 2007; 35: 144–155
- 11 Mohebbati A, Shaha AR. Imaging techniques in parathyroid surgery for primary hyperparathyroidism. *Am J Otolaryngol* 2012; 33: 457–468. DOI: 10.1016/j.amjoto.2011.10.010
- 12 Solbiati L, Osti V, Cova L et al. Ultrasound of thyroid, parathyroid glands and neck lymph nodes. *Eur Radiol* 2001; 11: 2411–2424. DOI: 10.1007/s00330-001-1163-76718936
- 13 Kunstman JW, Kirsch JD, Mahajan A et al. Clinical review: Parathyroid localization and implications for clinical management. *J Clin Endocrinol Metab* 2013; 98: 902–912. DOI: 10.1210/jc.2012-3168
- 14 Mihai R, Simon D, Hellmann P. Imaging for primary hyperparathyroidism – an evidence-based analysis. *Langenbecks Arch Surg* 2009; 394: 765–784. DOI: 10.1007/s00423-009-0534-4
- 15 Reidel MA, Schilling T, Graf S et al. Localization of hyperfunctioning parathyroid glands by selective venous sampling in reoperation for primary or secondary hyperparathyroidism. *Surgery* 2006; 140: 907–913. DOI: 10.1016/j.surg.2006.06.037
- 16 Jones JJ, Brunaud L, Dowd CF et al. Accuracy of selective venous sampling for intact parathyroid hormone in difficult patients with recurrent or persistent hyperparathyroidism. *Surgery* 2002; 132: 944–950. DOI: 10.1067/msy.2002.128477
- 17 Liew V, Gough IR, Nolan G et al. Re-operation for hyperparathyroidism. *ANZ J Surg* 2004; 74: 732–740. DOI: 10.1111/j.1445-1433.2004.03142.x
- 18 Hessman O, Stalberg P, Sundin A et al. High success rate of parathyroid reoperation may be achieved with improved localization diagnosis. *World J Surg* 2008; 32: 774–781. DOI: 10.1007/s00268-008-9537-5
- 19 Eloy JA, Mitty H, Genden EM. Preoperative selective venous sampling for nonlocalizing parathyroid adenomas. *Thyroid* 2006; 16: 787–790. DOI: 10.1089/thy.2006.16.787
- 20 Nawrot I, Chudzinski W, Ciałka T et al. Reoperations for persistent or recurrent primary hyperparathyroidism: results of a retrospective cohort study at a tertiary referral center. *Med Sci Monit* 2014; 20: 1604–1612. DOI: 10.12659/MSM.890983
- 21 Rodgers SE, Lew JJ, Solórzano CC. Primary hyperparathyroidism. *Curr Opin Oncol* 2008; 20: 52–58. DOI: 10.1097/CCO.0b013e3282f2838f