

Factors associated with incomplete gastric endoscopic submucosal dissection due to misdiagnosis

Authors

Haruhisa Suzuki, Ichiro Oda, Masau Sekiguchi, Seiichiro Abe, Satoru Nonaka, Shigetaka Yoshinaga, Yutaka Saito

Institution

Endoscopy Division, National Cancer Center Hospital, Tokyo, Japan

submitted

27. December 2015

accepted after revision

25. April 2016

Bibliography

DOI <http://dx.doi.org/10.1055/s-0042-108191>

Published online: 29.6.2016

Endoscopy International Open

2016; 04: E788–E793

© Georg Thieme Verlag KG

Stuttgart · New York

E-ISSN 2196-9736

Corresponding author

Haruhisa Suzuki, MD

Endoscopy Division

National Cancer Center Hospital

5-1-1 Tsukiji, Chuo-ku, Tokyo

104-0045

Japan

Phone: +81-3-3542-2511

Phone: +81-3-3542-7794

Fax: +81-3-3542-3815

harusuzu@ncc.go.jp

Background and study aims: Endoscopic submucosal dissection (ESD) is widely accepted for treating early gastric cancer (EGC); however, there can be cases of incomplete resection due to not only technical problems, but also misdiagnosis. Our aim was to identify factors associated with incomplete gastric ESD due to misdiagnosis.

Patients and methods: A total of 2,268 patients with solitary EGCs at initial onset underwent ESD with curative intent at our hospital from 1999 to 2008. We retrospectively assessed the clinicopathological factors by comparing the two groups of incomplete ESD cases due to misdiagnosis (cases with a positive lateral margins [LM] [Group A] or those with a positive vertical margins [VM] [Group B]) with complete ESD cases using multivariable analysis.

Results: Complete ESD was achieved in 2,097 patients. The 171 patients with incomplete ESDs

were divided into 109 with a positive LM and 80 with a positive VM (overlapped). Except 49 cases with a positive LM due to technical problems, a positive LM due to misdiagnosis was identified in 60 cases (Group A). Excluding 32 cases with a positive VM due to technical problems, a positive VM due to misdiagnosis was found in 48 cases (Group B). Significant independent factors (odds ratios [OR]; 95% confidence intervals [CI]) for each group were as follows: Group A: size >20 mm (5.4; 3.0–9.9), undifferentiated-type (4.1; 1.8–9.0), submucosal invasion (2.0; 1.1–3.4) and location of upper/middle (1.9; 1.0–3.6); Group B: size >20 mm (3.0; 1.6–5.5), undifferentiated-type (3.0; 1.1–8.0) and location of upper/middle (2.4; 1.2–4.8).

Conclusions: Endoscopists must be aware of these factors associated with incomplete gastric ESD due to misdiagnosis to further decrease their incidence.

Introduction

Endoscopic submucosal dissection (ESD) is widely used in Japan as an initial treatment for early gastric cancer (EGC) with a negligible risk of lymph node (LN) metastasis, even for cases that involve large and ulcerative lesions [1–3]. The therapeutic outcomes of gastric ESD are excellent; however, some cases of incomplete resection still occur because of not only technical problems, but also misdiagnosis [4–10]. From the perspective of ESD procedural techniques, the resectability of gastric ESD has improved with the technical stabilization of gastric ESD [11]. In contrast, although several reports have roughly estimated the factors associated with incomplete gastric ESD on the basis of univariate or subgroup analyses, only a few have thoroughly evaluated the various factors associated with incomplete gastric ESD due to misdiagnosis using multivariable analysis [4, 10, 12–15]. In particular, no published reports have demonstrated these factors using multivariable analysis by

dividing incomplete gastric ESD cases into positive for either lateral margins (LM) or vertical margins (VM) [3, 16]. Therefore, we attempted to identify these factors in accordance with the actual clinical setting.

Patients and methods

Patients

After excluding patients with synchronous EGCs, patients with metachronous EGCs, EGCs in the remnant stomach, and EGCs in the gastric tube, a total of 2,268 patients with solitary EGC lesions at initial onset underwent ESD with curative intent at our hospital from 1999 to 2008 [1–3]. Before treatment, an upper endoscopy with indigo carmine dye was performed to evaluate the tumor margins and depth of invasion [17]. Biopsies were obtained from the lesion in all cases. At the endoscopist's discretion, biopsies were also obtained outside the lesion to confirm the lateral

License terms



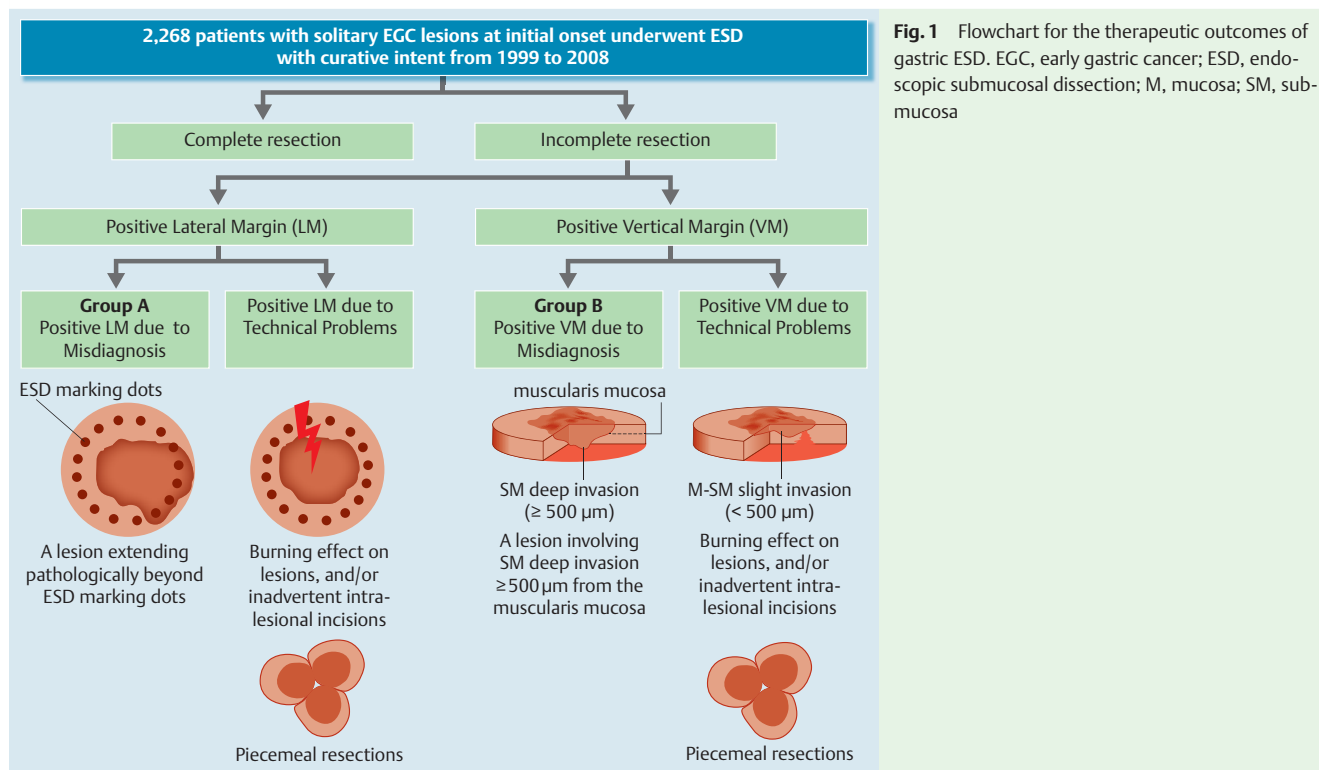


Fig. 1 Flowchart for the therapeutic outcomes of gastric ESD. EGC, early gastric cancer; ESD, endoscopic submucosal dissection; M, mucosa; SM, submucosa

margins. As for the narrow band imaging (NBI) and magnification endoscopy (ME), our hospital had minimal experience with such endoscopic modalities for the diagnosis of lateral extent of EGC lesions between 1999 and 2008, because this period was prior to the clinical application of NBI and ME for gastric lesions [18]. In addition, endoscopic ultrasonography (EUS) was performed if deemed necessary, particularly for lesions that were strongly suspected of having submucosal invasion [19].

A flowchart for the therapeutic outcomes of gastric ESD is shown in **Fig. 1**. An en-bloc resection was defined as a one-piece resection and a complete (R0) resection was defined as an en-bloc resection with tumor-free LM and VM irrespective of curability [3, 16]. A resection that did not satisfy any of these criteria was considered an incomplete resection. Incomplete resection cases were divided into those with positive LM and those with positive VM. An inconclusive resection margin was regarded as a positive resection margin.

From both the perspective of endoscopic diagnosis and ESD procedural techniques, cases with a positive LM were subdivided into cases with a positive LM due to misdiagnosis (Group A) and cases with a positive LM due to technical problems. Positive LM due to misdiagnosis was defined as an incomplete ESD with a positive LM because EGC lesion was extended pathologically beyond the ESD marking dots. Positive LM due to technical problems was defined as an incomplete ESD with a positive LM because of a burning effect on lesions, inadvertent intralesional incisions, and/or piecemeal resections. Furthermore, cases with a positive VM were subdivided into cases with a positive VM due to misdiagnosis (Group B) and cases with a positive VM due to technical problems. Positive VM due to misdiagnosis was defined as an incomplete ESD with a positive VM because EGC lesions involved a submucosa (SM) deep layer (SM2 layer of $\geq 500\mu\text{m}$ from the muscularis mucosae) [3,16]. Positive VM due to technical problems was defined as an incomplete ESD performed for EGC lesions confined to the mucosa (M) or the SM1 layer ($< 500\mu\text{m}$

from the muscularis mucosae), with a positive VM because of a burning effect on lesions, inadvertent intralesional incisions, and/or piecemeal resections.

The risks and benefits of ESD were thoroughly explained to each patient and written informed consent was obtained from them in accordance with our institutional protocols prior to treatment.

Assessments of factors associated with incomplete ESD

To determine the factors associated with an incomplete gastric ESD due to misdiagnosis, we retrospectively assessed the following clinicopathological factors by comparing the two groups of incomplete ESD cases due to misdiagnosis (cases with a positive LM [Group A] or those with a positive VM [Group B]) with complete ESD cases: age, gender, lesion location (upper/middle vs lower third of the stomach), macroscopic type (elevated type vs flat/depressed type), tumor size ($\leq 20\text{mm}$ vs $> 20\text{mm}$), depth of invasion (M vs SM), presence/absence of ulceration and major histological type (differentiated-type vs undifferentiated-type). Macroscopic lesions were divided into elevated (0-I, 0-IIa, 0-I+IIa, 0-I+IIb, 0-I+IIc, 0-IIa+IIb, 0-IIa+IIc) or flat/depressed types (0-IIb, 0-IIc, 0-IIc+I, 0-IIc+III) on the basis of their major macroscopic features. The definitions for the characteristics of EGC lesions, such as lesion location, macroscopic type, tumor size, depth of invasion, presence of ulcerations, and histologic type, were based on Japanese classification of gastric carcinoma and Japanese gastric cancer treatment guidelines [3, 16].

The cut-off value of a tumor size of 20mm was determined using the receiver operating characteristic (ROC) curve for the risk of a positive LM because of misdiagnosis (**Fig. 2**). The area-under-the-curve (AUC) value for the risk of a positive LM because of misdiagnosis was 0.77. The sensitivity and specificity for risk of a positive LM because of misdiagnosis using a threshold tumor size of 20mm were 76.7% and 61.2%, respectively. In addition, the cut-off value of a tumor size of 20mm was determined using the ROC curve for the risk of a positive VM because of misdiagno-

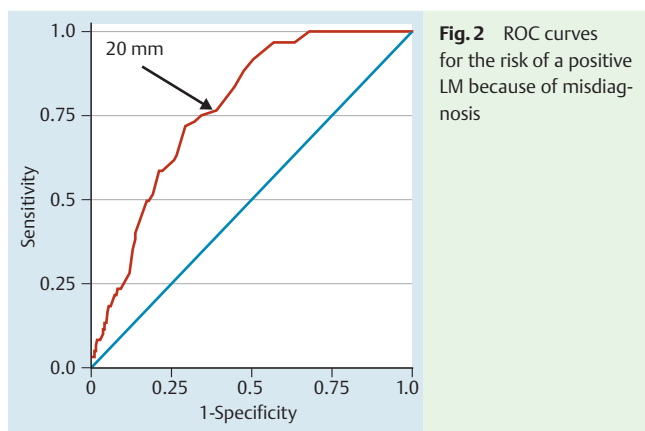


Fig. 2 ROC curves for the risk of a positive LM because of misdiagnosis

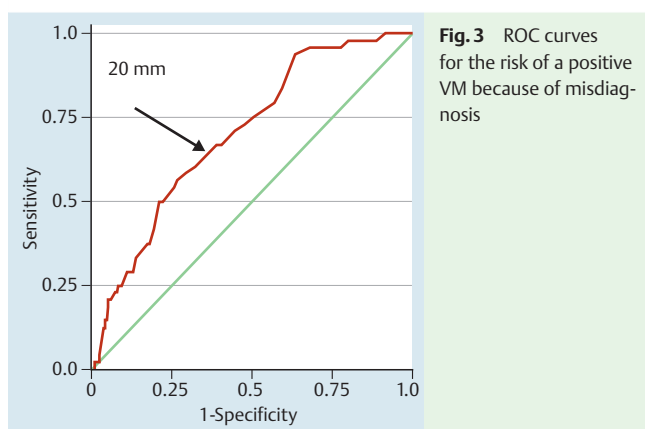


Fig. 3 ROC curves for the risk of a positive VM because of misdiagnosis

sis (● Fig. 3). The AUC value for risk of a positive VM because of misdiagnosis was 0.70. The sensitivity and specificity for risk of a positive VM because of misdiagnosis using a threshold tumor size of 20 mm were 66.7% and 61.2%, respectively.

Statistical analysis

The Fisher exact test or chi-square test was used for univariate analysis. We then performed a multivariable binary logistic regression analysis (backward, stepwise) for factors with *P* values of less than 0.2 in the univariate analyses to identify factors that were independently associated with incomplete resection. All the statistical analyses were performed using the statistical analysis software SPSS, version 20 (SPSS Japan Inc., Tokyo, Japan). A *P* value <0.05 was considered statistically significant.

Results

Complete resection was achieved in 2,097 cases (92.5%). In 171 cases (7.5%), resection was incomplete, of which a positive LM was found in 109 cases (4.8% of all cases) and a positive VM in 80 cases (3.5%), including both positive LM and VM in 18. From both the perspective of endoscopic diagnosis and ESD procedural techniques, 109 cases with a positive LM were subdivided into 60 cases (2.6%) with a positive LM due to misdiagnosis (Group A) and 49 cases (2.2%) with a positive LM due to technical problems. Furthermore, 80 cases with a positive VM were subdivided into 48 cases (2.1%) with a positive VM due to misdiagnosis (Group B) and 32 cases (1.4%) with a positive VM due to technical problems.

In the 60 cases with a positive LM due to misdiagnosis (Group A), lesion location of upper/middle, tumor size >20 mm, SM invasion, and undifferentiated-type were factors that were significantly associated with a positive LM based on univariate analyses (● Table 1). Using multivariable analysis, tumor size >20 mm (OR=5.4; 95% CI: 3.0–9.9; *P*<0.0001), undifferentiated-type (OR=4.1; 95% CI: 1.8–9.0; *P*=0.001), SM invasion (OR=2.0; 95% CI: 1.1–3.4; *P*=0.015), and lesion location of upper/middle (OR=1.9; 95% CI: 1.0–3.6; *P*=0.048) were significantly associated with a positive LM due to a misdiagnosis.

For the 48 cases with a positive VM due to the misdiagnosis (Group B), lesion location of upper/middle and tumor size >20 mm were factors that were significantly associated with a positive VM due to a misdiagnosis based on univariate analyses (● Table 2). Based on multivariable analysis, tumor size >20 mm (OR=3.0; 95% CI: 1.6–5.5; *P*<0.0001), undifferentiated-type (OR=3.0; 95% CI: 1.1–8.0; *P*=0.028) and lesion location of upper/middle (OR=2.4; 95% CI: 1.2–4.8; *P*=0.018) were significantly associated with a positive VM due to a misdiagnosis.

Discussion

This is the first report to identify factors associated with incomplete ESD for EGC using multivariable analysis by dividing incomplete ESD cases into positive for LM or positive for VM from the perspective of endoscopic diagnosis. ESD for EGC is performed with excellent complete resection rates ranging from 80.4% to 97.8%; however, there still are cases of incomplete resection [4–10]. Only a few published reports have thoroughly evaluated the various factors associated with incomplete gastric ESD due to a misdiagnosis using multivariable analysis [4, 10, 12–15]. Kakushima N. et al. reported that tumor diameter, recurrent-type cancer, submucosal cancer, and undifferentiated-type cancer were identified by multivariate analysis as factors that were significantly associated with incomplete resection with a positive LM due to misdiagnosis [12]. From the perspective of a positive LM due to a misdiagnosis, their results were nearly comparable to our results. Both reports identified undifferentiated-type cancer as a significant independent factor. Accurate evaluation of the lateral extent of a tumor is more challenging with undifferentiated-type cancer [17, 18, 20, 21]. Abe S. et al. and Okada K. et al. reported that complete resection rates for patients with undifferentiated EGC undergoing ESD were 90.7% and 95.1%, respectively [17, 20]. In addition, Hanaoka N. et al. evaluated the pathological findings of SM-invasive EGC and then reported that tumor size and width of submucosal invasion were greatest in undifferentiated-type-predominant mixed type and differed significantly from the respective values in differentiated type tumors [21]. Therefore, we must acknowledge the distinct possibility that before ESD, inaccurate evaluations of the lateral extent of undifferentiated-type EGCs occur even more frequently.

However, the report by Kakushima N. et al. only focused on incomplete resection with a positive LM due to misdiagnosis and EGC lesions outside of ESD indications (such as recurrent-type cancer), and clinically diagnosed SM invasive cancer also were included. Takenaka R. et al., using multivariate analysis, reported that tumors >3 cm in diameter, tumors located in the upper and middle third of the stomach, and the presence of ulcers were significantly associated with incomplete resection [10]. In their report, only differentiated-type EGC lesions were eligible for these evaluations and clinically diagnosed undifferentiated-type

Table 1 Factors associated with incomplete ESD with a positive LM due to a misdiagnosis (Group A).

Clinicopathological feature	Univariate analysis		Odds ratio (95% CI), P value	Multivariable analysis, odds ratio (95% CI), P value
	Positive LM due to misdiagnosis (n = 60)	Complete resection (n = 2097)		
Age				
> 65	30 (50%)	1194 (56.9%)	1.3 (0.8 – 2.2), 0.28	–
≤ 65	30 (50%)	903 (43.1%)		
Gender				
Male	47 (78.3%)	1624 (77.4%)	1.1 (0.6 – 1.9), 0.87	–
Female	13 (21.7%)	473 (22.6%)		
Location				
Upper/middle	47 (78.3%)	1221 (58.2%)	2.6 (1.4 – 4.8), 0.002	1.9 (1.0 – 3.6), 0.048
Lower	13 (21.7%)	876 (41.8%)		
Macroscopic type				
Elevated	22 (36.7%)	824 (39.3%)	1.1 (0.7 – 1.9), 0.68	–
Flat/depressed	38 (63.3%)	1273 (60.7%)		
Size (mm)				
≤ 20	15 (25%)	1379 (65.8%)	5.8 (3.2 – 10.3), <0.0001	5.4 (3.0 – 9.9), <0.0001
> 20	45 (75%)	718 (34.2%)		
Depth				
Mucosa	36 (60%)	1709 (81.5%)	2.9 (1.7 – 5.0), <0.0001	2.0 (1.1 – 3.4), 0.015
Submucosa	24 (40%)	388 (18.5%)		
Ulceration				
Present	15 (25%)	374 (17.8%)	1.5 (0.9 – 2.8), 0.15	1.2 (0.7 – 2.3), 0.52
Absent	45 (75%)	1723 (82.2%)		
Histological type				
Differentiated	51 (85%)	2001 (95.4%)	3.7 (1.8 – 7.6), 0.0002	4.1 (1.8 – 9.0), 0.001
Undifferentiated	9 (15%)	96 (4.6%)		

ESD, endoscopic submucosal dissection; LM, lateral margin

mucosal cancers <2cm and without ulceration were not included. In addition, Asada-Hirayama I. et al. reported factors that were predictive of inaccurate determinations of the lateral extent of differentiated-type EGCs during ESD irrespective of the LM positivity of ESD specimens [13]. Based on multivariate analysis, they found that the presence of a flat component, large size, and predominant histologic findings of moderately-differentiated adenocarcinoma were significant independent factors that contributed to an inaccurate endoscopic evaluation of lateral tumor extent. Their report investigated the misdiagnosis of the lateral extent of EGC lesions during ESD in detail, although it only focused on differentiated-type EGCs that fulfilled the indications for ESD. More recently, Numata N. et al. reported that a tumor location in the upper third of the stomach and a lesion not meeting the absolute indication were identified as risk factors for a positive LM in EGC resected by en bloc ESD, although this report focused on not only incomplete gastric ESD because of misdiagnosis, but also incomplete gastric ESD because of technical problems [15].

There have been no previous reports on factors associated with a positive VM due to a misdiagnosis. Our results showed that tumor size >20mm, undifferentiated-type cancer, and lesion in upper/middle third were significant independent factors associated with a positive VM due to a misdiagnosis. These findings are nearly the same as those in previous reports regarding incorrect endoscopic diagnoses for EGC invasion depth [19,22].

According to Japanese gastric cancer treatment guidelines, for cases of incomplete ESD for differentiated-type adenocarcinoma with positive VM or undifferentiated-type adenocarcinoma with positive LM or VM, the standard treatment is gastrectomy with

LN dissection, even if these are the only non-curative factors [3]. In contrast, these guidelines describe that nonsurgical management (close observation or immediate additional endoscopic treatment) can be performed instead of gastrectomy for patients with differentiated-type adenocarcinoma for whom the only non-curative factor is a cancer-positive LM [3,23]. Under these circumstances, more careful attention is needed to avoid incomplete ESD for differentiated-type adenocarcinoma with positive VM and those for undifferentiated-type adenocarcinoma with positive LM or VM because surgical resections would be necessitated. Therefore, the results of the current study are significant because they identify both factors associated with incomplete ESD with positive LM and those with positive VM from the perspective of endoscopic diagnosis based on the data for both histologic types of EGCs that fulfill the indications for ESD.

Our study had a few limitations. First, we did not directly determine the factors associated with a misdiagnosis of the lateral and vertical extent of EGC lesions. Asada-Hirayama I. et al. reported that LM will be negative even if the lesion size is underestimated and the tumor extends beyond the marking dots [13]. Similarly, the cases with complete resections in our study included EGC lesions with inaccurate endoscopic evaluations of demarcation or invasion depth. Thus, to determine those factors associated with a misdiagnosis of the lateral or vertical extent of EGC lesions, a study that only focuses on the diagnosis of the lateral or vertical extent of EGC lesions irrespective of cut end margin positivity of ESD specimens will be necessary. Second, we evaluated incomplete gastric ESD due to misdiagnosis mainly using by conventional endoscopy so we did not assess whether use of several endoscopic modalities, such as NBI, ME, and EUS, decreased the

Table 2 Factors associated with incomplete ESD with a positive VM due to a misdiagnosis (Group B).

Clinicopathological feature	Univariate analysis		Odds ratio (95% CI), P value	Multivariable analysis, odds ratio (95% CI), P value
	Positive VM due to misdiagnosis (n = 48)	Complete resection (n = 2097)		
Age				
>65	33 (68.8%)	1194 (56.9%)	1.7 (0.9–3.1), 0.10	1.7 (0.9–3.1), 0.11
≤65	15 (31.2%)	903 (43.1%)		
Gender				
Male	37 (77.1%)	1624 (77.4%)	1.0 (0.5–2.0), 0.95	–
Female	11 (22.9%)	473 (22.6%)		
Location				
Upper/middle	38 (79.2%)	1221 (58.2%)	2.7 (1.4–5.4), 0.004	2.4 (1.2–4.8), 0.018
Lower	10 (20.8%)	876 (41.8%)		
Macroscopic type				
Elevated	19 (39.6%)	824 (39.3%)	1.0 (0.6–1.8), 0.97	–
Flat/depressed	29 (60.4%)	1273 (60.7%)		
Size (mm)				
≤20	18 (37.5%)	1379 (65.8%)	3.2 (1.8–5.7), <0.0001	3.0 (1.6–5.5), <0.0001
>20	30 (62.5%)	718 (34.2%)		
Ulceration				
Present	10 (20.8%)	374 (17.8%)	1.2 (0.6–2.4), 0.59	–
Absent	38 (79.2%)	1723 (82.2%)		
Histological type				
Differentiated	43 (89.6%)	2001 (95.4%)	2.4 (1.0–6.1), 0.07	3.0 (1.1–8.0), 0.028
Undifferentiated	5 (10.4%)	96 (4.6%)		

ESD, endoscopic submucosal dissection; VM, vertical margin

incidence of incomplete resection with a positive LM or VM because of misdiagnosis. To reduce the incidence of incomplete ESD because of misdiagnosis, further improvement in endoscopic diagnostic modalities is necessary. Third, in some cases, it was difficult to divide incomplete ESD cases into 2 groups consisting of technical problems and misdiagnosis because the 2 causes of incomplete resection partially overlapped, although these 2 causes were defined as mentioned above in this study. Fourth, multivariable analysis used in this study (multivariable analysis for factors with *P* values less than 0.2 in the univariate analyses) may lead to exclusion of variables that are important to include in order to avoid residual confounding and to inclusion of variables that generate over-adjustment bias or collider stratification bias. However, the OR from multivariable analysis for all factors (data not shown) are almost the same as that from multivariable analysis used in this study, so we considered that bias for selection of variables would be minimized. Finally, the results of the current study were based on a retrospective assessment conducted at a single center, although the data were based on a large consecutive series of gastric ESDs. Thus, a prospective multicenter study is required for a more precise evaluation of these factors. Several multicenter prospective studies on gastric ESD are currently under way [24–26].

In conclusion, further advances in endoscopic diagnosis are needed to improve the rate of incomplete gastric ESD due to misdiagnosis because there still are cases with a positive LM or VM due to several factors associated with misdiagnosis. Furthermore, endoscopists must be aware of the factors associated with incomplete gastric ESD due to misdiagnosis to further decrease their incidence.

Competing interests: None

References

- 1 Gotoda T, Yanagisawa A, Sasako M et al. Incidence of lymph node metastasis from early gastric cancer: estimation with a large number of cases at two large centers. *Gastric Cancer* 2000; 3: 219–225
- 2 Hirasawa T, Gotoda T, Miyata S et al. Incidence of lymph node metastasis and the feasibility of endoscopic resection for undifferentiated-type early gastric cancer. *Gastric Cancer* 2009; 3: 148–152
- 3 Japanese Gastric Cancer Association. Japanese gastric cancer treatment guidelines 2010 (ver. 3). *Gastric Cancer* 2011; 14: 113–123
- 4 Oda I, Gotoda T, Hamanaka H et al. Endoscopic submucosal dissection for early gastric cancer: technical feasibility, operation time and complications from a large consecutive series. *Dig Endosc* 2005; 17: 54–58
- 5 Chung IK, Lee JH, Lee SH et al. Therapeutic outcomes in 1000 cases of endoscopic submucosal dissection for early gastric neoplasms: Korean ESD Study Group multicenter study. *Gastrointest Endosc* 2009; 69: 1228–1235
- 6 Akasaka T, Nishida T, Tsutsui S et al. Short-term outcomes of endoscopic submucosal dissection (ESD) for early gastric neoplasm: multicenter survey by Osaka University ESD study group. *Dig. Endosc* 2011; 23: 73–77
- 7 Ahn JY, Jung HY, Choi KD et al. Endoscopic and oncologic outcomes after endoscopic resection for early gastric cancer: 1370 cases of absolute and extended indications. *Gastrointest. Endosc* 2011; 74: 485–493
- 8 Shin KY, Jeon SW, Cho KB et al. Clinical outcomes of the endoscopic submucosal dissection of early gastric cancer are comparable between absolute and new expanded criteria. *Gut Liver* 2014; 9: 181–187
- 9 Nakamura K, Honda K, Akahoshi K et al. Suitability of the expanded indication criteria for the treatment of early gastric cancer by endoscopic submucosal dissection: Japanese multicenter large-scale retrospective analysis of short- and long-term outcomes. *Scand J Gastroenterol* 2015; 50: 413–422
- 10 Takenaka R, Kawahara Y, Okada H et al. Risk factors associated with local recurrence of early gastric cancers after endoscopic submucosal dissection. *Gastrointest Endosc* 2008; 68: 887–894
- 11 Suzuki H, Oda I, Sekiguchi M et al. Process of technical stabilization of gastric endoscopic submucosal dissection at the National Cancer Center in Japan. *Turk J Gastroenterol* 2014; 25: 619–623
- 12 Kakushima N, Ono H, Tanaka M et al. Factors related to lateral margin positivity for cancer in gastric specimens of endoscopic submucosal dissection. *Dig Endosc* 2011; 23: 227–32

- 13 Asada-Hirayama I, Kodashima S, Goto O et al. Factors predictive of inaccurate determination of horizontal extent of intestinal-type early gastric cancers during endoscopic submucosal dissection: A retrospective analysis. *Dig Endosc* 2013; 25: 593–600
- 14 Kim TK, Kim GH, Park DY et al. Risk factors for local recurrence in patients with positive lateral resection margins after endoscopic submucosal dissection for early gastric cancer. *Surg Endosc* 2015; 29: 2891–2898
- 15 Numata N, Oka S, Tanaka S et al. Risk factors and management of positive horizontal margin in early gastric cancer resected by en bloc endoscopic submucosal dissection. *Gastric Cancer* 2015; 18: 332–338
- 16 Japanese Gastric Cancer Association. Japanese classification of gastric carcinoma: 3rd English edition. *Gastric Cancer* 2011; 14: 101–112
- 17 Abe S, Oda I, Suzuki H et al. Short- and long-term outcomes of endoscopic submucosal dissection for undifferentiated early gastric cancer. *Endoscopy* 2013; 45: 703–707
- 18 Nagahama T, Yao K, Maki S et al. Usefulness of magnifying endoscopy with narrow-band imaging for determining the horizontal extent of early gastric cancer when there is an unclear margin by chromoendoscopy (with video). *Gastrointest Endosc* 2011; 74: 1259–1267
- 19 Yanai H, Matsumoto Y, Harada T et al. Endoscopic ultrasonography and endoscopy for staging depth of invasion in early gastric cancer: a pilot study. *Gastrointest Endosc* 1997; 46: 212–216
- 20 Okada K, Fujisaki J, Yoshida T et al. Long-term outcomes of endoscopic submucosal dissection for undifferentiated-type early gastric cancer. *Endoscopy* 2012; 44: 122–127
- 21 Hanaoka N, Tanabe S, Mikami T et al. Mixed-histologic-type submucosal invasive gastric cancer as a risk factor for lymph node metastasis: feasibility of endoscopic submucosal dissection. *Endoscopy* 2009; 41: 427–432
- 22 Yin J, Oda I, Suzuki H et al. Endoscopic diagnosis of gastric cancer invasion depth. *Nippon Shokakibyo Gakkai Zasshi* (abstract in English) 2009; 106: 1603–1609
- 23 Sekiguchi M, Suzuki H, Oda I et al. Risk of recurrent gastric cancer after endoscopic resection with a positive lateral margin. *Endoscopy* 2014; 46: 273–278
- 24 Oda I, Shimazu T, Ono H et al. Design of Japanese multicenter prospective cohort study of endoscopic resection for early gastric cancer using Web registry (J-WEB/EGC). *Gastric Cancer* 2012; 15: 451–454
- 25 Kurokawa Y, Hasuike N, Ono H et al. Gastrointestinal Oncology Study Group of Japan Clinical Oncology Group. A phase II trial of endoscopic submucosal dissection for mucosal gastric cancer: Japan Clinical Oncology Group Study JCOG0607. *Jpn J Clin Oncol* 2009; 39: 464–466
- 26 Takizawa K, Takashima A, Kimura A et al. Gastrointestinal Endoscopy Study Group (GIESG) of Japan Clinical Oncology Group (JCOG). Stomach Cancer Study Group (SCSG) of Japan Clinical Oncology Group (JCOG). A phase II clinical trial of endoscopic submucosal dissection for early gastric cancer of undifferentiated type: Japan Clinical Oncology Group study JCOG1009/1010. *Jpn J Clin Oncol* 2013; 43: 87–91