

Endoscopic extraction of adjustable gastric bands after intragastric migration as a complication of bariatric surgery: technique and advice

Authors

David Collado-Pacheco¹, Luis Ramon Rábago-Torre¹, María Arias-Rivera¹, Alejandro Ortega-Carbonel¹, Ana Olivares-Valles¹, Alicia Alonso-Prada¹, Jaime Vázquez-Echarri², Norberto Herrera-Merino²

Institutions

¹ Gastroenterology Unit, Hospital Universitario Severo Ochoa, Leganés (Madrid), Spain

² General and Gastroenterological Surgery Department, Hospital Universitario Severo Ochoa, Leganés (Madrid), Spain

submitted:

19. August 2015

accepted after revision:

14. March 2016

Bibliography

DOI <http://dx.doi.org/10.1055/s-0042-105868>
Published online: 12.5.2016
Endoscopy International Open 2016; 04: E673–E677
© Georg Thieme Verlag KG
Stuttgart · New York
E-ISSN 2196-9736

Corresponding author

David Collado-Pacheco, MD
Gastroenterology Unit
Hospital Universitario Severo Ochoa
Avenida Orellana s/n
Leganés (Madrid)
Leganés 28911
Spain
Fax: +34-91-694-07-17
davidcolladopacheco@yahoo.es

Background: Surgery has been the method most widely used to manage the extraction of gastric bands with inclusion as a late complication of bariatric surgery; however, surgical extraction entails morbidity and limits future surgical procedures. The development of endoscopic techniques has provided an important means of improving the treatment of this complication, enabling minimally invasive and safe procedures that have a high success rate.

Methods: A retrospective analysis was conducted of patients who had laparoscopic gastric banding complicated by intragastric migration and were treated endoscopically. A technique already described for managing this complication was employed. An MTW Endoskopie Dormia basket for mechanical lithotripsy or a standard 0.0035-in guidewire was placed around the band, and an MTW Endoskopie emergency lithotripter was used to section it, after which the band was extracted with a standard polypectomy snare. Also

analyzed were the initial symptoms of patients with this complication, the mean time from surgery to development of the event, the success rate of endoscopic treatment, and complications. **Results:** A total of 127 patients had undergone gastric banding surgery in our Bariatric Surgery Center; of these, 12 patients (9.4%) developed a complication such as intragastric migration of the band. Weight gain and pain were the main symptoms in 11 patients (92%), and the mean time to the development of symptoms was 51.3 months. A single endoscopic treatment was successful in 7 of 9 patients (78%). Only 1 complication, involving ventilation during anesthesia, occurred; no other adverse events were recorded.

Conclusions: The endoscopic extraction of bands with inclusion is feasible and can be performed easily and successfully. The procedure is available in all hospitals and has a low incidence of related complications, so that unnecessary surgical procedures can be avoided.

Introduction

The laparoscopic placement of adjustable gastric bands has been a frequently performed bariatric surgical procedure during the past 30 years. In this technique, a silicone band is placed around the gastric fundus, approximately 2 cm below the gastroesophageal junction, to form a pouch, or neostomach. This device is then connected by a tube to an external access port, which is placed extraperitoneally under the abdominal rectus sheath or under the external thoracic fascia, so that a saline solution can be introduced to adjust the diameter of the opening through which gastric contents pass [1]. This is a safe surgical technique with low rates of morbidity and mortality, which is why it is the second most widely used bariatric surgery technique throughout the world [2]. However, it is not free of complications, many of which are associated with implantation of the

ring and band: slippage (type I), stenosis with pouch dilation (type II), and minor erosion with likely associated port infection (type IIIa) or intragastric migration (type IIIb) [3]. Port site infection and intra-abdominal infection are well-known complications of laparoscopic adjustable gastric banding. Early port site infections are usually related to the surgical procedure; however, late port site infections with delayed band erosion have also been described, and these are probably due to loss of integrity of the band surface, which allows passage of the gastric contents within. Migrated bands must be removed, not only to relieve the symptoms they cause but also to prevent intra-abdominal infections, gastric obstruction, and bleeding resulting in anemia. Surgery has been the traditional way to manage these complications, although it is associated with morbidity and can make any future bariatric surgery more difficult. The endoscopic extraction of dysfunc-

License terms



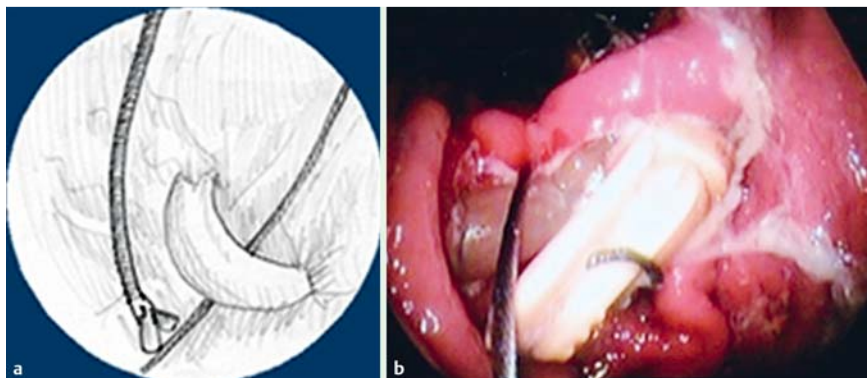


Fig. 1 Extraction of a migrated adjustable gastric band. A metallic thread (Dormia basket or guidewire) is introduced through the opening between the digestive tube wall and the migrated band within the gastric cavity and recovered through the opposite opening with forceps. **a** Drawing. **b** Endoscopic image.

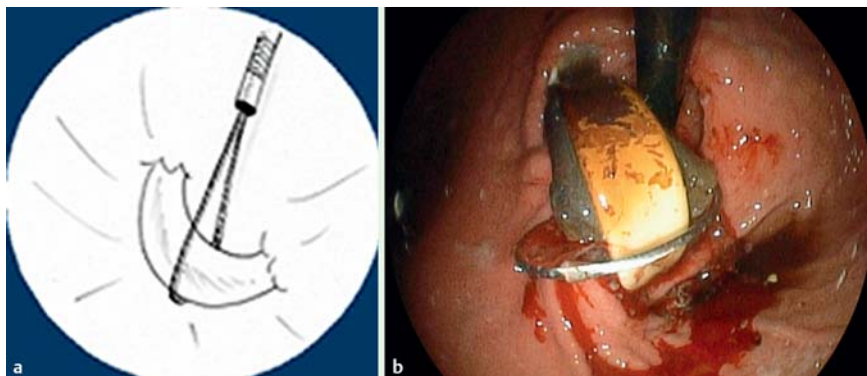


Fig. 2 **a,b** Metallic thread surrounding the gastric band is introduced into the emergency lithotripter. **a** Diagram. **b** Endoscopic image.

tional bands has been described as a safe and minimally invasive alternative [4], and various techniques have been used (endoscopic laser, endoscopic scissors, self-expanding prosthesis, and electro-surgical devices).

The objective of the present study was to review our experience in the extraction of migrated bands with an endoscopic technique similar to those previously described [3], which is easily accessible at most centers. The study focuses on the difficulties and key points of the technique, in an effort to increase its success rate.

Patients and methods

A retrospective study was conducted of patients with morbid obesity who underwent laparoscopic adjustable gastric banding (LAGB) in our center between January 2003 and June 2013. All patients who presented with band dysfunction such as major erosion or intragastric migration (type IIIb), defined as inclusion of more than 50% of the band circumference within the gastric cavity [3,5], were enrolled in the study. The procedure was performed only in patients with migration of more than 50% of the band circumference, never less, for the following reasons: (i) this ensured the shortest possible route for the band to pass through the gastric wall during the procedure; (ii) when more than 50% of the band circumference is included within the gastric cavity, intragastric inclusion of the closure clip is more likely, which facilitates moving the band and overcoming the resistance of tissues holding it in place. (This was not an absolute requirement in our patients but is highly recommended.)

The diagnosis was made in all patients via gastroscopy, and all were offered endoscopic treatment after the procedure, its advantages, and potential complications had been explained to them and after they had provided written informed consent.

All patients in the study were outpatients seeking medical advice for various problems, but they did not need to go to the emergency department because they did not have an acute abdomen. However, even if the results of a patient's physical examination were normal, complete blood testing as well as chest and abdominal radiography were always performed to exclude perforation. All patients were also evaluated by the anesthesiology team before they were treated endoscopically. Computed tomography was not indicated in any of our patients.

We present herein a retrospective study of an internationally well-known type of treatment that can be implemented without the consent of an ethics committee. However, patient informed consent is always required.

Extraction technique

Endoscopic extraction was conducted in an operating room while the patient was under general anesthesia with orotracheal intubation and while a surgical team was present. A conventional gastroscope was used; for band sectioning, a lithotripsy Dormia basket (MTW Endoskopie, Wesel, Germany) with its plastic sheath removed or a standard 0.0035-in guidewire was used. Even though the lithotripsy Dormia basket was not designed to cut adjustable gastric bands, we had previously confirmed that it or a standard 0.0035-in guidewire was able to cut the adjustable band, and both were successfully used off label.

The Dormia basket or guidewire is introduced through the endoscope channel, and the distal end is left in the gastric antrum; the basket or guidewire is introduced through either of the two openings between the band and the gastric wall at the level of the gastro-esophageal junction (▶ Fig. 1a, ▶ Fig. 1b). The endoscope is removed and then reintroduced to recover the distal end left in the gastric cavity, which is pulled through the opening between the band and the gastric wall opposite the one through which it was initially introduced. Thus, when the endoscope is

again removed, the two ends are brought out through the patient's mouth, and the Dormia basket or guidewire is left completely surrounding the band (● Fig. 2a, ● Fig. 2b).

The two metallic ends emerging from the patient's mouth are placed in an MTW Endoskopie emergency lithotripter (● Fig. 3), which, after complete closure, sections the band (● Fig. 4); this step must be conducted under endoscopic monitoring to ensure that the gastric band is sectioned in the middle, far from the closure clip, which is made of hard plastic that cannot be sectioned and is located close to the junction of the band with the tube connecting it to the port. The sectioned band is extracted by capturing and pulling one of its ends with a standard polypectomy snare – the end of the band that is closer to the tube connecting it with the external reservoir.

Simultaneously with this last step, the surgical team makes an incision in the abdominal wall to disconnect the port from the tube joining it to the band (● Fig. 5), to make possible subsequent extraction. We perform the endoscopic and the surgical procedure together for several reasons. Once we have been able to cut off the rubber band successfully, the surgeon disconnects the band from the tube and extracts the external portion of the port and the tube; this helps us to determine which of the two ends of the sectioned band is better to grasp with the snare device to facilitate extraction. If we disconnect the port before removal of the band, the portion of the tube in the subcutaneous tract will not move into the stomach because the band is fixed within the stomach wall and surrounding tissue, and the portion of the band that has migrated into the stomach will not increase.

Theoretically, there is a fear of perforation, but perforation does not occur. Perhaps when the surgical and endoscopic procedures are done together, air introduced into the stomach by the endoscope leaves through the subcutaneous tube tract; this might not happen in a split procedure. In any case, once we remove the band, the inflamed tissue around the stomach seals the tract completely, so that the patient can be fed in 24 hours. Performing the two parts of the procedure simultaneously reduces the required time and expense of the anesthesiology team.

Patient management

Once the band has been removed, the patient remains hospitalized on a fluid diet and receives intravenous proton pump inhibitors for 24 hours. Patients can be discharged from the hospital within the next 24 to 48 hours after adequate oral tolerance and the absence of clinical signs suggesting complications (high temperature, abdominal pain) have been confirmed. No radiologic follow-up is required.

Results

In total, 127 patients were identified who had undergone surgery in our bariatric surgery center with the gastric banding technique; of these, 12 patients (9.4%) experienced a complication such as major erosion or intragastric migration of the band. In all patients, band migration was diagnosed via gastroscopy. The clinical signs that caused us to suspect dysfunction were the following (● Table 1): weight gain in 11 patients (91%), failure to lose weight in 1 patient, symptoms of port infection in 2 patients (18%), and signs of dysmotility or epigastric pain in 2 patients (18%). A surgical procedure was chosen as the first treatment for 3 of the 12 patients; 2 patients underwent surgery for band dysfunction so that another bariatric surgery could be

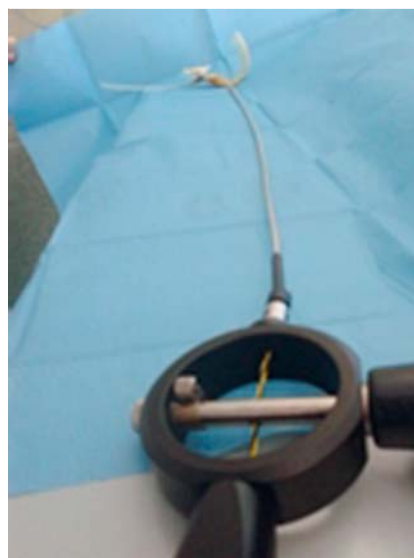


Fig. 3 Emergency lithotripter with the two metallic ends of the Dormia basket or guidewire introduced.

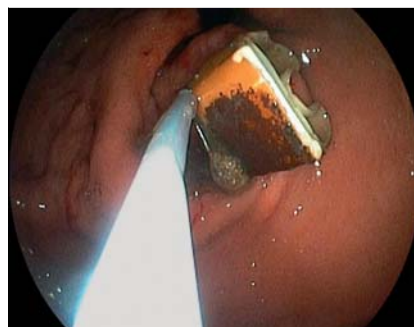


Fig. 4 Endoscopic image of the band sectioned and grasped with a polypectomy snare immediately before extraction.

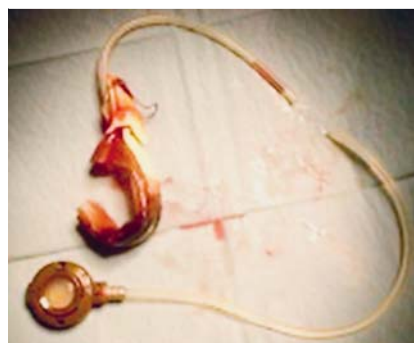

Fig. 5 Sectioned band and its components. The external circular reservoir is connected by a tube attached to the band close to its closure tip.

performed and the migrated band was diagnosed intraoperatively, and 1 patient was given a preoperative diagnosis and chose to undergo surgery rather than be treated endoscopically. The remaining 9 patients were treated endoscopically: 8 women and 1 man with a mean age of 44.8 years (range 33–55) and a mean time between surgery and dysfunction of 53.1 months (range 29–84).

Extraction with a single endoscopic procedure was successfully achieved in 7 of the 9 patients (78%). Technique failure occurred in 2 patients. In the first patient, the cut was made in a very eccentric manner; the Dormia basket surrounded the band closure clip, so that sectioning was impossible (● Fig. 6). This patient with a failed endoscopic extraction underwent a surgical procedure without incident.

In the other patient, the endoscopic procedure failed because the silicone band was cut in an area too close to the closure clip and

Table 1 Characteristics of nine patients included in a study of the endoscopic extraction of adjustable gastric bands after intragastric migration as a complication of bariatric surgery.

Sex, n	
Male	1
Female	8
Age, y, mean (range)	44.8 (33–55)
Time to dysfunction, mo, mean (range)	53.1 (29–84)
Patients with symptoms of dysfunction, n	
Weight gain	8
Failure to lose weight	1
Port infection	2
Dysmotility/epigastric pain	2
Endoscopic success, n (%) [*]	7 (77.7)
Length of postsurgical hospitalization, d, mean (range)	2.5 (1–7)

^{*} In one patient, the band surrounded the closure clip and could not be sectioned; the patient underwent a surgical procedure after endoscopy. In a second patient, the band was sectioned but could not be extracted because the cut was too close to the closure clip, making traction impossible.

its connection with the tube between the band and the port, so that adequate traction was impossible because only the opposite side could be accessed, forcing slippage of the band closure clip and part of the tube through the gastric wall, which is technically very difficult. At present (7-year follow-up), this patient (who has cirrhosis caused by hepatitis B infection and a high level of venous circulation in the cardia) continues with the band sectioned and not extracted because of the high surgical risk; thus far, no incidents have been observed. We were not able to remove the band quickly during the procedure because of its strong adherence to the surrounding tissues and problems with ventilation; we therefore think the risk for spontaneous migration without endoscopic intervention (such as placement of a plastic expanding stent) is theoretical, and the likelihood of the band passing the pylorus is even smaller.

We did not experience any endoscopic complications. The only adverse event was an anesthesia problem related to the patient's ventilation; this was caused by abdominal distension during difficult extraction of a sectioned band. We were forced to interrupt the procedure and rule out pneumoperitoneum, and the procedure was ended without further incident. In this case, we chose a policy of follow-up and wait and see. The mean duration of postsurgical hospitalization was 2.5 days (range 1–7).

Discussion

Major erosion or intragastric migration is defined as the presence of an adjustable band within the gastric cavity; the inclusion of at least 50% of the circumference of the band within this location is required [3] for endoscopic extraction to be feasible. The incidence of band migration as a complication of bariatric surgery has been reported to be between 0.5% and 11% [2], although some studies suggest a potential underestimation of this complication due to the lack of follow-up gastroscopy procedures in these patients; band migration usually appears a relatively long time after surgery, and many patients may be asymptomatic during the initial stages [4]. Some of the etiologic factors underlying this event that have been described are the following: (i) foreign body reaction to the band material; (ii) local infection in the area

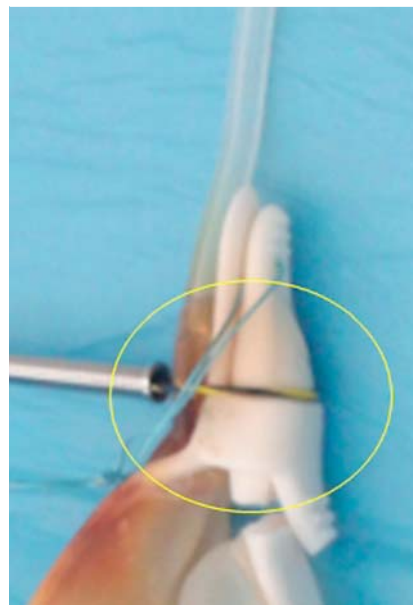


Fig. 6 Care must be taken not to cut within the circled area.

of the band; (iii) excessive tightening of the band, which causes wall ischemia; and (iv) damage to the gastric wall during the surgical act of implanting the band. Likewise, an increased risk has been suggested in patients who have a gastric ulcer or are taking nonsteroidal anti-inflammatory drugs or aspirin [5], as well as those who have bands made of polypropylene rather than silicone [6].

The presenting symptoms of band intragastric migration can be nonspecific; however, the most common are weight gain, port infection, and abdominal pain, although up to 15% of patients may remain asymptomatic [1].

Treatment for this complication has been traditionally been surgical, with endoscopy reserved for diagnosis; however, various endoscopic procedures for band extraction, to avoid surgery, have been reported; these reduce morbidity and allow future bariatric procedures to be conducted in patients who are likely to continue to be obese after band migration [3].

The patients in our study are similar to those in previous publications in regard to incidence of complications (9.4%) and symptomatology leading to suspicion of a complication. The endoscopic technique used and described by other authors [3] has proved safe, achieves a high success rate without morbidity and mortality, and is easily accessible in most hospitals because of the materials used. However, it is necessary to be aware of two key aspects of the procedure to ensure success and potentially complete extraction: (i) the optimal point for sectioning the band and (ii) the best place for applying traction to extract the band. The band must be sectioned approximately in the middle of the hemi-circumference visible within the stomach; however, it must be remembered that sectioning should be done as far as possible from the closure clip (intragastric inclusion of the clip is recommended as it makes extraction easier) because it is necessary to have a piece of the band close to the clip that is long enough to be grasped easily by the polypectomy snare and pulled proximally from this end, so that the clip and the tube connecting with the reservoir will go through the gastric wall via the shortest possible route. Finally, we must emphasize that traction on the band while it is held with the polypectomy snare will be applied when the endoscope is withdrawn, usually from the esophagus. Traction requires the continuous application of a certain amount of force

to move the band and overcome the resistance of the tissues holding it in place, which necessitates a deeper level of analgesia. In conclusion, we can state that based on these principles, the endoscopic extraction of bands in cases of inclusion is feasible and can be performed easily and successfully. The procedure is accessible in nontertiary hospitals and has a low incidence of relevant complications, so that unnecessary surgical procedures can be avoided.

Competing interests: None.

References

- 1 *Neto MP, Ramos AC, Campos JM et al.* Endoscopic removal of eroded adjustable gastric band: lessons learned after 5 years and 78 cases. *Surg Obes Relat Dis* 2010; 6: 423–427
- 2 *Cortés Arriagada C, Navarrete García C, Silva Fuente-Alba C.* Erosion and intragastric migration of the gastric band as a complication of bariatric surgery. Case report and review of the literature [in Spanish]. *Gastroenterology* 2007; 30: 465–468
- 3 *Blero D, Eisendrath P, Vandermeeren A et al.* Endoscopic removal of dysfunctioning rings or bands after restrictive bariatric procedures. *Gastrointest Endosc* 2010; 71: 468–474
- 4 *Silecchia G, Restuccia A, Elmore U et al.* Laparoscopic adjustable silicone gastric banding: prospective evaluation of intragastric migration of the lap-band. *Surg Laparosc Endosc Percutan Tech* 2001; 11: 229–234
- 5 *Singhal R, Bryant C, Kitchen M et al.* Band slippage and erosion after laparoscopic gastric banding: a meta-analysis. *Surg Endosc* 2010; 24: 2980–2986
- 6 *Bozboru A, Coskun H, Barbaros U et al.* The effects of gastric bands of different synthetic materials on the gastric and esophageal mucosa: an experimental study. *Obes Surg* 2004; 14: 246–252