

# Complications of Percutaneous Peritoneal Dialysis Catheter

Bharvi P. Oza-Gajera, MD<sup>1</sup> Ahmed K. Abdel-Aal, MD<sup>2</sup> Ammar Almehehi, MD<sup>3</sup>

<sup>1</sup>Department of Medicine, University of Cincinnati, Cincinnati, Ohio

<sup>2</sup>Department of Interventional Radiology, University of Texas at Houston, Houston, Texas

<sup>3</sup>Department of Radiology and Medicine, University of Alabama at Birmingham, Birmingham, Alabama

Address for correspondence Ammar Almehehi, MD, 619 19th Street South, Birmingham, AL 35249 (e-mail: aalmehehi@uabmc.edu).

Semin Intervent Radiol 2022;39:40–46

## Abstract

### Keywords

- ▶ peritoneal dialysis
- ▶ peritonitis
- ▶ infectious complications
- ▶ dialysis access
- ▶ peritoneal dialysis catheter
- ▶ interventional radiology

A functional peritoneal dialysis (PD) catheter is the cornerstone for the success of renal replacement therapy. This success is largely dependent on adhering to best practices during catheter insertion, which starts with a comprehensive preoperative evaluation that helps in determining the catheter configuration type and both entry and exit sites. Additionally, following the best practice guidelines during PD catheter insertion minimizes undesirable complications and provides a durable functional access for dialysis. However, adverse complications are still encountered despite abiding with these clinical guidelines. These complications are categorized into mechanical and infectious groups. The description and management of these adverse events are discussed in detail in this article with particular attention to the technical pitfalls that can occur during catheter insertion. Avoiding these pitfalls can minimize PD catheter complications and potentially improve clinical outcomes.

Peritoneal dialysis (PD) is a renal replacement therapy with many benefits including being a home modality leading to a better quality of life and autonomy, continuous therapy, decreased vascular complications, as well as fewer interruptions in therapy. The utilization of PD as a renal replacement therapy in the United States is lower than that around the world. However, after the launch of the Advancing American Kidney Health Initiative in 2019 which emphasized the role of the home dialysis modality, many programs are investing more resources into expanding PD programs.

Successful PD is dependent on the interaction of cycles of peritoneal fluid freely flowing within the peritoneal cavity and thus interacting with the peritoneal membrane through a reliably functional long-term peritoneal access. The fluid must be able to instill quickly, dwell for the intended period of time with adequate membrane contact, and subsequently drain quickly. This must be an efficient process which occurs multiple times per the patient's prescribed treatment to be successful. Hence, monitoring and treatment of dialysis-

related peritoneal infections, mechanical complications, and catheter-related infections are crucial factors in catheter survival and successful PD therapy.<sup>1</sup>

Catheter placement can occur via an open surgical placement, laparoscopic placement, peritoneoscopic placement, fluoroscopic placement (with or without ultrasound), as well as blindly. Although there are benefits and challenges to each method utilized, no specific method has been proven to be more successful generally than any other.<sup>2</sup> Each patient should be evaluated individually, and local resources examined before deciding which method is preferred.<sup>3</sup> This article will cover complications of percutaneous fluoroscopic placement of the PD catheter performed by interventionalists in the radiology suite.

## Preoperative Preventive Practices

Because achieving a durable and infection-resistant access is staple to therapy, following best practices during insertion

Issue Theme Dialysis Interventions;  
Guest Editor, Ahmed Kamel Abdel Aal,  
MD, PhD, FSIR

© 2022. Thieme. All rights reserved.  
Thieme Medical Publishers, Inc.,  
333 Seventh Avenue, 18th Floor,  
New York, NY 10001, USA

DOI <https://doi.org/10.1055/s-0041-1741484>.  
ISSN 0739-9529.

can minimize the risk of catheter complications which can lead to PD failure.<sup>1</sup> A best practice checklist for preoperative preparation and peritoneal catheter placement is detailed in the International Society for Peritoneal Dialysis (ISPD) guidelines.<sup>4</sup> In essence, the main aim of utilization of the guidelines is to decrease the occurrence of catheter-related complications from the time of insertion.

## Complication Categories

The ultimate goal of PD catheter placement is successful PD treatments. Therefore, any issue that occurs in which the patient is not able to obtain adequate treatments is a complication. When related to the catheter itself, these can be categorized into early perioperative complications, mechanical complications, and infectious complications. Percutaneous fluoroscopic PD catheter placement is described in detail elsewhere and is beyond the scope of this article; however, many complications occur due to variations in placement procedure. Therefore, following a systematic stepwise approach during PD placement is vital for successful PD programs.

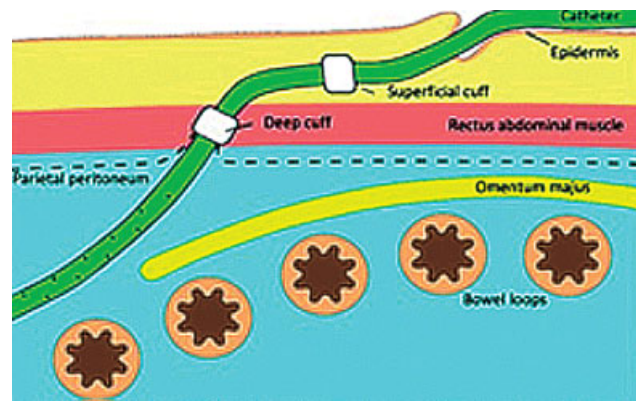
Selecting the insertion method and the catheter type is significant ingredient for successful functional PD catheters.

## Selection of Insertion Method

Prevention of acute complications can be mitigated by appropriate patient selection for percutaneous fluoroscopic PD catheter insertion. Therefore, obtaining a thorough history and physical exam is critical. In general, each patient should be evaluated in the outpatient clinic for prior abdominal surgeries, bladder or bowel incontinence, as well as foreign tubing or devices. Obesity and abdominal wall thickness are also important to review when considering percutaneous insertion. Laparoscopic placement may be preferred for those patients as various issues can be addressed surgically simultaneously during catheter insertion. Accordingly, careful patient selection for percutaneous fluoroscopic catheter insertion and appropriate mapping of the insertion site and exit site are necessary. It is worth mentioning that any scarring of the peritoneal membrane may render it ineffective for dialysis, regardless of insertion method utilized.

## Selection of Catheter Type

Catheter type selection is an important component of successful peritoneal therapy and should be individualized for each patient. As a rule, the best catheter for any particular patient is the one that can achieve appropriate pelvic placement, a clean exit site easily visible and accessible to the patient, and one which can be inserted and implanted through the abdominal wall using the least amount of tubing stress.<sup>2</sup> In general, a double Dacron cuff is preferred, as the deep cuff can be embedded within the rectus muscle, a merit that provides firm tissue ingrowth and fixation of the cuff leading to better catheter immobilization<sup>2,4</sup> (► Fig. 1). Additionally, the superficial cuff, which is placed in the subcuta-

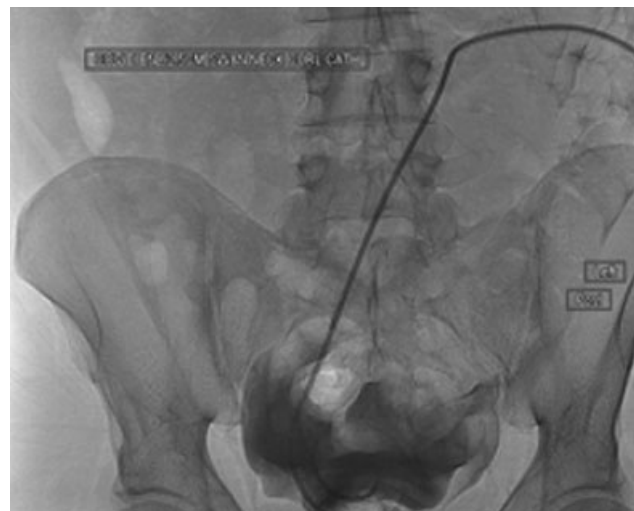


**Fig. 1** Relationship of the peritoneal catheter cuffs to the adjacent structures.

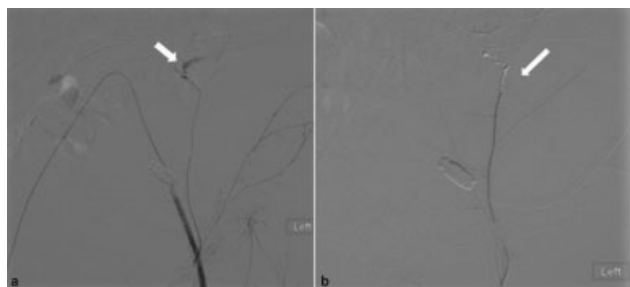
neous tissue 2 to 4 cm from the exit site, serves as an effective barrier to contaminants that can invade the catheter track.<sup>2</sup> Furthermore, the double-cuff configuration may lower the risk of *Staphylococcus aureus* peritonitis.<sup>5</sup> An extended two-piece catheter with a second piece that has a two-cuff subcutaneous extension with a titanium connector can be used to create a remote exit site location in the upper abdomen, back, or chest. These extended PD catheters are ideal for patients with multiple skin creases and folds, obesity, intestinal stomas, feeding tubes, fecal or urinary incontinence, suprapubic catheters, or those who like to take deep tub baths.<sup>4</sup> ► Fig. 2 shows the normal position of PD catheter.

## Perioperative Complications

Immediate and early complications are those that occur in the perioperative period. The most severe and critical of these complications is bowel or bladder perforation as well as critical hemorrhage usually due to puncture of the inferior epigastric vessels (► Fig. 3). Bleeding that is related to the rectus muscle and tissue trauma is occasionally encountered. Using ultrasound during insertion can mitigate the bleeding



**Fig. 2** Proper peritoneal catheter position within the pelvis.



**Fig. 3** Selective arteriogram reveals extravasation from the inferior epigastric artery (arrow, a) treated with coil embolization (arrow, b).

complications, as vessels and bowel loops are visualized and needle entry into the peritoneum is performed under direct ultrasound guidance. Moreover, fluoroscopy to insert a guidewire into the deep pelvis and contrast injection to identify the posterior pelvis are also helpful tools in preventing the injury to intra-abdominal organs and structures.

Visceral injury typically occurs during entry into the abdominal cavity or during advancement of the catheter into the pelvis. If bowel perforation is considered, it is crucial to recognize and confirm the diagnosis immediately. This can be done via visualization of bowel lumen, return of bowel contents from the dialysate effluent, a hissing sound from gas release, or emanation of foul-smelling gas. Contrast injection characteristically outlines the mucosal folds of the small or large intestine.<sup>6</sup> If undetected, manifestations postoperatively include severe watery diarrhea, abdominal pain with hypotension, rigid abdomen, and peritonitis.<sup>2</sup> A through-and-through bowel perforation may temporarily mask some of these manifestations. This is far more common with the use of trocars and blind insertion methodologies. Most microperforations can be managed by keeping the patient NPO, giving prophylactic antibiotics, and close observation.<sup>7</sup> Occasionally, immediate surgical intervention may be required to address this complication.

Bladder perforation is rarely encountered when the percutaneous PD technique is used. Several signs and tests can help in the diagnosis, such as checking glucose on a urinalysis, an increase in urine volume, hematuria, bladder distention immediately after instillation of dialysis fluid, and urinary peritonitis causing ileus. Importantly, this complication can go unnoticed as some of the holes of the PD catheter may remain outside the bladder; therefore, other diagnostic tools can be used to confirm the diagnosis including postoperative cystoscopy, cystogram, and other imaging. Notably, neurogenic bladder with incomplete emptying may predispose to perforation.<sup>2</sup> Therefore, emptying the bladder and inserting a Foley catheter prior to PD catheter insertion are important preventive steps.

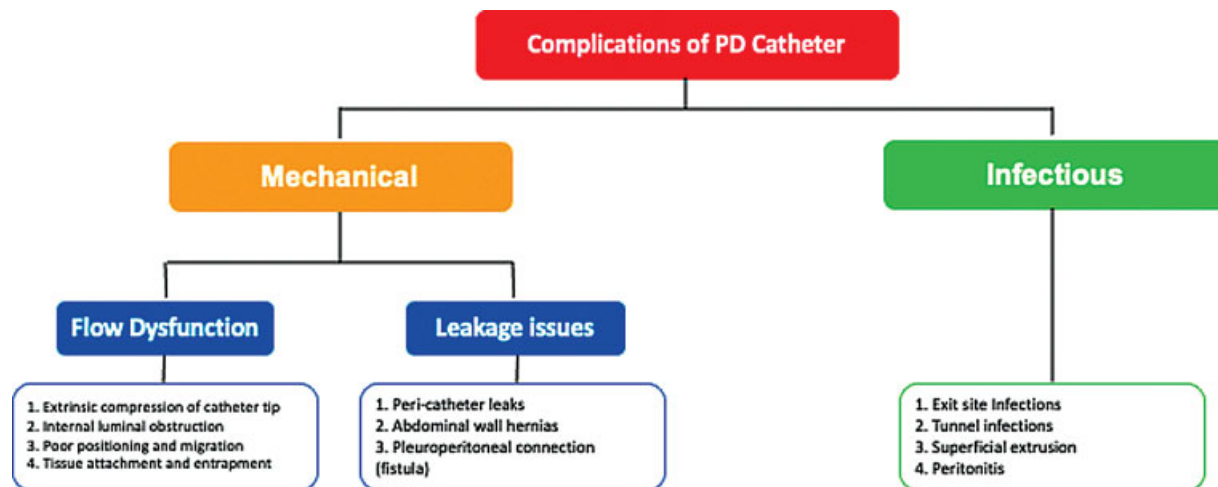
Hemorrhage of the inferior epigastric vessels may require ligation if noted intraoperatively or surgical versus angiographic embolization if discovered postoperatively (►Fig. 3).<sup>2</sup> On the other hand, intra-abdominal trauma may result in mild bleeding that manifests as blood-stained effluent. This is usually self-limited and requires conservative management including regular flushes and possible use of intraperitoneal heparin.<sup>2</sup> Bleeding at the exit site may also occur and is usually controlled with manual pressure, suture placement, injection with epinephrine, and frequent dressing changes.

### Post-Insertion Complications

Complications that occur after PD catheter placement can be categorized into mechanical and infectious, as depicted in ►Fig. 4.<sup>5</sup> Mechanical complications can be further grouped into flow dysfunction or pericatheter leakage issues.

#### Mechanical Complications

These complications include issues with flow dysfunction due to extrinsic compression of the catheter tip, internal luminal obstruction, poor positioning and/or migration, and tissue attachment and entrapment. On the other hand,



Ref: Adapted from IN Primer ASDIN

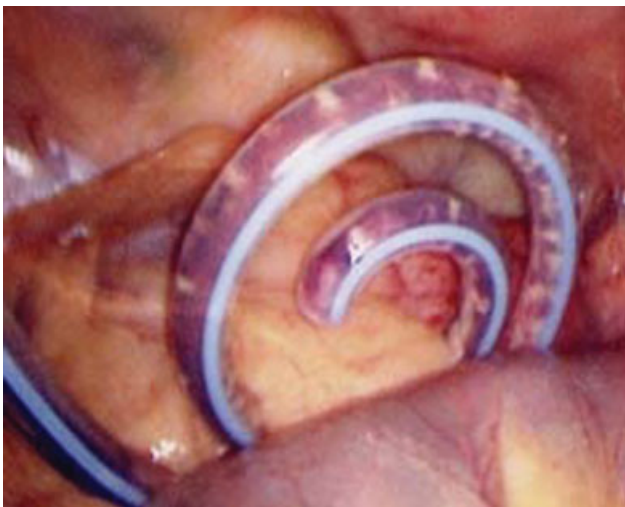
**Fig. 4** Classification of PD catheter complications post-insertion.

peritoneal leakage complications can also occur with a reported frequency as high as 12.8%. These leakages can broadly be categorized into pericatheter leaks, abdominal wall hernias, and pleuroperitoneal connection or fistula development.<sup>2</sup>

**Flow dysfunction issues:** Flow dysfunction mainly manifests as drain pain that is encountered upon draining the dialysate. This pain typically results from incomplete evacuation of dialysate fluid as visceral structures in the pelvis siphon up to the catheter tip causing contact and irritation against the parietal peritoneum. This phenomenon typically occurs when the PD catheter is placed too deep in the pelvis, usually seen when the umbilicus is used as a landmark rather than the pubic symphysis. Subsequently, the PD catheter may become crowded between the rectum, uterus, and bladder. In most cases, catheter replacement is required, as neither drainage to gravity nor manipulation would effectively solve this problem. Therefore, it is of the utmost importance that the operator applies due diligence preoperatively and during implantation to ensure adequate placement of the PD catheter with careful attention paid to catheter type according to body habitus/belt line, incision site, and exit-site location. Flow dysfunction of PD catheter may arise from extrinsic compression, luminal obstruction, catheter migration, or catheter entrapment, as detailed in the following paragraphs.

**Extrinsic compression of the catheter tip:** This dysfunction is commonly caused by constipation and/or bladder distension and usually manifests as a difficulty with draining the dialysate, incomplete draining, or drain pain. The distended bladder or colon obstructs the side holes of the catheter, which, in turn, impairs the drainage process of the dialysate fluid. A simple abdominal X-ray and checking a post-void residual urine volume are used for diagnosis and treating the underlying cause usually solves the problem.

**Luminal obstruction of the catheter:** This complication occurs due to a tube kink or fibrin/blood clot creating a two-way obstruction that manifests as a difficulty with both instillation and drainage of the dialysate (→ Fig. 5).<sup>8</sup> Simple



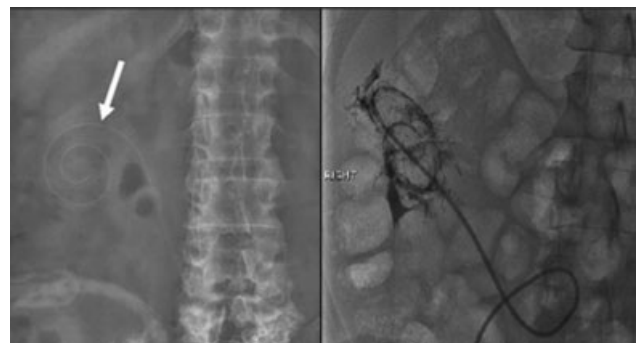**Fig. 5** Obstructed peritoneal dialysis catheter with intraluminal debris.

methods to dislodge or dissolve debris include irrigation using a syringe of saline, instilling tissue plasminogen activator to dissolve the luminal clot, or the use of wires under fluoroscopic guidance through the catheter lumen to dislodge obstructive debris. If these maneuvers are unsuccessful, the next step would involve PD catheter exchange to resume the effective PD. A subcutaneous kink in the tubing system is almost always due to technical errors during insertion that often occurs in the transmural segment.<sup>4</sup>

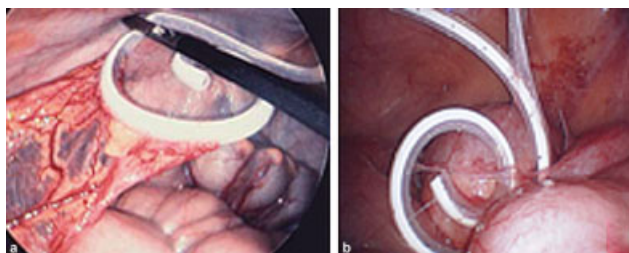
**Catheter migration:** This complication can occur any time after placement and is usually related to the catheter shape-memory resiliency forces that occur when a straight catheter is bent imposing excessive stress on the tubing. Typically, catheter migration occurs with the tip into a subdiaphragmatic location. A plain radiograph is usually sufficient for diagnosis as seen in → Fig. 6.<sup>9</sup> Once catheter migration is diagnosed on plain radiograph, repositioning the PD catheter can be attempted under fluoroscopic guidance. The success rate of catheter repositioning is usually low, making catheter exchange the next logical step.

Catheter migration can be minimized by ensuring that when the catheter is placed, the appropriate shape is chosen to follow the catheter's natural course of direction and that the deep cuff is immobilized in the rectus musculature, preferably with a purse string suture. Specifically, the tangential insertion of the appropriate catheter through the rectus muscle at the paramedian site with positioning of the deep cuff within the musculature is critical. Choosing the correct configuration of the catheter is important as well. If the incision site (location of the deep cuff) is located above the belt line, a catheter with a straightened intercuff segment should be chosen so that the exit site and catheter sit laterally and downward externally without inducing resiliency forces on the internal portion of the catheter. Packaging can also induce shape-memory resiliency forces, especially in the coiled configuration. Special attention should be paid to this when placing the catheter so that the coil is facing the appropriate direction (typically left for left abdominal wall placement and vice versa).<sup>1</sup>

**Tissue attachment and entrapment:** This complication can create either one-way flow issues (during drainage) or two-way flow impairment during both instillation and drainage. The catheter becomes entrapped due to omental wrapping or ensnaring by adhesions within the peritoneal cavity



**Fig. 6** Abdominal radiographs demonstrating catheter tip migration superiorly from the pelvis to the right upper abdomen (arrow).



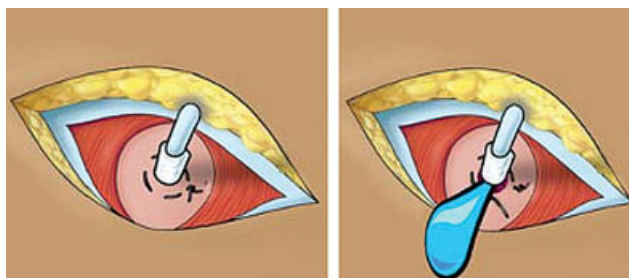
**Fig. 7** The PD catheter is trapped within the omentum (a) and within the adhesions (b).

resulting in obstruction of the side holes of the catheter (►Fig. 7).<sup>10</sup> In most cases, catheter entrapment requires a laparoscopic approach in which adhesions and omental entrapment can be addressed and the PD catheter can be released or exchanged.

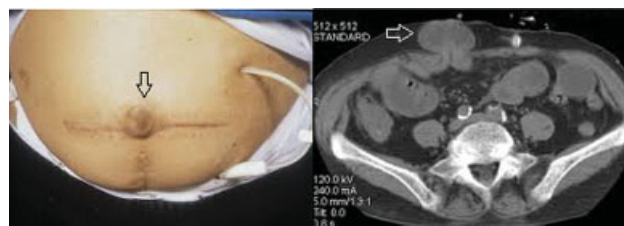
### PD Catheter Leakage Issues

These complications can occur early or late after PD catheter placement.

*Early pericatheter leaks* are mostly seen in urgent start PD patients in which PD therapy is initiated immediately after catheter placement. To mitigate pericatheter leakage, low-volume fills of PD fluids used in the supine position are advised. Furthermore, avoiding any activity that increases the abdominal pressure, such as vigorous physical activities and heavy lifting, in the perioperative period is recommended. Depending on the severity of the leak, the patient may require switching to hemodialysis until the PD catheter site is fully healed.<sup>5</sup> Delaying the PD initiation for approximately 2 weeks—known as the peritoneal catheter “break-in period”—can minimize the risk for pericatheter leak. A dramatic early leak (within 30 days of catheter insertion by convention) can be seen with purse string suture failure of the deep cuff or technical error of wound repair during placement<sup>11</sup> (►Fig. 8). This requires immediate exploration as persistent leakage of fluid is prone to infection, which may require prophylactic antibiotics. Eventually, persistent leaks will require catheter replacement. Of special note, in cases of urgent start PD use, special attention is required to ensure water-tight seals at all incision points including a tight purse string suture around the deep cuff within the rectus muscle, precise placement of the superficial cuff, and tight creation of the exit site.



**Fig. 8** Diagram showing pericatheter leak.



**Fig. 9** Abdominal wall hernia is evident on exam and confirmed with CT abdomen (arrows).

*Late pericatheter leaks* are usually seen after 30 days of catheter insertion and encountered with occult tunnel infections or pericatheter hernia development in the setting of improper placement of the deep cuff outside the muscle wall or in the midline fascia. Most late PD catheter leaks require catheter replacement.<sup>11</sup>

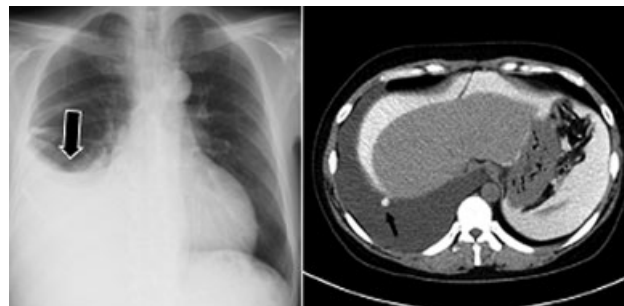
*Abdominal wall hernias* can develop due to increased abdominal pressure during PD treatments. Risk factors include steroid use and obesity. These hernias may require surgical repair (►Fig. 9).

*Hydrothorax* is a rare complication that usually occurs on the right side of the chest. It usually develops as the result of a pleuroperitoneal connection (fistula formation).<sup>12</sup> Consequently, in the presence of this connection, the dialysate fluid moves from the peritoneum into the pleural space resulting in clinical sequelae. Hydrothorax requires surgical repair of the fistulous communication between the two cavities within the diaphragm (►Fig. 10).<sup>12</sup>

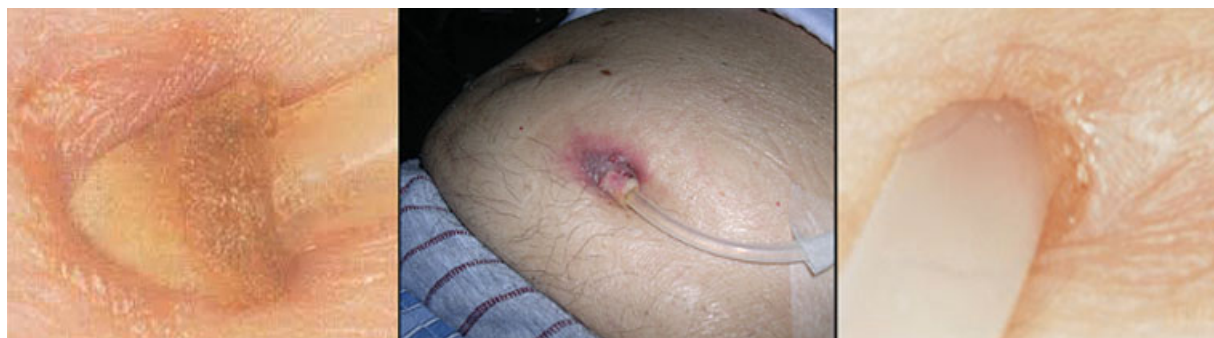### Infectious Complications

Catheter-related infections are the most common cause for the loss of PD catheters with subsequent switch to the hemodialysis modality. Infectious complications can be classified into exit-site infections, superficial cuff extrusion, tunnel infections, and peritonitis.

*Exit-site infections:* These infections are typically related to either poor exit site location or poor exit site care. The diagnosis is usually made on clinical basis through examining of the visible exit site and performing an ultrasound of the tunneled track to rule out any track involvement. Management includes obtaining culture and Gram stain of the drainage fluid and starting empiric antibiotics. If the exit-site infection becomes chronic (persists or relapses after 2–3



**Fig. 10** Massive right pleural effusion shown on chest X-ray and chest CT (arrows).

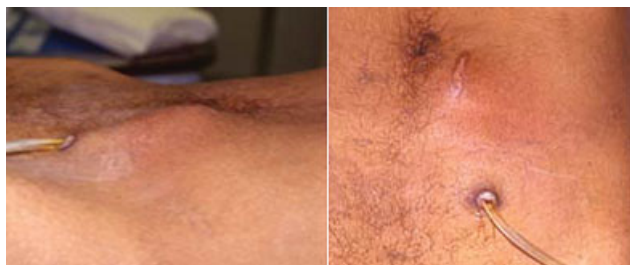

**Fig. 11** Cuff extrusion and exit-site infection.

weeks of appropriate care), especially with *S. aureus* or *Pseudomonas aeruginosa*, involvement of the superficial cuff and/or the tunnel needs to be ruled out using ultrasound and requires timely treatment to prevent infection spread with subsequent development of peritonitis. As a preventive best practice measure, the exit site should be created in a lateral and downward position that the patient can easily see and access to ensure adequate exit-site care and prevent pooling of bacteria, debris, or fluids.

**Superficial cuff extrusion:** Hypermobility of the PD catheter may lead to this complication. To prevent catheter hypermobility, a purse string suture around the deep cuff ensures immobility of the catheter. Moreover, the placement of the superficial cuff at least 1 to 2 cm internal to the exit site without excessive manipulation of the tubing is also helpful in preventing this complication.<sup>4</sup> Interestingly, this complication can be managed conservatively by shaving and removing the external cuff with a scalpel or avulsing from the tubing with forceps and allowing the exit site to heal without the need to exchange the catheter (→**Fig. 11**).<sup>13</sup> However, purulent drainage related to cuff extrusion mandates wound cultures, empiric antibiotics initiation, and local exit-site care.

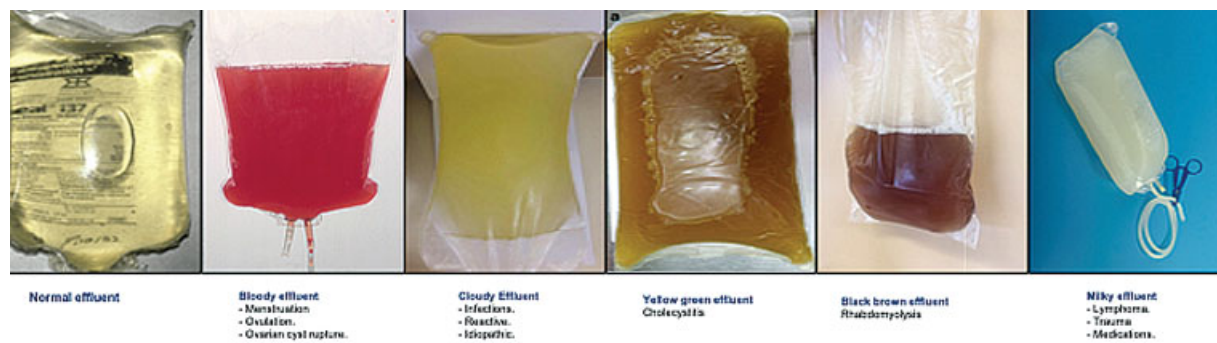
**PD catheter tunnel infections:** The spread of infection into the catheter tunnel is the culprit for these complications (→**Fig. 12**). The management of these infections is largely dependent on the involvement of the deep cuff. Therefore, the absence of evidence for infection that is usually suspected by the presence of fluid around the superficial cuff implies that the infection is mainly related to poor exit-site location. In this case scenario, the catheter can be salvaged by splicing a new catheter segment to the intercuff section of the indwelling catheter and tunneling it to an appropriate exit-site location.<sup>4</sup> However, the presence of fluid around the



**Fig. 12** Peritoneal catheter tunnel infection.

superficial cuff on ultrasound without the involvement of the deep cuff and without concurrent peritonitis implies catheter tunnel infection. In experienced centers, these infections can be managed conservatively by excising the exit-site skin and extending the incision over the subcutaneous track until the superficial cuff is exposed. The cuff is then shaved, and the catheter immobilized with the shaved segment external to the wound, leaving the incision open to heal by secondary intention.<sup>4,14</sup> Another strategy to manage tunnel infections is to excise the exit site and skin overlying the subcutaneous track en bloc with the underlying tissue around the catheter segment containing the superficial cuff (in theory to avoid contamination of infected material). The wound is then closed, and subsequently infected tissue removed from the catheter, the superficial cuff shaved, and the catheter immobilized. However, in real-life practice, most tunnel infections are treated by removing the old catheter and inserting a new one using a different site. Finally, once the deep cuff is infected or the infection reaches the peritoneal cavity causing peritonitis, the treatment usually consists of a staged removal of the infected catheter, fluid cultures and antibiotic initiation, and eventually insertion of a new catheter after a period of peritoneal rest.<sup>4</sup> The ultimate goal is to preserve the peritoneal membrane at all costs.

**Catheter-related peritonitis:** This complication occurs when the deep cuff is involved in infection and subsequently the infection spreads to the peritoneal cavity resulting in full blown peritonitis that manifests as systemic symptoms (fever, chills), abdominal pain, and PD fluid color changes (→**Fig. 13**). Once peritonitis is suspected, peritoneal fluid cultures are obtained and antibiotic therapy is initiated. The decision of changing the PD catheter is dependent on the response to antibiotic therapy. Therefore, the infected PD catheter can be exchanged over a wire if the patient is responding to appropriate treatment. However, in the absence of response to appropriate treatment, there should be a low threshold for removing the PD catheter as the next step. The rationale for this approach is always to save the peritoneum and prevent further scarring. In daily clinical practice, the lack of improvement after 5 days of antibiotic therapy necessitates immediate catheter removal. There are certain clinical scenarios of peritonitis in which PD catheter removal is indicated. These include fungal peritonitis, refractory or relapsing peritonitis, refractory exit-site/tunnel infections,



**Fig. 13** Peritoneal fluid color in different clinical scenarios.

nonresponse to medical therapy, growth of multiple enteric organisms, and mycobacterial peritonitis cases.

Finally, to avoid or prevent both mechanical and infectious complications, the International Society of Peritoneal Dialysis (ISPD) recommends that programs utilize the best practice guidelines and routinely monitor and audit catheter-related complications at least annually to provide opportunities to improve practices.<sup>4</sup> Specific goals should include catheter patency at 12 months more than 80% for non-laparoscopic insertion, exit-site/tunnel infection within 30 days of insertion less than 5%, peritonitis within 30 days of insertion less than 5%, visceral injury (bladder, bowel) less than 1%, significant hemorrhage requiring transfusion or surgical intervention less than 1%, incidence of pericatheter leaks recorded separately for early PD starts (<14 days) versus late starts (>14 days).<sup>4</sup>

## Conclusion

PD is increasingly used in home dialysis centers in recent years. The PD catheter is a tube system made of a foreign material, which come in multiple different configurations. Once inserted, these catheters are prone to develop complications that can be related either to variations in procedural technique or to infections. In experienced centers, many of these complications can be managed conservatively without the need to remove or replace the catheter remaining mindful of the ultimate goal of preserving the peritoneal membrane. Finally, careful, precise insertion can help avoid common complications, and astute diagnosis and management can salvage the peritoneal membrane with minimal interruption in dialytic therapy.

### Authors' Contributions

All authors contributed equally to this article. All authors read and approved the final manuscript.

### Conflict of Interest

B.P.O.-G. and A.A.: Nothing to disclose.

A.K.A.-A.: Consultant, St Jude Medical; consultant, Boston Scientific; consultant, Bard Peripheral Vascular; consul-

tant, Baxter Healthcare; consultant; Sirtex medical. Unrestricted grants from BTG, Sirtex Medical, Bard peripheral vascular, Medtronic, Boston Scientific. Research grants: Boston Scientific.

## References

- Crabtree JH. Peritoneal dialysis catheter implantation: avoiding problems and optimizing outcomes. *Semin Dial* 2015;28(01):12–15
- Crabtree JH, Chow KM. Peritoneal dialysis catheter insertion. *Semin Nephrol* 2017;37(01):17–29
- Lok CE, Moist L. KDOQI 2019 vascular access guidelines: What is new? *Adv Chronic Kidney Dis* 2020;27(03):171–176
- Crabtree JH, Shrestha BM, Chow KM, et al. Creating and maintaining optimal peritoneal dialysis access in the adult patient: 2019 update. *Perit Dial Int* 2019;39(05):414–436
- Almehmi A. *Interventional Nephrology Primer: Part 2: Peritoneal Dialysis Catheter* ASDIN Endorsed Material. 2020
- Fujiwara M, Soda T, Okada T, Kanamaru H, Inoue T, Ogawa O. Bowel perforation by a peritoneal dialysis catheter: report of two cases. *BMC Nephrol* 2017;18(01):312
- Asif A. Approach to a patient with visceral perforation. In: Yevzlin AS, et al (eds.) *Interventional Nephrology*. New York: Springer Science + Business Media; 2014:319–320
- Narayan R, Fried T, Chica G, Schaefer M, Mullins D. Minimally invasive fluoroscopic percutaneous peritoneal dialysis catheter salvage. *Clin Kidney J* 2014;7(03):264–268
- Goldstein M, Carrillo M, Ghai S. Continuous ambulatory peritoneal dialysis—a guide to imaging appearances and complications. *Insights Imaging* 2013;4(01):85–92
- Jheng JS, Chang CT, Huang CC. Omental wrapping of a peritoneal dialysis catheter. *Kidney Int* 2012;82(07):827
- Yilmaz E, Kurultak I, Ustundag S, Tuncbilek N. Computed tomography findings of peritoneal dialysis related complications. *EJMI* 2019;3(01):19–22
- Nakayama T, Hashimoto K, Kiriya T, Hirano K. Optimal imaging conditions for the diagnosis of pleuroperitoneal communication. *BMJ Case Rep* 2019;12(03):e228940
- Debowski JA, Wærp C, Kjellevoid SA, Abedini S. Cuff extrusion in peritoneal dialysis: single-centre experience with the cuff-shaving procedure in five patients over a 4-year period. *Clin Kidney J* 2017;10(01):131–134
- Crabtree JH, Burchette RJ. Surgical salvage of peritoneal dialysis catheters from chronic exit-site and tunnel infections. *Am J Surg* 2005;190(01):4–8