



# Insight into Noninvasive Radiological Modalities to Detect Heart Transplant Rejection

Dhruva Sharma<sup>1</sup> Ganapathy Subramaniam<sup>2</sup> Neha Sharma<sup>3</sup> Preksha Sharma<sup>4</sup> Pooja Sharma<sup>5</sup>

<sup>1</sup>Department of Cardiothoracic and Vascular Surgery, SMS Medical College and Attached Hospitals, Jaipur, Rajasthan, India

<sup>2</sup>Department of Cardiothoracic Surgery, Institute of Heart and Lung Transplant and Mechanical Circulatory Support, MGM Healthcare, Chennai, Tamil Nadu, India

<sup>3</sup>Department of Pharmacology, SMS Medical College and Attached Hospitals, Jaipur, Rajasthan, India

<sup>4</sup>Department of Anatomy, SMS Medical College and Attached Hospitals, Jaipur, Rajasthan, India

<sup>5</sup>Department of Cardiology, Eternal Heart Care Centre, Jaipur, Rajasthan, India

Address for correspondence Neha Sharma, MD, Department of Pharmacology, SMS Medical College and Attached Hospitals, J.L.N. Marg, Jaipur - 302001, Rajasthan, India  
(e-mail: nsharma226@gmail.com).

Indian J Radiol Imaging 2021;31:946–955.

## Abstract

**Purpose** Patients with end-stage heart failure who remain symptomatic even with exemplary medical and device therapy are treated with heart transplantation. Multitudes of endeavor have been contrived during the last decennium in the field of noninvasive tests to rule out heart transplant rejection (HTR). In spite of having supportive literature, noninvasive imaging techniques lack acceptable documentation of clinical robustness, and endomyocardial biopsy (EMB) still remains the gold standard. The aim of this review is to shed light on the existing noninvasive radiological modalities to detect rejection among heart transplant recipients.

**Methods** A comprehensive search was conducted for this review article on the basis of literature available including scientific databases of PubMed, Embase, and Google Scholar, using keywords of “Heart transplantation,” “Acute allograft rejection,” “Arrhythmias,” “Echocardiography,” “Speckle tracking echocardiography,” and “Cardiac magnetic resonance imaging” from inception until September 2020.

**Results** After preliminary screening of the databases, details regarding existent noninvasive radiological modalities to detect HTR were gathered and compiled in this review article. Currently, deformation imaging using speckle tracking and T2 time using cardiac magnetic resonance imaging can serve as screening tools based on which further invasive investigations can be planned. Standardization of blood-based and imaging modalities as screening and possible diagnostic tools for rejection would have obvious clinical and financial benefits in the care of growing number of post heart transplant recipients in our country.

**Conclusion** Diagnosis of allograft rejection in heart transplant recipients through noninvasive techniques is demanding. To unravel the potential of noninvasive radiological modalities that can serve as a standard-of-care test, a prospective multicentric study randomizing noninvasive modality as first strategy versus current EMB-based gold standard of care is the need of the hour.

## Keywords

- ▶ acute allograft rejection
- ▶ cardiac magnetic resonance imaging
- ▶ echocardiography
- ▶ heart transplantation
- ▶ speckle-tracking echocardiography

published online  
January 11, 2022

DOI <https://doi.org/10.1055/s-0041-1741098>.  
ISSN 0971-3026.

© 2022. Indian Radiological Association. All rights reserved.  
This is an open access article published by Thieme under the terms of the Creative Commons Attribution-NonDerivative-NonCommercial-License, permitting copying and reproduction so long as the original work is given appropriate credit. Contents may not be used for commercial purposes, or adapted, remixed, transformed or built upon. (<https://creativecommons.org/licenses/by-nc-nd/4.0/>)  
Thieme Medical and Scientific Publishers Pvt. Ltd., A-12, 2nd Floor, Sector 2, Noida-201301 UP, India

## Introduction

Patients with end-stage heart failure who remain symptomatic even with exemplary medical and device therapy are treated with heart transplantation (HTx). Although management of heart transplant recipients has profoundly improved with current regimens of immunosuppressive drugs, yet heart transplant rejection (HTR) remains its immense dilemma.<sup>1</sup> HTR when occurs within first 24 hours, it is said as early graft dysfunction, and when it develops weeks to years after transplantation, it is called as late graft dysfunction.

Early graft dysfunction can be primary or secondary while late graft dysfunction includes acute cardiac allograft rejection (ACAR) and cardiac allograft vasculopathy (CAV).

Acute allograft rejection again can be classified as acute cellular rejection (ACR) or antibody-mediated rejection (AMR). Young age, female donor or recipient, and elevated human leukocyte antigen (HLA) mismatches are crucial risk factors for acute allograft rejection.<sup>2</sup> ACAR remains the "Achilles heel" during the first year post cardiac transplantation. ACAR is liable for ~12% of mortality reported between 1 and 12 months of posttransplantation, while 40% of cardiac transplant recipients experience ACAR within this period.<sup>3,4</sup> It is correlated with the evolution of CAV and conclusively deteriorating sequelae.<sup>5</sup>

Thus, early disclosure of ACAR and its restriction is imperative for better survival of cardiac transplant recipients. Routine and frequent surveillance is imperative to detect ACAR as most of the patients remain asymptomatic until and unless hemodynamic compromise occurs.

It is important for surgeons to be up to date especially in the area of noninvasive imaging to provide better clinical care, which can translate into clinical and economic gains by avoiding unnecessary endomyocardial biopsies (EMBs) and doing while it is essential. Multitudes of endeavor have been contrived during the last decennium in the field of noninvasive tests to rule out HTR. In spite of having supportive literature, noninvasive imaging techniques lack acceptable documentation of clinical robustness and EMB still remains the gold standard.

The aim of this review is to shed light on the existing noninvasive radiological modalities to detect rejection among heart transplant recipients.

## Methods

A comprehensive search was conducted for this review article on the basis of literature available including scientific

databases of PubMed, Embase, and Google Scholar, using keywords of "Heart transplantation," "Acute allograft rejection," "Arrhythmias," "Echocardiography," "Speckle-tracking echocardiography," and "Cardiac magnetic resonance imaging" from inception until September 2020.

## Results and Discussion

After preliminary screening of the databases, details regarding existent noninvasive radiological modalities to detect HTR were gathered and compiled in this review article.

### Endomyocardial Biopsy (EMB)

Although EMB remains the gold standard method for ACAR surveillance, yet 20% of patients are reported with histological "false negative" ACAR attributed to sampling error associated with the inhomogeneous nature of ACAR.<sup>6</sup> Customarily, biopsies are executed every week for the first 4 weeks followed by every 2 weeks for the next 6 weeks, which is consequently followed by monthly biopsies for 3 to 4 months and then every 3 months until the end of the first year.

### Histopathological Findings of ACR

A mononuclear inflammatory response is seen in ACR that infiltrates myocardium with predominant lymphocytic cells. CD4 and CD8 positive T-lymphocytes with elevated affinity to interleukin-2 receptors can be established on immunohistologic assessment.

Additionally, cardiac myocytes exhibit existence of marked-up adhesion molecules with high MHC-II expression. However, Quilty lesions that extend to the endocardial surface and include significant B-lymphocytes are one of the differential diagnoses of these findings and are clinically insignificant. Grading of ACR has been elaborated in ►Table 1 as provided by International Society for Heart and Lung Transplantation (ISHLT).<sup>2</sup>

### Histopathological Findings of AMR

Intravascular accretion of macrophages including interstitial edema, hemorrhage, and neutrophilic intrusion in and around capillaries are histological features of AMR. Immunopathologic data of AMR acknowledged the presence of positive immunofluorescent staining for C4d, C3d, and anti-HLA-DR or immunoperoxidase staining for C4d and CD68 (or C3d; ►Table 2).<sup>2</sup> Treatment of AMR is difficult and not standardized; even the diagnosis depends on complement staining. Imaging plays a major role in the management of

**Table 1** Histopathological grading of acute cellular rejection by International Society for Heart and Lung Transplantation

Grade 0	No rejection
Grade 1 R (mild)	Interstitial and/or perivascular infiltrate with up to one focus of myocyte damage (grades 1A, 1B, and 2 in 1990 system)
Grade 2 R (moderate)	Two or more foci of infiltrates with associated myocyte damage (grade 3A in 1990 system)
Grade 3 R (severe)	Diffuse infiltrate with multifocal myocyte damage, with or without edema, hemorrhage, or vasculitis (grades 3B and 4 in 1990 system)

**Table 2** Antibody-mediated rejection (AMR) grading: pathologic diagnosis of cardiac AMR

Grade	Findings
pAMR 0	Negative histologic and immunopathologic findings
pAMR 1 (H <sup>+</sup> ) pAMR 1 (I <sup>+</sup> )	Histologic findings are present and immunopathologic findings are negative Histologic findings are negative and immunopathologic findings are positive (CD68+ and/or C4d +)
pAMR 2	Presence of both histologic and immunopathologic findings
pAMR 3	Presence of severe histologic plus immunopathologic findings

AMR,<sup>2,7</sup> as the treatment relies on the presence of dysfunction whether clinical or subclinical. The biopsy findings of AMR in the absence of any dysfunction are still a gray area for initiation of therapy.

However, conventional ISHLT histologic grade at no time contributes to longer-term risk stratification, surveillance testing, and immunosuppression-weaning protocols that cannot be stipulated to individual ACAR risk.<sup>8</sup>

Less invasive techniques than conventional biopsy like newer echocardiographic techniques, cardiac magnetic resonance imaging (CMR), and positron emission tomography have shown promise in excluding rejection.<sup>9</sup> It has been suggested that a typical management plan post cardiac transplantation involves more than 10 EMBs in the first year, which imposes the risk for serious complications.<sup>10,11</sup>

### Echocardiography in ACAR Monitoring

Echocardiography is a universal tool for ACAR monitoring. The preeminent echocardiographic variables intended for diagnosis of allograft rejection include increased wall thickness and wall echogenicity, pericardial effusion, left ventricular (LV) diastolic dysfunction, and regional/global LV systolic dysfunction.<sup>12</sup> Although indices like LV size, wall thickness, mass, pericardial effusion, and ejection fraction are insensitive markers of ACAR, Doppler indices of mitral valve inflow are the most extensively investigated parameter for detecting ACAR.<sup>12,13</sup> Transplanted heart reveals increased size of both the atria along with an echo-dense ridge at the site of anastomosis between the residual recipient atrial tissue and the donor atria. Increased left ventricular mass (LVM) may be because of repetitive rejections, arterial hypertension, immunosuppressive therapy, chronic tachycardia, and denervation. Left ventricular hypertrophy (LVH) is a predictor of mortality.<sup>13</sup> Valvular regurgitation and tricuspid valve regurgitation is often noted immediately after heart transplant.<sup>14</sup> Early right ventricular (RV) dilation and linked hemodynamic reformation improve progressively within a week after HTx,<sup>15</sup> while moderate to large pericardial effusion might be seen because of donor and recipient heart mismatch or because of development of acute allograft rejection.

Echocardiography is highly operator-dependent imaging modality. Tissue Doppler parameters, like peak systolic wall motion velocity and diastolic wall motion velocity, were reported to have very high sensitivities and specificities for ACAR by Dandel et al.<sup>16</sup> But contradictory results were also

reported, with low sensitivities and specificities, by employing the similar parameters.<sup>17</sup>

Echocardiography is usually performed in the intraoperative period and early postoperative period to rule out early dysfunction of the graft. There is increased LV wall thickness seen usually after 1 month posttransplantation, which gradually normalizes at the end of 3 months. But if LV wall thickness increases rapidly and persists, then it warrants further investigation.<sup>13,18</sup>

Posttransplant severe LVH (LVM > 250 g) is suggested as a strong predictor of mortality when detected through transthoracic echocardiography among 141 heart transplant recipients.<sup>13</sup>

Since left ventricular ejection fraction (LVEF) might remain normal in the context of biopsy-proven ACR, conventional two-dimensional transthoracic echocardiography is thus deficient in detecting ACR. Nevertheless, evaluation of LV strain and strain rate with the help of tissue Doppler imaging has been noted in some studies to be sensitive in detecting mild form, but the technique lacks reproducibility and accuracy.<sup>19,20</sup> Speckle tracking aims to address these concerns and make it observer independent.

Reporting of numerous echocardiographic indices—in conjunction with (among others) LV end-diastolic and end-systolic volumes, ejection fraction, septal and thicknesses of inferolateral wall, valvar regurgitation assessment, *E, A*, and pulmonary vein Doppler flow velocities, left atrial volume, mitral *s'* and *e'* wave tissue Doppler velocities, global longitudinal strain (GLS), pericardial effusion, and measures of RV function, including wall thickness, tricuspid annular systolic excursion, fractional area change, *s'* tissue velocity, and longitudinal strain—has been mandated by The European Association of Cardiovascular Imaging.<sup>21–23</sup>

### What Is Strain, Strain Rate, and Speckle-Tracking Imaging—The Deformation Imaging?

The myocardial fibers adjacent to the endocardium are oriented longitudinally from base to apex, and during longitudinal shortening the base is pulled toward the apex. The mid wall muscles are oriented circularly, and contraction results in radial shortening or decrease in diameter of the ventricular cavity. The muscles adjacent to epicardium are oriented approximately at 60° in relation to the fibers of the mid wall and shortening results in twisting motion—the basal segments rotate clockwise, and the apex rotates counter clockwise.

Traditional methods of assessing LV function—ejection fraction and fractional shortening do not elucidate regional variations in contractility or the different forms of contraction—the longitudinal, radial, and twisting contraction. It gives no idea of diastolic function, which is increasingly being recognized as the first to be affected in various pathologies including rejection.

The focus on regional wall “motion” can help us pick up early changes in myocardial contractility and has obvious importance in the management of coronary artery disease. Myocardial motion has two components—the distance traveled and the velocity. Pulsed tissue Doppler measures myocardial motion and velocity. This is routinely done to measure the velocity of the mitral annulus that moves toward the apex and then recoils to its starting position. Mitral annulus velocity is an important measure of global longitudinal function. The disadvantage is that since the myocardium is interconnected, even “dead” myocardium may show motion as it can move with surrounding normal myocardium.

The solution is to use “deformation” as a measure; the “dead” myocardium will not deform during systole or diastole irrespective of the motion of the surrounding myocardium. Measuring deformation has proven superior to measuring motion and that is what is measured by strain, strain rate, and speckle-tracking imaging.

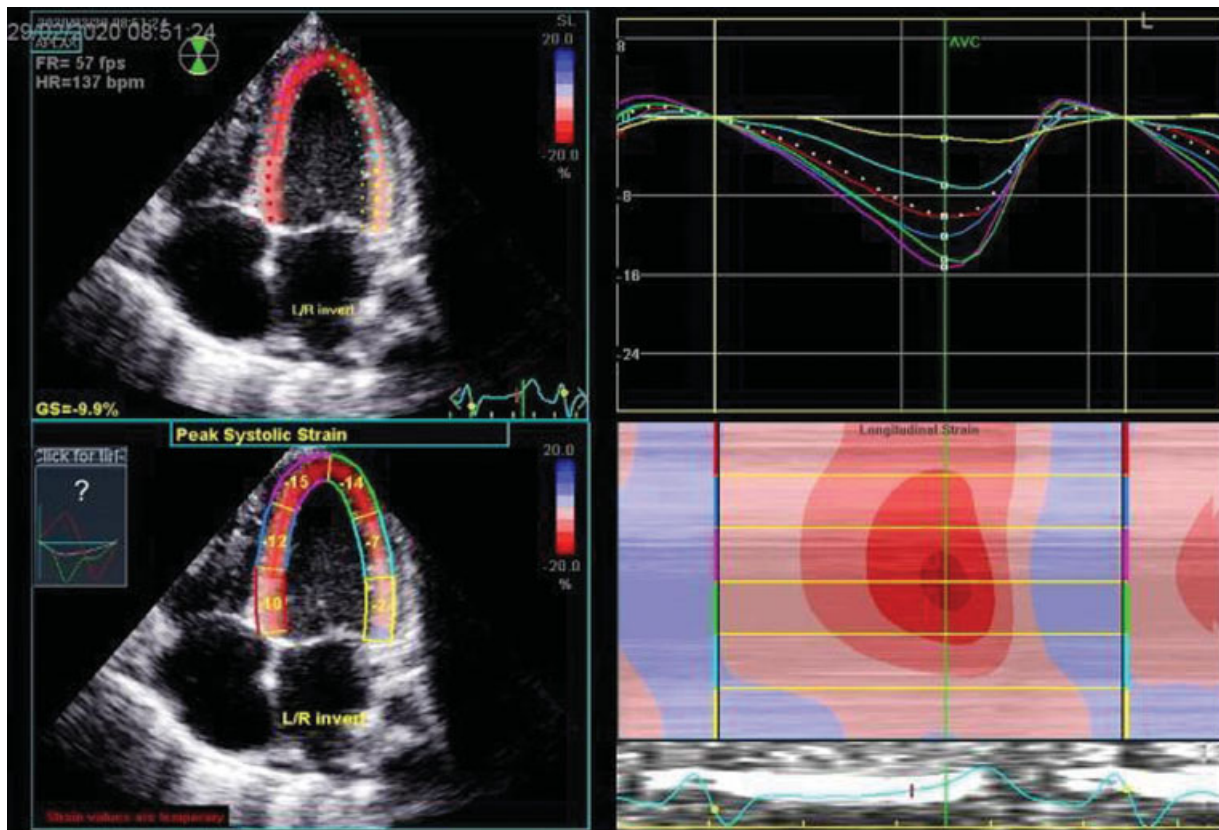
Strain is the amount of shortening (systole) or lengthening (diastole) of the myocardium, which is the difference in

the final length compared with the initial length so the value is negative for systole and is positive for diastole. The speed at which this occurs is the strain rate. The strain uses pulsed wave Doppler and is angle dependent. As the longitudinal fibers are parallel to the direction of the Doppler wave in apical view, longitudinal strain is the most commonly used and standardized measure of strain. Myocardium displays a nonhomogeneous structure on ultrasound, creating speckles. Analyzing the way they move is called speckle tracking and has replaced Doppler to measure strain and strain rate. Speckle tracking does not depend on Doppler, so is not dependent on the angle of insonation. Strain is defined as the distance between two speckle points divided by the initial distance.<sup>24</sup>

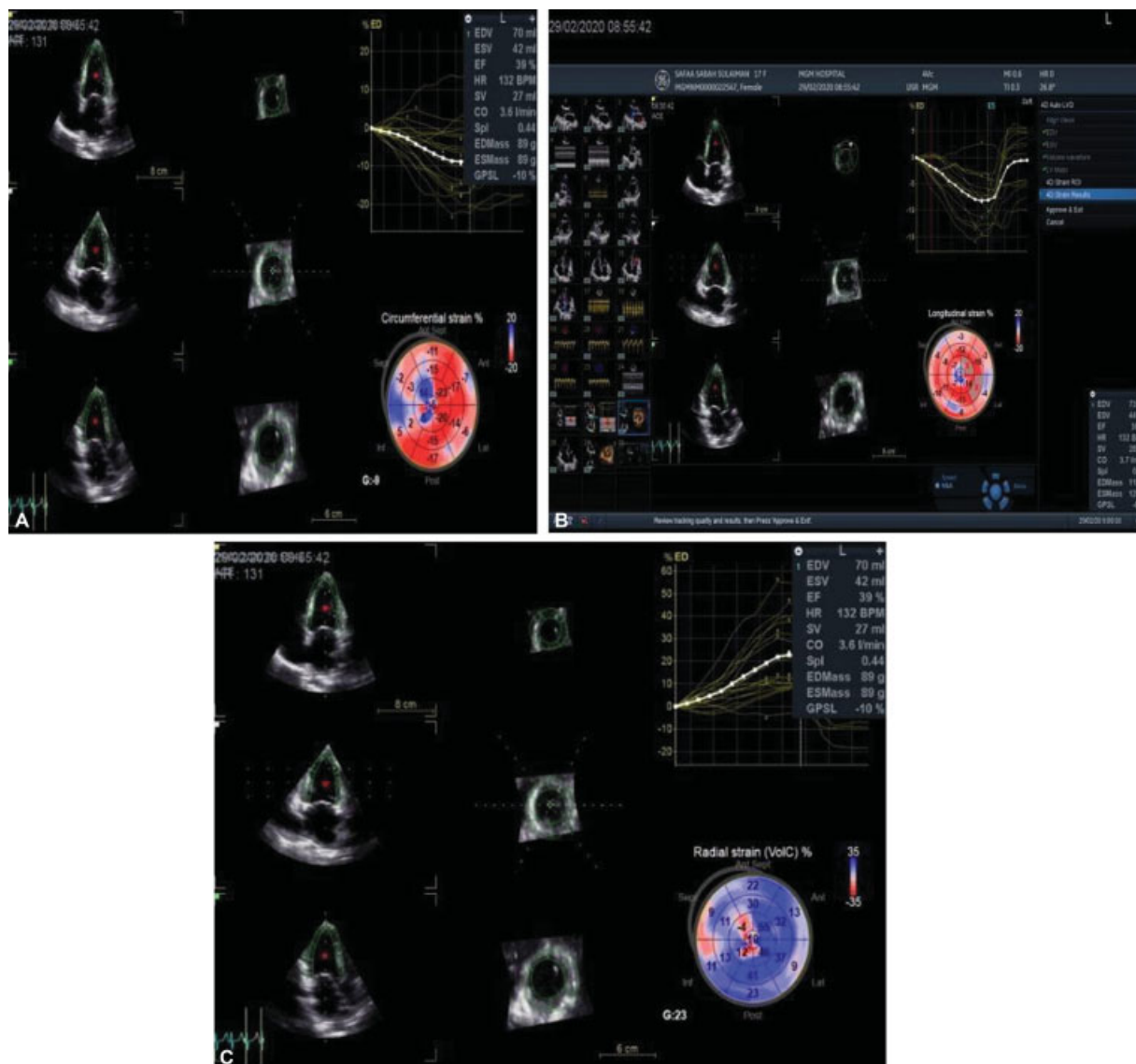
**Speckle-Tracking Echocardiography in ACAR Detection**

Speckle-tracking echocardiography is progressively employed to assess strain following HTx and may assist in the disclosure of rejection and CAV.<sup>25-27</sup> Presence of abnormal longitudinal strain with a compensatory increase in circumferential strain (CS) parameters was seen in the early post-HTx period. These changes in echocardiography will be normalized by 1 year post transplant and remains the same over time in the absence of graft complications (→Figs. 1 and 2A-C).

Tseng et al exemplified the utility of two-dimensional speckle-tracking echocardiography (2D-STE) to anticipate



**Fig. 1** Image showing ventricular function in a post heart transplant recipient using three-dimensional speckle-tracking echocardiography in “Bull’s eye plot” fashion showing reduced global strain; this patient had acute cellular rejection confirmed by endomyocardial biopsy.



**Fig. 2** (A–C) Images showing circumferential, longitudinal, and radial strain calculated by automated two-dimensional speckle tracking. Note that the radial strain is blue predominantly as the final length is higher than the initial length resulting in positive value; both in longitudinal and circumferential strain, the final length is smaller than the initial length resulting in negative value and varying degrees of red color. The strain represents the final length minus the initial length, divided by the initial length. This image is from a patient with acute cellular rejection, 18 months post heart transplantation showing reduction in longitudinal and circumferential strain and preservation of radial strain.

severe rejection in heart transplant recipients with preserved LVEF. Strain analysis revealed significantly elevated early diastolic longitudinal strain rate ( $p=0.02$ ) and decreased global circumferential strain (GCS;  $p<0.001$ ) and GCS rate ( $p=0.02$ ) for the rejection group compared with the control group. The sensitivity and specificity of GCS to detect severe acute rejection were observed as 81.8 and 68.4%, respectively.<sup>25</sup>

A momentous decline in GLS was noted in a meta-analysis reported by Elkaryoni et al. The study revealed a significant difference in GLS between patients who did and did not have ACR proven by biopsy (weighted mean differences = 2.18; 95% confidence interval [CI]: 1.57–2.78,  $p<0.001$ ;  $I^2=76\%$ ). The comprehensive sensitivity for GLS in detecting ACR was 78% (95% CI: 63–90%,  $p=0.123$ ;  $I^2=52.2\%$ ) while

the overall specificity was 68% (95% CI: 50–83%,  $p<0.001$ ;  $I^2=88.3\%$ ).<sup>5</sup>

Results of another meta-analysis showed that HTx patients with rejection had significantly lower GLS than rejection-free subjects. They further demonstrated that myocardial strain parameters derived from 2D-STE might be a convenient tool in detection of ACAR in HTx patients. The present results provide affirmative evidence to consider the routine use of GLS, CS, and RV free wall motion as markers of graft function involvement during ACAR.<sup>26</sup>

Moreover, two studies reported that GLS was not mitigated among patients with ACR as compared with no ACR.<sup>25,28</sup>

The use of GLS appraisal as a noninvasive imaging modality in routine post-HTR surveillance was also reported in other studies (► **Table 3**).

**Table 3** Studies showing echocardiography as a noninvasive imaging modality in routine post heart transplant rejection surveillance

Reference study	No. of heart transplant recipients	Type of study	Parameters studied	Inference from the study
Tseng et al (2018) <sup>25</sup>	65 adult heart transplant recipients with preserved ejection fraction (>55%)	Retrospective study, single centered	LV-GLS, GLSR, GCS, and GCSR	Increased early diastolic longitudinal strain rate ( $p = 0.02$ ); decreased GCS ( $p < 0.001$ ) and GCSR ( $p = 0.02$ ); AUC for GCS 0.77; GCS cutoff of $-17.60\%$ ; sensitivity 81.8%, and specificity of GCS 68.4%
Antończyk et al (2018) <sup>38</sup>	45 heart transplant recipients	Prospective study, single centered	RV FW, 4CH LS, SRS	RV FW $\leq 16.8\%$ and 4CH LS $\leq 13.8\%$
Sade et al (2019) <sup>39</sup>	49 heart transplant recipients	Retrospective study, single centered	16-segment - GLS and CS, later on validated with CMR	T1 time 71,090 milliseconds, extracellular volume 732%, GLS $> -14\%$ , and global circumferential strain 724% had 100% sensitivity and 100% NPV to define grade 2 rejection; the combination of GLS $> -16\%$ and T1 time 71,060 milliseconds defined grade 1 rejection with 91% sensitivity and 92% NPV
Mingo-Santos et al (2015) <sup>40</sup>	34 heart transplant recipients	Prospective study, single centered	Speckle-tracking-derived LV longitudinal, radial, and circumferential strain; and global and free wall right ventricular (RV) longitudinal strain	Lower absolute values of global LV longitudinal strain and free wall RV LV longitudinal strain $< 15.5\%$ had 85.7% sensitivity, 81.4% specificity, 98.8% NPV, and 25.0% PPV for 2R ACR; free wall RV longitudinal strain $< 17\%$ had 85.7% sensitivity, 91.1% specificity, 98.8% NPV, and 42.9% PPV for 2R ACR
Clemmensen et al (2014) <sup>19</sup>	34 heart transplant recipients	Retrospective study, single centered	GLS	A significant difference in GLS was observed comparing the groups with OR ( $-15.5\%$ ; 95% confidence interval [CI], $-16.2\%$ to $-14.2\%$ ), IR ( $-15.3\%$ ; 95% CI, $-16.0\%$ to $-14.6\%$ ), and 2R ( $-13.8\%$ ; 95% CI, $-14.6\%$ to $-12.9\%$ ) rejection ( $p < 0.0001$ )
Ruiz Ortiz et al (2015) <sup>41</sup>	20 heart transplant recipients	Prospective study, single centered	Average radial strain	Significantly lower values of average radial strain were found with higher grades of ACR (29.1 $\pm$ 7.7%, 23.2 $\pm$ 8.5%, and 14.3 $\pm$ 8.8% for grades OR, 1R, and 2R of ACR, $p = 0.001$ ); average deformation was similar for controls versus transplanted patients, in the absence of acute rejection: radial 29.1 $\pm$ 10.0% versus 29.1 $\pm$ 7.7%, $p = 0.98$ ; circumferential $-19.3 \pm 3.2\%$ versus $-20.2 \pm 5.9\%$ , $p = 0.62$ ; and longitudinal $-20.7 \pm 4.1\%$ versus $-18.5 \pm 5.4\%$ , $p = 0.19$ ; an average radial strain $< 25\%$ presented 100% sensitivity, 48% specificity, 6% PPV, and 100% NPV for the presence of 2R rejection (AUC = 0.80, 95% CI, 0.60–0.99, $p = 0.048$ )
Clemmensen et al (2015) <sup>42</sup>	178 heart transplant recipients	Retrospective study, single centered	GLS	Significantly decreasing GLS compared with rejection groups (GLS group 1: $-16.8 \pm 2.4\%$ ); GLS group 2: $-15.9 \pm 3.3\%$ ); GLS group 3: $-14.5 \pm 2.9\%$ ), $p = 0.0003$ )

Abbreviations: 4CH LS, 4-chamber longitudinal strain; AUC, area under the curve; CMR, cardiac magnetic resonance imaging; CS, circumferential strain; GCS, global circumferential strain; GLS, global longitudinal strain; GLSR, global longitudinal strain rate; LV, left ventricular; NPV, negative predictive value; PPV, positive predictive value; RV FW, RV free wall longitudinal strain; SRS, Strain Rejection Score.

### Cardiac Magnetic Resonance Imaging (CMR) in ACAR Detection

ACR can be detected by emerging biomarkers: myocardial T1 and T2 values derived from CMR. An Indian study mentioned standardized T1 and T2 mapping values as 900 to 1,020 milliseconds and 43 to 55 milliseconds, respectively, at 1.5 Tesla magnetic resonance imaging (MRI), for normal population.<sup>29</sup>

Evolution of creeping detrimental remodeling among heart transplant recipients can be tracked through appraisal of structural and functional changes over time to facilitate the detection of ACR by CMR. Studies projecting CMR as a noninvasive imaging modality in routine post-HTR surveillance have been depicted in **Table 4**.

CMR can help in detection of edema, inflammatory transformation, development of fibrosis, and forecast of mortality through volumetric estimation of ventricles.<sup>30</sup>

### What Is T1 and T2 Relaxation Time and How Does It Help Interpret Rejection?

Magnetic resonance (MR) utilizes the spin property of protons of hydrogen to elicit images. Hydrogen is abundant in the body in the form of water and fat. In the absence of any external magnetic field, the hydrogen atoms are spinning in haphazard fashion and cancel all magnetization; when external magnetic field is applied, the hydrogen atoms align in one direction—either parallel or antiparallel to the magnetic field. This can be manipulated by using radiofrequency pulse, which changes the magnetization; when the pulse is stopped, the atoms return to their original state emitting radiofrequency signal in the process, which is detected by using receiving coils. This property is used in MRI. T1 is longitudinal relaxation and T2 is transverse relaxation; the T1 includes the T2 relaxation period also, hence is always longer than T2 time. This property is related to the amount of fluid present in the tissue, and increase in T2 time more consistently and T1 time in some studies has been shown to correlate with rejection. Using T1 with contrast, extracellular volume fraction (ECV) can be calculated, which has been found to correlate with rejection. Using these criteria to decide in whom EMB needs to be done can reduce the need of biopsies by almost 70%. Only ~5% of the biopsies would be performed that would yield normal results and with normal values of both, the rejection is unlikely.<sup>31</sup>

T2 relaxation time, T2 short time inversion recovery intensity, T1 myocardial contrast enhancement, late gadolinium enhancement (LGE), and peak systolic CS are five parameters of CMR that were applied in different studies to detect moderate ACAR (rejection grade ?2). Out of these parameters, T2 value related to myocardial edema was the most widely used parameter.

Recently, it has been published in a prospective study among 58 heart transplant recipients with 14 control subjects that T2 was significantly higher in patients with past ACAR compared with those with no ACAR (51.0 ? 3.8 milliseconds versus 49.2 ? 4.0 milliseconds;  $p = 0.02$ ). CMR, global T2, and global ECV were predictive of ACAR (area under the curve = 0.84).<sup>10</sup>

Similar encouraging results were reported by Vermes et al. They proposed that an elevated diagnostic accuracy for surveillance of acute rejection is obtained by an integrated CMR approach utilizing T2 mapping and ECV quantification that could potentially decrease the number of routine EMB among heart transplant patients.<sup>31</sup> However, Şimşek et al found in their prospective study among heart transplant recipients that there was no correlation between late LGE and ACR ( $p = 0.879$ ).<sup>32</sup> Similarly, Greenway et al in their pilot study among 30 pediatric heart transplant recipients with 14 control subjects demonstrated that CMR did not reliably identify ACR-related changes in pediatric HTx patients.<sup>33</sup>

Improvements in cardiac imaging techniques have proved the fact how artificial intelligence has prepared a new paradigm for substantial data-driven scrutiny in cardiac-transplantation research.<sup>34</sup> A rapid MRI protocol should be entrenched to lessen the time span of cardiac MR examination extensively, thus enabling execution of myocardial tissue characterization without the exigency for gadolinium contrast.

The use of CMR as a noninvasive imaging modality in routine post-HTR surveillance has been elaborated (**Table 3**).

Gadolinium-based contrast agents on repeated administration to patients with renal insufficiency triggered development of nephrogenic systemic fibrosis. Additionally, gadolinium deposition is observed in brains. However, it is a matter of concern because it poses a risk for the development of vascular emboli.<sup>35,36</sup>

### Surveillance of Heart Transplant Rejection in COVID-19 Era

The surfacing of coronavirus disease 2019, or COVID-19, has posed a substantial impact on HTx. It has heightened the safety affair of patient as well as surgical team. Owing to the invasive nature of EMB, the Indian Society of Heart and Lung Transplantation has suggested that routine biopsies may be protracted for 2 to 3 months in asymptomatic recipients.<sup>37</sup>

Using noninvasive investigative modalities, which have high negative predictive value, up to 70 to 80% of EMB can be avoided without compromising clinical outcome. The expertise for performing and interpreting EMB is not widely available, and travel for getting a routine EMB is difficult and risky in times of current pandemic. In situation like this and in a country like India, monitoring rejection using noninvasive and observer-independent modalities like cell-free deoxyribonucleic acid, automated speckle-tracking strain analysis, and T2 recovery time will help greatly improve clinical outcomes.

### Conclusion

Diagnosis of allograft rejection in heart transplant recipients through noninvasive techniques is demanding. To unravel the potential of noninvasive radiological modalities that can serve as a standard-of-care test, a prospective multicentric study randomizing noninvasive modality as first strategy versus current EMB-based gold standard of care is the need of

**Table 4** Studies projecting CMR as a noninvasive imaging modality in routine post heart transplant rejection surveillance

Reference study	No. of heart transplant recipients	Parameters studied	Inference from the study
Krieghoff et al (2014) <sup>43</sup>	146 examinations in 73 patients	ER T1-weighted gRE LGE	Sensitivity, specificity, PPV, and NPV were as follows: ER: 63%, 78%, 30%, and 93%; gRE: 63%, 70%, 24%, and 93%; LGE: 68%, 36%, 13%, and 87%; with the combination of ER and gRE with at least one out of two positive: 84%, 57%, 23%, and 96%; ROC analysis revealed an AUC of 0.724 for ER and 0.659 for gRE
Dolan et al (2019) <sup>10</sup>	97 CMR studies from 58 heart transplant recipients and 14 controls	Global left ventricular function and myocardial T2, T1, and ECV	Myocardial T2 was significantly higher in patients with past ACAR compared with those with no ACAR (51.0 ± 3.8 milliseconds versus 49.2 ± 4.0 milliseconds; <i>p</i> = 0.02); ECV was significantly elevated in ACAR+ patients
Butler et al (2014) <sup>30</sup>	60 participants with 73 studies	T2 relaxation time and right ventricular end-diastolic volume index	Combining threshold right ventricular end-diastolic volume index and edema values predicted a positive EMB with very good accuracy: sensitivity, 93%; specificity, 78%; PPV, 52%; and NPV, 98%; CMR was more sensitive than EMB at predicting clinical rejection (sensitivity of 67% versus 58%)
Vermes et al (2018) <sup>31</sup>	20 participants with 31 studies	Global and segmental T2 and T1 values were measured	Patients with acute rejection had significantly higher global T2 values at 3 levels: (AUC) for each level (basal, median, apical level) was 0.83, 0.79, and 0.78, respectively, and higher ECV at basal level: AUC = 0.84; the sensitivity, specificity, and diagnosis accuracy for basal T2 (cut off: 57.7 milliseconds) were 71, 96, and 90%, respectively; and for basal ECV: (cutoff 32%) were 86, 85, and 85%, respectively
Imran et al (2019) <sup>44</sup>	112 biopsies	T1 maps were acquired at 1.5-T	Using a T1 cutoff value of 1,029 milliseconds, the sensitivity, specificity, and NPV were 93, 79, and 99%, respectively
Sethi et al (2020) <sup>45</sup>	11 pediatric patients, 18 studies	Volumetry, flow, and T2 mapping	The five rejection cases had significantly higher mean T2 values compared with cases without rejection (58.3 ± 4 milliseconds versus 53 ± 2 milliseconds, <i>p</i> = 0.001)

Abbreviations: ACAR, acute cardiac allograft rejection; AUC, area under the curve; CMR, cardiac magnetic resonance imaging; ECV, extracellular volume fraction; EMB, endomyocardial biopsy; ER, edema ratio; gRE, global relative enhancement; LGE, late gadolinium enhancement; NPV, negative predictive value; PPV, positive predictive value; ROC analysis, receiver operating characteristic analysis.



the hour. Furthermore, meticulous standardization of techniques across sites will be enforced. Additionally, it should be able to prove its cost effectiveness. Moreover, the radiological modalities should be able to confront other noninvasive blood-based modalities to detect rejection.

Currently, deformation imaging using speckle tracking and T2 time using CMR can serve as screening tools based on which further invasive investigations can be planned. Standardization of blood-based and imaging modalities as screening and possible diagnostic tools for rejection would have obvious clinical and financial benefits in the care of growing number of post heart transplant recipients in our country.

#### Conflicts of Interest

There are no conflicts of interest.

#### References

- Sharma D, Sharma N. A potential drug in the armamentarium of post-cardiac transplantation immunosuppression: belatacept. *Indian J Thorac Cardiovasc Surg* 2020;36(06):625–628
- Ludhwani D, Kanmanthareddy A. Heart Transplantation Rejection [Updated 2020 Jun 5]. In: StatPearls [Internet]. Treasure Island, FL: StatPearls Publishing; 2020 Jan-. Available from: <https://www.ncbi.nlm.nih.gov/books/NBK537057/>
- Lu W, Zheng J, Pan XD, et al. Diagnostic performance of cardiac magnetic resonance for the detection of acute cardiac allograft rejection: a systematic review and meta-analysis. *J Thorac Dis* 2015;7(03):252–263
- Patel JK, Kobashigawa JA. Should we be doing routine biopsy after heart transplantation in a new era of anti-rejection? *Curr Opin Cardiol* 2006;21(02):127–131
- Elkaryoni A, Altibi AM, Khan MS, et al. Global longitudinal strain assessment of the left ventricle by speckle tracking echocardiography detects acute cellular rejection in orthotopic heart transplant recipients: a systematic review and meta-analysis. *Echocardiography* 2020;37(02):302–309
- Tang Z, Kobashigawa J, Rafiei M, Stern LK, Hamilton M. The natural history of biopsy-negative rejection after heart transplantation. *J Transplant* 2013;2013:236720. Doi: 10.1155/2013/236720
- Berry GJ, Burke MM, Andersen C, et al. The 2013 International Society for Heart and Lung Transplantation Working Formulation for the standardization of nomenclature in the pathologic diagnosis of antibody-mediated rejection in heart transplantation. *J Heart Lung Transplant* 2013;32(12):1147–1162
- Peyster EG, Wang C, Ishola F, et al. In situ immune profiling of heart transplant biopsies improves diagnostic accuracy and rejection risk stratification. *JACC Basic Transl Sci* 2020;5(04):328–340
- Olymbios M, Kwiecinski J, Berman DS, Kobashigawa JA. Imaging in heart transplant patients. *JACC Cardiovasc Imaging* 2018;11(10):1514–1530
- Dolan RS, Rahsepar AA, Blaisdell J, et al. Multiparametric cardiac magnetic resonance imaging can detect acute cardiac allograft rejection after heart transplantation. *JACC Cardiovasc Imaging* 2019;12(8 Pt 2):1632–1641
- Costanzo MR, Dipchand A, Starling R, et al; International Society of Heart and Lung Transplantation Guidelines. The International Society of Heart and Lung Transplantation Guidelines for the care of heart transplant recipients. *J Heart Lung Transplant* 2010;29(08):914–956
- Frigerio M, Pedrazzini G, Merli M, Vitali E. Heart transplantation. In: Savonitto S, ed. *Niguarda Cardiovascular Therapy*. Roma: Il Pensiero Scientifico Editore; 2006:437–75
- Goodroe R, Bonnema DD, Lunsford S, et al. Severe left ventricular hypertrophy 1 year after transplant predicts mortality in cardiac transplant recipients. *J Heart Lung Transplant* 2007;26(02):145–151
- Mondillo S, Maccherini M, Galderisi M. Usefulness and limitations of transthoracic echocardiography in heart transplantation recipients. *Cardiovasc Ultrasound* 2008;6:2. Doi: 10.1186/1476-7120-6-2
- Bhatia SJ, Kirshenbaum JM, Shemin RJ, et al. Time course of resolution of pulmonary hypertension and right ventricular remodeling after orthotopic cardiac transplantation. *Circulation* 1987;76(04):819–826
- Dandel M, Hummel M, Müller J, et al. Reliability of tissue Doppler wall motion monitoring after heart transplantation for replacement of invasive routine screenings by optimally timed cardiac biopsies and catheterizations. *Circulation* 2001;104(12, Suppl 1):I184–I191
- Palka P, Lange A, Galbraith A, et al. The role of left and right ventricular early diastolic Doppler tissue echocardiographic indices in the evaluation of acute rejection in orthotopic heart transplant. *J Am Soc Echocardiogr* 2005;18(02):107–115
- Wilhelmi M, Pethig K, Wilhelmi M, Nguyen H, Strüber M, Haverich A. Heart transplantation: echocardiographic assessment of morphology and function after more than 10 years of follow-up. *Ann Thorac Surg* 2002;74(04):1075–1079, discussion 1079
- Clemmensen TS, Eiskjær H, Kofoed-Nielsen PB, Høyer S, Poulsen SH. Case of acute graft failure during suspected humoral rejection with preserved ejection fraction, but severely reduced longitudinal deformation detected by 2D-speckle tracking. *Case Rep Transplant* 2014;2014:173589. Doi: 10.1155/2014/173589
- Kato TS, Oda N, Hashimura K, et al. Strain rate imaging would predict sub-clinical acute rejection in heart transplant recipients. *Eur J Cardiothorac Surg* 2010;37(05):1104–1110
- Friedberg MK. Echocardiographic detection of heart transplant graft dysfunction: a new twist on an old theme. *Circ Cardiovasc Imaging* 2016;9(09):e005439. Doi: 10.1161/CIRCIMAGING.116.005439
- Badano LP, Miglioranza MH, Edvardsen T, et al; Document reviewers. European Association of Cardiovascular Imaging/Cardiovascular Imaging Department of the Brazilian Society of Cardiology recommendations for the use of cardiac imaging to assess and follow patients after heart transplantation. *Eur Heart J Cardiovasc Imaging* 2015;16(09):919–948
- Smith JD, Stowell JT, Martínez-Jiménez S, et al. Evaluation after orthotopic heart transplant: what the radiologist should know. *Radiographics* 2019;39(02):321–343
- Dandel M, Lehmkuhl H, Knosalla C, Suramelashvili N, Hetzer R. Strain and strain rate imaging by echocardiography - basic concepts and clinical applicability. *Curr Cardiol Rev* 2009;5(02):133–148
- Tseng AS, Gorski US, Barros-Gomes S, et al. Use of speckle-tracking echocardiography-derived strain and systolic strain rate measurements to predict rejection in transplant hearts with preserved ejection fraction. *BMC Cardiovasc Disord* 2018;18(01):241
- Zhu S, Li M, Tian F, et al. Diagnostic value of myocardial strain using two-dimensional speckle-tracking echocardiography in acute cardiac allograft rejection: a systematic review and meta-analysis. *Echocardiography* 2020;37(04):561–569
- Mirabet S, García-Osuna A, Garcia de Frutos P, et al. High-sensitivity troponin T and soluble form of AXL as long-term prognostic biomarkers after heart transplantation. *Dis Markers* 2018;2018:6243529. Doi: 10.1155/2018/6243529
- Ambardekar AV, Alluri N, Patel AC, Lindenfeld J, Dorosz JL. Myocardial strain and strain rate from speckle-tracking echocardiography are unable to differentiate asymptomatic biopsy-proven cellular rejection in the first year after cardiac transplantation. *J Am Soc Echocardiogr* 2015;28(04):478–485

- 29 Ojha V, Nakra T, Narwal A, et al. Noninvasive detection of cardiac transplant rejection using cardiovascular magnetic resonance: correlation with endomyocardial biopsy. *J Pract Cardiovasc Sci* 2020;6:87–89
- 30 Butler CR, Kim DH, Chow K, et al. Cardiovascular MRI predicts 5-year adverse clinical outcome in heart transplant recipients. *Am J Transplant* 2014;14(09):2055–2061
- 31 Vermes E, Pantaléon C, Auvet A, et al. Cardiovascular magnetic resonance in heart transplant patients: diagnostic value of quantitative tissue markers: T2 mapping and extracellular volume fraction, for acute rejection diagnosis. *J Cardiovasc Magn Reson* 2018;20(01):59
- 32 Şimşek E, Nalbantgil S, Ceylan N, et al. Diagnostic performance of late gadolinium enhancement in the assessment of acute cellular rejection after heart transplantation. *Anatol J Cardiol* 2016;16(02):113–118
- 33 Greenway SC, Dallaire F, Kantor PF, et al. Magnetic resonance imaging of the transplanted pediatric heart as a potential predictor of rejection. *World J Transplant* 2016;6(04):751–758
- 34 Battikha CE, Selevany I, Kim PJ. Advances and new insights in post-transplant care: from sequencing to imaging. *Curr Treat Options Cardiovasc Med* 2020;22:32. Doi: 10.1007/s11936-020-00828-8
- 35 Garcia J, Liu SZ, Louie AY. Biological effects of MRI contrast agents: gadolinium retention, potential mechanisms and a role for phosphorus. *Philos Trans- Royal Soc, Math Phys Eng Sci* 2017;375(2107):20170180. Doi: 10.1098/rsta.2017.0180
- 36 Idée J-M, Fretellier N, Robic C, Corot C. The role of gadolinium chelates in the mechanism of nephrogenic systemic fibrosis: a critical update. *Crit Rev Toxicol* 2014;44(10):895–913
- 37 Krishna Gokhale AG, Balakrishnan KR, Punnen J, et al. Recommendations of the INSHLT task force for thoracic organ transplant during COVID-19 pandemic in India. *J Pract Cardiovasc Sci* 2020;6:108–110
- 38 Antończyk K, Niklewski T, Antończyk R, Zakliczyński M, Zembala M, Kukulski T. Speckle-tracking echocardiography for monitoring acute rejection in transplanted heart. *Transplant Proc* 2018;50(07):2090–2094
- 39 Sade LE, Hazirolan T, Kozan H, et al. T1 mapping by cardiac magnetic resonance and multidimensional speckle-tracking strain by echocardiography for the detection of acute cellular rejection in cardiac allograft recipients. *JACC Cardiovasc Imaging* 2019;12(8 Pt 2):1601–1614
- 40 Mingo-Santos S, Moñivas-Palomero V, Garcia-Lunar I, et al. Usefulness of two-dimensional strain parameters to diagnose acute rejection after heart transplantation. *J Am Soc Echocardiogr* 2015;28(10):1149–1156
- 41 Ruiz Ortiz M, Peña ML, Mesa D, et al. Impact of asymptomatic acute cellular rejection on left ventricle myocardial function evaluated by means of two-dimensional speckle tracking echocardiography in heart transplant recipients. *Echocardiography* 2015;32(02):229–237
- 42 Clemmensen TS, Løgstrup BB, Eiskjaer H, Høyer S, Poulsen SH. The long-term influence of repetitive cellular cardiac rejections on left ventricular longitudinal myocardial deformation in heart transplant recipients. *Transpl Int* 2015;28(04):475–484
- 43 Kriehoff C, Barten MJ, Hildebrand L, et al. Assessment of sub-clinical acute cellular rejection after heart transplantation: comparison of cardiac magnetic resonance imaging and endomyocardial biopsy. *Eur Radiol* 2014;24(10):2360–2371
- 44 Imran M, Wang L, McCrohon J, et al. Native T1 mapping in the diagnosis of cardiac allograft rejection: a prospective histologically validated study. *JACC Cardiovasc Imaging* 2019;12(8 Pt 2):1618–1628
- 45 Sethi N, Doshi A, Doshi T, et al. Quantitative cardiac magnetic resonance T2 imaging offers ability to non-invasively predict acute allograft rejection in children. *Cardiol Young* 2020;30(06):852–859