

Deep Brain Stimulation for Morbid Obesity: An Underutilized Neuromodulatory Treatment for Severely Obese Patients?

Angelika Stapińska-Syniec¹  Anna Kupryjaniuk¹ Michał Sobstyl¹

¹ Department of Neurosurgery, Instytut Psychiatrii i Neurologii, Warsaw, Poland

Address for correspondence Angelika Stapińska-Syniec, MD, Department of Neurosurgery, Instytut Psychiatrii i Neurologii, Sobieskiego 9, Warsaw 02-957, Poland (e-mail: angelika.stapinska@gmail.com).

J Neurol Surg A Cent Eur Neurosurg 2022;83:471–477.

Abstract

Background Morbid obesity (MO) has been steadily increasing in the last few years. Pharmacotherapy and bariatric surgeries remain the main treatment modalities for MO, although in the long-term they may lose their effectiveness. Other treatment approaches are urgently needed and deep brain stimulation (DBS) is a promising therapy. Disturbed energy homeostasis caused by intake of highly palatable and caloric foods may induce hedonic eating. The brain nuclei responsible for energy homeostasis and hedonia are the hypothalamic nuclei and nucleus accumbens. These brain structures constitute the stereotactic targets approached with DBS to treat MO.

Material and Methods We have performed a literature search of all available clinical applications of DBS for MO in humans. We were able to identify three case series reports and additional six case reports involving 16 patients. The selected stereotactic targets included lateral hypothalamus in eight patients, ventromedial hypothalamus in two patients, and nucleus accumbens in six patients.

Results In general, the safety profile of DBS in refractory MO patients was good. Clinical improvement regarding the mean body mass index could be observed in obese patients.

Conclusions MO is a demanding condition. Since in some cases standardized treatment is ineffective, new therapies should be implemented. DBS is a promising therapy that might be used in patients suffering from MO, however, more studies incorporating more individuals and with a longer follow-up are needed to obtain more reliable results concerning its effectiveness and safety profile.

Keywords

- ▶ neurosurgery
- ▶ morbid obesity
- ▶ deep brain stimulation (DBS)
- ▶ nucleus accumbens
- ▶ hypothalamus

Introduction

Obesity is one of the civilization diseases, which afflicts westernized populations, leading to several metabolic complications.¹ According to the World Health Organization (WHO), morbid obesity (MO) is defined as a body mass index (BMI) amounting $\geq 40 \text{ kg/m}^2$ or $\geq 35 \text{ kg/m}^2$ with coexisting obesity-related health conditions for both women and men.^{2,3} It is estimated that between 2005 and 2014 in the

United States there were 7.7% of adults meeting the criteria for MO.⁴ Furthermore, since 1985 MO has been officially recognized as a chronic disease.²

People with obesity are at higher risk of developing other chronic diseases such as hypertension, insulin resistance, diabetes, and cardiovascular diseases.⁵ In addition, obesity is also associated with an elevated risk of carcinogenesis.⁵ Obesity is a risk factor for breast, prostate, or colorectal cancer. Central fat accumulation in children and adolescents

received

April 20, 2021

accepted after revision

September 15, 2021

published online

May 29, 2022

© 2022, Thieme. All rights reserved.

Georg Thieme Verlag KG,

Rüdigerstraße 14,

70469 Stuttgart, Germany

DOI <https://doi.org/>

10.1055/s-0041-1740616.

ISSN 2193-6315.

is correlated with an unfavorable lipid profile and blood lipoprotein concentrations (atherogenic dyslipidemia, hyperlipidemia), higher blood pressure, atherosclerosis, and greater left ventricular mass.^{6,7} Different factors may lead to the development of obesity, including genetic, environmental, socioeconomic, and psychological factors.^{4,8–10} The current treatment options include dieting, physical exercise, pharmacological treatment, psychotherapy, and surgical treatment.^{3,8–10} Surgical treatment is mostly covered by general and gastroenterological surgeons who perform bariatric surgeries, which are considered the most effective type of treatment for obesity.^{11,12}

Deep brain stimulation (DBS) is a safe and proven treatment modality for patients suffering from disabling movement disorders such as Parkinson's disease (PD), dystonia, essential tremor (ET), and also more recently neuropsychiatric conditions such as Tourette's syndrome (TS), major depressive disorder (MDD), obsessive-compulsive disorder (OCD), anorexia nervosa (AN), or epilepsy.¹³ DBS is also a new direction in the treatment of different appetite disorders and MO.^{2,3,14–23} Three neural targets are considered for DBS in MO: lateral hypothalamus (LH), ventromedial hypothalamus (VMH), and nucleus accumbens (NAc)^{2,14,24} (→ Fig. 1).

LH is considered a feeding center. A lot of studies on animal models have shown that lesions in the LH resulted in decreased food intake, weight loss, and *accelerated metabolic rates*.^{15,22,25,26} Lesions of the VMH, which is known as the

satiety center, have been shown to impact the weight in obese animals.³ NAc is an anatomical structure located in the ventral striatum and plays a major role in a reward system, motivation, and action.² In the animal model studies, where the NAc was adopted as the stereotactic target, a decrease in food intake, as well as body weight loss, was observed.^{14,21,27}

The primary aim of the review was to investigate DBS outcomes in individuals with MO based on published reports and evidence. Moreover, we have summarized the criteria for implementing this treatment in severely obese patients. We have searched for all the case reports connected with DBS for MO using the PubMed database. We included magnetic resonance images of those structures targeted by DBS electrodes in MO.

Material and Methods

Using the PubMed search engine and passwords like MO and DBS, we found 23 studies, including 9 studies on the use of DBS in the treatment of MO (→ Tables 1 and 2). So far, 16 participants have been subjected to the DBS procedure, of which 6 are in case reports and 10 in case series. The most frequently chosen stereotactic targets in the treatment of MO are the LH (50% of cases), the NAc (37.5% of cases), and the VMH (12.5% of cases). The NAc is also a stereotactic target in other diseases, including OCD, depression, TS, AN, and alcoholism.^{23,28} The NAc was a stereotactic target in the treatment of six cases, despite many studies on animal models. In more than half of all cases, DBS lead implantations caused weight reduction and decrease in BMI. Even memory improvement was reported in a 2008 study. There were no differences in side effects between women and men. Eight people had side effects, including one successful suicide attempt.

Deep Brain Stimulation for Morbid Obesity (Case Reports)

Hamani et al implanted DBS electrodes bilaterally in the ventral hypothalamus in the case of a 50-year-old man who suffered from MO (BMI: 55.1 kg/m²).²⁹ With the stimulation parameters set at 50 Hz, 3.0 to 4.0 V, and 210 microseconds, the patient lost 12 kg over 5 months and reported reduced food cravings. In the case of this patient, the hypothalamic stimulation modulated a limbic activity and resulted in improvement of certain memory functions. In 2010, Mantione et al presented another case report of a 47-year-old woman with OCD and coexisting obesity, who had DBS electrodes bilaterally implanted in the NAc.³⁰ The stimulation resulted in BMI reduction from 39 to 25 kg/m², and the OCD symptoms disappeared. Wilent et al reported the case of a 19-year-old obese woman, who suffered from a panic attack after bilateral implantation in the VMH.³¹ Harat et al described the case of a 19-year-old woman with hypothalamic obesity due to previous craniopharyngioma surgery. After 3 months of bilateral NAc stimulation, weight reduction from 52.9 to 46.2 kg/m² was observed.³² Talakoub et al reported the case of a patient with Prader-Willi

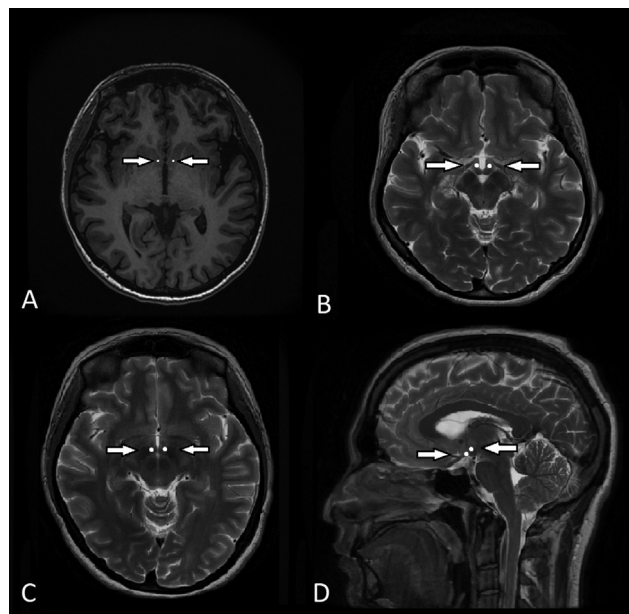


Fig. 1 (A) The visualization of nucleus accumbens (NAc) in 1.5-T magnetic resonance imaging (MRI) T1-weighted image in axial orientation. The nucleus accumbens is marked on the image with white dots. NAc lies medial to the ventral capsule. (B) The ventromedial hypothalamus (VMH) presented on the axial 1.5-T MRI T2-weighted image lies posterior to the optic nerve, anterior to the mammillary body, and inferior to the anterior commissure. (C) The lateral hypothalamus (LH) is demarcated in 1.5-T MRI T2-weighted image in axial orientation. The LH is located superoposterior to the optic nerve and chiasma and inferior to the fornix. (D) The VMH and LH are marked on the sagittal image with white dots. The VMH lies medial and ventral to the LH. The arrows indicate the location of the white dots.

Table 1 A list of published case reports raising the issue of deep brain stimulation for the treatment of morbid obesity

Study	Age and sex	Main diagnosis	Target	Stimulation parameters	Follow-up (months)	Results	Side effects
Hamani et al ²⁹	50♂	MO	VMH (bilateral), stereotactic coordinates of the right electrode tip: 6 mm lateral, 11.7 mm inferior; and 10.5 mm anterior to the MCP; stereotactic coordinates of the left electrode tip: 4.2 mm lateral, 11.3 mm inferior; and 11 mm anterior to the MCP; no microelectrode recording; macrostimulation	Monopolar stimulation: 50 Hz, 210 µs, and 3–4 V	5 months	Decreased appetite, minimal long-term weight change (12 kg over 5 months), improved memory; during the last 4 months, the patient turned the stimulator off in the evenings	Warming sensation, flashes of light, and difficulties in falling asleep
Mantione et al ³⁰	47♀	OCD MO	NAC (bilateral), stereotactic coordinates of the electrode tip: 7 mm lateral, 4 mm inferior to the ACPC line, and 3 mm anterior to the AC	185 Hz, 90 µs, and 3.5 V	24 months	Weight reduction from 39 to 25 kg/m ² ; reduction of obsessive-compulsive symptoms, anxiety, and depression	None
Wilent et al ³¹	50♀	MO	VMH (bilateral), stereotactic coordinates of the left electrode tip: 4.7 mm lateral, 3.8 mm inferior, and 6 mm anterior to the MCP; stereotactic coordinates of the right electrode tip: 8.2 mm lateral, 3.8 mm inferior, and 8 mm anterior to the MCP; microelectrode recording	135 Hz, 60 µs, and 1–7 V	–	–	Panic attack
Harat et al ³²	19♀	MO	NAC (bilateral)	130 Hz, 208 µs, and 2–3.75 mA	14 months	Reduction in BMI from 52.9 to 46.2 kg/m ² ; weight reduction from 151.4 to 132 kg; improvement of cognitive and psychomotor functions	No major adverse effects reported
Talakoub et al ³³	19♂	Obesity Prader-Willi syndrome	LH (bilateral), anatomically based target on MRI-CT images fusion; microelectrode recording; macrostimulation	8 Hz, 90 µs, and 3 V	–	Early feeling of fullness without effects on craving for food	None
Tronnier et al ³⁴	40♀	Depression MO	NAC (bilateral), stereotactic coordinates of the electrode tip: 7 mm lateral, 3 mm anterior to the AC, and 4 mm inferior to the ACPC; microelectrode recording	130 Hz, 90 µs, and 3–4 V	14 months	2.85 kg/months weight reduction	Difficulties in falling asleep

Abbreviations: AC, anterior commissure; ACPC line, anterior commissure–posterior commissure (intercommissural line); BMI, body mass index; MCP, midcommissural point; MO, morbid obesity; NAC, nucleus accumbens; –, data not available; OCD, obsessive-compulsive disorder; VMH, ventromedial hypothalamus.

Table 2 A list of published case series raising the issue of deep brain stimulation (DBS) for the treatment of morbid obesity

Study	No. of patients, sex	Target Targeting method	Stimulation parameters	Follow-up (month)	Results	Side effects
Whiting et al ³⁵	3 (2♀, 1♂)	LH (bilateral), stereotactic coordinates: 6.5 mm lateral to the ACPC line, 3 mm inferior to the ACPC line, and 4.5 mm posterior to the AC; microelectrode recording; macrostimulation	Monopolar or bipolar: 185 Hz, 90 µs, and 1–7 V (standard settings derived from movement disorder DBS programming)	35	Weight reduction; no change in cognitive functions	No major adverse effects reported
Franco et al ³⁶	4 (2♀, 2♂)	LH (bilateral), stereotactic coordinates: 8.3 mm lateral, 7.3 mm inferior, and 5.8 mm anterior to the MCP; no microelectrode recording; macrostimulation	Off (2 month) 40 Hz (1 month) 15-d washout 130 Hz (1 month)	Not found	No major effects on hormonal levels, blood workup, neuro-psychological evaluation, and sleep	2 patients developed mania symptoms, 2 developed infections, with 1 infection resulting in the removal of hardware
Rezai et al ²⁷	3 (3♀)	NAC (bilateral), targeting method not mentioned	Not reported (high-frequency)	36	Reduction of weight and desire to eat, binge eating behaviors, and depressed symptoms; improvement in the quality of life and mood. Two patients did not complete the trial. Following a review of the data from the first 3 subjects, the pilot study was discontinued due to lack of feasibility	One of the patients committed suicide after 27 months into the study

Abbreviations: AC, anterior commissure; ACPC line, anterior commissure–posterior commissure (intercommissural line); LH, lateral hypothalamus; MCP, midcommissural point; NAC, nucleus accumbens.

syndrome who underwent bilateral implantation in the LH.³³ In this case, DBS resulted in the feeling of fullness without an effect on food craving. Tronnier et al described the effect of bilateral NAc stimulation in a 47-year-old obese woman with a history of gastric bypass surgery and drug-resistant depression.³⁴ The weight loss after bariatric surgery was 1.75 kg/month and accelerated to 2.85 kg/month after neurostimulation. The case reports have been presented and summarized in ►Table 1.

Deep Brain Stimulation for Morbid Obesity (Case Series)

In 2013, Whiting et al published a study in which three patients with intractable obesity were implanted bilaterally with DBS electrodes in the LH.³⁵ Even though the patients lost weight, no significant weight reduction trends were seen with stimulation parameters used in movement disorder patients. However, when the monopolar DBS was implemented, a resting metabolic rate measured in a respiratory chamber increased. Rezai et al performed a bilateral implantation into the NAc in three patients with morbid, treatment-refractory obesity, and coexisting psychiatric conditions.²⁷ Only one patient completed a 3-year trial with a reduction in BMI from 55.7 to 39.3 kg/m². Two patients did not complete the study: one of them committed suicide and the other one requested electrode explantation. The authors concluded that neuromodulation itself was not responsible for these events. After a review of the data obtained from the first three subjects, the research group decided to discontinue the study due to lack of feasibility. Franco et al reported four case series of patients with Prader-Willi syndrome.³⁶ After 6 months of bilateral implantation of DBS electrodes in the LH, there was a mean 9.6% increase in weight and a 5.8% increase in BMI. The clinical features including the number of patients enrolled, target with targeting method, stimulation parameters, follow-up period, results, and side effects of the above-mentioned studies are presented in ►Table 2.

Discussion

Because of its rising prevalence, obesity has become a matter of great importance in global health. When conservative treatments fail, surgery becomes a necessity. The main goal of bariatric surgery is restriction of food intake or inducing of short bowel syndrome.^{11,12,14,15} Although bariatric surgeries are considered and have proven to be a highly effective treatment modality, they bear a significant risk of adverse effects.^{11,12} For example, laparoscopic Roux-en-Y gastric bypass that is considered a gold standard bariatric operation is associated with 65% weight loss with over 85% of patients losing and maintaining 50% of initial excess weight loss; however, the procedure is associated with 10 to 15% long-term failure rate.³⁷ Also, this type of treatment might not be effective in some patients. This has forced some investigators to search for new treatment possibilities. Since DBS has proven to be highly effective in numerous movement disorders like PD and dystonia, and as it is gaining popularity in

the treatment of neuropsychiatric conditions, scientists have attempted to apply this method in other indications as well.^{17,23,28,38}

In the last decades, we have had a better insight into understanding the pathophysiology of appetite disorders. Based on the current scientific reports in the field of obesity and the research on animal and human models, there are three main stereotactic targets: NAc, VMH, and LH.^{2,14,24} The NAc is a part of the striatum lying just below the anterior limb of the internal capsule, superolateral to the optic nerve, and anterior to the preoptic area.³⁹ The NAc consists of shell projecting mainly to the limbic system and core projecting to the basal ganglia.⁴⁰ The NAc DBS high-frequency stimulation in animal model studies resulted in caloric intake restriction and weight loss.⁴¹ The VMH is a target lying posterior to the optic nerve, anterior to the mammillary body, and inferior to the anterior commissure.³⁹ The results of animal model studies involving low-frequency stimulation of the VMH showed reduction in body weight and fat, whereas high-frequency stimulation led to increased food intake.^{42,43} The LH is a small target placed inferior to the fornix and superoposterior to the optic nerve and chiasm.³⁹ Animal model studies revealed that low-frequency stimulation of the LH resulted in melanin-concentrating hormone and orexin stimulation, which induces food-seeking behavior, whereas high-frequency stimulation of the LH resulted in weight loss.⁴⁴⁻⁴⁷ Imaging studies, such as functional magnetic resonance imaging (fMRI), might be useful to define the stereotactic target for MO.⁴⁸ Applying DBS in MO also requires a battery of neuropsychiatric tests.¹⁴ For this reason, a multidisciplinary cooperation between clinicians, specialists treating obesity, neurosurgeons, psychiatrists, and neuro-psychologists is absolutely needed.

The implementation of unequivocal inclusion and exclusion criteria for applying DBS in MO patients is an important clinical step. In all of the proposed studies, the main inclusion criterion is the diagnosis of MO in accordance with the WHO criteria. Other criteria include age ≥ 18 years, chronicity of the illness, failure of bariatric surgery, stable at present bodyweight for 6 months, and ability to give informed consent to surgery.¹⁵

Patients between the ages of 18 and 60 years are typically referred for a DBS procedure. The surgery is extremely demanding and may last from 3 to 6 hours. To overcome the surgery-related stress, a patient must be in good physical condition. The exclusion criteria are a treatable underlying cause of MO as well as an active neurologic disease such as movement disorder. An active psychiatric disorder, excluding depression, is another exclusion criterion. Patients with structural changes visible on MRI or a history of brain surgery should be excluded from undergoing DBS surgery. Also, contraindications for MRI examinations, such as a metal, pacemaker, or when the patient is unable to fit in MRI, are the exclusion criteria for DBS. A lot of DBS studies associated with mental illnesses emphasize the necessity of preservation of cognitive functions. Patients should understand the consequences of the procedure to give informed written consent for the procedure.^{17,18,29,36,49} It is also

associated with a better ability to control the patient's mental state.^{21,49} Another exclusion criterion is dementia or an incorrect result in the Mini-Mental State Examination (MMSE).^{29,49} Moreover, the local ethics committee should review each case individually and decide whether a MO patient is suitable for a DBS procedure.

The main advantage of DBS is reversibility and the possibility of applying different stimulation parameters. However, some authors dispute this claim taking into account the possibility of permanent morbidity and other complications related to the possible risk of the procedure.⁵⁰ Despite promising results of preclinical trials addressing DBS in treating MO, the clinical experience concerning human objects remains very limited.⁵¹

Conclusion

MO is a demanding condition. Since in some cases standardized treatment is ineffective, new therapies should be implemented. DBS is a promising therapy that might be used in patients suffering from MO. However, more studies incorporating more individuals and with a longer follow-up are needed to obtain more reliable results concerning its effectiveness and safety profile.

Conflict of Interest

None declared.

References

- Kopp W. How western diet and lifestyle drive the pandemic of obesity and civilization diseases. *Diabetes Metab Syndr Obes* 2019;12:2221–2236
- Whiting AC, Oh MY, Whiting DM. Deep brain stimulation for appetite disorders: a review. *Neurosurg Focus* 2018;45(02):E9
- Melega WP, Lacan G, Gorgulho AA, Behnke EJ, De Salles AA. Hypothalamic deep brain stimulation reduces weight gain in an obesity-animal model. *PLoS One* 2012;7(01):e30672
- Flegal KM, Kruszon-Moran D, Carroll MD, Fryar CD, Ogden CL. Trends in obesity among adults in the United States, 2005 to 2014. *JAMA* 2016;315(21):2284–2291
- San Martin R, Brito J, Siques P, León-Velarde F. Obesity as a conditioning factor for high-altitude diseases. *Obes Facts* 2017;10(04):363–372
- Adamczak M, Gojowy D. Nadciśnienie tętnicze związane z otyłością. *Nt Viamedica* 2014;18(04):224–236
- Martinson ML, Teitler JO, Reichman NE. Health across the life span in the United States and England. *Am J Epidemiol* 2011;173(08):858–865
- Haslam DW, James WP. Obesity. *Lancet* 2005;366(9492):1197–1209
- Szymocha M, Bryła M, Maniecka-Bryła I. Epidemia otyłości w XXI wieku. *Zdr Publ* 2009;119:207–212
- Ahima RS. Digging deeper into obesity. *J Clin Invest* 2011;121(06):2076–2079
- Colquitt JL, Pickett K, Loveman E, Frampton GK. Surgery for weight loss in adults. *Cochrane Database Syst Rev* 2014;(08):CD003641
- Jensen MD, Ryan DH, Apovian CM, et al; American College of Cardiology/American Heart Association Task Force on Practice Guidelines Obesity Society. 2013 AHA/ACC/TOS guideline for the management of overweight and obesity in adults: a report of the American College of Cardiology/American Heart Association Task Force on Practice Guidelines and the Obesity Society. *Circulation* 2014;129(25, Suppl 2):S102–S138
- Lee DJ, Lozano CS, Dallapiazza RF, Lozano AM. Current and future directions of deep brain stimulation for neurological and psychiatric disorders. *J Neurosurg* 2019;131(02):333–342
- Kumar R, Simpson CV, Froelich CA, Baughman BC, Gienapp AJ, Sillay KA. Obesity and deep brain stimulation: an overview. *Ann Neurosci* 2015;22(03):181–188
- Tomycz ND, Whiting DM, Oh MY. Deep brain stimulation for obesity—from theoretical foundations to designing the first human pilot study. *Neurosurg Rev* 2012;35(01):37–42, discussion 42–43
- Dupré DA, Tomycz N, Oh MY, Whiting D. Deep brain stimulation for obesity: past, present, and future targets. *Neurosurg Focus* 2015;38(06):E7
- Nangunoori RK, Tomycz ND, Oh MY, Whiting DM. Deep brain stimulation for obesity: from a theoretical framework to practical application. *Neural Plast* 2016;2016:7971460
- Formolo DA, Gaspar JM, Melo HM, et al. Deep brain stimulation for obesity: a review and future directions. *Front Neurosci* 2019;13:323
- Jáuregui-Lobera I, Martínez-Quifiones JV. Neuromodulation in eating disorders and obesity: a promising way of treatment? *Neuropsychiatr Dis Treat* 2018;14:2817–2835
- Rieu I, Derost P, Ulla M, et al. Body weight gain and deep brain stimulation. *J Neurol Sci* 2011;310(1–2):267–270
- Oterdoom DLM, van Dijk G, Verhagen MHP, et al. Therapeutic potential of deep brain stimulation of the nucleus accumbens in morbid obesity. *Neurosurg Focus* 2018;45(02):E10
- Dalton B, Campbell IC, Schmidt U. Neuromodulation and neurofeedback treatments in eating disorders and obesity. *Curr Opin Psychiatry* 2017;30(06):458–473
- Sobstyl M, Stapińska-Syniec A, Sokół-Szawłowska M, Kupryjaniuk A. Deep brain stimulation for the treatment of severe intractable anorexia nervosa. *Br J Neurosurg* 2019;33(06):601–607
- Halpern CH, Wolf JA, Bale TL, et al. Deep brain stimulation in the treatment of obesity. *J Neurosurg* 2008;109(04):625–634
- Schulkin J, Ruger J. Relation between lateral hypothalamic damage and impairment of sodium appetite: evidence of subcortical mass action. *Behav Neural Biol* 1980;30(01):90–96
- Pandey S, Bhattacharya S. Impact of obesity on gynecology. *Womens Health (Lond)* 2010;6(01):107–117
- Rezai AR, Krishna V, Bogner J, et al. Letter: feasibility of nucleus accumbens deep brain stimulation for morbid, treatment-refractory obesity. *Neurosurgery* 2018;82(05):E136–E137
- Ho AL, Salib AN, Pendharkar AV, Sussman ES, Giardino WJ, Halpern CH. The nucleus accumbens and alcoholism: a target for deep brain stimulation. *Neurosurg Focus* 2018;45(02):E12
- Hamani C, McAndrews MP, Cohn M, et al. Memory enhancement induced by hypothalamic/fornix deep brain stimulation. *Ann Neurol* 2008;63(01):119–123
- Mantione M, van de Brink W, Schuurman PR, Denys D. Smoking cessation and weight loss after chronic deep brain stimulation of the nucleus accumbens: therapeutic and research implications: case report. *Neurosurgery* 2010;66(01):E218, discussion E218
- Wilent WB, Oh MY, Buetefisch CM, et al. Induction of panic attack by stimulation of the ventromedial hypothalamus. *J Neurosurg* 2010;112(06):1295–1298
- Harat M, Rudaś M, Zieliński P, Birska J, Sokal P. Nucleus accumbens stimulation in pathological obesity. *Neurol Neurochir Pol* 2016;50(03):207–210
- Talakoub O, Paiva RR, Milosevic M, et al. Lateral hypothalamic activity indicates hunger and satiety states in humans. *Ann Clin Transl Neurol* 2017;4(12):897–901
- Tronnier VM, Rasche D, Thorns V, Alvarez-Fischer D, Münte TF, Zurovski B. Massive weight loss following deep brain stimulation of the nucleus accumbens in a depressed woman. *Neurocase* 2018;24(01):49–53

- 35 Whiting DM, Tomycz ND, Bailes J, et al. Lateral hypothalamic area deep brain stimulation for refractory obesity: a pilot study with preliminary data on safety, body weight, and energy metabolism. *J Neurosurg* 2013;119(01):56–63
- 36 Franco RR, Fonoff ET, Alvarenga PG, et al. Assessment of safety and outcome of lateral hypothalamic deep brain stimulation for obesity in a small series of patients with Prader-Willi syndrome. *JAMA Netw Open* 2018;1(07):e185275
- 37 Madura JA II, Dibaise JK. Quick fix or long-term cure? Pros and cons of bariatric surgery. *F1000 Med Rep* 2012;4:19
- 38 Gorgulho AA, Pereira JL, Krahl S, Lemaire JJ, De Salles A. Neuro-modulation for eating disorders: obesity and anorexia. *Neurosurg Clin N Am* 2014;25(01):147–157
- 39 Schaltenbrand G, Wahren W, Hassler R. Atlas for stereotaxy of the human brain. . in: *Atlas for Stereotaxy of the Human Brain*. 2nd ed. Stuttgart: Thieme; 1977:84
- 40 Deutch AY, Cameron DS. Pharmacological characterization of dopamine systems in the nucleus accumbens core and shell. *Neuroscience* 1992;46(01):49–56
- 41 Halpern CH, Tekriwal A, Santollo J, et al. Amelioration of binge eating by nucleus accumbens shell deep brain stimulation in mice involves D2 receptor modulation. *J Neurosci* 2013;33(17):7122–7129
- 42 Laćan G, De Salles AA, Gorgulho AA, et al. Modulation of food intake following deep brain stimulation of the ventromedial hypothalamus in the vervet monkey. Laboratory investigation. *J Neurosurg* 2008;108(02):336–342
- 43 Torres N, Chabardes S, Piallat B, Devergnas A, Benabid AL. Body fat and body weight reduction following hypothalamic deep brain stimulation in monkeys: an intraventricular approach. *Int J Obes* 2012;36(12):1537–1544
- 44 Sani S, Jobe K, Smith A, Kordower JH, Bakay RA. Deep brain stimulation for treatment of obesity in rats. *J Neurosurg* 2007;107(04):809–813
- 45 Folkow B, Rubinstein EH. Behavioural and autonomic patterns evoked by stimulation of the lateral hypothalamic area in the cat. *Acta Physiol Scand* 1965;65(04):292–299
- 46 Herberg LJ, Blundell JE. Lateral hypothalamus: hoarding behavior elicited by electrical stimulation. *Science* 1967;155(3760):349–350
- 47 Mendelson J, Chorover SL. Lateral hypothalamic stimulation in satiated rats: T-maze learning for food. *Science* 1965;149(3683):559–561
- 48 Val-Laillet D, Aarts E, Weber B, et al. Neuroimaging and neuro-modulation approaches to study eating behavior and prevent and treat eating disorders and obesity. *Neuroimage Clin* 2015;8:1–31
- 49 Whiting AC, Sutton EF, Walker CT, et al. Deep brain stimulation of the hypothalamus leads to increased metabolic rate in refractory obesity. *World Neurosurg* 2019;121:e867–e874
- 50 Pugh J. No going back? Reversibility and why it matters for deep brain stimulation. *J Med Ethics* 2019;45(04):225–230
- 51 Bétry C, Thobois S, Laville M, Disse E. Deep brain stimulation as a therapeutic option for obesity: a critical review. *Obes Res Clin Pract* 2018;12(03):260–269