



# Transcystic Removal of Common Bile Duct Stones in Surgically Altered Anatomy (Roux-en-Y Gastric Bypass)

Surakshith K. Thyloor<sup>1</sup> Vikas Singla<sup>1</sup> Pradeep Chowbey<sup>2</sup>

<sup>1</sup>Center for Gastroenterology, Hepatology and Endoscopy, Max Super Specialty Hospital, New Delhi, India

<sup>2</sup>Minimal Access, Metabolic and Bariatric Surgery, Max Super Specialty Hospital, New Delhi, India

**Address for correspondence** Surakshith T. K., MD, DNB (gastroenterology), Center for Gastroenterology, Hepatology and Endoscopy, Max Super Specialty Hospital, Saket, New Delhi, India (e-mail: surakshyth@gmail.com).

J Digest Endosc 2021;12:172–174.

## Abstract

### Keywords

- ▶ CBD stone
- ▶ cholangioscope
- ▶ ERCP
- ▶ Roux-en-Y gastric bypass
- ▶ SpyGlass
- ▶ transcystic CBD stone removal

Endoscopic retrograde cholangiopancreatography in patients with surgically altered anatomy can be technically challenging. Various techniques have been described; however, the technical success rate depends on the type of reconstruction, length of the afferent limb, access to the papilla, availability of accessories, and adequate expertise. We describe successful transcystic removal of common bile duct stones in a patient with Roux-en-Y gastric bypass using cholangioscope and SpyGlass retrieval device at the time of cholecystectomy.

## Introduction

Endoscopic retrograde cholangiopancreatography (ERCP) in patients with surgically altered anatomy can be technically challenging. Various techniques have been described; however, the technical success rate depends on the type of reconstruction, length of the afferent limb, access to the papilla, availability of accessories, and adequate expertise.<sup>1</sup> We describe successful transcystic removal of common bile duct (CBD) stones in a patient with Roux-en-Y gastric bypass (RYGB) using cholangioscope and SpyGlass retrieval device at the time of cholecystectomy (**Video 1**).

### Video 1

Transcystic removal of common bile duct stones in a patient with Roux-en-Y gastric bypass. Online content including video sequences viewable at: <https://www.thieme-connect.com/products/ejournals/html/10.1055/s-0041-1739970>.

## Case Presentation

A 64-year-old female, presented with history of right upper abdominal pain for 7 days. She had no comorbidities but had undergone RYGB for morbid obesity in 2017. On examination, mild tenderness was noted in the right hypochondrium. Liver function tests showed normal bilirubin level 1.1 mg/dL with elevated alanine aminotransferase 103 U/L, aspartate aminotransferase 144 U/L, and also raised alkaline phosphatase (ALP) and gamma glutamyl transferase (GGT) 731 and 370, respectively. Ultrasound abdomen showed dilated CBD (10 mm), cholelithiasis with pericholecystic fluid. MRCP Magnetic Resonance Cholangio-Pancreatography was done which showed choledocholithiasis (two stones), dilated CBD approximately 10 mm with centrally dilated biliary radicals, and minimal pericholecystic fluid. In the view of altered anatomy (RYGB), she was planned for transcystic CBD exploration and stone extraction during laparoscopic cholecystectomy. Decision was taken after discussing the CBD anatomy with the radiologist and the surgeon. The procedure was done in the operating theater after prior informed consent explaining the procedures and related complications to the

**DOI** <https://doi.org/10.1055/s-0041-1739970>  
**ISSN** 0976-5042

© 2021. Society of Gastrointestinal Endoscopy of India.

This is an open access article published by Thieme under the terms of the Creative Commons Attribution-NonDerivative-NonCommercial-License, permitting copying and reproduction so long as the original work is given appropriate credit. Contents may not be used for commercial purposes, or adapted, remixed, transformed or built upon. (<https://creativecommons.org/licenses/by-nc-nd/4.0/>).

Thieme Medical and Scientific Publishers Pvt. Ltd. A-12, 2nd Floor, Sector 2, Noida-201301 UP, India

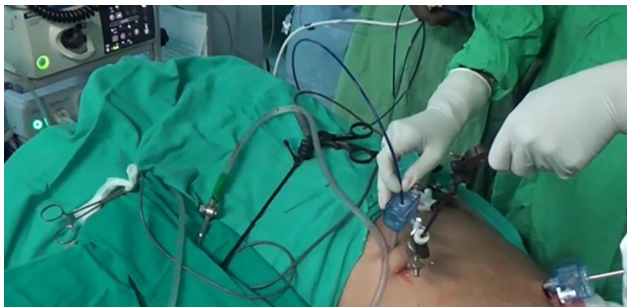patient. After the laparotomy and dissection of the Calots triangle, cystic artery was divided. The cystic duct was isolated and partially cut open. Cholangioscope (SpyGlass Direct Visualization System; Boston Scientific, Natick, Massachusetts, United States) was introduced through the umbilical port (►Fig. 1) and into the CBD through the cystic duct opening. The cholangioscope was maneuvered using a grasper. Countertraction during the CBD exploration maneuvers was provided through another grasper by holding at the neck of the gall bladder. Continuous saline irrigation was done during cholangioscopy. Under direct vision, Spyglass retrieval basket was advanced beyond the stone and deployed. Basket was then slowly withdrawn to grasp the stone. Stone was removed by milking the cystic duct (►Fig. 2) and subsequently retrieved from the peritoneal cavity using a spoon forceps. Another large stone was visualized within the CBD; however, due to its larger size, could not be grasped by the Spyglass retrieval basket. Hence, a Dormia basket was introduced through the same port beside the cholangioscope (►Fig. 3). Under direct visualization, the stone was grasped using the Dormia basket and stone was retrieved as before (►Fig. 4). Cholangioscope was reintroduced through the infraumbilical port and was maneuvered into the common hepatic duct (CHD) and the confluence, to check for any residual stones. Cholangiogram was done

to confirm CBD clearance and then cholecystectomy was completed.

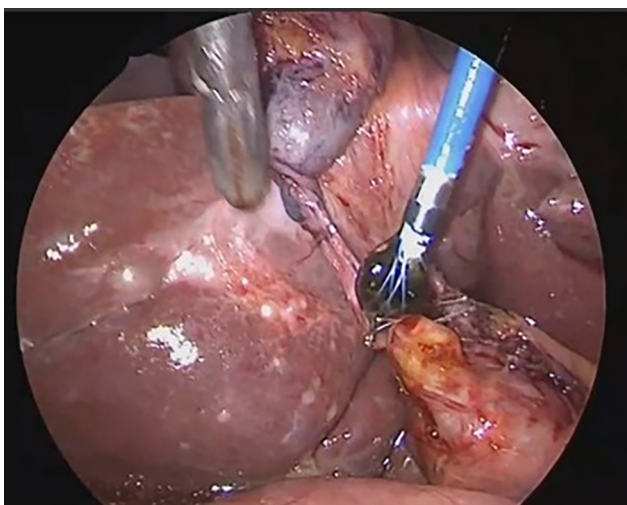
## Discussion

In individuals with surgically changed anatomy, ERCP can be difficult. The technical success rate is dependent on the type of reconstruction, length of the afferent limb, access to the papilla, availability of accessories, and enough skill. In bariatric surgery, RYGB involves creating a long afferent limb (>100 cm). Postbariatric surgery, due to rapid weight loss, these patients are at risk of gall stone diseases.<sup>2</sup> Cholelithiasis is common and is seen in around 40% within 6 months of surgery and up to 7 to 8% of them can develop biliary complications.<sup>3,4</sup> In RYGB patients, because of adhesion formation, angulation of the jejunojejunal anastomosis, and figure-eight looping of the scope, the therapeutic success rate of peroral endoscopic ERCP using a pediatric colonoscope or device-assisted ERCP is very low (59%).<sup>5</sup> Laparoscopic CBD exploration carries significant morbidity (2–6% of bile leak, retained stones, and 1–10% risk of infection) and mortality (0.25%).<sup>6</sup> Newer techniques, like endoscopic ultrasonography (EUS)-guided biliary drainage (EUS-BD) and laparoscopic-assisted transgastric ERCP (LA-ERCP), have higher technical success rates of 80 to 100%.<sup>7</sup> However, EUS-BD is traditionally done as a two-stage procedure and requires EUS expertise.<sup>8</sup> In LA-ERCP, because only a small portion of the scope is inside the gastrotomy site, maintaining scope stability for negotiation through the pylorus into the second part of the duodenum and proper orientation for cannulation is difficult, requiring coordination with the operating surgeon and ERCP expertise. LA-ERCP like the peroral endoscopic ERCP carries the risk of pancreatitis.

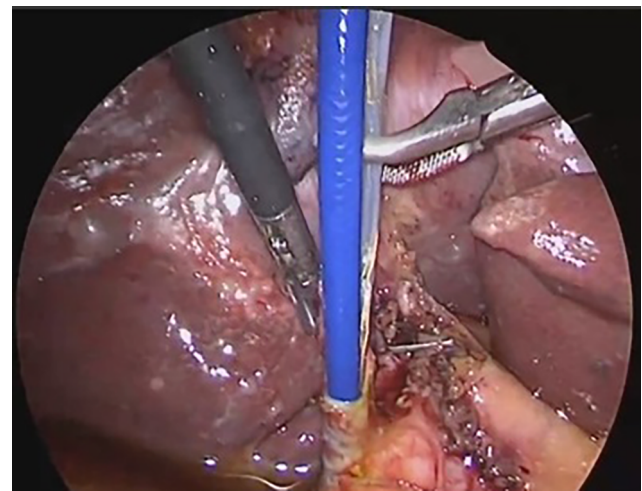
The therapeutic capability of cholangioscopy is increasing with technical advances and greater availability. The advantage of transcystic cholangioscopic approach for removal of CBD stones in a patient with altered anatomy circumvents



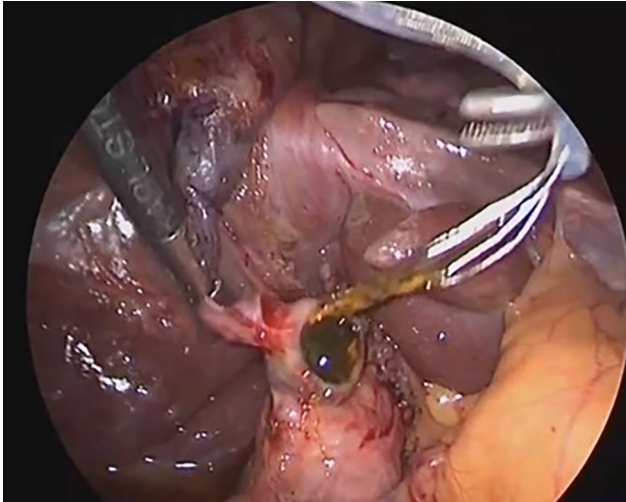
**Fig. 1** Introduction of the cholangioscope through the partially cut open cystic duct.



**Fig. 2** Stone retrieval using SpyGlass retrieval basket through the cystic duct.



**Fig. 3** Introduction of Dormia basket besides the cholangioscope, through the same laparoscopic port.



**Fig. 4** Retrieval of larger stone using Dormia basket and milking the stone out of cystic duct.

the need for CBD incision, hence fewer postoperative complications and stone capture can be directly visualized. Also, it does not require additional expertise and also reduces the operating time. Technical difficulties that can be faced during transcystic approach are large or impacted stones, lower insertion, or altered cystic duct anatomy. Hence, prior imaging and planning is required. Additional holmium laser lithotripsy or electrohydraulic lithotripsy (EHL) can solve the problem of impacted or large stones.

#### **Conflict of Interest**

None declared.

#### **References**

- 1 Krutsri C, Kida M, Yamauchi H, Iwai T, Imaizumi H, Koizumi W. Current status of endoscopic retrograde cholangiopancreatography in patients with surgically altered anatomy. *World J Gastroenterol* 2019;25(26):3313–3333
- 2 Shiffman ML, Sugeran HJ, Kellum JM, Brewer WH, Moore EW. Gallstone formation after rapid weight loss: a prospective study in patients undergoing gastric bypass surgery for treatment of morbid obesity. *Am J Gastroenterol* 1991;86(8):1000–1005
- 3 Deitel M, Petrov I. Incidence of symptomatic gallstones after bariatric operations. *Surg Gynecol Obstet* 1987;164(6):549–552
- 4 Snauwaert C, Laukens P, Dillemans B, et al. Laparoscopy-assisted transgastric endoscopic retrograde cholangiopancreatography in bariatric Roux-en-Y gastric bypass patients. *Endosc Int Open* 2015;3(5):E458–E463
- 5 Schreiner MA, Chang L, Gluck M, et al. Laparoscopy-assisted versus balloon enteroscopy-assisted ERCP in bariatric post-Roux-en-Y gastric bypass patients. *Gastrointest Endosc* 2012;75(4):748–756
- 6 Horwood J, Akbar F, Davis K, Morgan R. Prospective evaluation of a selective approach to cholangiography for suspected common bile duct stones. *Ann R Coll Surg Engl* 2010;92(3):206–210
- 7 Lopes TL, Clements RH, Wilcox CM. Laparoscopy-assisted ERCP: experience of a high-volume bariatric surgery center (with video). *Gastrointest Endosc* 2009;70(6):1254–1259
- 8 Attam R, Leslie D, Freeman M, Ikramuddin S, Andrade R. EUS-assisted, fluoroscopically guided gastrostomy tube placement in patients with Roux-en-Y gastric bypass: a novel technique for access to the gastric remnant. *Gastrointest Endosc* 2011;74(3):677–682