



# Strategy for the Conservative Treatment of Type-III Camptodactyly in Children with Beals-Hecht Syndrome

## *Estratégia para o tratamento conservador da camptodactilia de tipo III em criança com síndrome de Beals-Hecht*

Maria da Conceição Soares de Oliveira<sup>1</sup> Saulo Fontes Almeida<sup>2</sup> Anderson Vieira Monteiro<sup>2</sup>  
 Maria Caroliny Soares de Oliveira<sup>3</sup> Felipe Soares Figueiredo<sup>3</sup> Diego Pinheiro Aguiar<sup>3,4</sup>

<sup>1</sup> Rehabilitation Area, Instituto Nacional de Traumatologia e Ortopedia, Rio de Janeiro, RJ, Brazil

<sup>2</sup> Hand Surgery Center, Instituto Nacional de Traumatologia e Ortopedia, Rio de Janeiro, RJ, Brazil

<sup>3</sup> Research Department, Instituto Nacional de Traumatologia e Ortopedia, Rio de Janeiro, RJ, Brazil

<sup>4</sup> Biomodels and Prototyping Laboratory, Centro Universitário Estadual da Zona Oeste, Rio de Janeiro, RJ, Brazil

Address for correspondence: Maria da Conceição Soares de Oliveira, Avenida Brasil, 500, Caju, Rio de Janeiro, RJ, 20940-070, Brazil (e-mail: mcsoaresto@gmail.com).

Rev Bras Ortop 2024;59(3):e485–e488.

### Abstract

#### Keywords

- ▶ congenital hand deformities
- ▶ finger joints
- ▶ orthoses
- ▶ rehabilitation

### Resumo

#### Palavras-chave

- ▶ articulações dos dedos
- ▶ deformidades congênicas da mão
- ▶ órteses
- ▶ reabilitação

The authors present a successful case in the conservative treatment of type-III camptodactyly in a patient with Beals-Hecht syndrome. Camptodactyly is a flexion deformity of the proximal interphalangeal (PIP) joint, in the anteroposterior direction, painless and bilateral in 2/3 of the cases. Type-III is the most severe and disabling form, as it usually affects several fingers and is associated with syndromes and other malformations. The case herein reported had the correction achieved with the systematic use of static orthoses started at 7 months of age and completed after 23 and a half months of the intervention.

Os autores apresentam um caso bem-sucedido no tratamento conservador da camptodactilia de tipo III em paciente com síndrome de Beals-Hecht. A camptodactilia é uma deformidade em flexão da articulação interfalangeana proximal (IFP), no sentido anteroposterior, indolor, e bilateral em 2/3 dos casos. A de tipo III é a forma mais grave e incapacitante, pois geralmente acomete vários dedos e está associada a síndromes e outras malformações. O caso apresentado teve a correção alcançada com o uso sistemático de órteses estáticas iniciado aos 7 meses de idade e concluído após 23 meses e meio de intervenção.

*Work developed at the Research Division, Instituto Nacional de Traumatologia e Ortopedia Jamil Haddad, Rio de Janeiro, RJ, Brazil.*

received  
November 9, 2020  
accepted  
March 8, 2021

DOI <https://doi.org/10.1055/s-0041-1739401>.  
ISSN 0102-3616.

© 2021. The Author(s).

This is an open access article published by Thieme under the terms of the Creative Commons Attribution 4.0 International License, permitting copying and reproduction so long as the original work is given appropriate credit (<https://creativecommons.org/licenses/by/4.0/>).

Thieme Revinter Publicações Ltda., Rua do Matoso 170, Rio de Janeiro, RJ, CEP 20270-135, Brazil

## Introduction

Camptodactyly is a flexion deformity of the proximal interphalangeal (PIP) joint of congenital and non-traumatic origin. It is a rare condition, with a prevalence of approximately 1%, with the fifth finger being the most affected.<sup>1</sup> It is classified into types I, II and III. Type I: infantile camptodactyly, which usually affects the little finger in isolation. Type II: adolescent camptodactyly, which has a rapid evolution with the growth spurt. Type III: present at birth, it affects several fingers, and is associated with other syndromes. Camptodactyly affects structures that cross the joint, and they are implicated as one of the possible causes. Changes in the skin, aponeurosis, tendons, lumbrical muscle, superficial flexor muscle of the fingers and ligaments can be found.<sup>1</sup> The initial treatment is conservative, with the use of orthoses and passive stretching, or surgical stretching.<sup>2</sup> In cases in which flexion of the PIP joint is  $\geq 60^\circ$ , surgery is the choice procedure.<sup>3,4</sup>

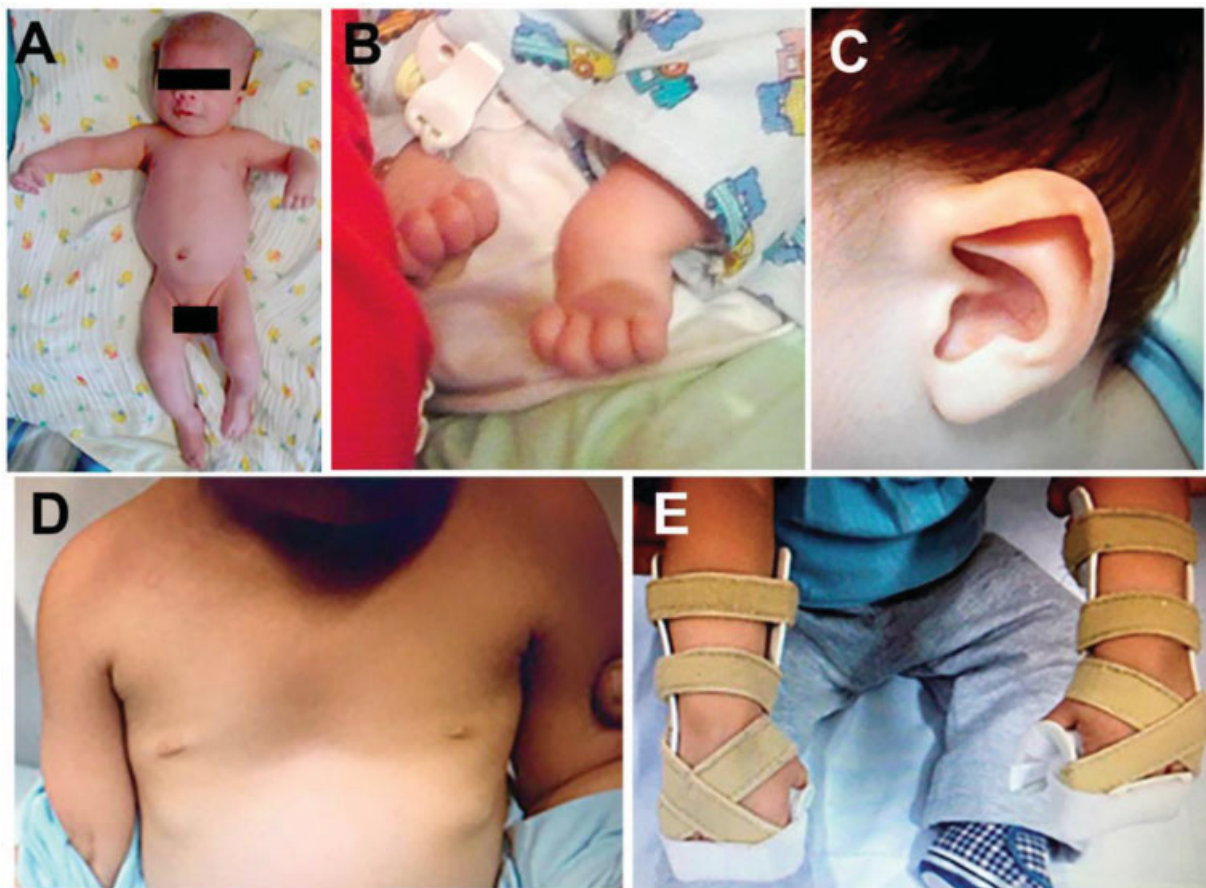
Beals-Hecht syndrome is a rare syndrome diagnosed in less than 1 in 10 thousand patients worldwide.<sup>5,6</sup> The clinical picture consists of congenital contractures of multiple joints,<sup>7</sup> long and slender limbs, congenital contratural arachnodactyly, kyphoscoliosis, and anomalies of the auricular

pavilions.<sup>3</sup> The contractures may reduce in severity, but the camptodactyly present in the fingers persists.<sup>7</sup>

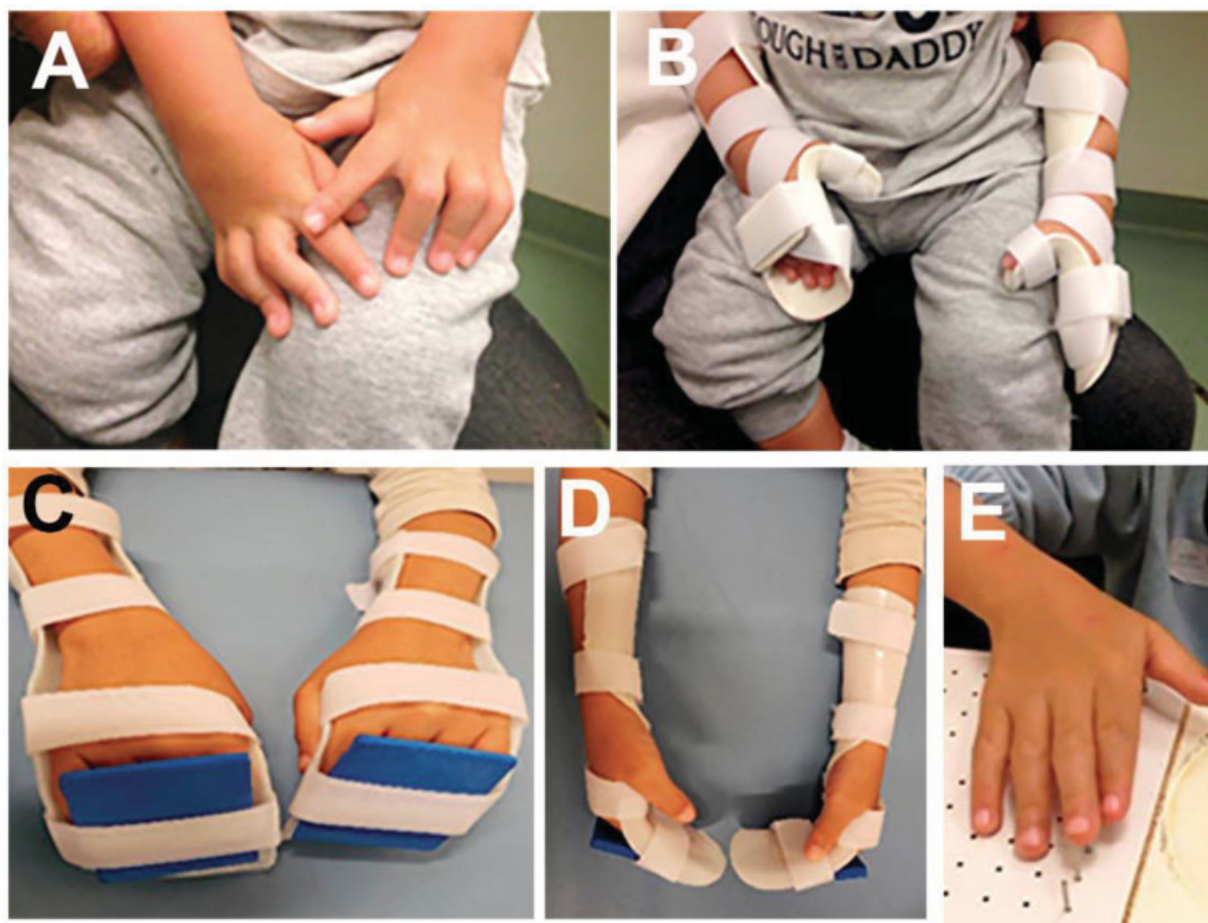## Case Report

A 6-month-old white male patient cared for at the Hand Surgery Outpatient Clinic of our institution for the first time in October 2013. The presence of some clinical signs was observed: PIP joint flexion of the middle, ring and little fingers, flexion of the wrists and hyperextension of the metacarpophalangeal (MCP) joints bilaterally, changes in the auricular pavilion, and pectus excavatum. All the contractures present were rigid. He was diagnosed with type-III camptodactyly, and we opted for the conservative treatment with orthotization in November 2013. The initial goniometry of the patient was not performed due to the difficulty in execution, and a photographic record was made (**Fig. 1A-E**). The flexion contractures of the PIP joint presented more than  $90^\circ$ . The use of static orthoses was initially uninterrupted,<sup>8</sup> and the follow-up visits occurred every three months for adjustments in the orthoses or to change them.

The orthotization process began at seven months of age. The initial objective was to reach the neutral position of the



**Fig. 1** Phenotypic features of the patient with Beals-Hecht syndrome. Two-month-old patient (A) with deformities in the wrist and metacarpophalangeal and proximal interphalangeal joints (B), anomalies in the auricular pavilion (C), pectus excavatum (D), and positioning orthosis with dorsal support (E).



**Fig. 2** Demonstration of the evolution of the conservative treatment of the patient with camptodactyly. Beginning of the correction (A), positioning orthosis with maintenance of the dorsal support (B), nocturnal orthosis with free thumbs and ethylene-vinyl acetate (EVA) plate in the dorsal region of the fingers (C), nightly use of orthosis in lateral view (D) and complete extension of fingers (E).

PIP joint flexion, wrist flexion and MCP joint hyperextension, achieved in February 2015 (►Fig. 2 A-E).

After reaching the neutral position, the orthosis was modified, starting with a slight flexion of the MCP joint and dorsal support device following the angulation of the orthosis to exert pressure on the fingers against the orthosis, thus maintaining the position besides assisting the flexion of the MCP. From July 2015, already at 26 months, the orthosis began to be made with free thumbs, flexed MCP joint, and wrist in extension (►Fig. 2, A-D).

The orthoses started to be used only at night, around 8 p. m., since June 2016. Correction of the camptodactyly was achieved (►Fig. 2E and ►Fig. 3A-C).

### Discussion

In this case of rigid type-III camptodactyly in children with Beals-Heacht syndrome, early intervention<sup>9</sup> with static orthoses provided a satisfactory outcome with the regression of the deformity and the achievement of functional use of the



**Fig. 3** Morphology of the upper limb after conservative treatment for 23 and a half months. Supine position with the fingers in extension (A), side view (B), fingers in flexion (C).

hands. The use of orthoses should be the first choice for the beginning of the treatment, even syndromic cases.<sup>9</sup>

The multiplicity of structures involved in camptodactyly that are responsible for joint imbalance can reach balance with tissue remodeling using orthoses.<sup>9</sup>

The use of orthoses to remodel musculoskeletal tissue is a low-complexity option, but there is a need for a relatively long period of use for the remodeling to occur.<sup>10</sup>

The use of the dorsal support device optimized the elongation of the structures responsible for flexion contracture in the PIP joint.

Clinical follow-up of the patient in question will be maintained until the end of the skeletal growth to avoid possible recurrence of soft-tissue contractures.<sup>4,8</sup>

The involvement of the family and their collaboration made a difference in the conservative treatment. The intervention is relatively long and exhaustive, but necessary.<sup>10</sup>

#### Financial Support

There was no financial support from public, commercial, or non-profit sources.

#### Conflict of Interests

The authors have no conflict of interests to declare.

#### References

- 1 Salazard B, Quilici V, Samson P. [Camptodactyly]. *Chir Main* 2008; 27(Suppl 1):S157–S164
- 2 Wang AMQ, Kim M, Ho ES, Davidge KM. Surgery and Conservative Management of Camptodactyly in Pediatric Patients: A Systematic Review. *Hand (N Y)* 2019;15(06):761–770
- 3 Evans BT, Waters PM, Bae DS. Early Results of Surgical Management of Camptodactyly. *J Pediatr Orthop* 2017;37(05):e317–e320
- 4 Almeida SF, Monteiro AV, Lanes RCS. Evaluation of treatment for camptodactyly: retrospective analysis on 40 fingers. *Rev Bras Ortop* 2014;49(02):134–139
- 5 Jurko A Jr, Krsiakova J, Minarik M, Tonhajzerova I. Congenital contractural arachnodactyly (Beals-Hecht syndrome): a rare connective tissue disorder. *Wien Klin Wochenschr* 2013;125(9-10):288–290
- 6 Tunçbilek E, Alanay Y. Congenital contractural arachnodactyly (Beals syndrome). *Orphanet J Rare Dis* 2006;1:20
- 7 Meena JP, Gupta A, Mishra D, Juneja M. Beals-Hecht syndrome (congenital contractural arachnodactyly) with additional cranio-spinal abnormality: a case report. *J Pediatr Orthop B* 2015;24(03): 226–229
- 8 Hori M, Nakamura R, Inoue G, et al. Nonoperative treatment of camptodactyly. *J Hand Surg Am* 1987;12(06):1061–1065
- 9 Benson LS, Waters PM, Kamil NI, Simmons BP, Upton J 3rd. Camptodactyly: classification and results of nonoperative treatment. *J Pediatr Orthop* 1994;14(06):814–819
- 10 Lethbridge K, Wollin L. A review of conservative management of camptodactyly in children and adolescent. *Hand Ther* 2014;19 (04):93–101